

EYELID & CONJUNCTIVAL TUMORS



PHOTOGRAPHIC ATLAS

Dr. Olivier Galatoire

Dr. Christine Levy-Gabriel

Dr. Mathieu Zmuda




Dear readers,

All rights of translation, adaptation, or reproduction by any means are reserved in all countries.

The reproduction or representation, in whole or in part and by any means, of any of the pages published in the present book without the prior written consent of the publisher, is prohibited and illegal and would constitute an infringement.

Only reproductions strictly reserved for the private use of the copier and not intended for collective use, and short analyses and quotations justified by the illustrative or scientific nature of the work in which they are incorporated, are authorized (Law of March 11, 1957 art. 40 and 41 and Criminal Code art. 425).



**Any
Reproduction
prohibited**

Foreword

Dr. Serge Morax

I am honored to introduce this Photographic Atlas of palpebral and conjunctival tumors, which is the culmination of the close collaboration between Drs. Olivier Galatoire and Mathieu Zmuda of the A. de Rothschild Ophthalmological Foundation and Dr. Christine Levy-Gabriel of the Curie Institute.

The subject is now of unquestionable importance and evidently of great interest to Ophthalmologists, whether they are orbital- palpebral specialists or not.

Indeed, errors or delays in the diagnosis of tumor pathologies are relatively common and the consequences can be serious in the case of malignant tumors, especially carcinomas.

Swift diagnosis and anatomopathological confirmation will lead to a treatment, discussed in multidisciplinary team meetings, ranging from surgery to radiotherapy.

Ophthalmologists must, therefore, be familiar with the main palpebral-conjunctival tumoral lesions and learn how to recognize them. For most benign lesions, the treatment must be simple. For suspicious or malignant lesions, patients should be referred to a specialist department.

This book, in the form of an Atlas, was produced with the support of Laboratoires Théa and is part of a collection of Atlases focusing on images extremely useful to Ophthalmologists. There are numerous, high-quality illustrations. Most of the chapters, classified according to the anatomopathology, are easy to read and very explicit. Without citing them all, the chapter on vascular tumors particularly caught my eye; they are wonderfully described, classified, and presented.

This Atlas on a topical subject must play an increasingly important role in the field of our activities and be of invaluable service to practitioners and patients.

Many thanks to Laboratoires Théa for this wonderful initiative.

Preface

Dr. Olivier Galatoire

Dear readers,

I would firstly like to thank Henri and Jean-Frédéric Chibret, as well as Laboratoires Théa, for entrusting me with overseeing this book dedicated to eyelid and conjunctival tumors.

After reading the various books published by Laboratoires Théa, the idea of creating a photographic Atlas in Oculoplastics seemed obvious to me and the subject of eyelid and conjunctival tumors was quickly settled on.

The etiological diagnosis of these tumors is not always easy. These lesions are common and ophthalmologists are confronted with complicated diagnosis on a daily basis.

Indeed, the etiologies and therapeutic consequences are extremely varied, from common, benign lesions that regress spontaneously, to serious lesions that require significant surgical resection and can be life-threatening. Therefore, it seemed necessary to create a didactic photographic book to assist practitioners in the diagnosis of palpebral and conjunctival lesions.

This atlas is essentially descriptive, to guide the practitioner in their diagnostic approaches. Once the etiology has been determined, the practitioner can then provide the patient with the most suitable treatment or refer him/her to an ophthalmologist oncologist oculoplastic surgeon.

I would like to thank Dr. Christine Levy-Gabriel who works with Professor Nathalie Cassoux at the Curie Institute and Dr. Mathieu Zmuda who works by my side me at the A. de Rothschild Foundation for helping me write this book, which is the result of the close collaboration between our two close, complementary teams.

Our cross-disciplinary activity initiated by Drs. Serge Morax and Laurence Desjardins with the establishment of multidisciplinary consultation meetings has been a success for about ten years.

I would like to thank my colleague Véronique Dauvin for her diligent help with writing this book, as well as Olivier Skypala, photographer, for the quality of his pictures.

I would also like to thank Mrs. Caroline Loubier from THÉA Laboratories and Dr. Elisabeth Millara for their support.

Thereby, we hope this Atlas will help you establish an accurate diagnosis of eyelid and conjunctival tumors with which you will be confronted and will enable you to distinguish what is serious from what is not.

Happy reading to you all.

Acknowledgments

A. de Rothschild Foundation

Dr. Sophie Azria
Dr. Paul Benillouche
Dr. Samuel Derman
Dr. Edgard Farah
Dr. Marie-Laure Herdan
Dr. Pierre-Vincent Jacomet
Mrs. Spomenka Jovanovic
Dr. Laurent Le
Mrs. Carine Lea
Dr. Marc Putterman
Mrs. Nadia Sadi

Curie Institute

Dr. Valentin Calugaru
Dr. Nathalie Cassoux
Dr. Didier Decaudin
Dr. Rémi Dendale
Dr. Laurence Desjardins
Dr. Frédérique Kuhnowski
Dr. Livia Lumbroso-Le Rouic



Dr. Olivier Galatoire

Ophthalmologist
Head of Department
Orbital Palpebral
Reconstructive Plastic Surgery
A. de Rothschild Foundation - Paris

Dr. Christine Levy-Gabriel

Ophthalmologist
Specialist Practitioner
Curie Institute - Paris

Dr. Mathieu Zmuda

Ophthalmologist
Practitioner
Orbital Palpebral
Reconstructive Plastic Surgery
A. de Rothschild Foundation – Paris

Table of contents

SECTION 1

PALPEBRAL TUMORS - Olivier Galatoire - Mathieu Zmuda

1. Epithelial tumors	19
1.1. Benign epithelial tumors	20
1.1.1. Molluscum contagiosum.....	20
1.1.2. Molluscum pendulum.....	23
1.1.3. Seborrheic keratosis	24
1.2. Precancerous lesions	28
1.2.1. Actinic keratosis	28
1.2.2. Xeroderma pigmentosum.....	30
1.3. Malignant epithelial tumors.....	31
1.3.1. Keratoacanthoma	31
1.3.2. Epidermoid carcinoma <i>in situ</i>	33
1.3.3. Infiltrating epidermoid carcinoma.....	36
1.3.4. Undifferentiated epidermoid carcinoma	41
1.3.5. Basal cell carcinoma	44
1.3.5.1. Nodular.....	45
1.3.5.2. Ulcerated	54
1.3.5.3. Pigmented.....	59
1.3.5.4. Sclerodermiform	60
2. Sebaceous tumors	67
2.1. Benign sebaceous tumors	68
2.1.1. Chalazion.....	68
2.1.2. Sebaceous cyst	71
2.1.3. Cyst of Zeiss	73
2.1.4. Miliun	74
2.1.5. Sebaceous hyperplasia	75
2.2. Malignant sebaceous tumors	78
2.2.1. Sebaceous carcinoma	79

3. Adnexal tumors	85
3.1. Tumors of the hair follicle.....	86
3.1.1. Trichofolliculoma.....	87
3.1.2. Pilomatrixoma	89
3.1.3. Trichoblastoma.....	91
3.1.4. Trichoepithelioma.....	92
3.2. Tumors of the sweat gland.....	94
3.2.1. Eccrine hidrocystoma	94
3.2.2. Apocrine cystadenoma	98
3.2.3. Syringocystadenoma papilliferum.....	102
3.2.4. Syringoma	103
3.2.5. Desmoplastic syringoma.....	105
4. Melanic tumors	107
4.1. Ephelides.....	109
4.2. Nevus.....	110
4.2.1. Junctional	110
4.2.2. Compound	111
4.2.3. Dermal	112
4.2.4. Of Ota.....	114
4.2.5. Kissing nevus.....	115
4.3. Malignant lentigo	117
4.4. Extensive superficial melanoma	118
4.5. Nodular melanoma.....	119
5. Vascular tumors	121
5.1. Vascular tumors.....	122
5.1.1. Infantile hemangioma	123
5.1.2. Congenital hemangioma	126
5.1.3. Pyogenic granuloma.....	127
5.2. Vascular malformations	130
5.2.1. Capillary malformation.....	131
5.2.2. Lymphangioma	132
5.2.3. Venous malformation	134
5.2.4. Venous and arterial malformation	138
5.2.5. Arterial malformation	142
5.3. Arteriovenous fistula.....	143
5.3.1. Direct	143
5.3.2. Indirect.....	144

6. Fibro-muscular tumors.....	147
6.1. Lipoma.....	148
6.2. Keloid.....	150
6.3. Xanthelasma.....	151
6.4. Juvenile xanthogranuloma	157
6.5. Xanthogranulomatosis	159
6.6. Rhabdomyosarcoma.....	162
6.7. Kaposi's sarcoma.....	163
6.8. Fibrosarcoma	165
7. Nerve tumors	167
7.1. Plexiform neuroma	168
7.2. Neurofibroma.....	169
7.3. Merkel cell carcinoma	171
8. Lymphoid tumors.....	175
8.1. B-cell lymphoma	177
8.2. T-cell lymphoma.....	184
9. Infectious diseases.....	187
9.1. Herpes	188
9.2. Chickenpox/shingles	189
9.3. Impetigo	191
9.4. Cellulitis	192
9.5. Abscess.....	193
10. Inflammatory diseases	197
10.1. Rosacea	198
10.2. Eczema	200
10.3. Atopic dermatitis	203
10.4. Psoriasis	204
10.5. Blepharochalasis syndrome	205
10.6. Seborrheic dermatitis.....	207
10.7. Ichthyosis.....	208
10.8. Vitiligo.....	209
10.9. Photoaging.....	210
10.10. Sarcoidosis	212
10.11. Dermatomyositis.....	214
10.12. IgG4 inflammation	215

SECTION 2

CONJUNCTIVAL TUMORS - CHRISTINE LEVY-GABRIEL²

1. Choristoma	219
1.1. Dermoid	221
1.2. Dermolipoma	222
2. Epithelial tumors	225
2.1. Papilloma	226
2.2. Conjunctival dysplasia and carcinoma <i>in situ</i>	229
2.3. Epidermoid carcinoma	237
3. Melanocytic tumors	241
3.1. Ethnic melanosis	242
3.2. Nevus	243
3.3. Precancerous Reese melanosis	246
3.4. Melanoma	249
4. Glandular tumors	257
4.1. Oncocytoma	259
4.2. Sebaceous adenoma	260
4.3. Sebaceous carcinoma	262
5. Lymphoproliferative tumors	265
5.1. Benign reactive lymphoid hyperplasia	266
5.2. Lymphoma	267
6. Vascular tumors	271
6.1. Pyogenic granuloma	272
6.2. Capillary angioma (child), cavernous angioma (venous)	273
6.3. Lymphangiectasia, lymphangioma	274
6.4. Kaposi's sarcoma	276
7. Stromal tumors	279
7.1. Fibrohistiocytic: juvenile xanthogranuloma, fibrous histiocytoma	280
7.2. Nerve: schwannoma	282

SECTION 1

Palpebral tumors

Olivier Galatoire - Mathieu Zmuda

Introduction

The eyelid comprises tissues of diverse origins in a very small space that can degenerate malignantly or benignly, resulting in a rich and varied palette of tumor pathologies. The skin covering the eyelid is very thin and exposed to a lot of light, which explains the predominance of epithelial tumors.

There are also numerous skin appendages with characteristics specific to the eyelid, especially the meibomian glands that are essential to the quality of the tear film. Being highly vascularized, this area is prone to numerous vascular lesions and can be the site of the transformation of fatty, muscle, and nerve tissues.

Finally, the particularity of having one side of the conjunctiva in contact with the environment makes it extremely prone to lymphoid pathologies. We recall that the key role of the eyelid is to protect the eyeball by fighting more particularly against foreign bodies thanks to the eyelashes and blinking. It actively participates in regulating corneal hydration through the secretion of components of the tear film and helping to spread the latter.

The eyelid also plays a fundamental role in eye esthetics. In clinical practice, this often results in small lesions causing greater discomfort and which in another location would go unnoticed.

For the sake of simplicity, we have chosen to classify the tumors according to their histological origin.

Practitioners will always be confronted with issues regarding diagnosis and treatment.

Our role is, therefore, to guide and advise patients with any palpebral lesion.

1. Epithelial tumors

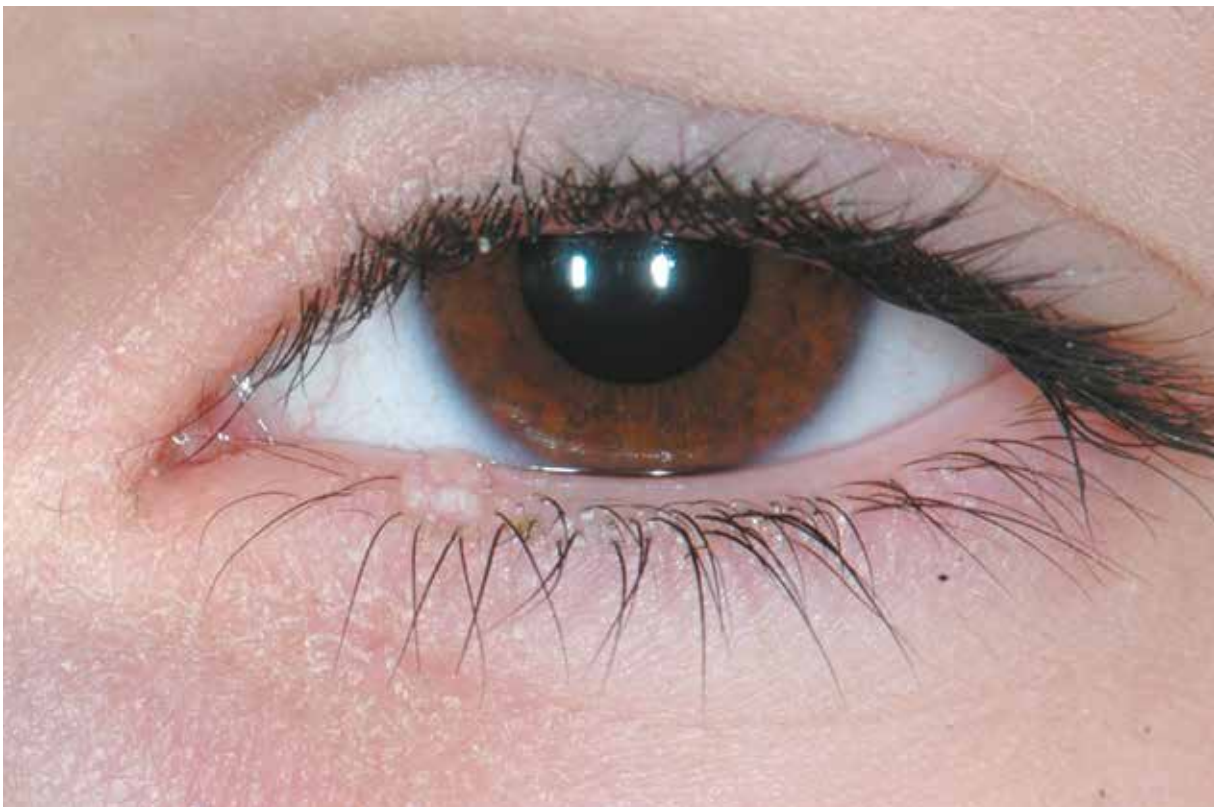Molluscum contagiosum

Viral infection of the skin and palpebral mucosa.

Viral infections of the skin and palpebral mucosa exhibit a broad spectrum of clinical symptoms.

Some viruses such as the human papillomavirus (HPV) or the molluscum contagiosum virus (MCV) can colonize the epidermis in most individuals without causing any clinical lesions.

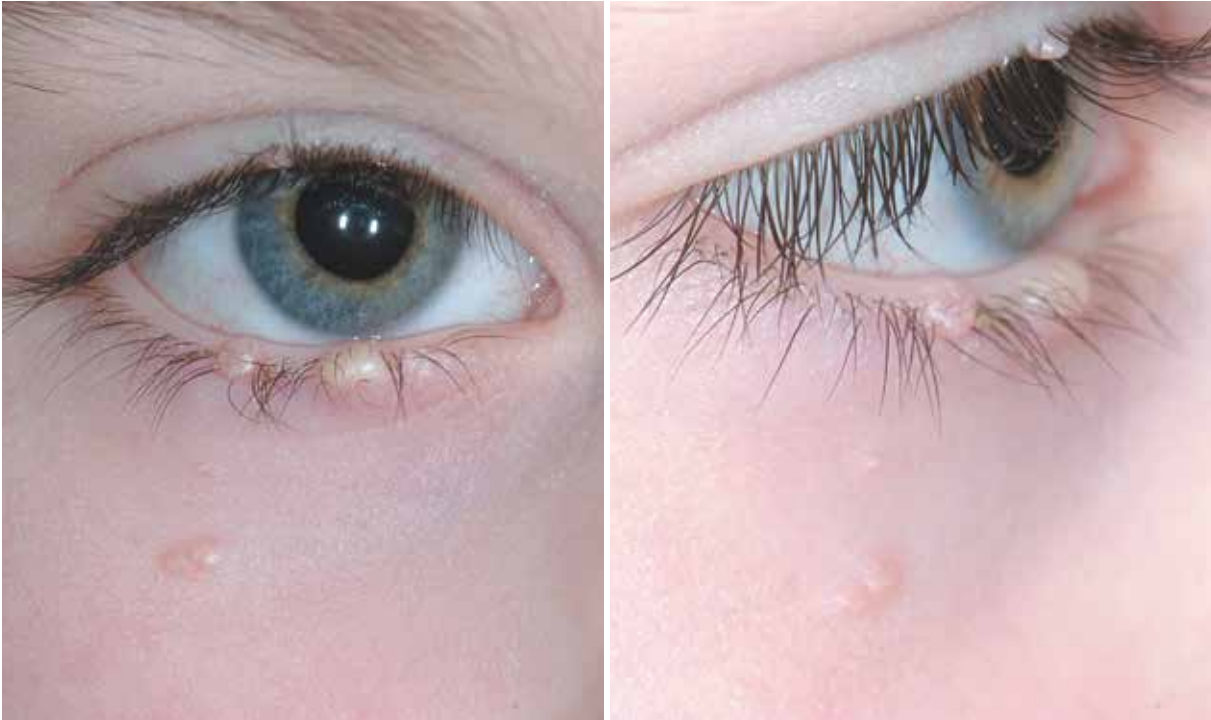Some benign epithelial proliferations such as warts or mollusca can nevertheless develop in these individuals. Most of the time they are temporary and heal spontaneously without any treatment.



Discrete 2-mm skin-colored papule on the free margin with central umbilication.

Molluscum contagiosum is a viral infection limited to the skin, characterized by papules of normal skin color, occasionally umbilicated, occurring in children or young adults.

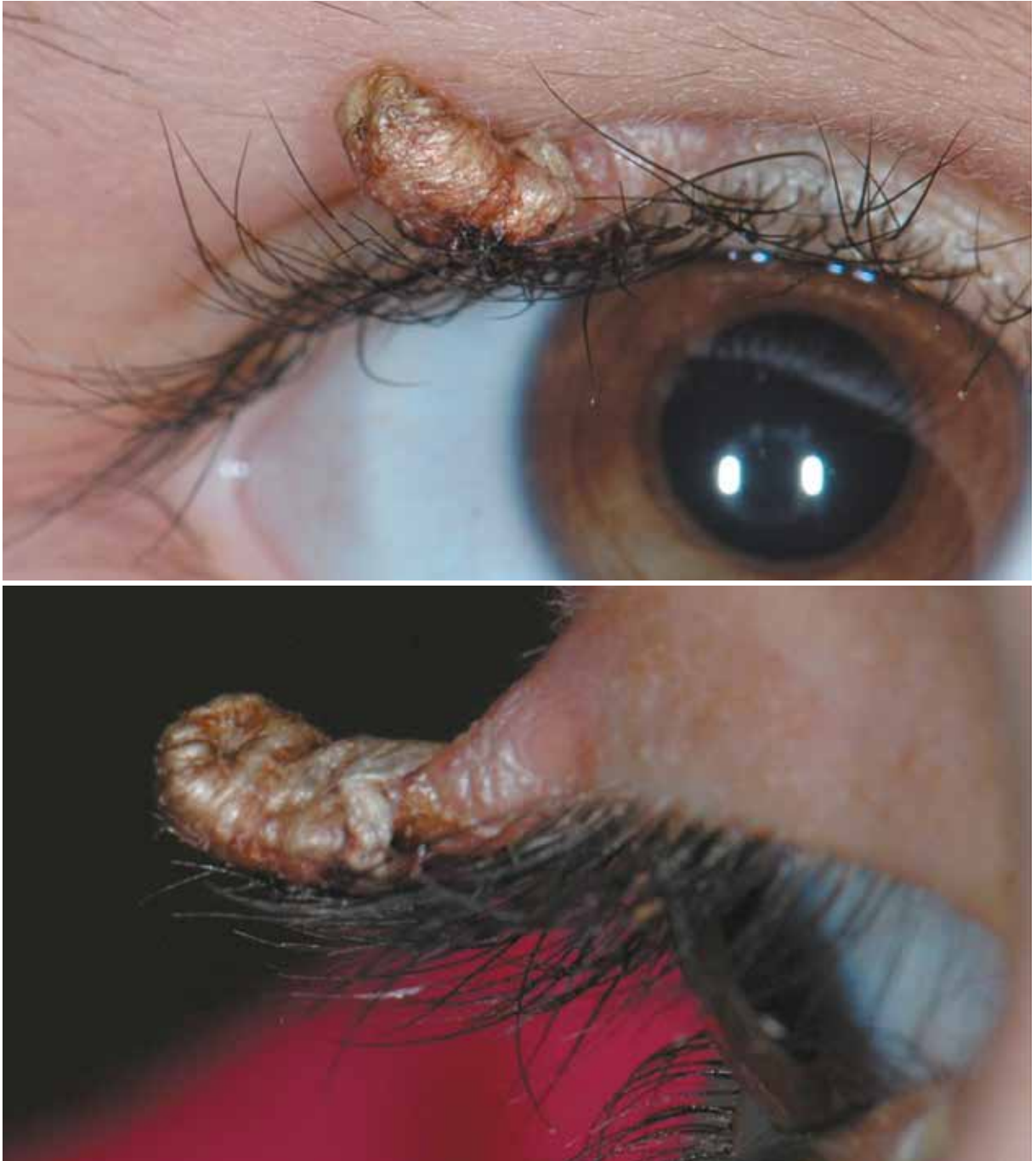Molluscum contagiosum



Multiple lesions on the upper and lower palpebral free margins as well as a lesion below the lower lid.

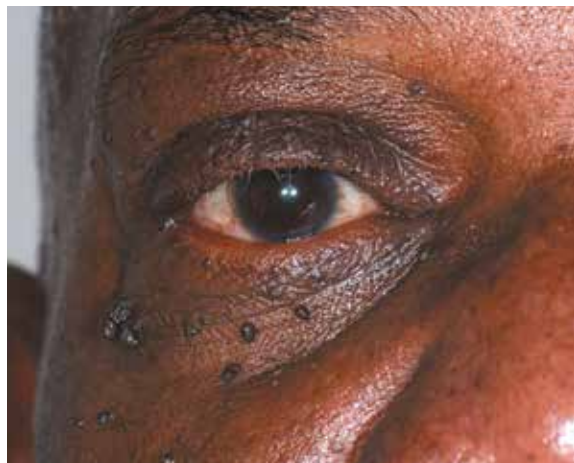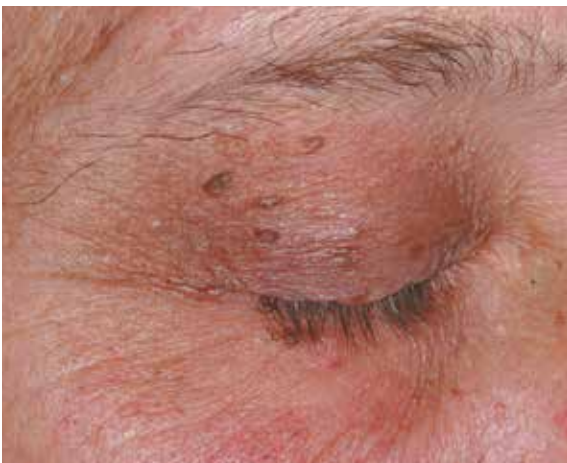
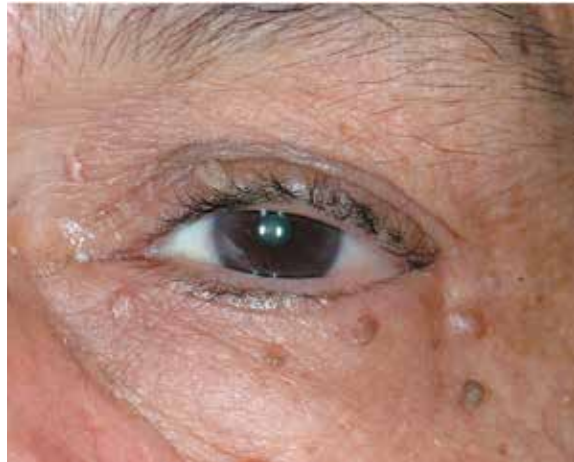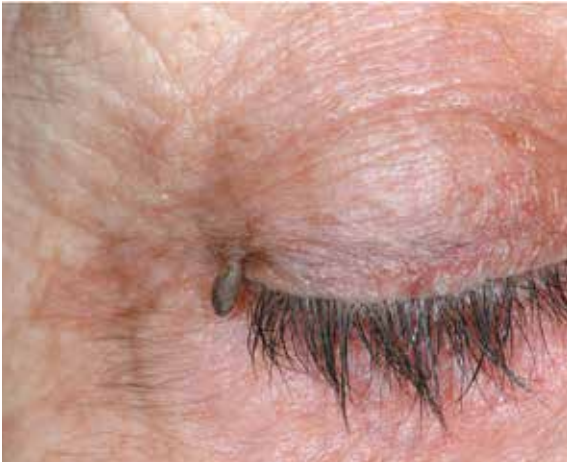There is no loss of lashes.

Molluscum contagiosum



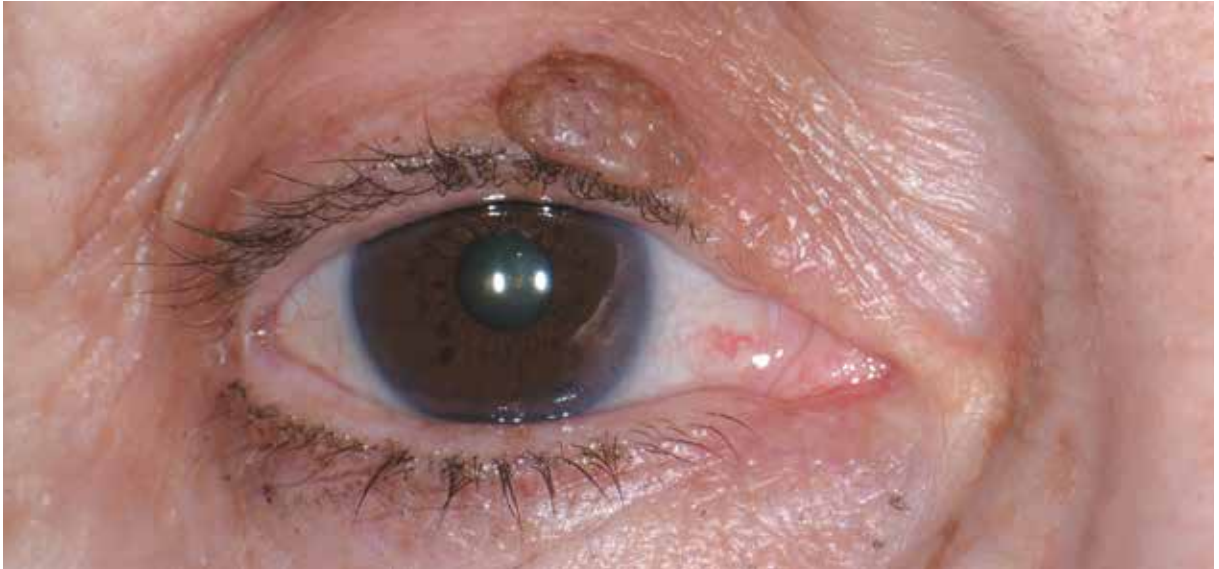
Molluscum contagiosum of the free margin with a hyperkeratotic horn.

Molluscum pendulum



Pedunculated papilloma, variable in color with a tendency to grow in size and number.
Combination of molluscum contagiosum and molluscum pendulum sometimes observed.

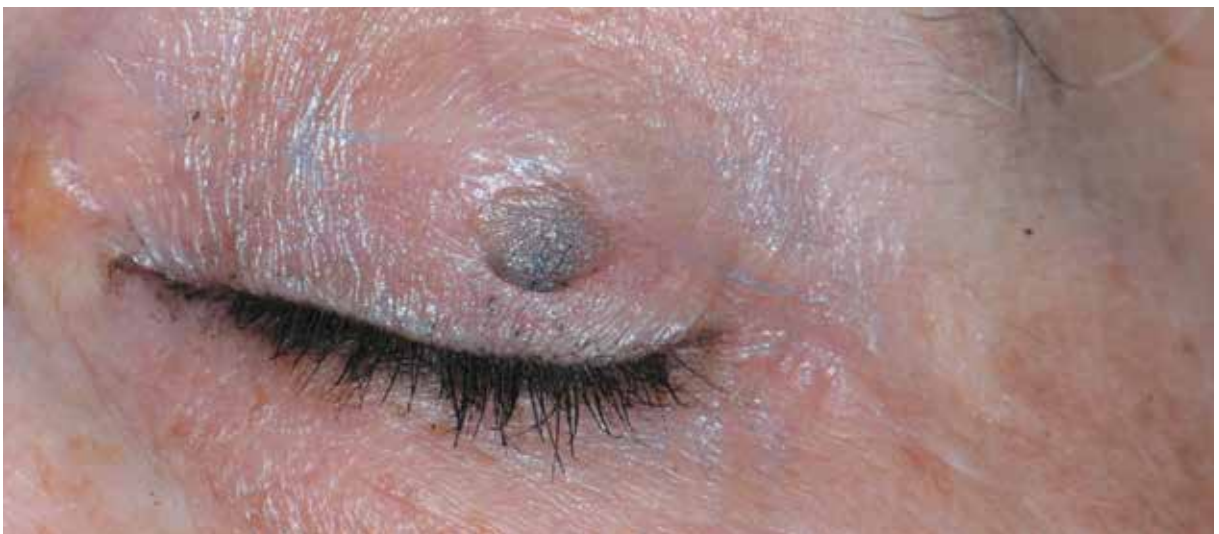Seborrheic keratosis



**Raised papules that grow progressively with varying pigmentation.
Wart-like on the surface with the presence of horny cysts.**

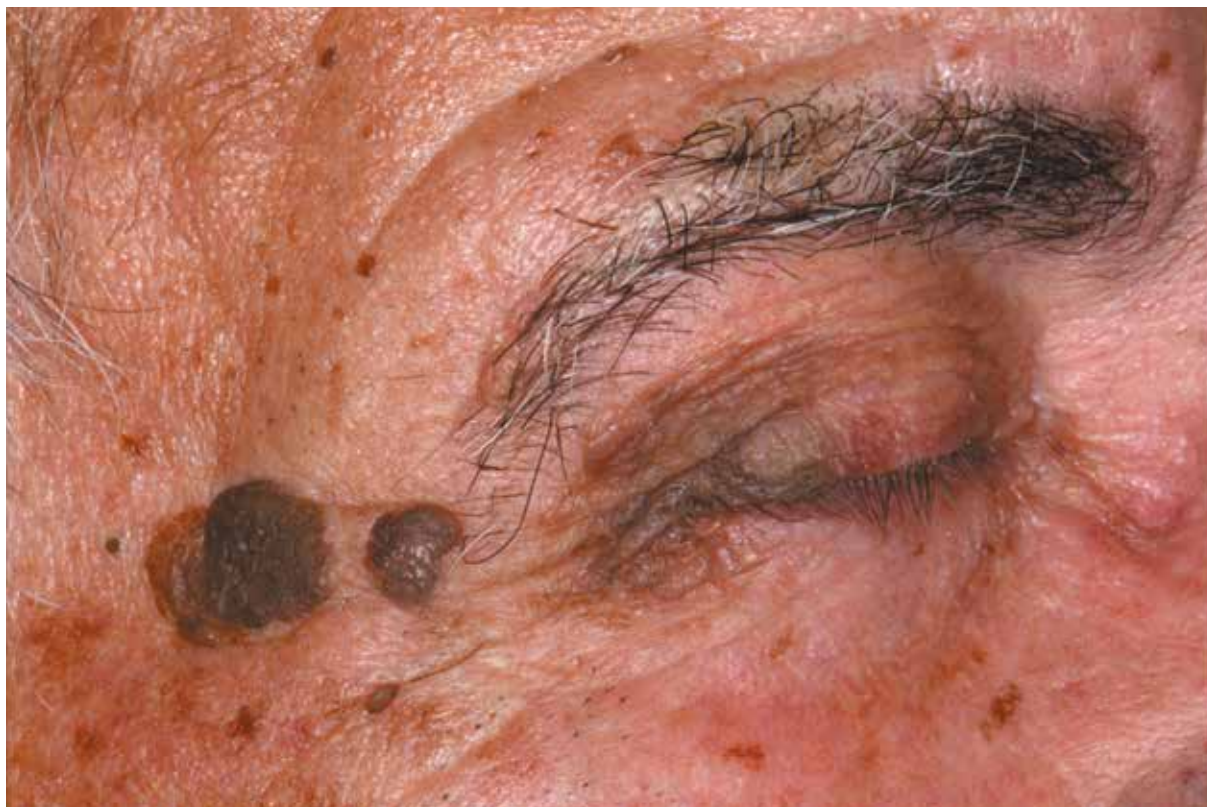Seborrheic keratosis is a common benign epithelial tumor.

They generally develop after the age of 30 and can continue to grow throughout life. They can vary in number from a few lesions to several hundred in the elderly.



Unique location of a seborrheic keratosis papule on the upper left eyelid.

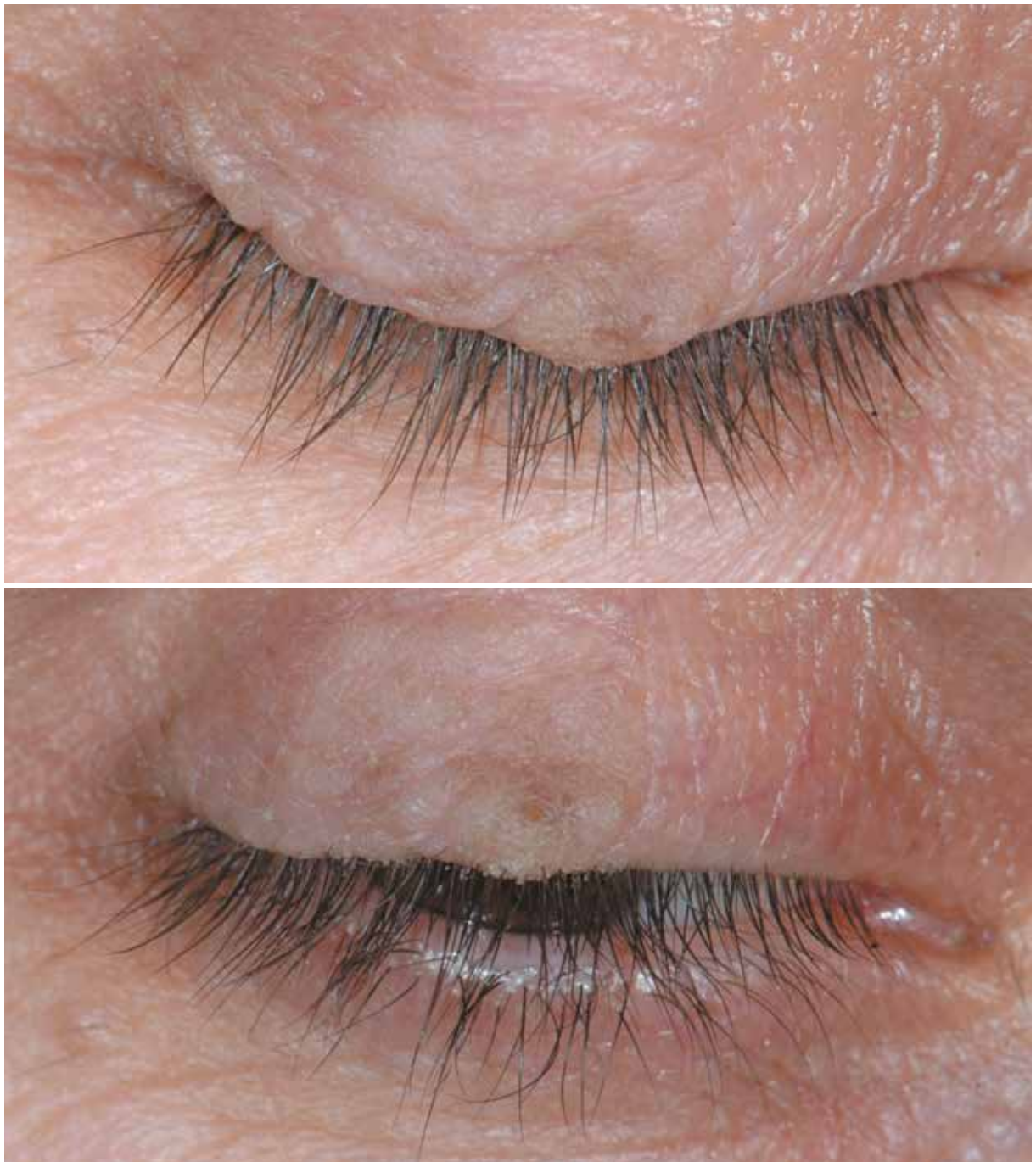Seborrheic keratosis



Multiple seborrheic keratosis lesions of varying appearance.

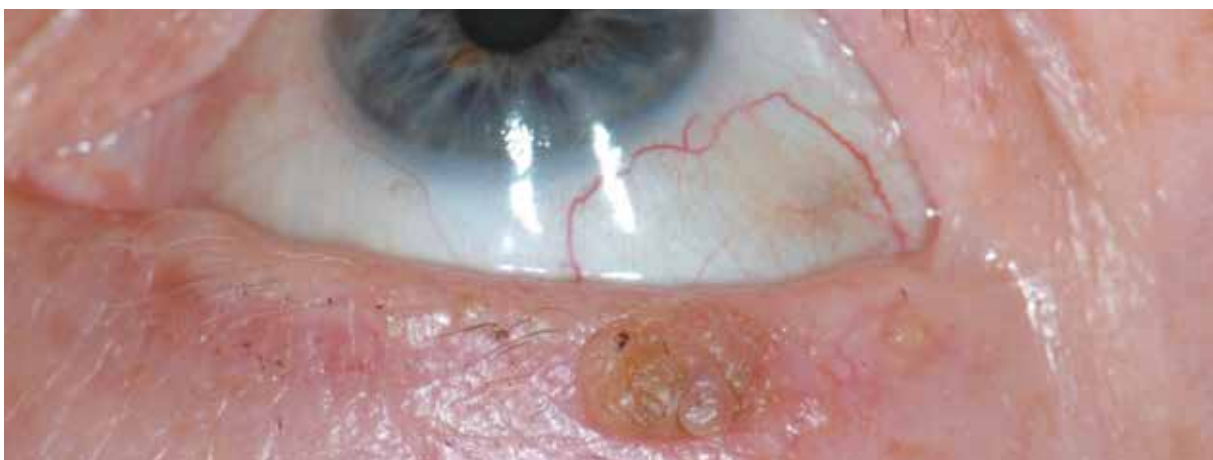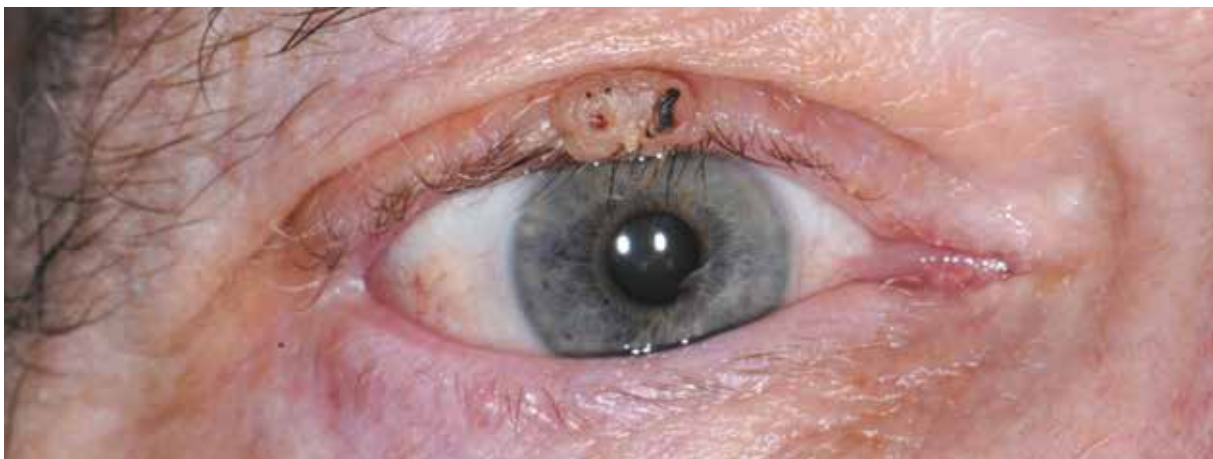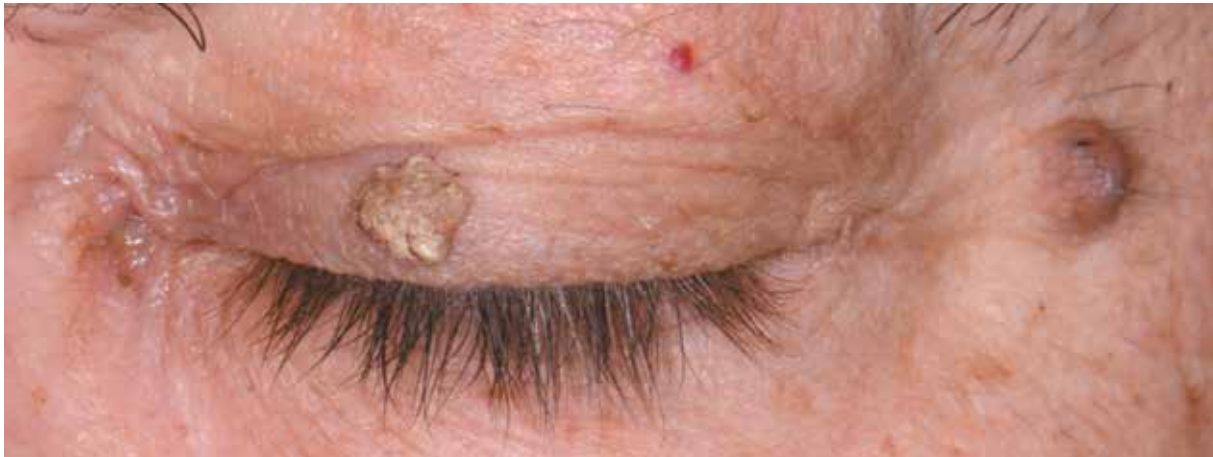At the temple, a slightly raised brown keratotic plaque, thickest in the center. On the free margin of the upper right eyelid, a raised wart-like brown papule with irregular edges.

Seborrheic keratosis



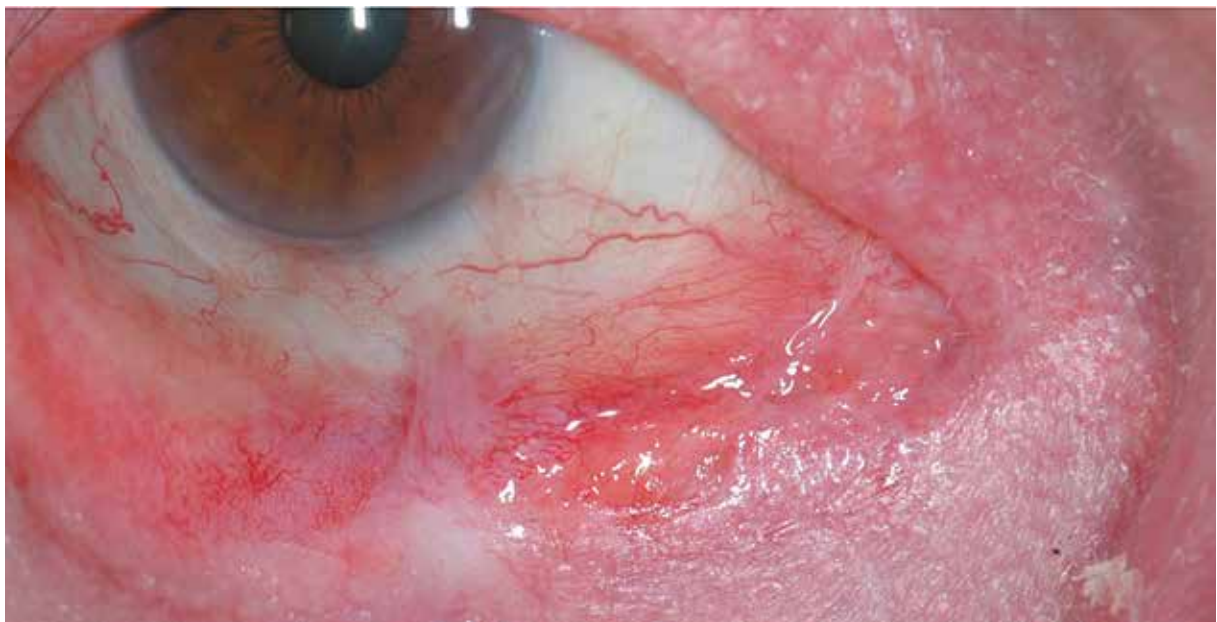
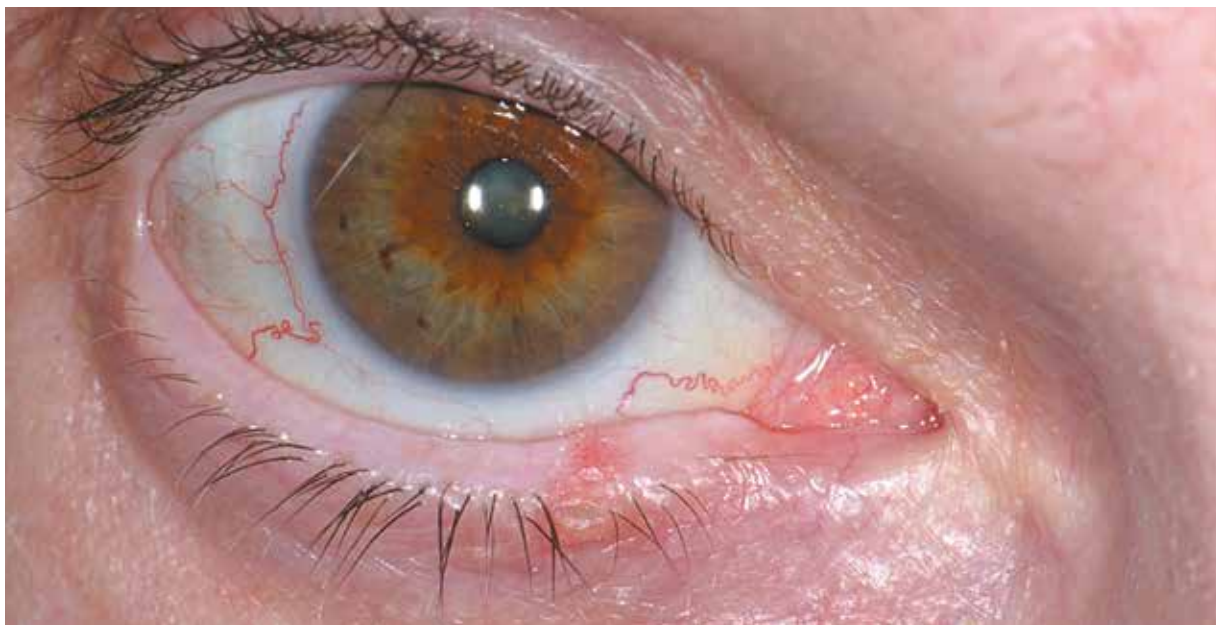Faintly pigmented papule with no loss of lashes or induration.

Seborrheic keratosis



Seborrheic keratosis that might indicate a differential diagnosis of molluscum or papilloma.

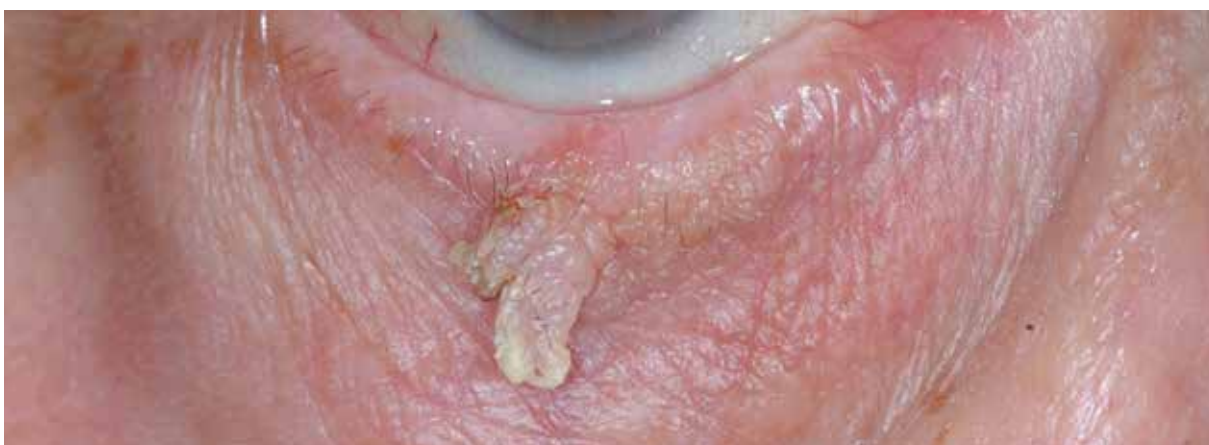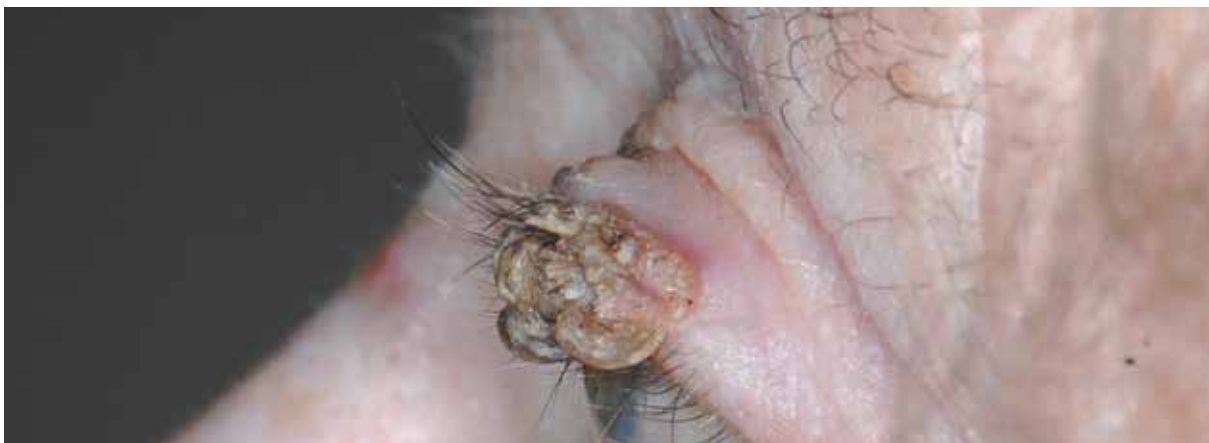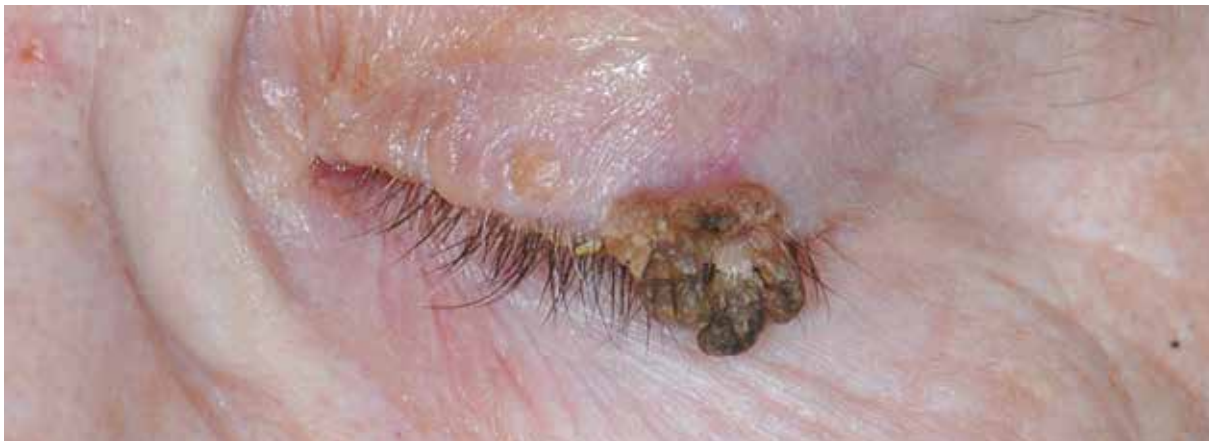Actinic keratosis



Actinic keratosis or solar keratosis is a lesion due to the alteration of the epithelium caused by sun exposure in subjects with light phototypes.

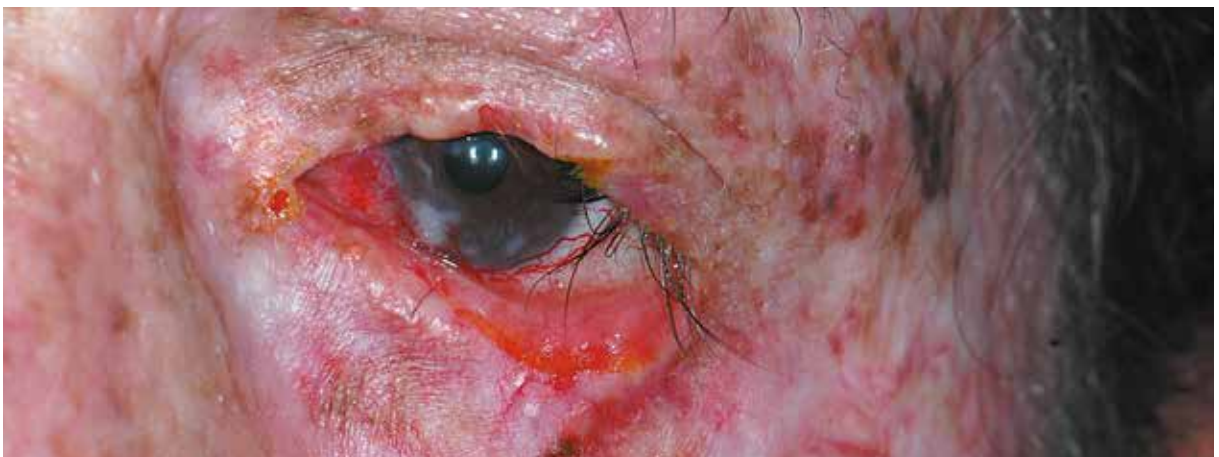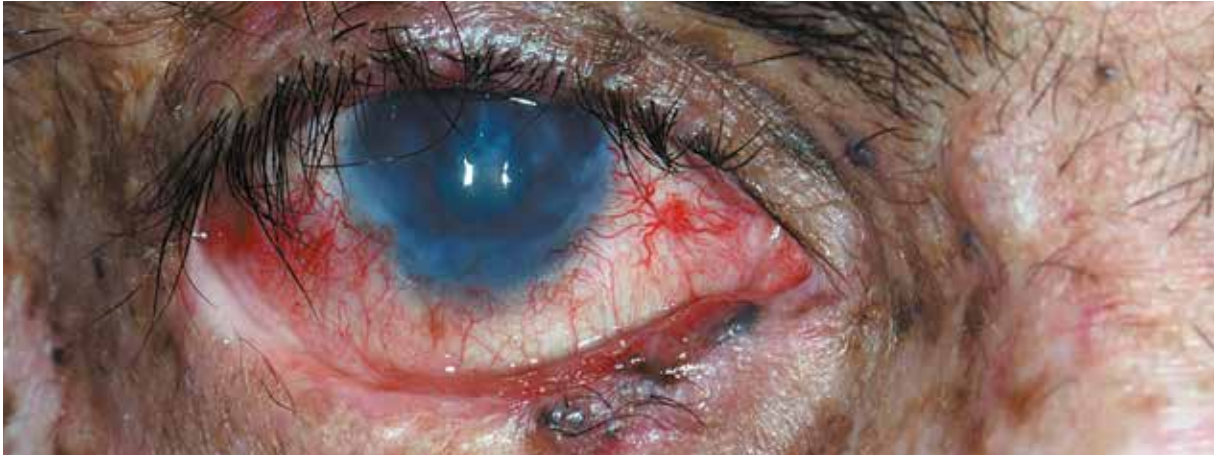The lesion is rough on palpation with scales on the surface and underlying palpebral erosion. Histological analysis is recommended so as not to disregard an incipient carcinoma.

Actinic keratosis with keratotic horn



A lesion with dryer, rougher, adhesive appearance against a backdrop of sun-induced aging. Here, associated with a hyperkeratotic horn.

Xeroderma pigmentosum



Xeroderma pigmentosum is an autosomal recessive disorder characterized by a genetic mutation leading to significant sensitivity to UV radiation.

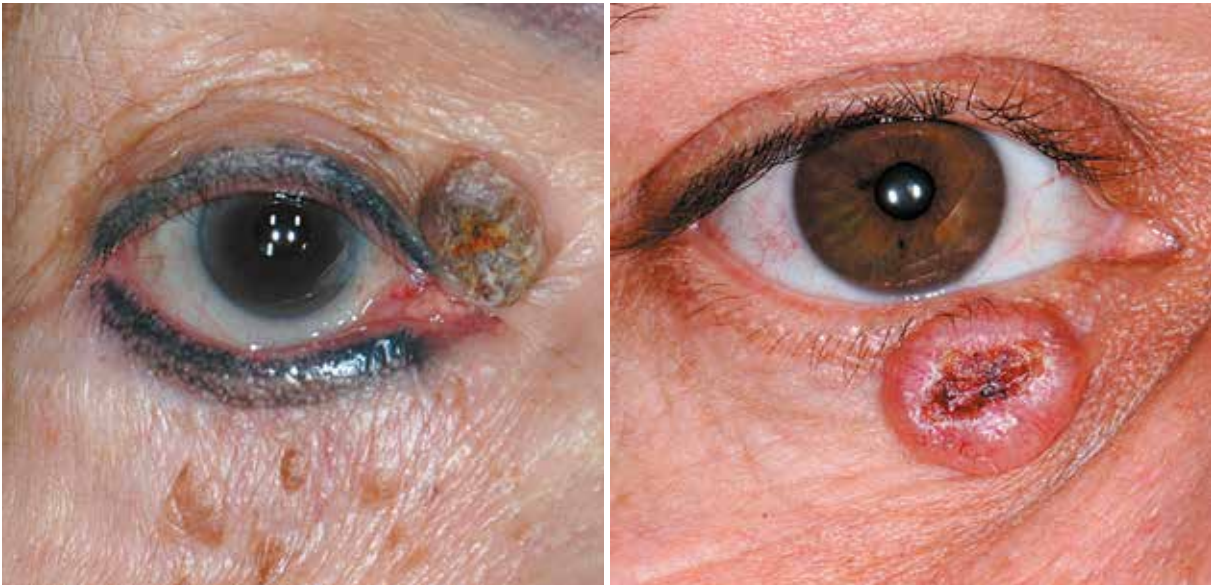
The clinical symptoms of Xeroderma pigmentosum develop in the first months of life with severe redness after exposure to the sun, even minimal and brief.

Numerous ephelides can be observed on the skin of these children. Then, irregular brown spots appear over the entire integument. Lesions such as sun keratosis normally found in much older subjects, rapidly develop with precancerous lesions.

The first skin cancers can develop at the age of 10 in the form of basal cell or spinocellular carcinomas.

Here we can observe the characteristic appearance of the ephelides with actinic keratosis and basal cell carcinoma of the palpebral free margins.

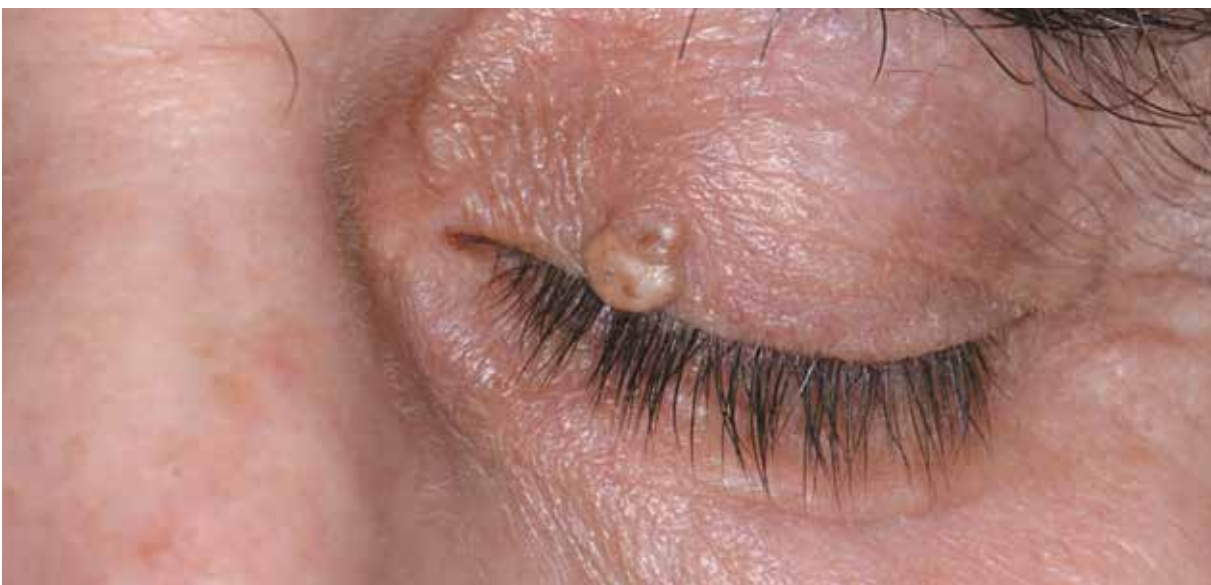Keratoacanthoma



An isolated nodule that develops rapidly with possible involution phase.

There is often a keratin plug in the center hiding the ulceration. Total excision with safety margins is recommended as it is impossible to distinguish it clinically from an epidermoid carcinoma and it often comprises atypical cells raising fears of the subsequent occurrence of an epidermoid carcinoma.

A keratoacanthoma is a pseudo-cancerous lesion in the form of an isolated nodule that develops rapidly with possible involution phase.



Epidermoid carcinoma

Epithelial skin cancers most often stem from the keratinocyte germ cell or adnexal structures.

The two main non-melanocyte skin cancers are basal cell carcinomas and epidermoid carcinomas.

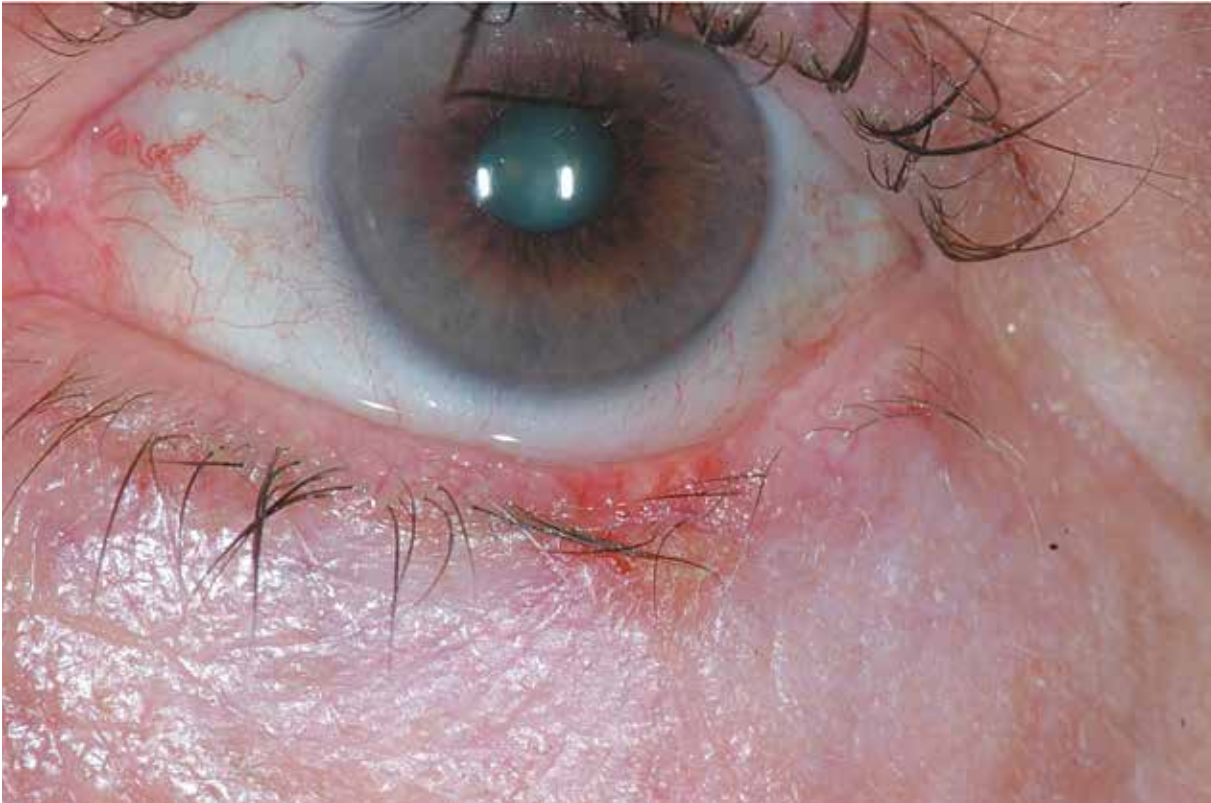Epidermoid carcinomas often give rise to dysplastic lesions in situ that can sometimes be treated before more serious invasion occurs.

Conversely, basal cell carcinomas in situ are unknown, but minimally invasive superficial basal cell carcinomas are common.

White skin, sun exposure, ultraviolet radiation, and human papillomavirus (HPV) are among the numerous risk factors of epithelial skin cancer.

Actinic keratoses precede the development of invasive epidermoid carcinomas in situ in subjects with light skin.

Epidermoid carcinoma *in situ*



Occurs on actinic keratotic or de novo precancerous lesions.

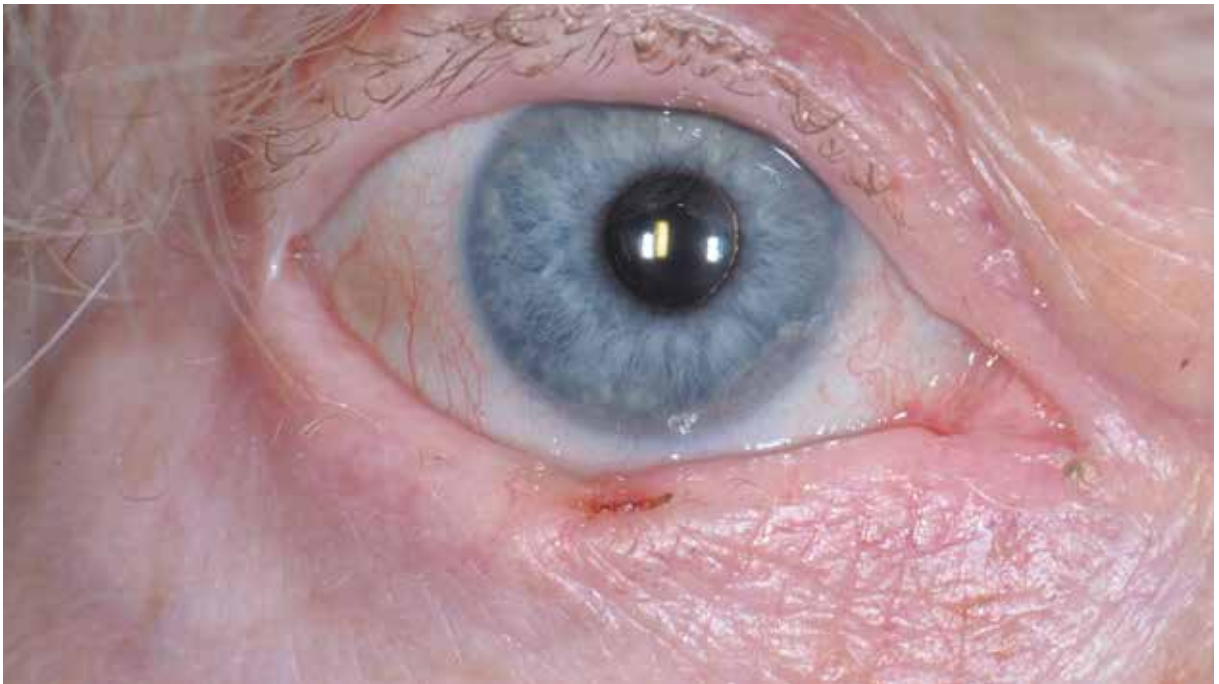
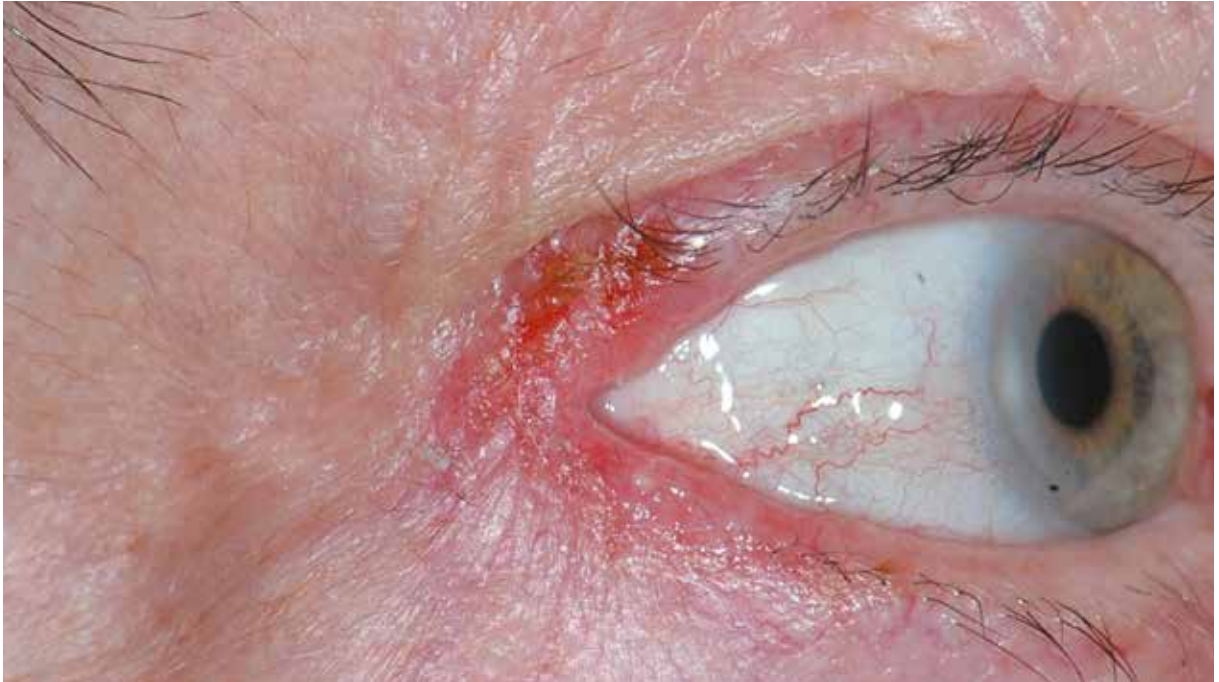Epidermoid carcinomas in situ present as erythematous squamous plaques.

Epidermoid carcinomas in situ are often linked to ultraviolet radiation or an HPV infection. It presents as a unique macula, papule or plaque sometimes squamous or hyperkeratotic.

Erythematous plaque partially covered with yellowish scales.

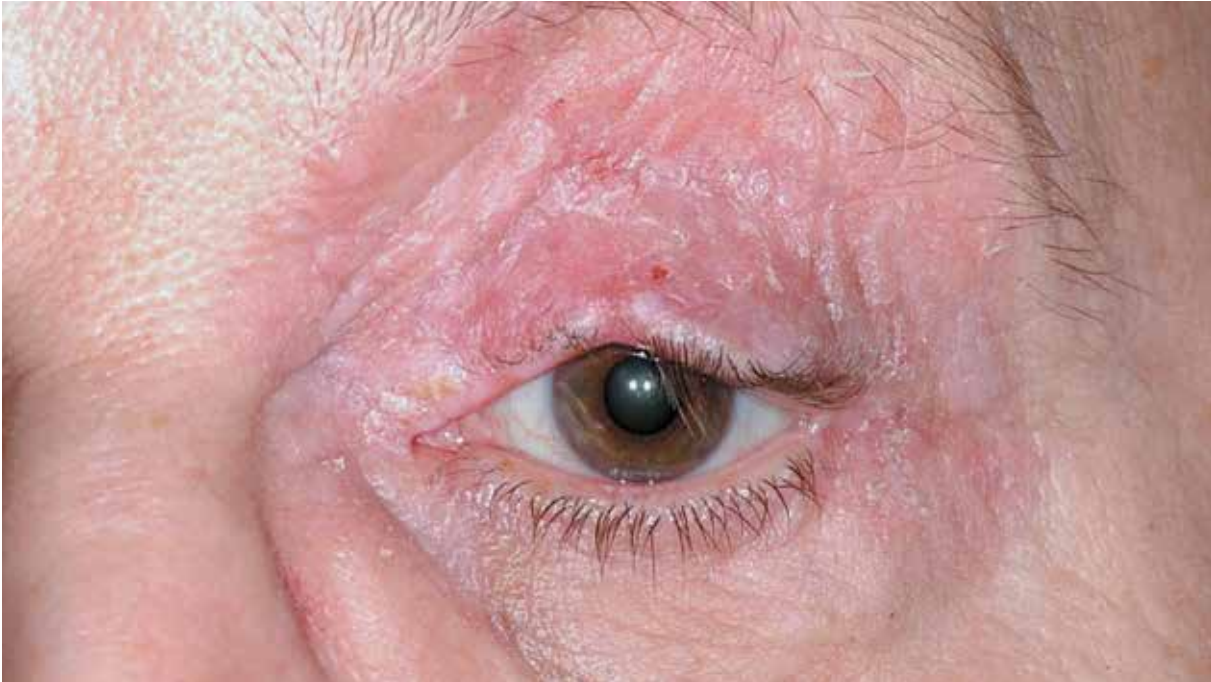Malignant epithelial tumors

Epidermoid carcinoma *in situ*

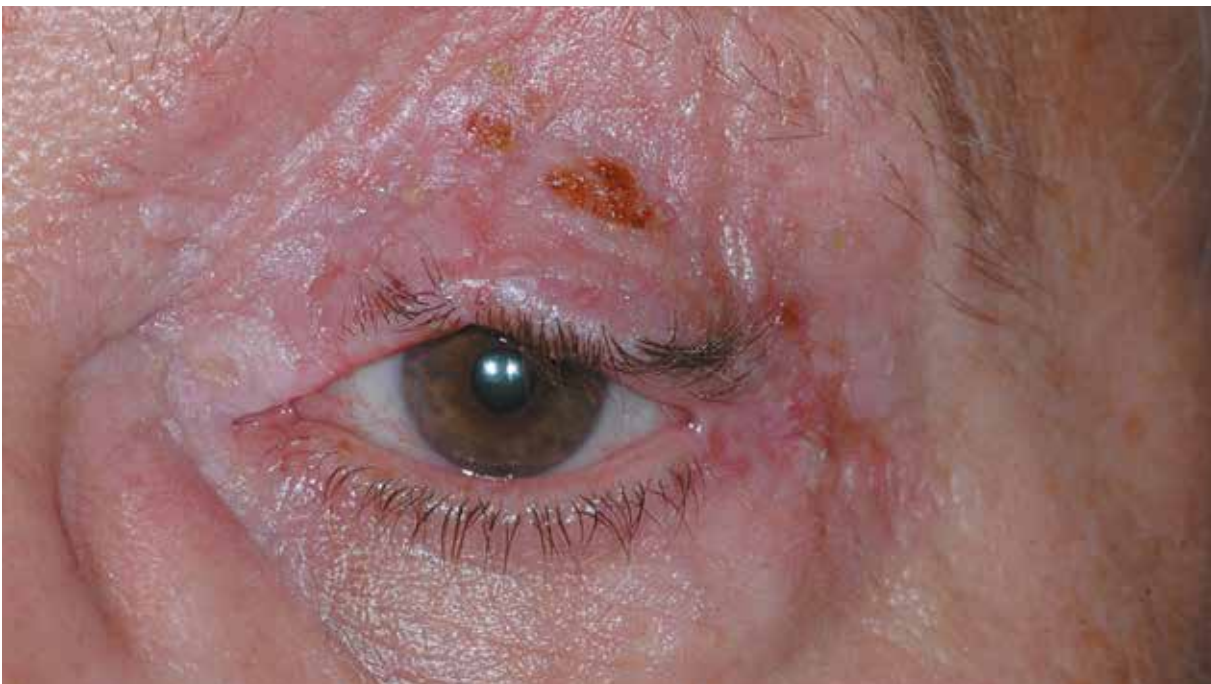

Formerly Bowen's disease, the lesion can develop nodules and ulcerations. Only a histological analysis can differentiate it from an epidermoid carcinoma.

Epidermoid carcinoma *in situ*

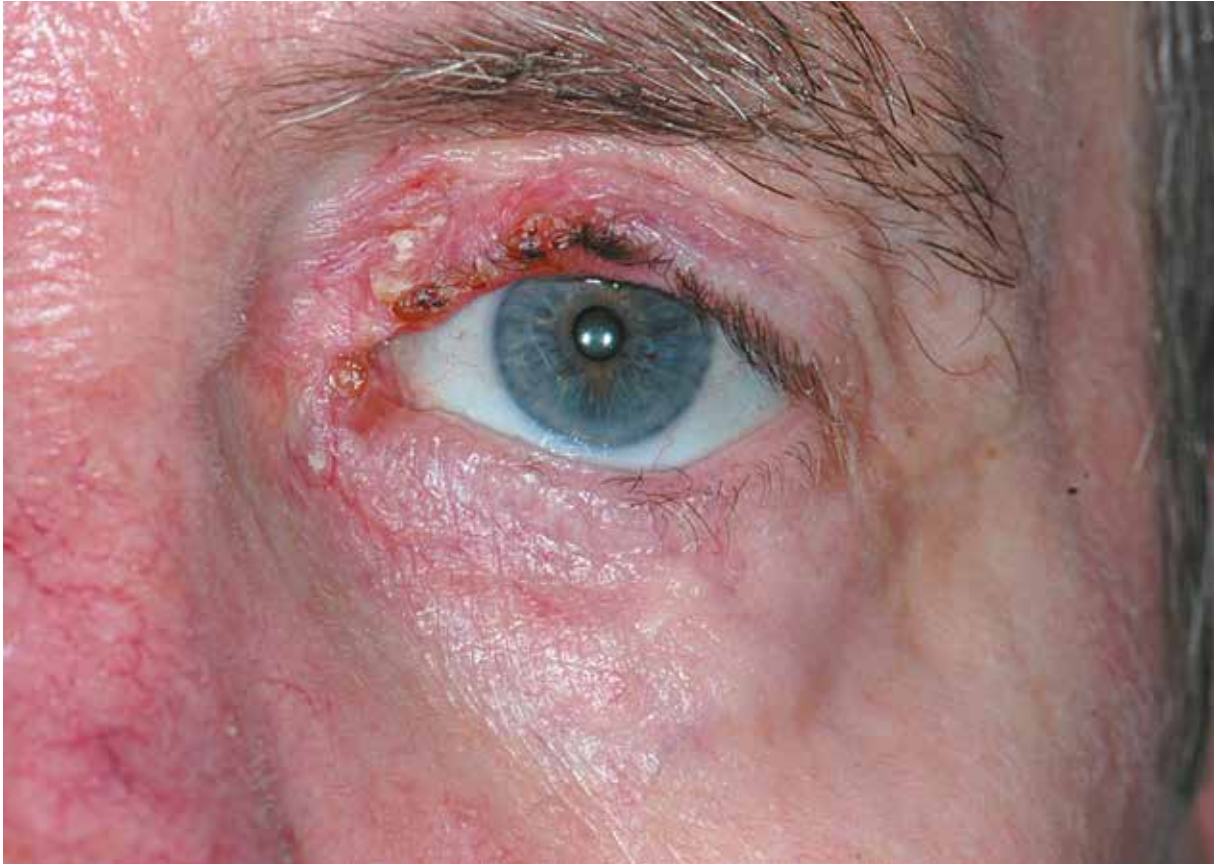

A patient presenting actinic keratosis lesions with erythematous squamous lesions.



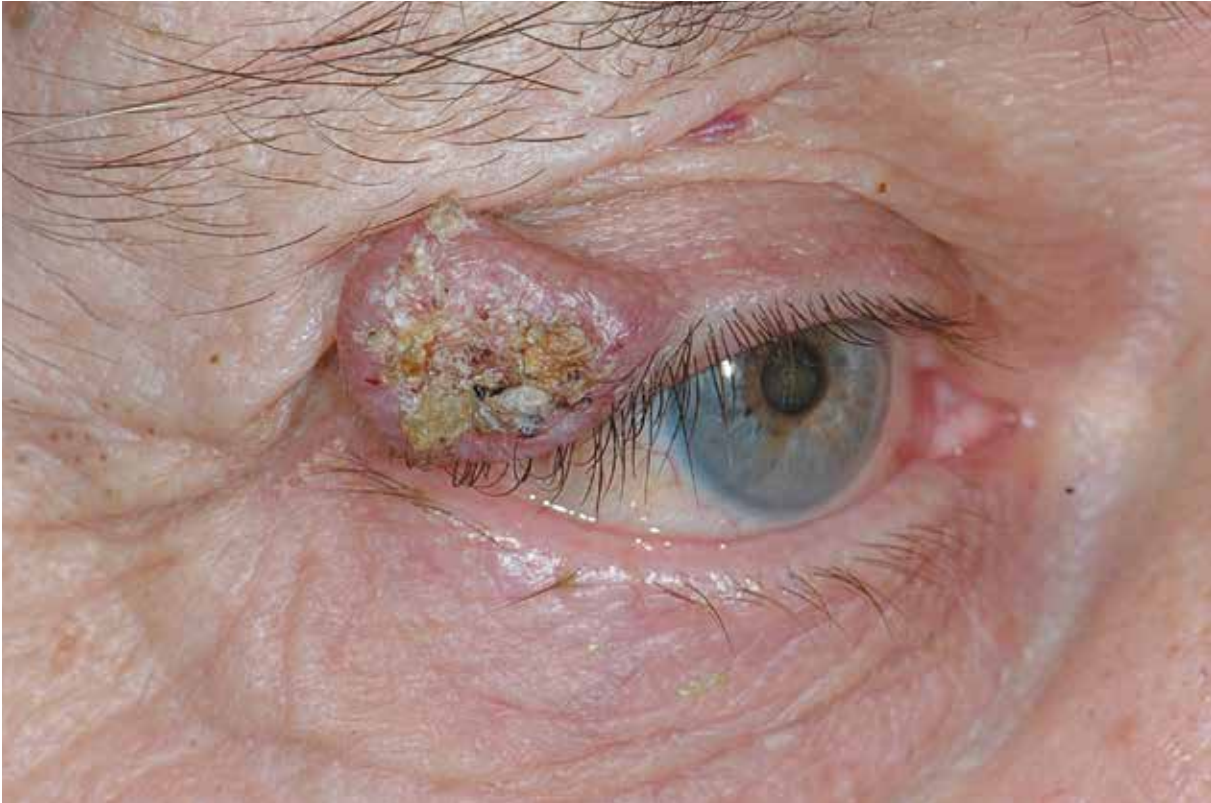
Epidermoid carcinomas *in situ* after progression and emergence of infiltrating carcinoma islets.

Infiltrating epidermoid carcinoma



The clinical appearance can be nodular, ulcerated or mixed. Madarosis occurs when the free margin is affected.

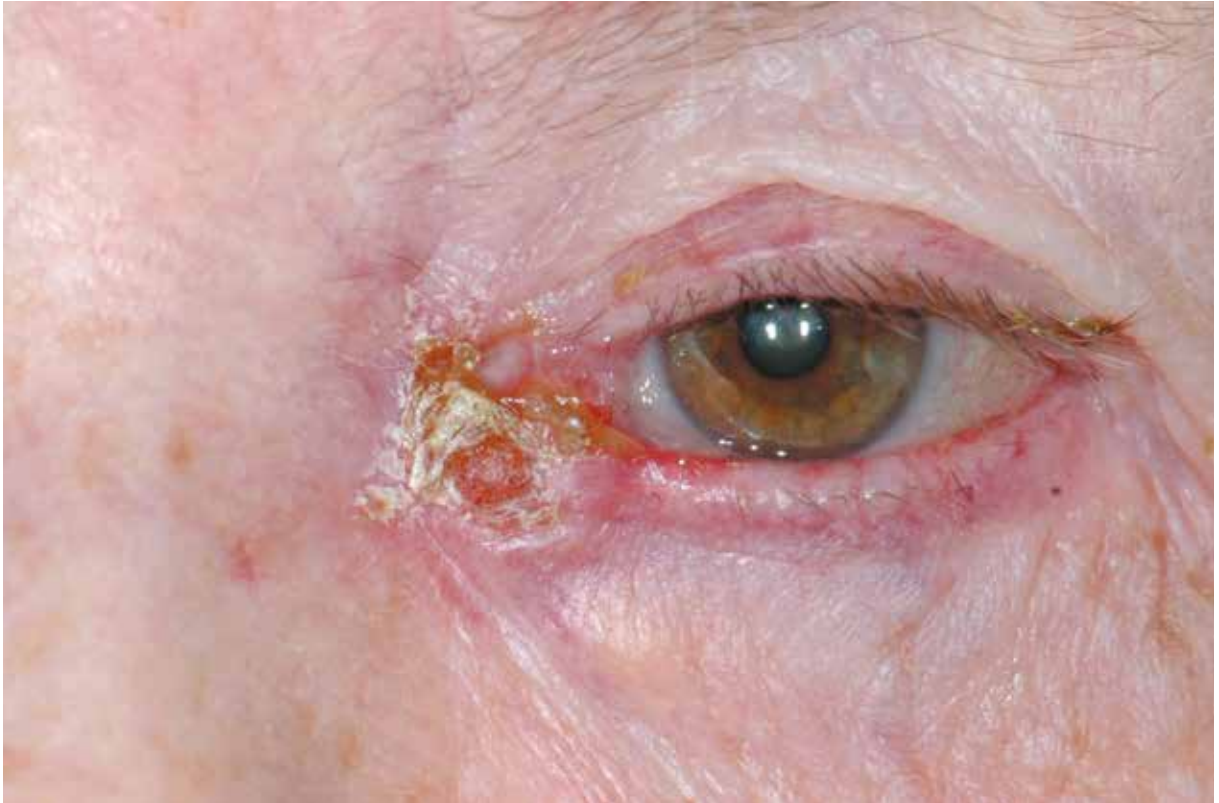Infiltrating epidermoid carcinoma



Invasive epidermoid carcinomas are malignant tumors that begin in the epidermis or appendages. The aggressiveness of the lesions varies according to the etiology.

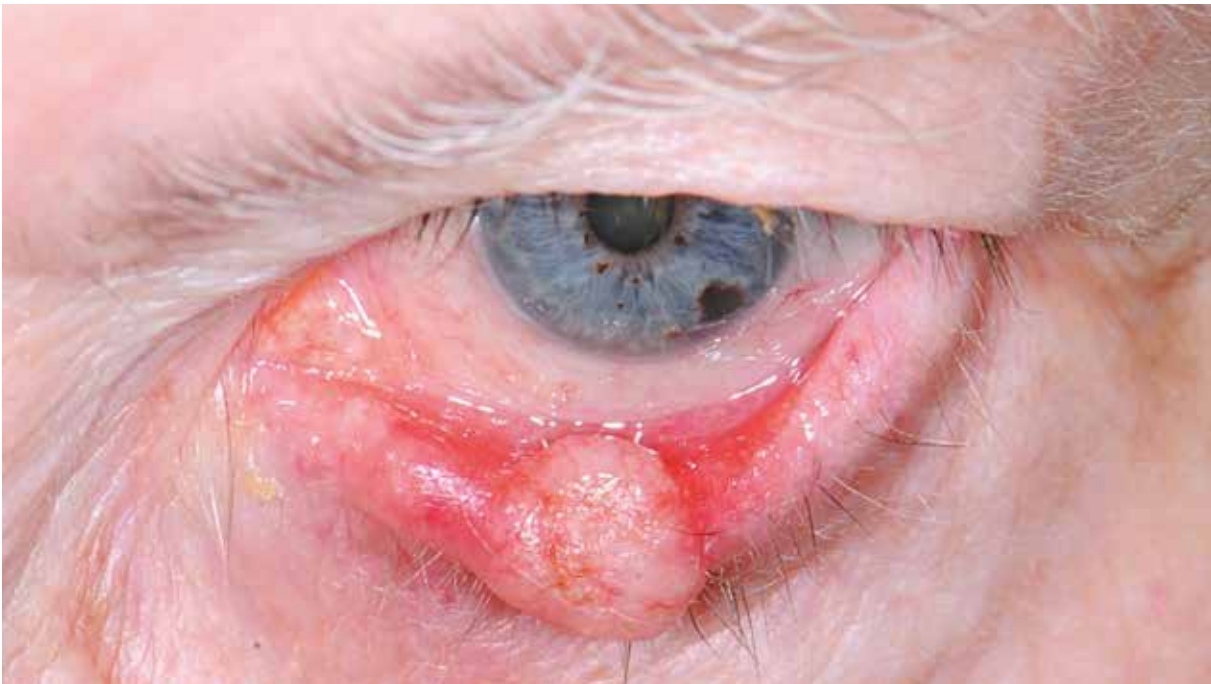
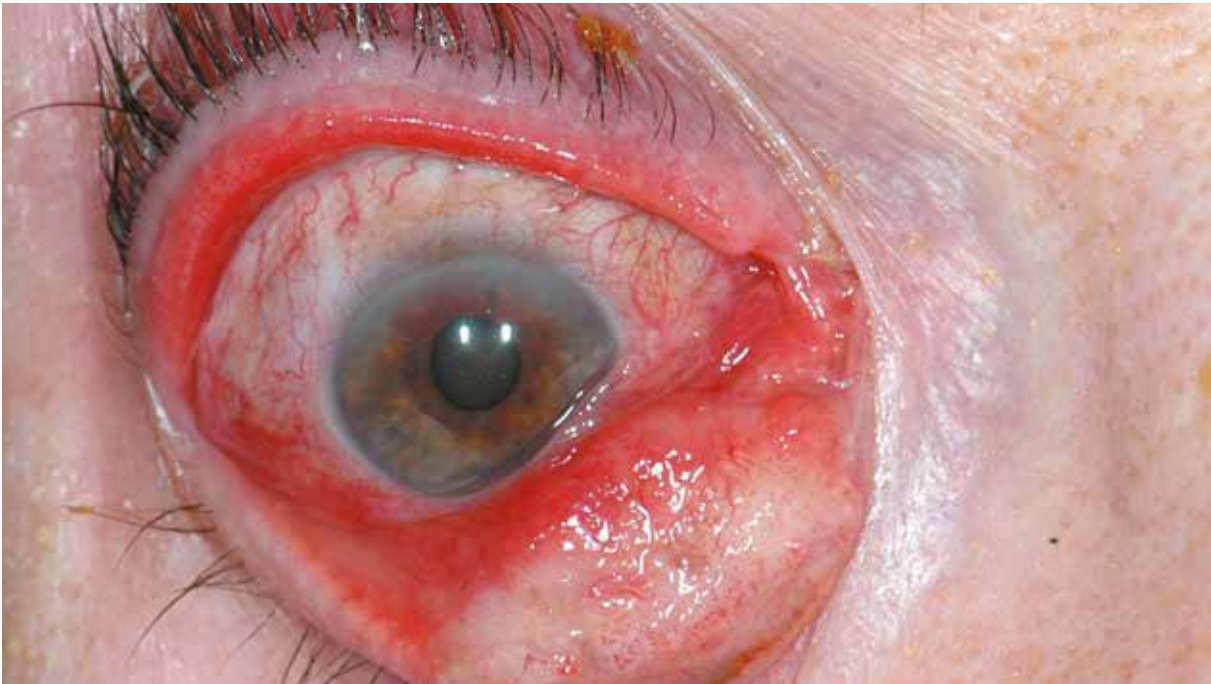These lesions are more aggressive in immunocompromised patients with a higher metastatic risk.

Infiltrating epidermoid carcinoma



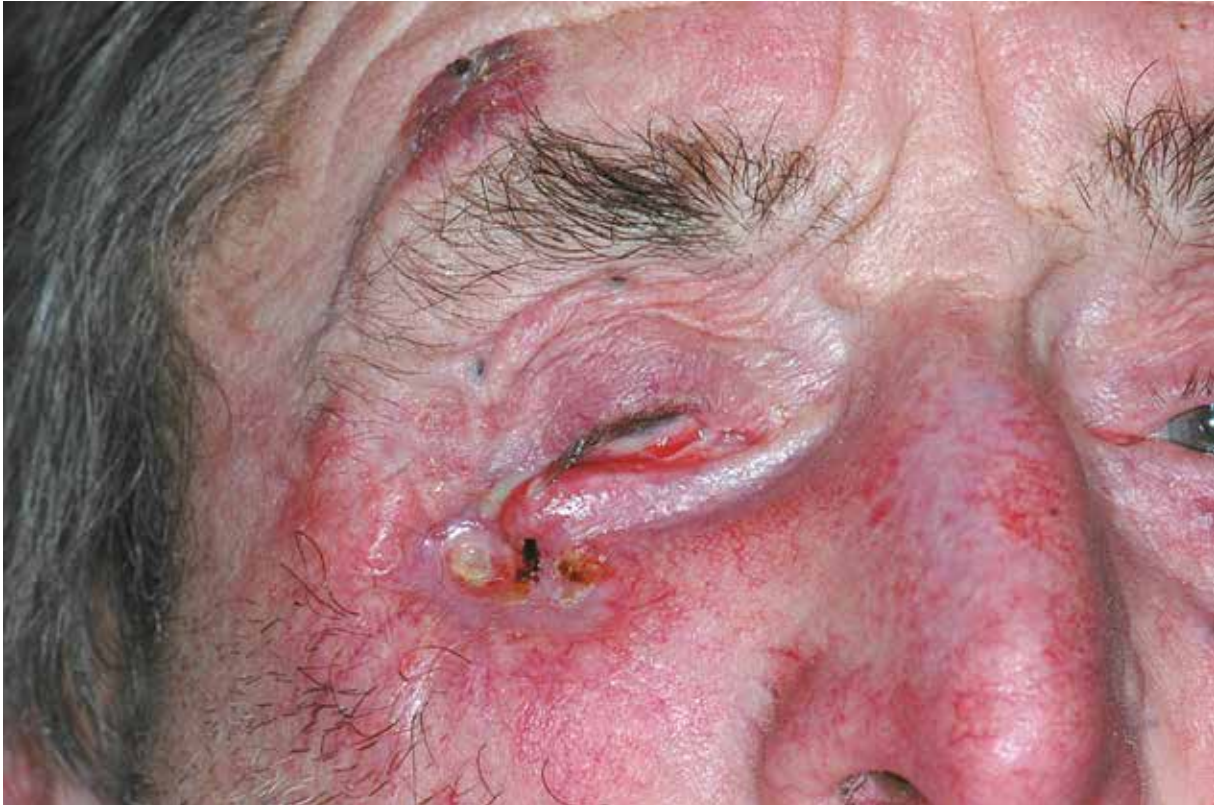Well-differentiated carcinomas are often hyperkeratotic and firm on palpation.

Infiltrating epidermoid carcinoma



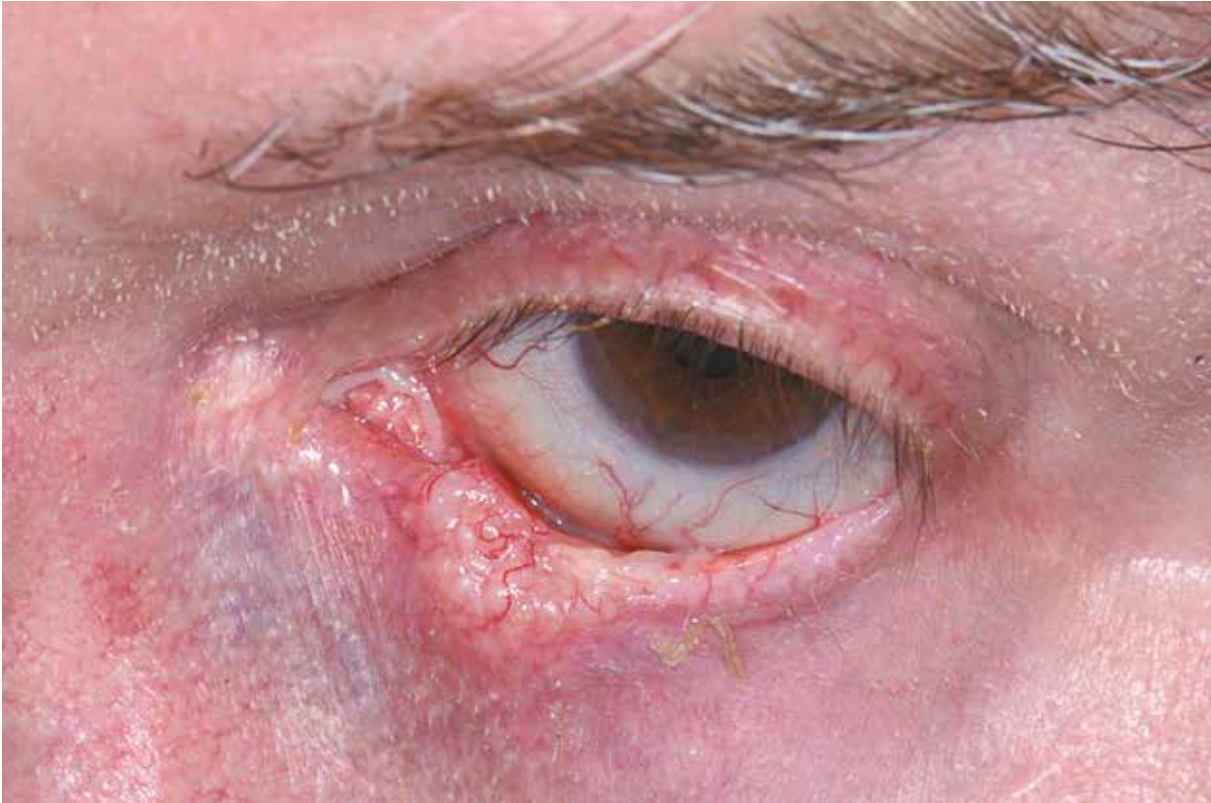Significant nodule on palpation with free margin affected. Hyperkeratotic and erosive zones can be distinguished.

Infiltrating epidermoid carcinoma



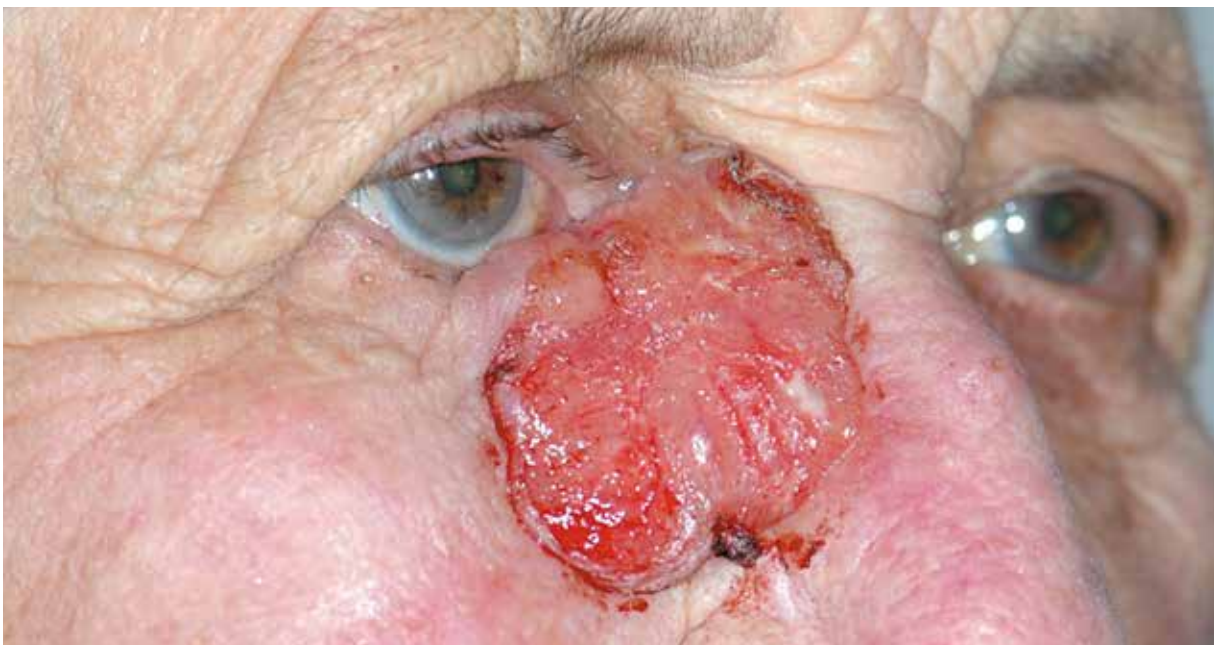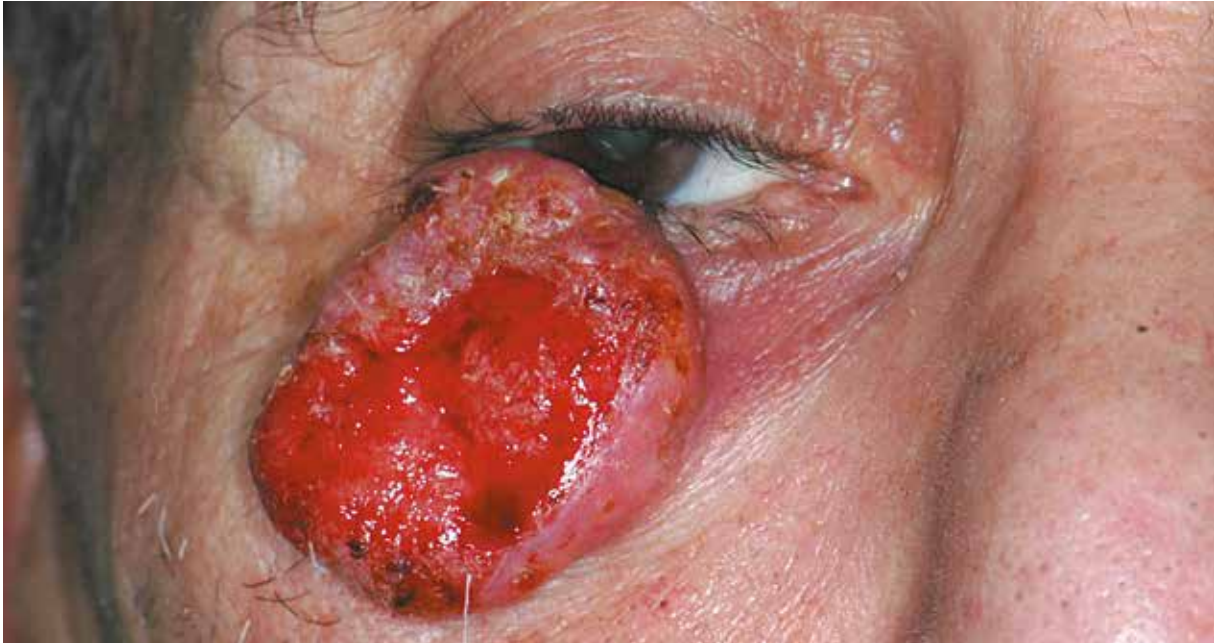The metastatic potential is higher via the hematogenic, lymphatic, and nerve pathways. General disease staging must systematically be conducted initially and for monitoring.

Undifferentiated epidermoid carcinoma



Undifferentiated epidermoid carcinomas present in the form of polylobed cauliflower-like nodules that are more or less friable.

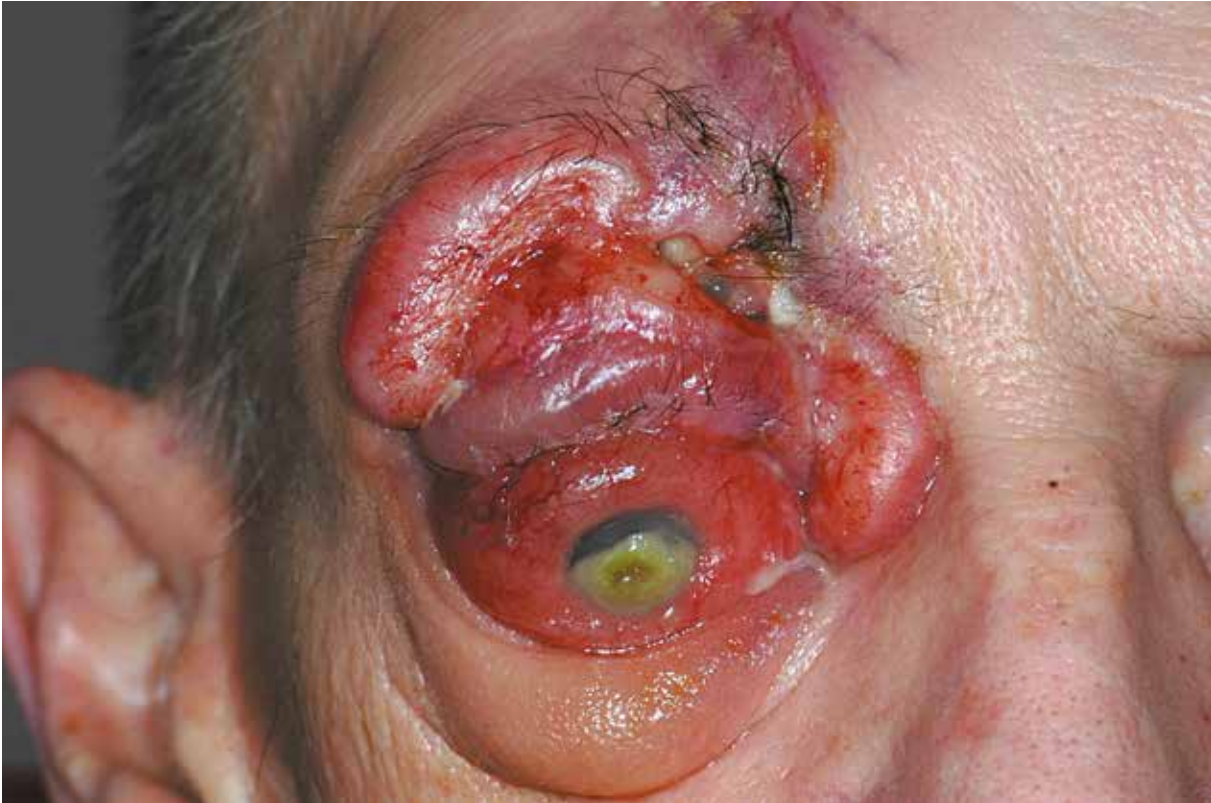Undifferentiated epidermoid carcinoma



Undifferentiated epidermoid carcinoma.

Advanced undifferentiated epidermoid carcinoma with nodule of significant size. Central necrosis. Vegetating, ulcerated, soft, friable, easily hemorrhagic lesions. Here, there is significant metastatic potential.

Epidermoid carcinoma



Local extension can lead to loss of ocular function and even invasion of neighboring organs in the case of lesions not examined initially.

Basal cell carcinoma

Basal cell carcinoma is the most common skin cancer.

It is aggressive and invasive, but rarely metastatic.

Basal cell carcinomas develop in the epidermis, are rare in subjects with black or dark brown skin.

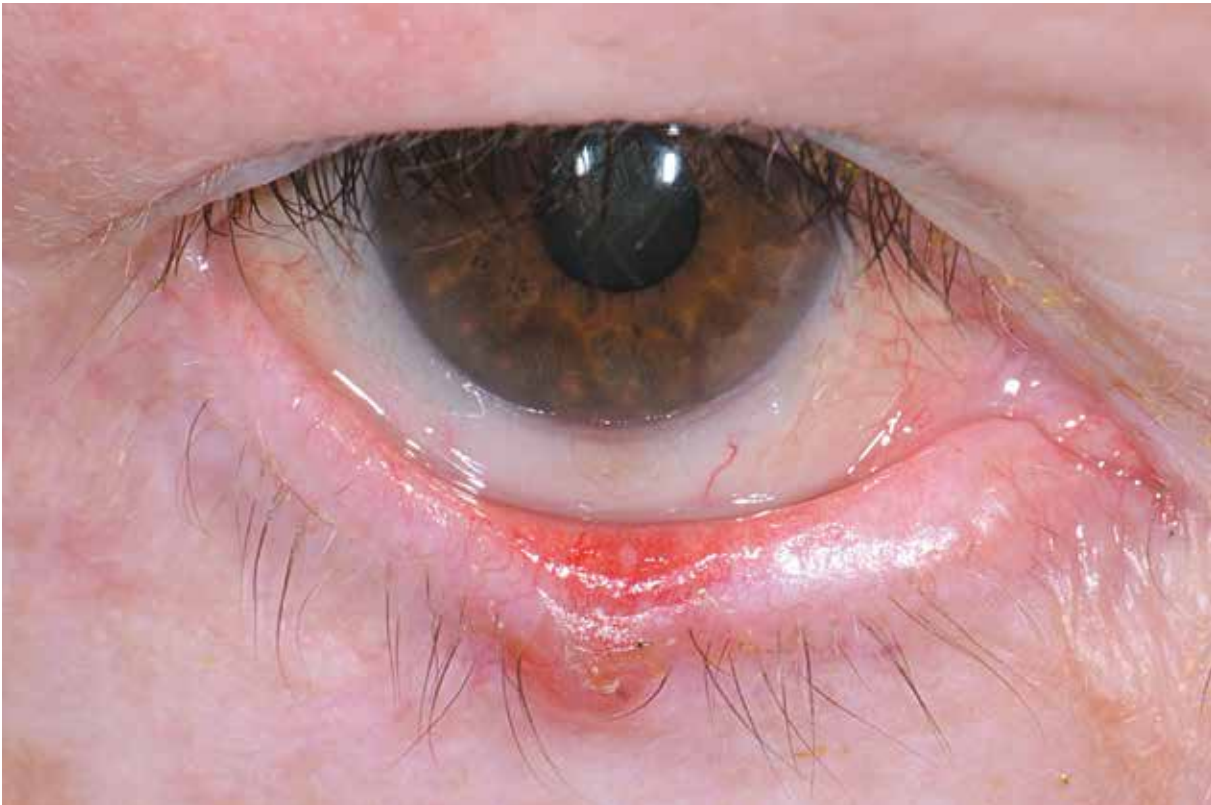Sun exposure, especially in childhood or youth, is a risk factor.

There are five major types:

Nodular, ulcerated, sclerodermiform, superficial and pigmented basal cell carcinomas.

Basal cell carcinomas exhibit significant polymorphism. Different clinical presentations are often associated.

Nodular basal cell carcinoma

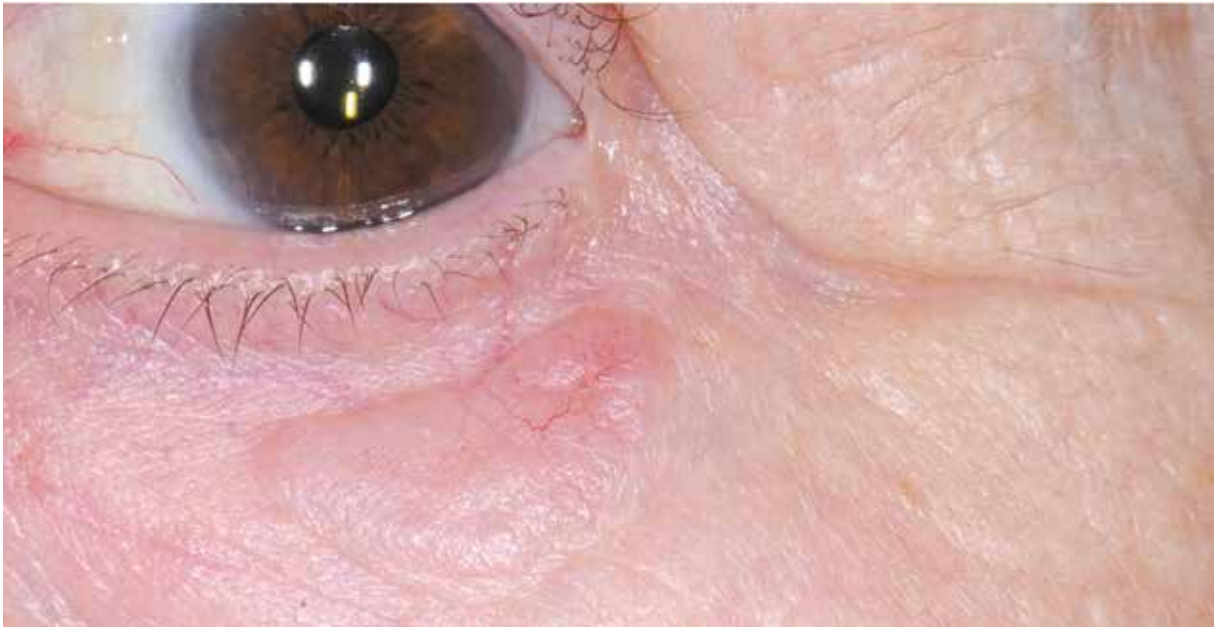

Small basal cell carcinoma of the free margin of the eyelid with characteristic bead and telangiectasia.

Loss of lashes can be observed.

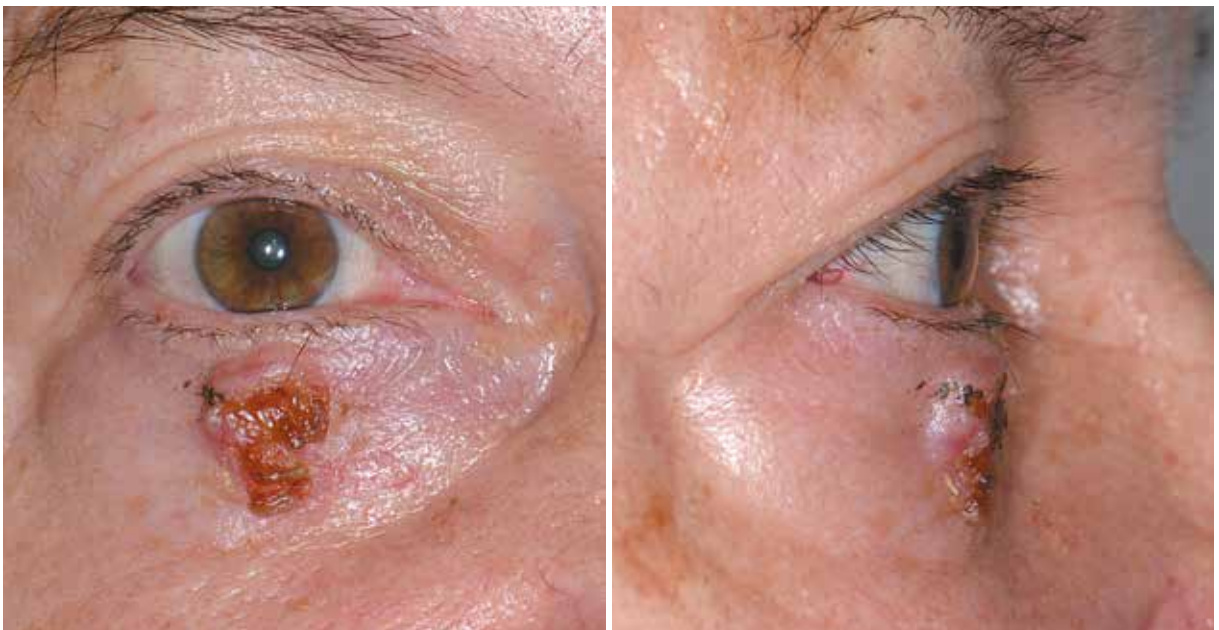
Malignant epithelial tumors

Nodular basal cell carcinoma



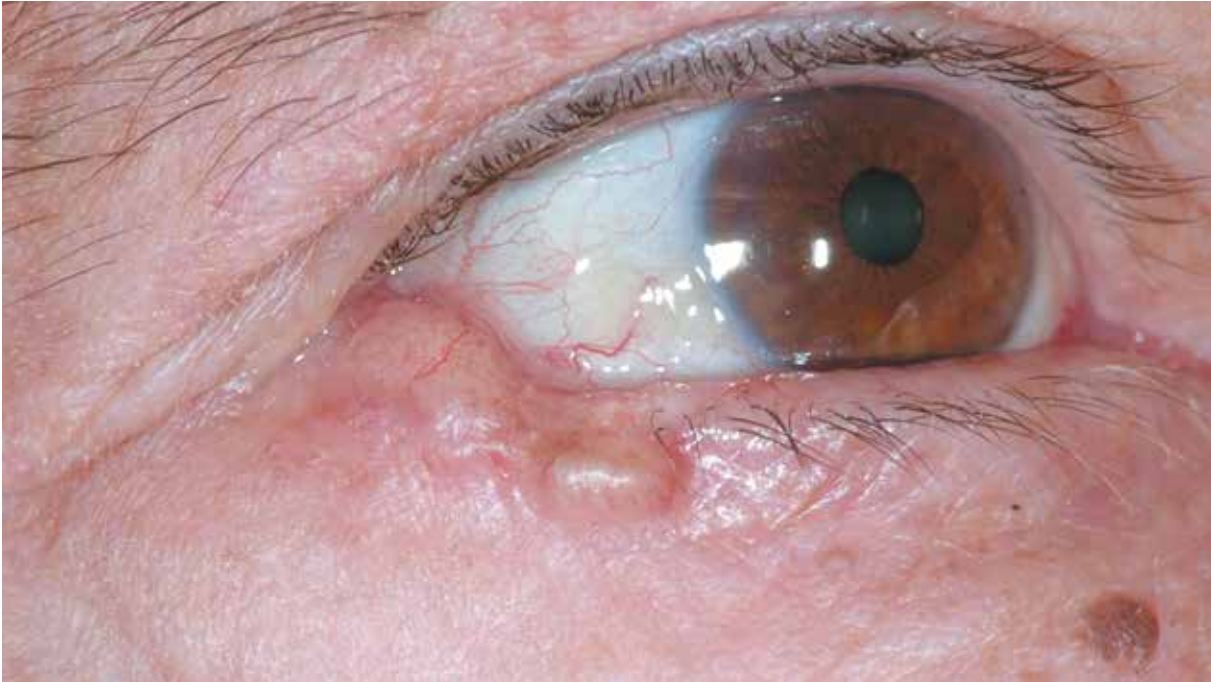Epidermal lesion not involving the free margin.

Infiltrate with raised, indurated appearance, beaded edges and telangiectasia.

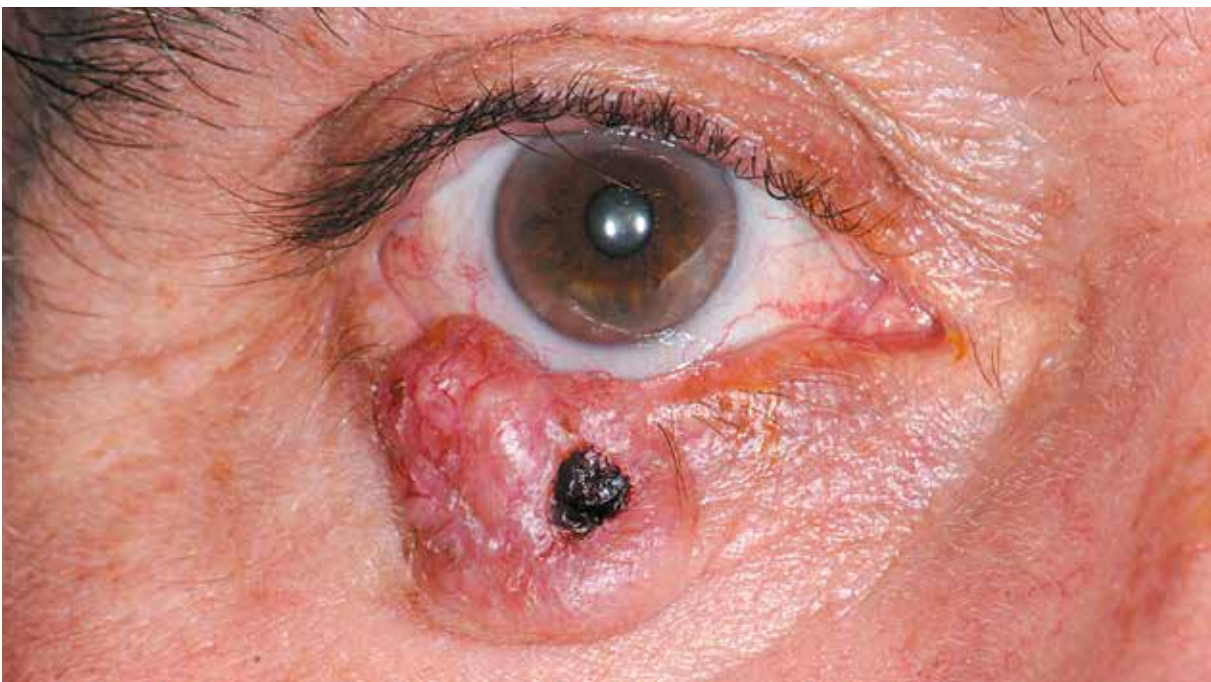

In the center of the ulceration, crusts and hyperkeratinization can develop making the diagnosis difficult with an epidermoid carcinoma.

Nodular basal cell carcinoma



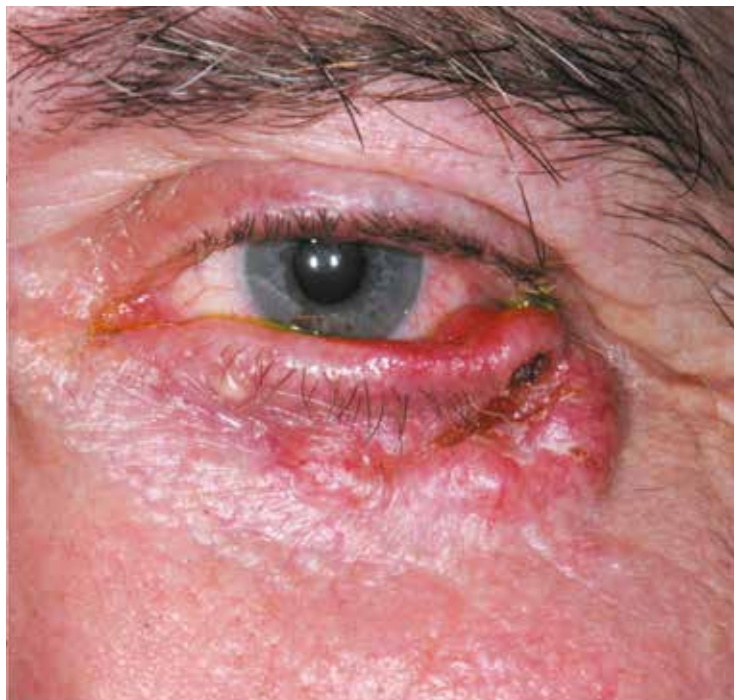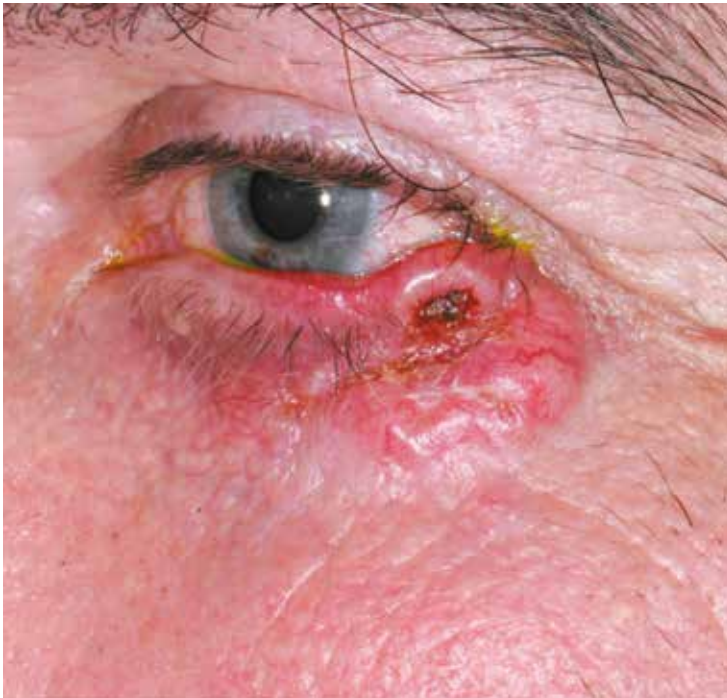Nodular basal cell carcinoma of the free margin with induration on palpation and telangiectasia, destructuring of the free margin, involvement of the hair follicles and loss of lashes.



Developing lesion with central necrosis.

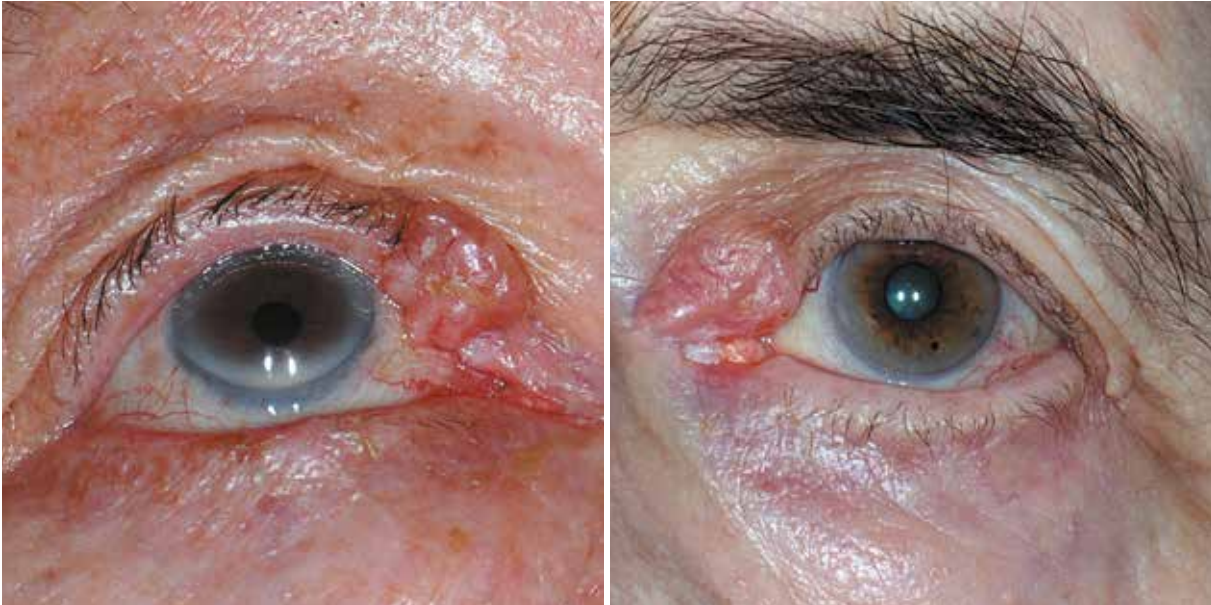Malignant epithelial tumors

Nodular basal cell carcinoma



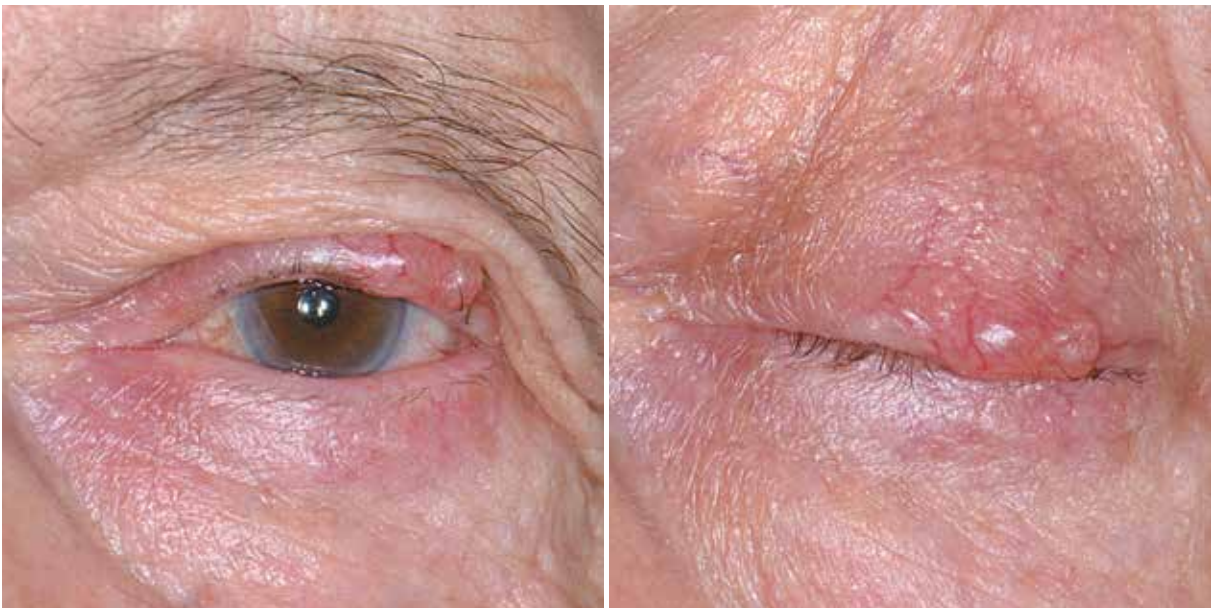At a later stage, the infiltration continues in the eyelid, which can lead to a malposition (ectropion here).

Nodular basal cell carcinoma



Developing forms must not be neglected.

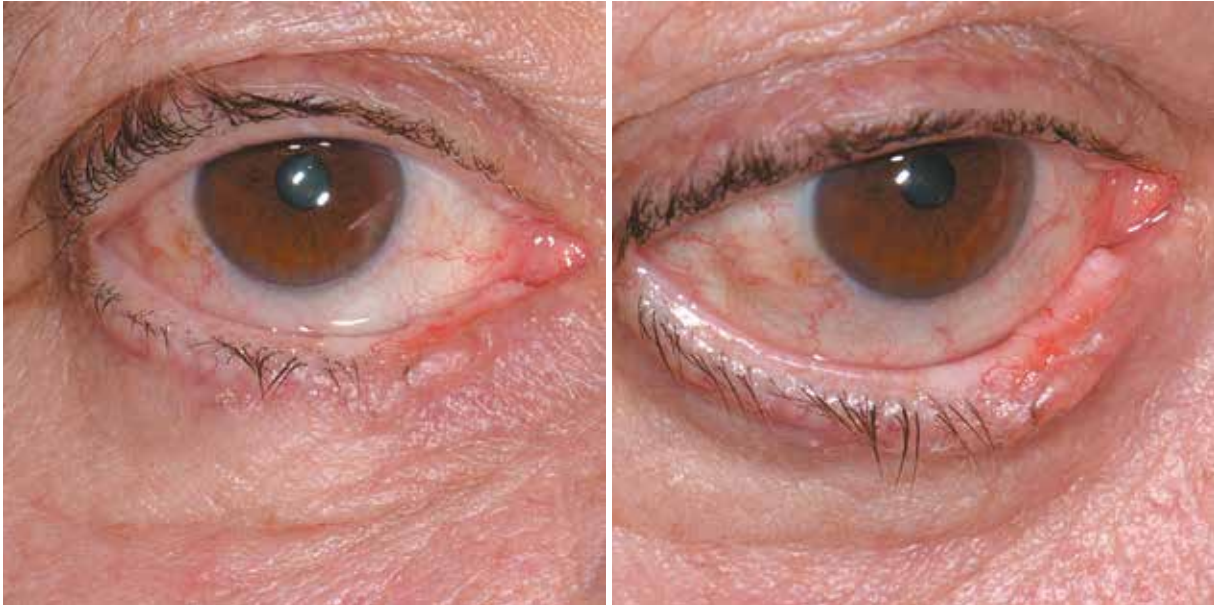If there are any doubts regarding the diagnosis, a biopsy must be performed. A histological analysis can thus be conducted to establish the diagnosis with certainty.



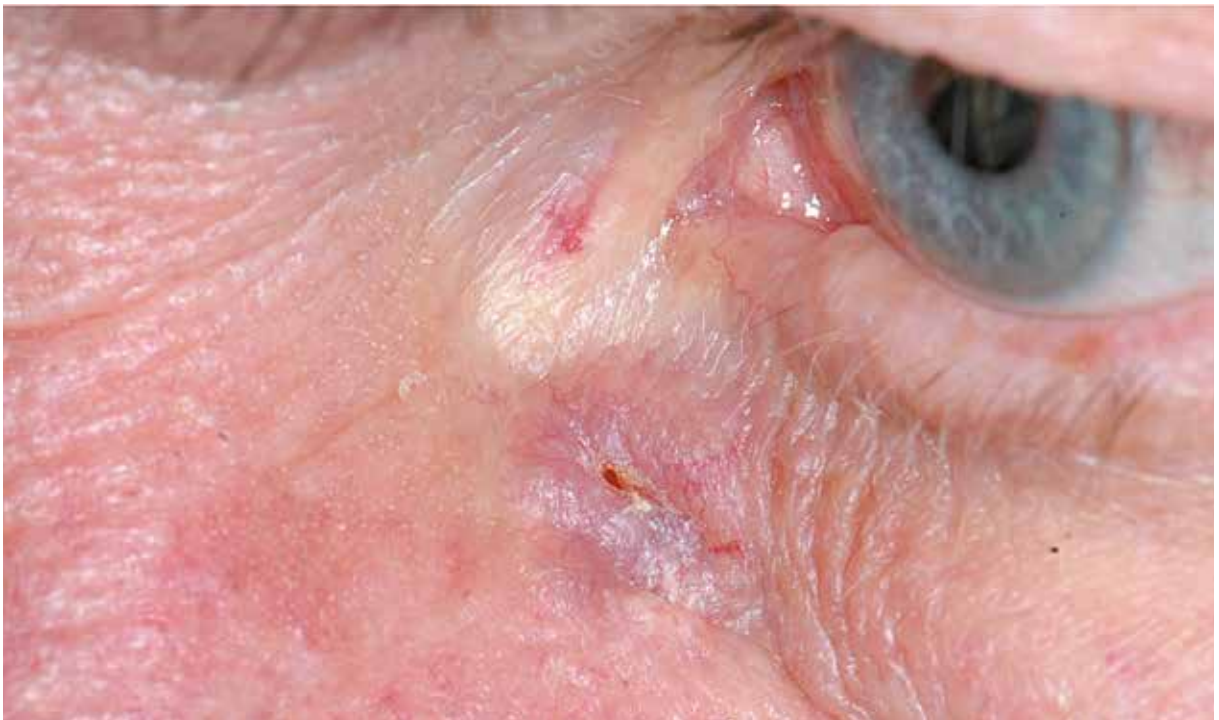The upper eyelid is more rarely affected. Madarosis is an early clinical sign.

Malignant epithelial tumors

Nodular basal cell carcinoma

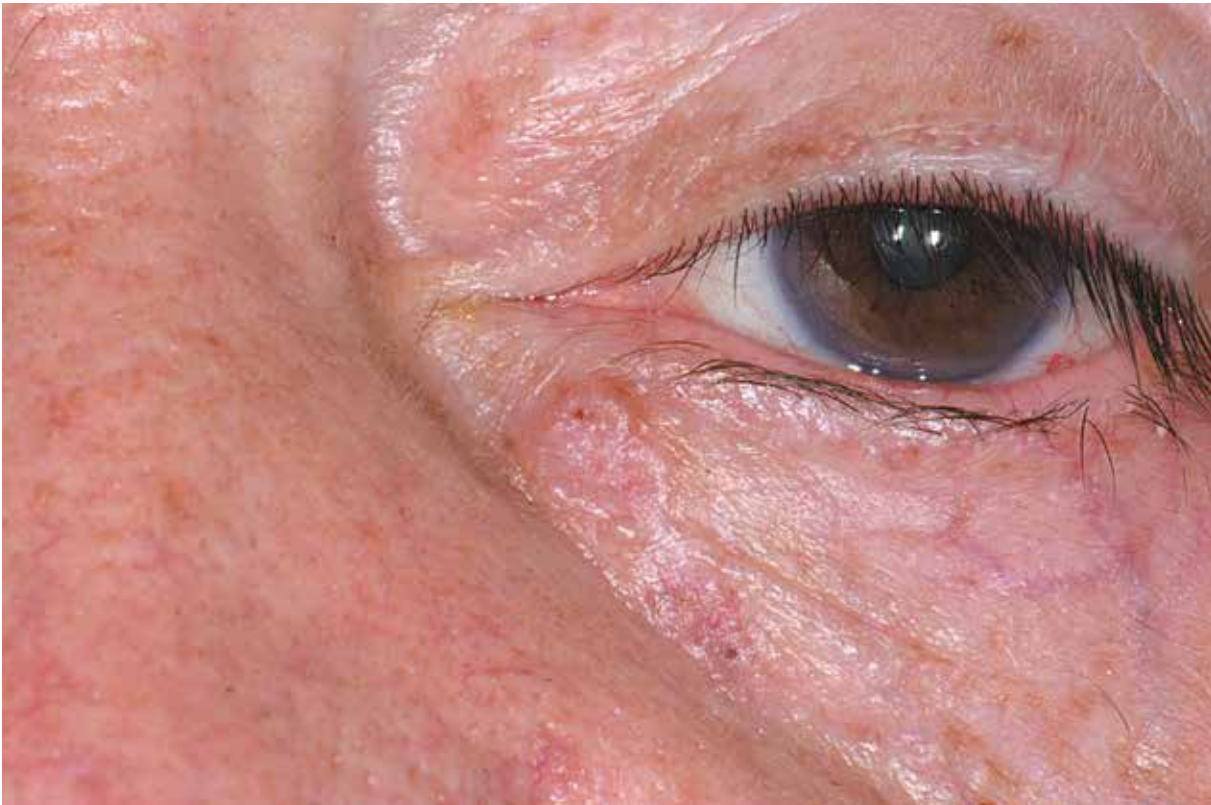


The lower eyelid is affected more often, particularly the free margin.



Basal cell carcinoma of the tear trough.

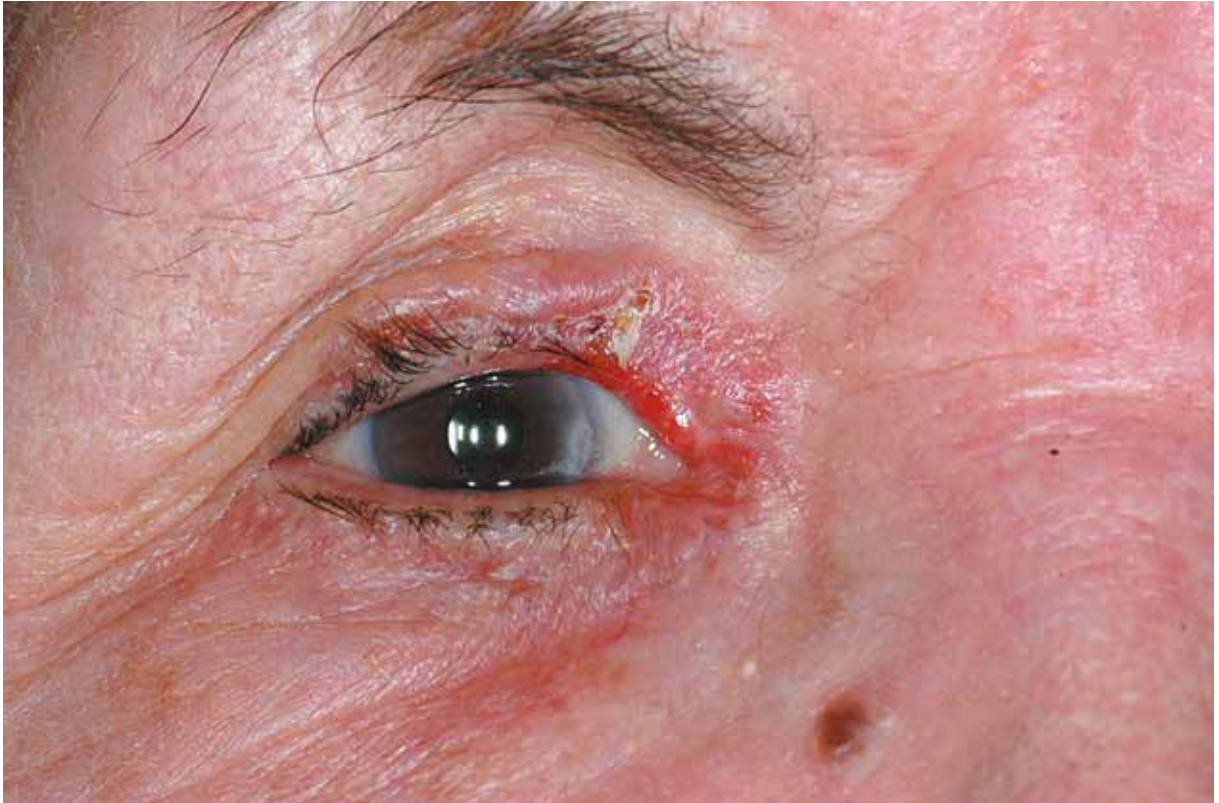Superficial basal cell carcinoma



The diagnosis is not easy, a slightly indurated plaque can be observed with a fine beaded strip along the edge and telangiectasia.

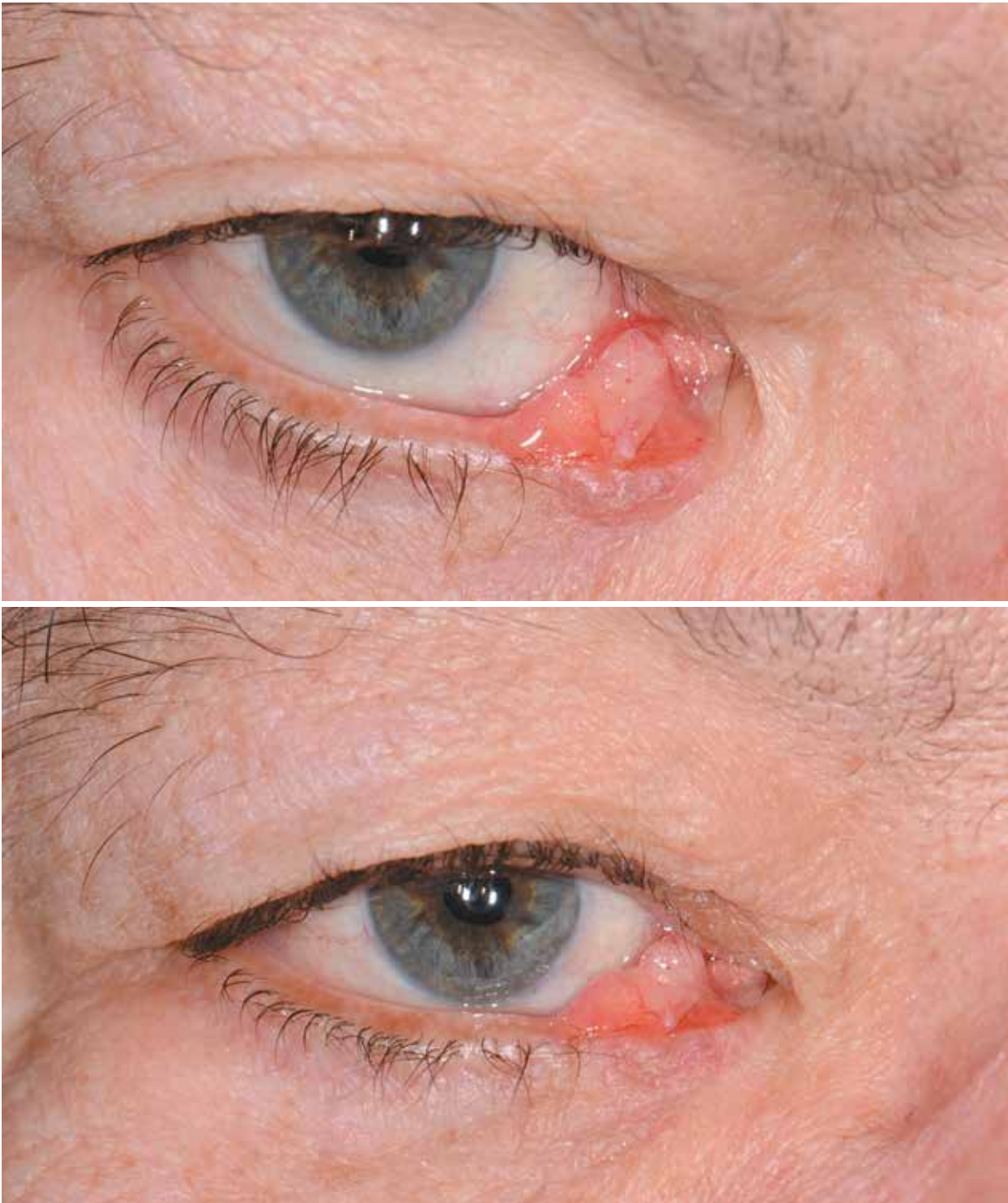The absence of ulceration contributes to the delay in diagnosis of the lesion inconspicuous in the dark circle under the eye.

Ulcerated superficial basal cell carcinoma



The retraction of the upper eyelid is a late sign, indicating extensive spreading.

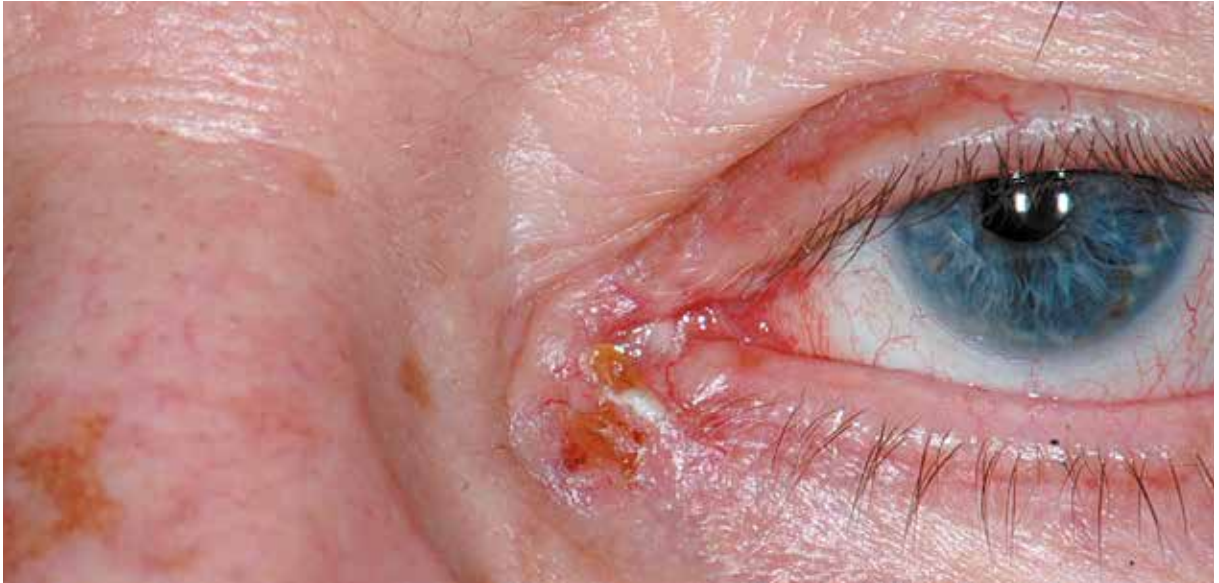Exophytic nodular basal cell carcinoma



Mixed basal cell carcinoma with nodule, ulceration. A histological examination will be performed to determine the differential diagnosis of an epidermoid carcinoma.

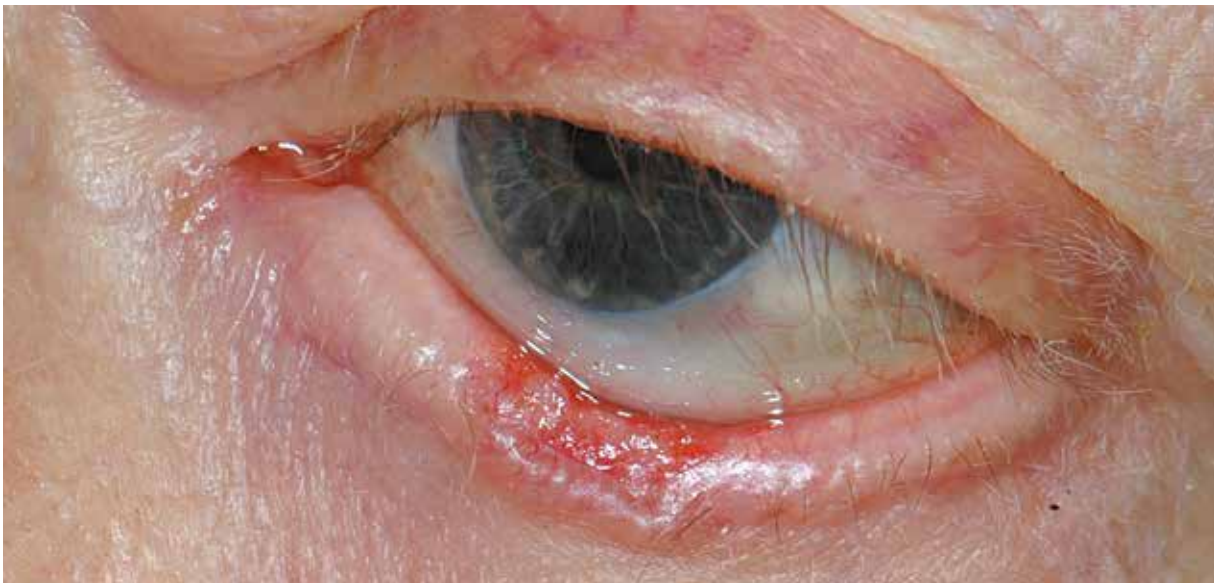Malignant epithelial tumors

Ulcerated basal cell carcinoma



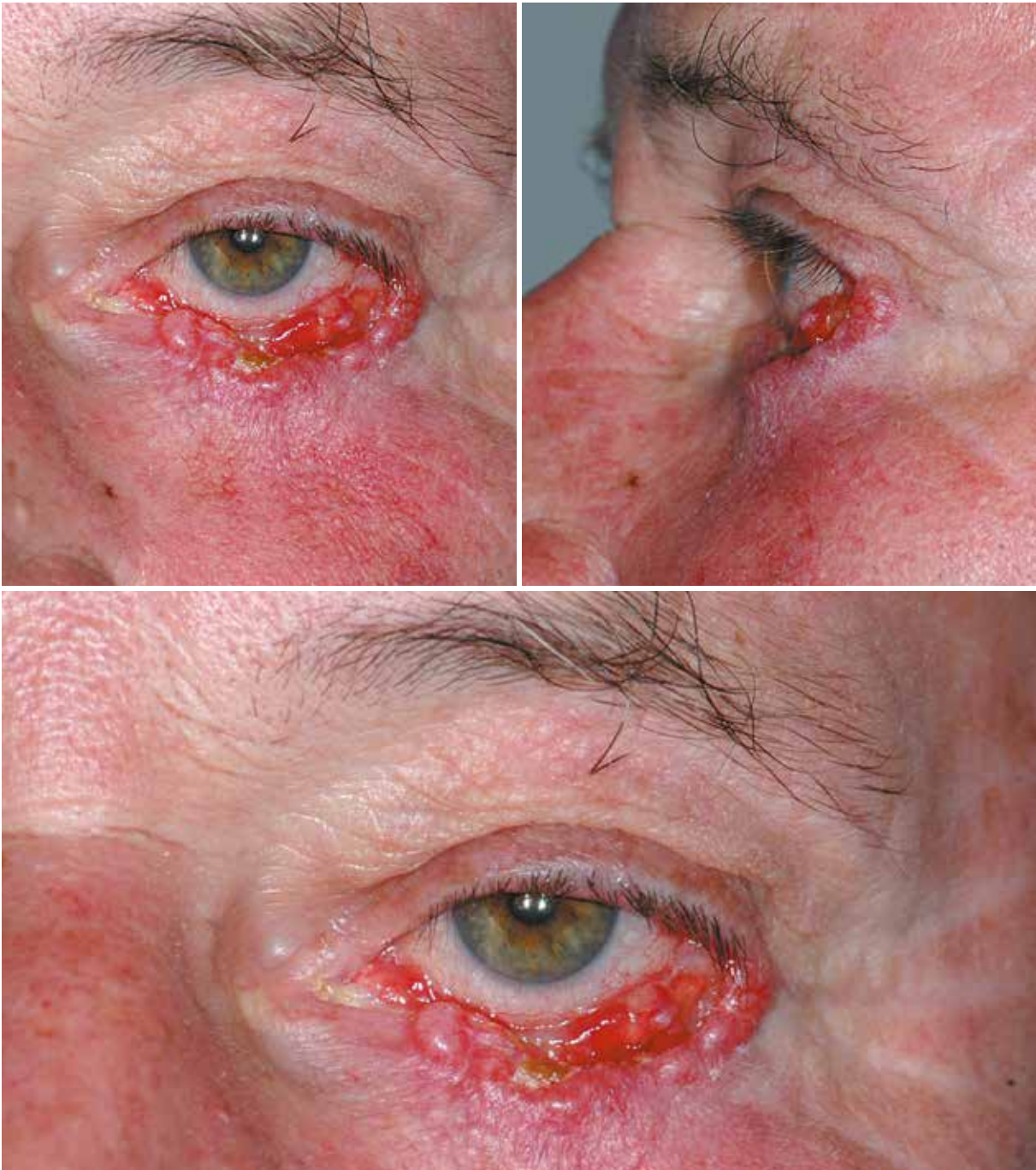
The appearance is heterogeneous with beads, ulceration, telangiectasia.

Ulceration in the inner canthus. The patient had been complaining about chronic irritation for several months.



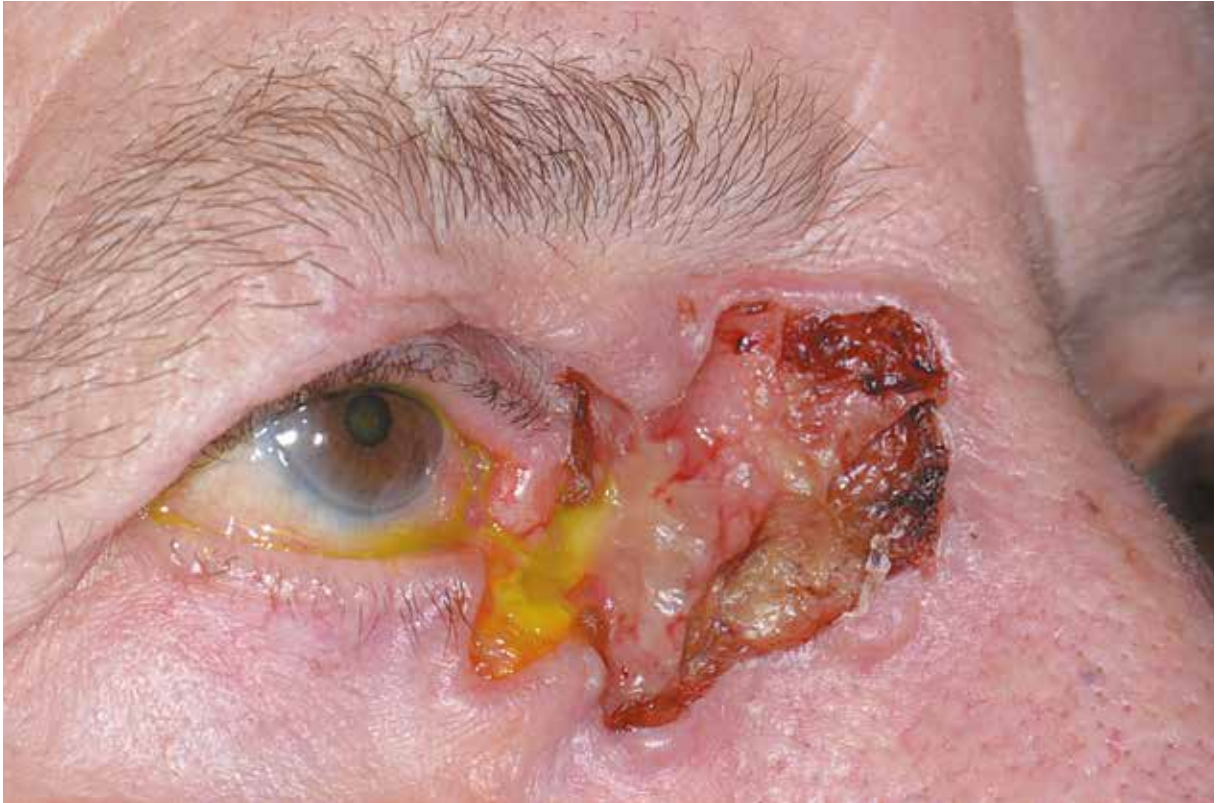It is the most common malignant palpebral tumor and is the proliferation of tumoral basal cells. The distinctive characteristic is the absence of metastasis.

Ulcerated basal cell carcinoma



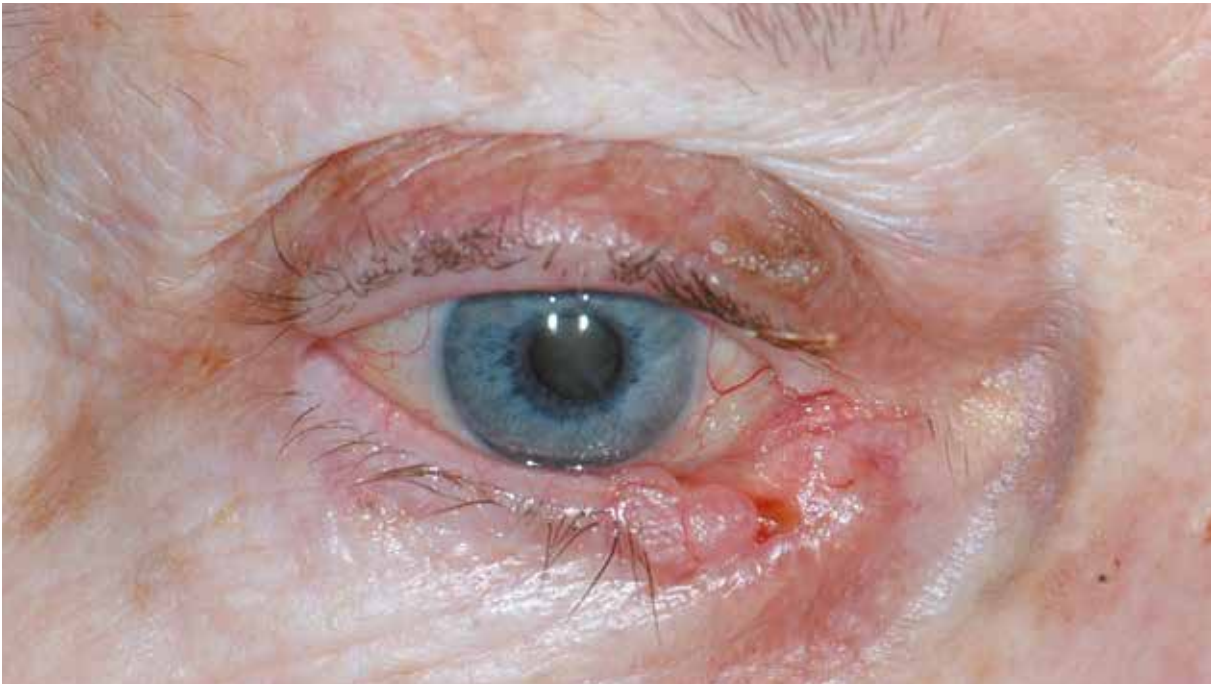Combination of ulceration with subcutaneous conjunctival invasion. Intra-orbital extension possible.

Ulcerated basal cell carcinoma

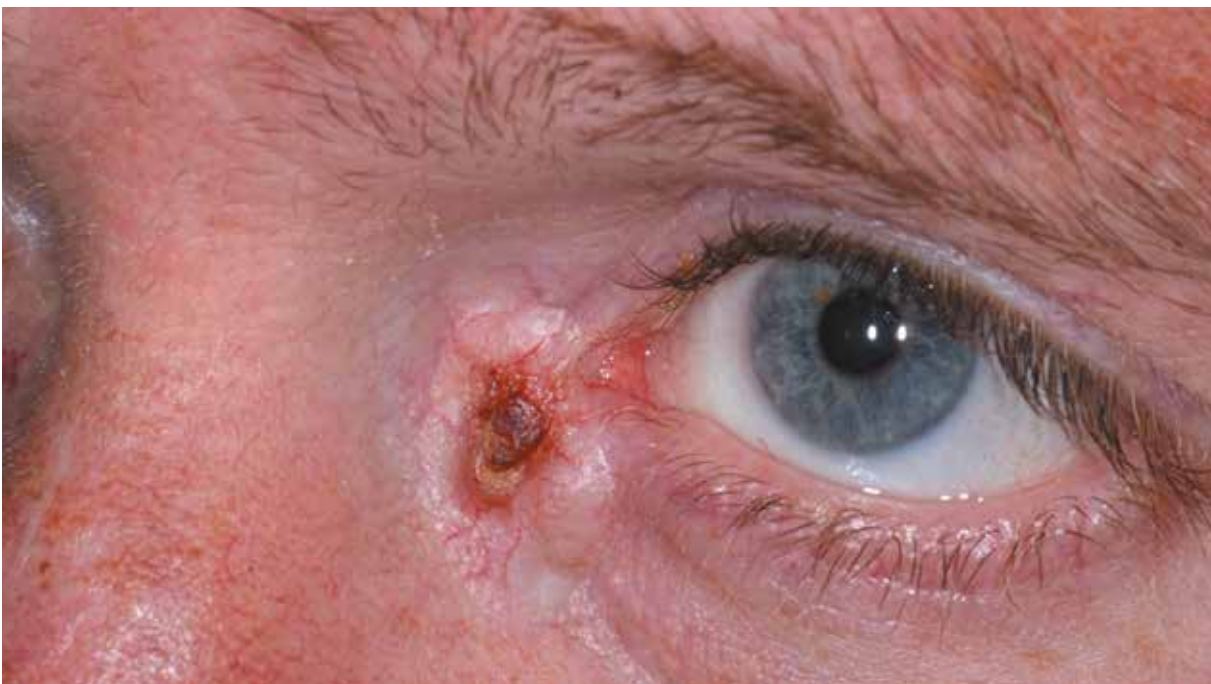

Basal cell carcinoma of the medial canthus with invasion and deterioration of the tear ducts, the canaliculi and the lacrimal sac.

Ulcerated basal cell carcinoma

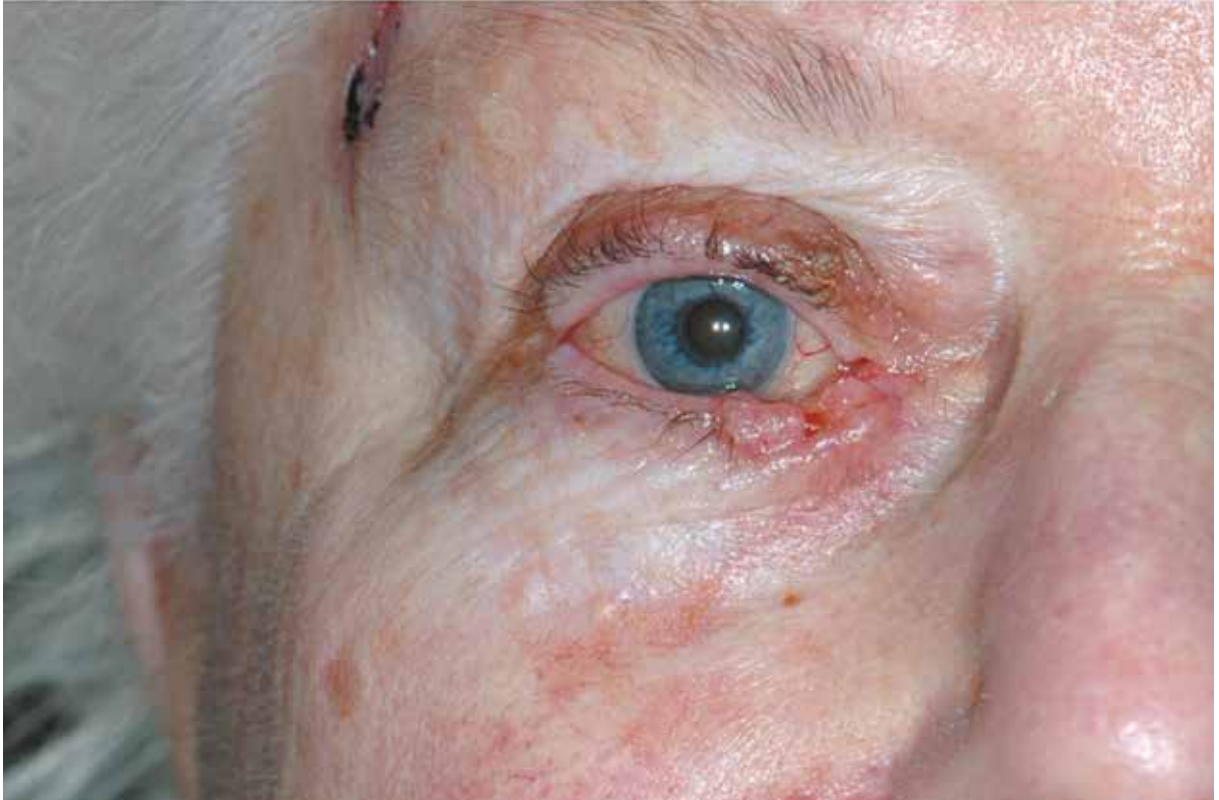

Basal cell carcinoma of skin origin with invasion of the meatus and the lacrimal puncta.



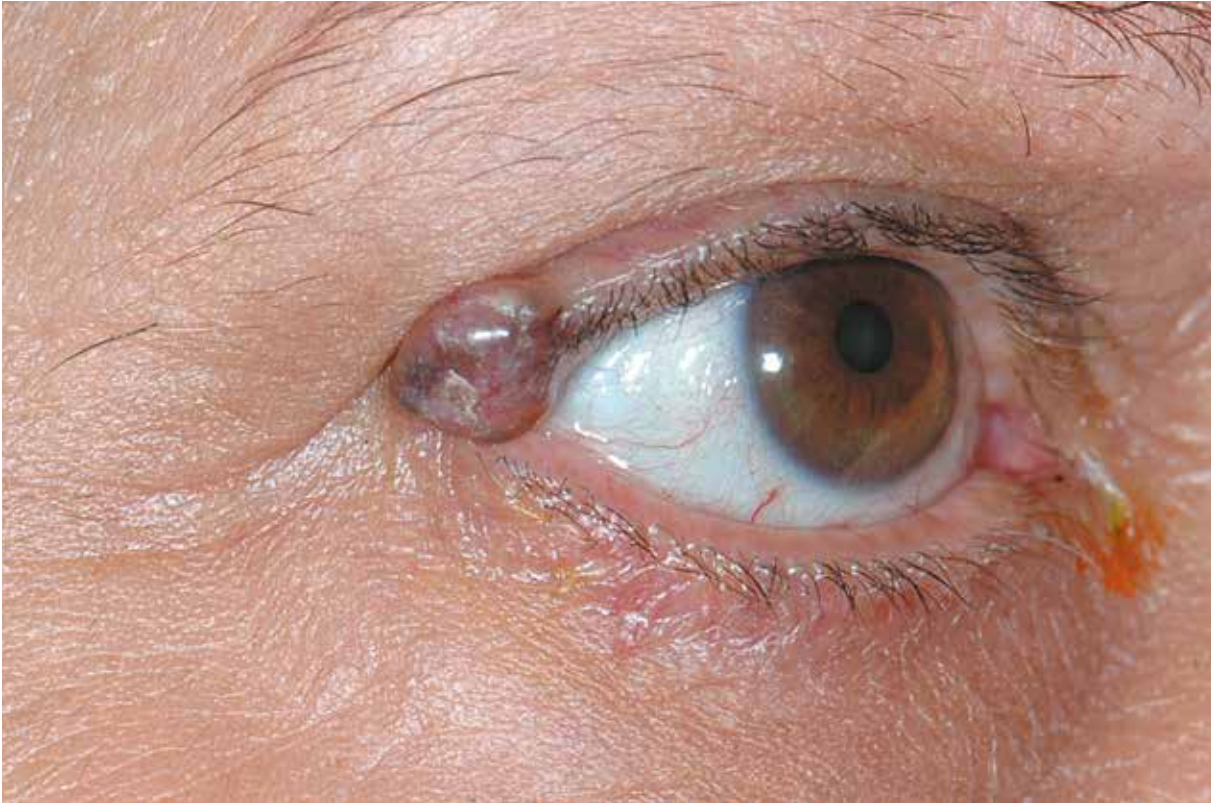
Basal cell carcinoma of the medial canthus, with nodule and ulceration in a young patient.

Ulcerated basal cell carcinoma



Basal cell carcinoma of the free margin of the lower right eyelid and the nasolabial fold, two areas considered «high risk» requiring broad surgical excision with verification of the edges.

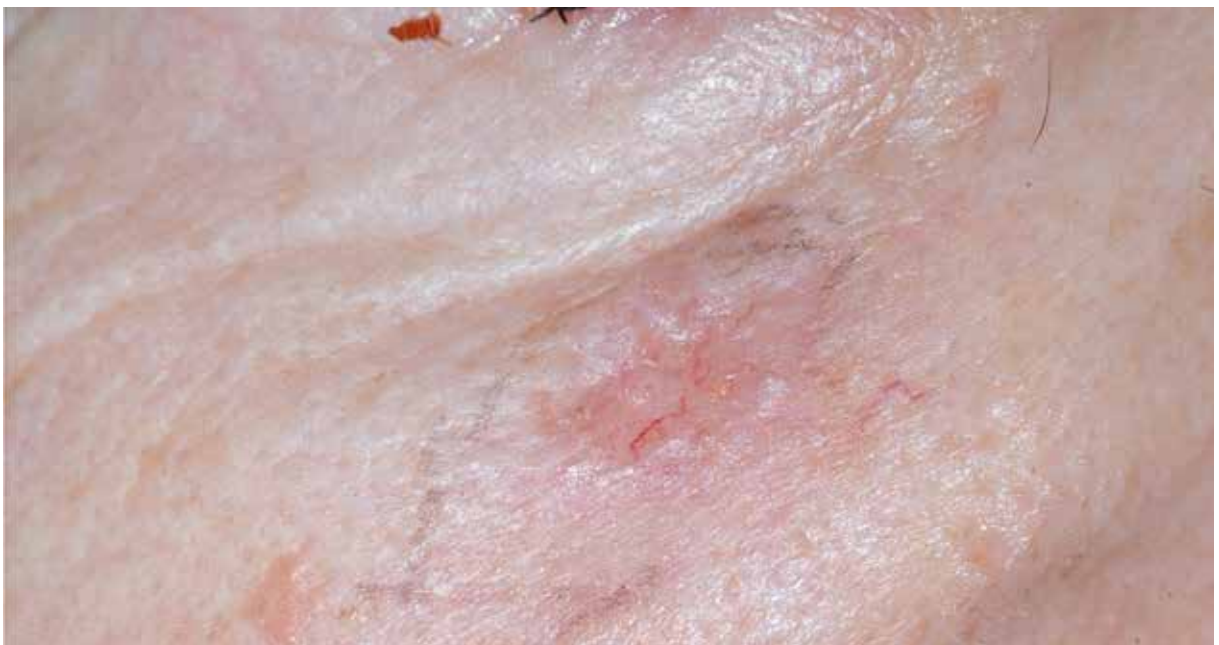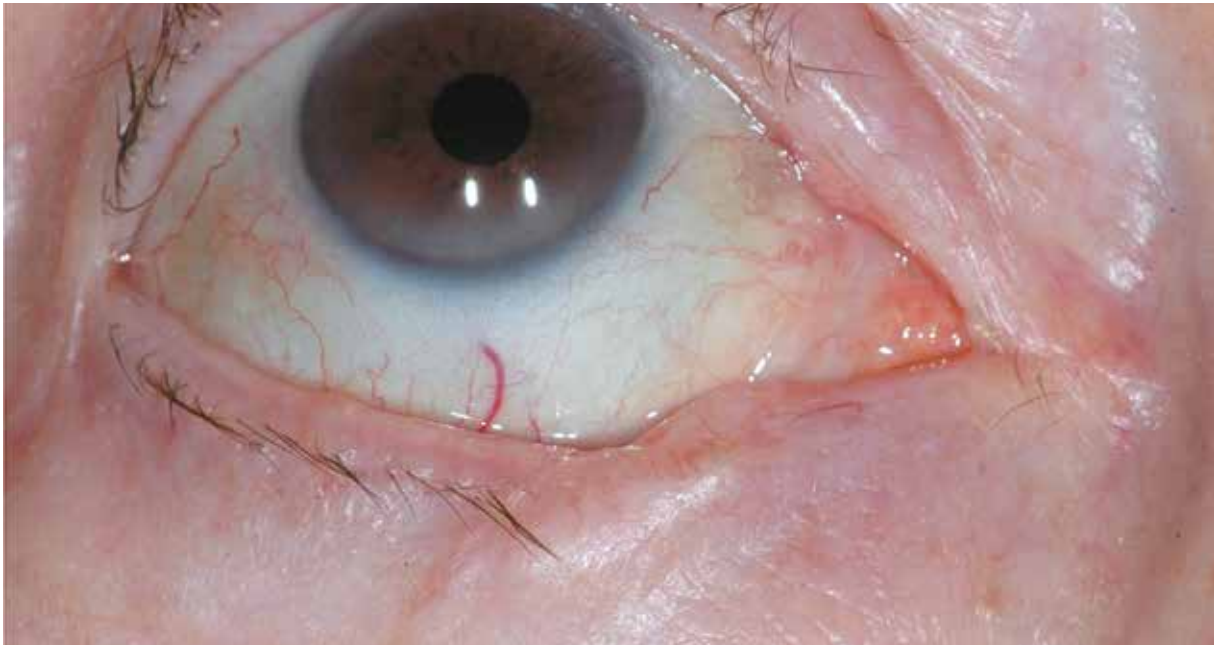
Pigmented basal cell carcinoma



Basal cell carcinomas can be pigmented.

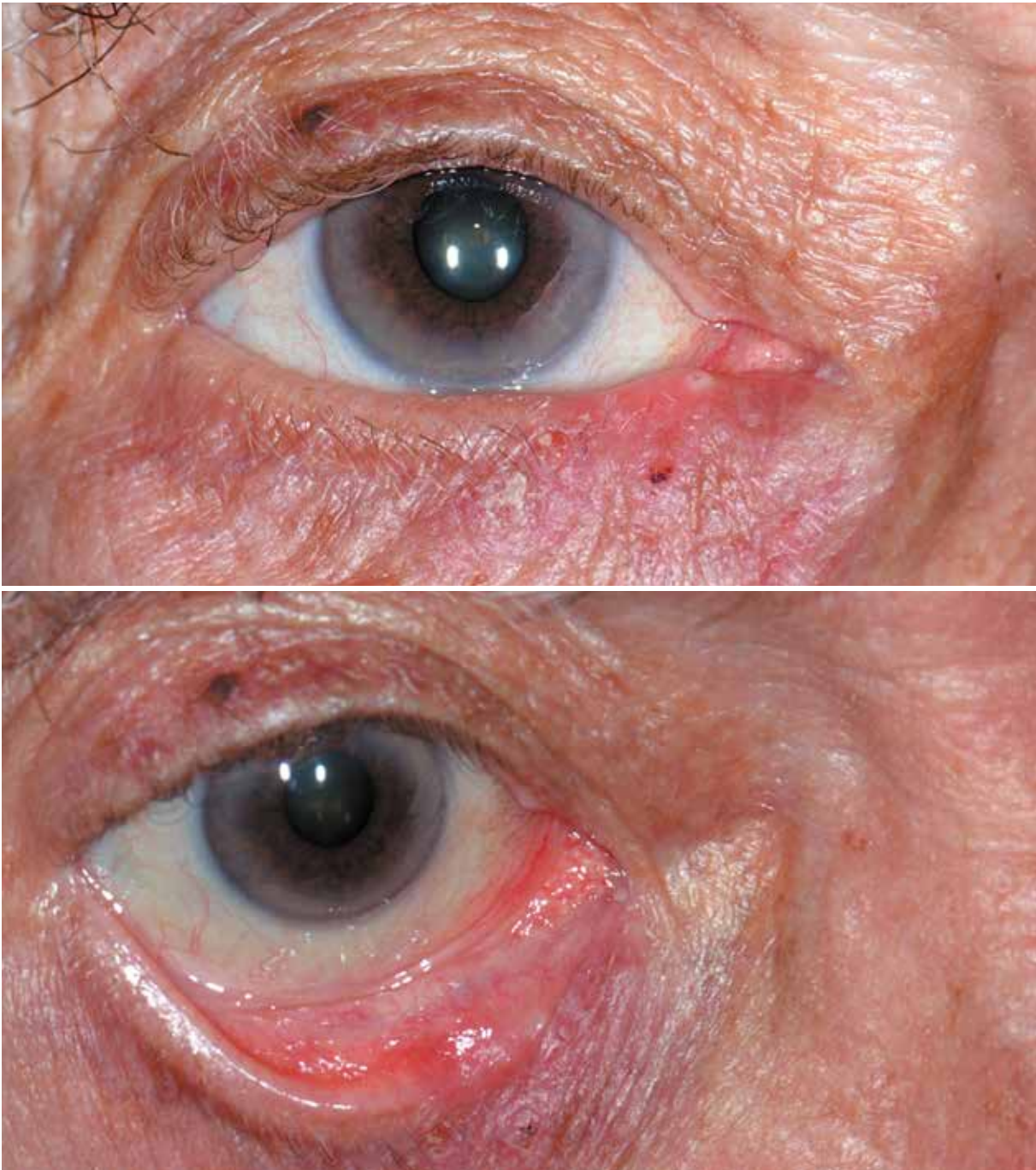
Brown, blue or black in appearance with a smooth and shiny surface. Lesion firm on palpation. It can be difficult to differentiate from a superficial spreading melanoma.

Sclerodermiform basal cell carcinoma



Appearance of an adhesive white plaque of which the edges are hard to distinguish. The histological infiltration is always greater than the superficial lesion suggests. The resection margins will be greater due to the higher risk of relapse.

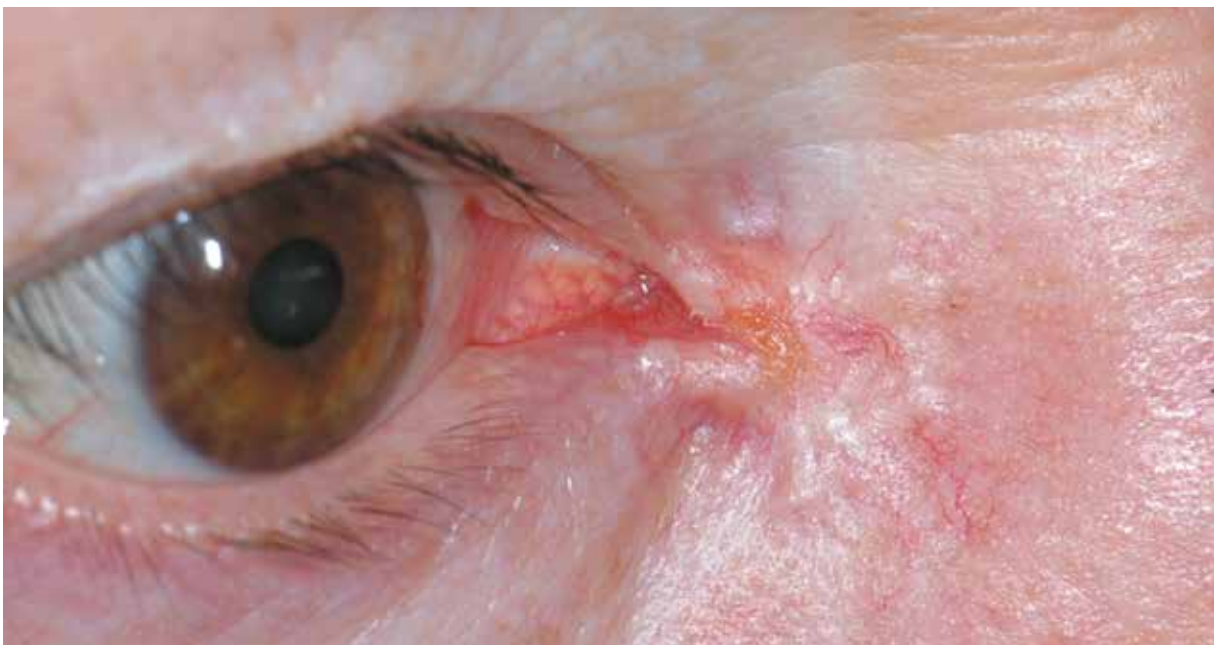
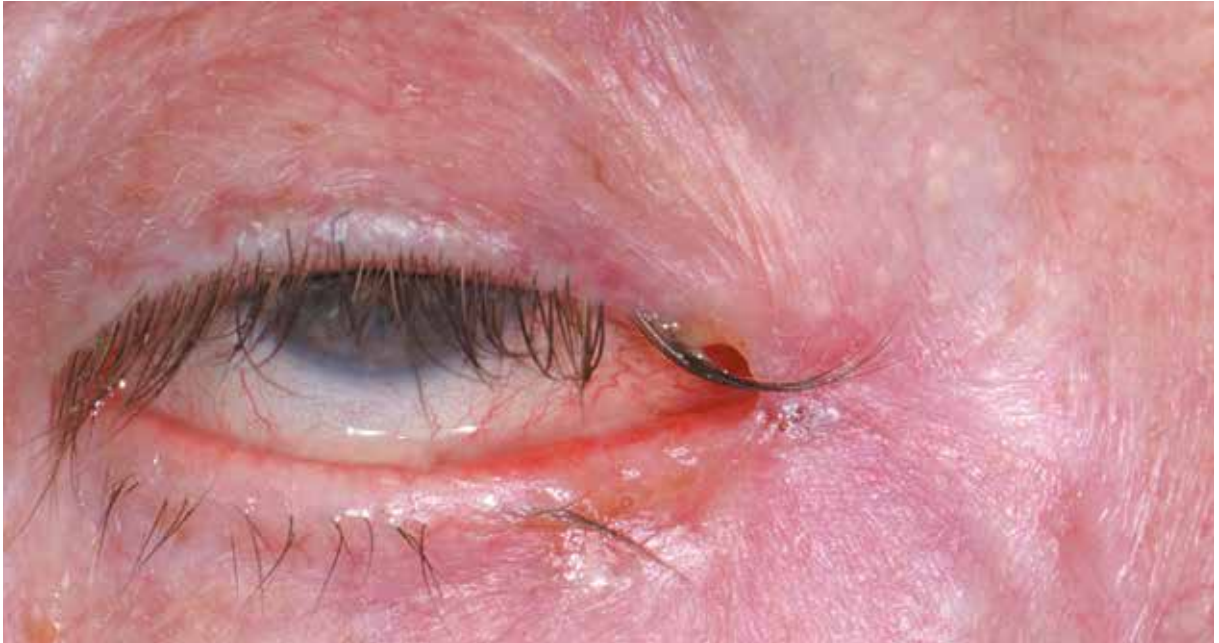Sclerodermiform basal cell carcinoma



Sclerodermiform basal cell carcinoma with appearance of plaque or superficial scar. Edges are hard to assess, white in color with a few hyperpigmented areas.

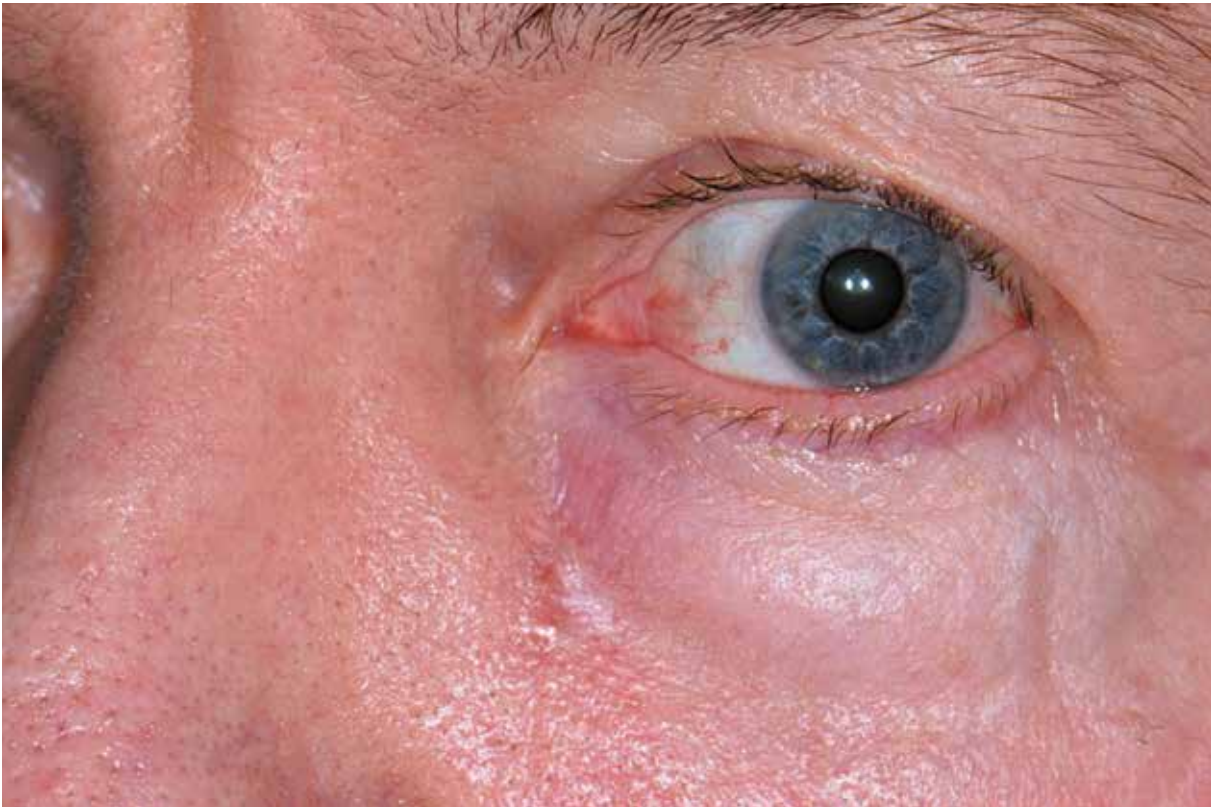The histological lesion is larger than the clinical aspect. Loss of lashes can be observed.

Sclerodermiform basal cell carcinoma



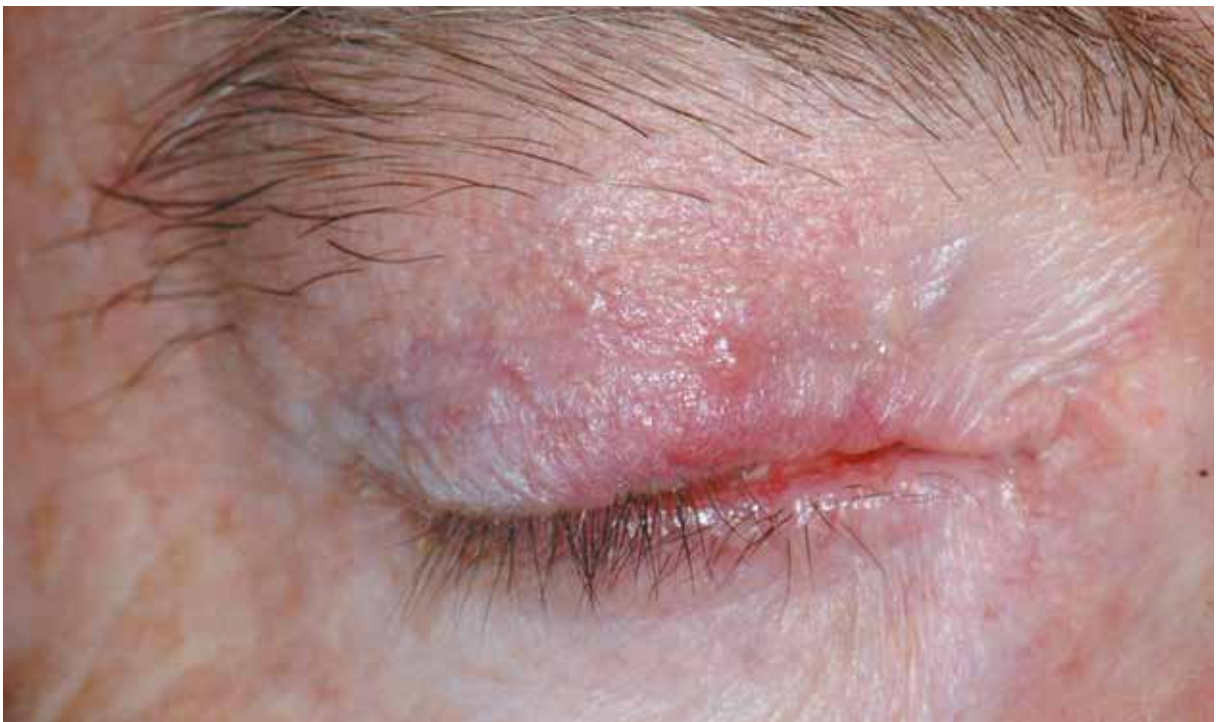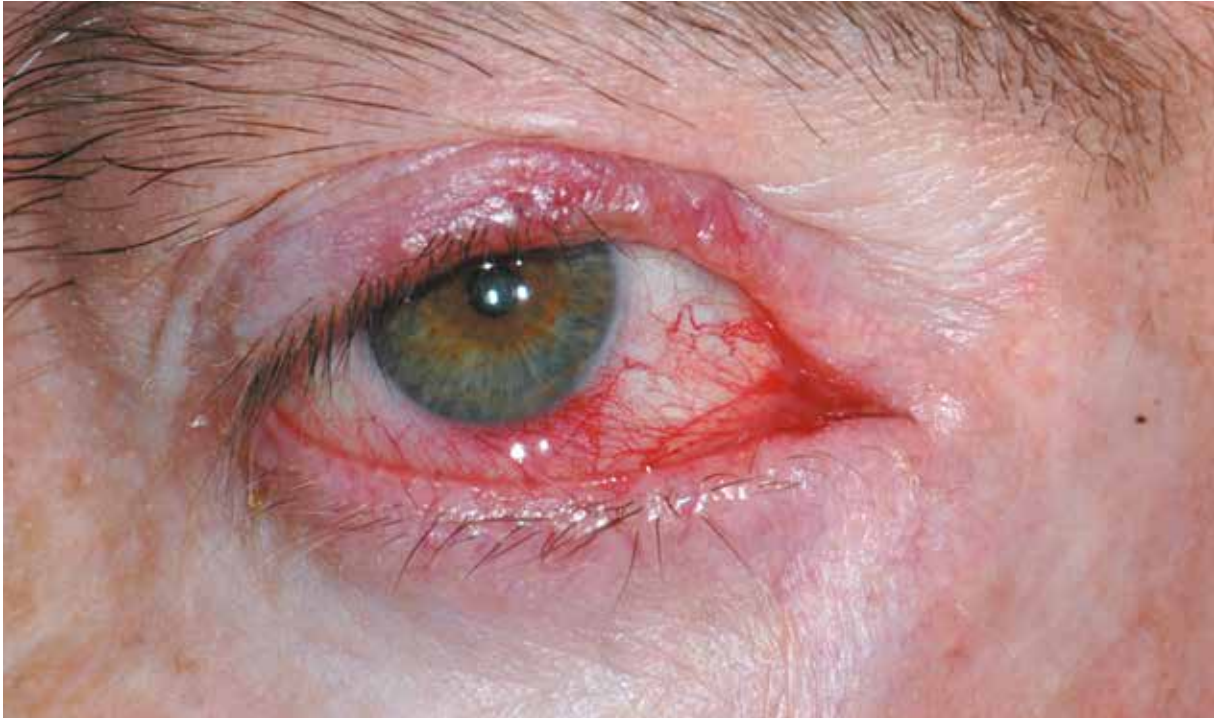Sclerodermiform basal cell carcinoma, appearance of skin retraction and ectropion of the lacrimal punctum.

Sclerodermiform basal cell carcinoma



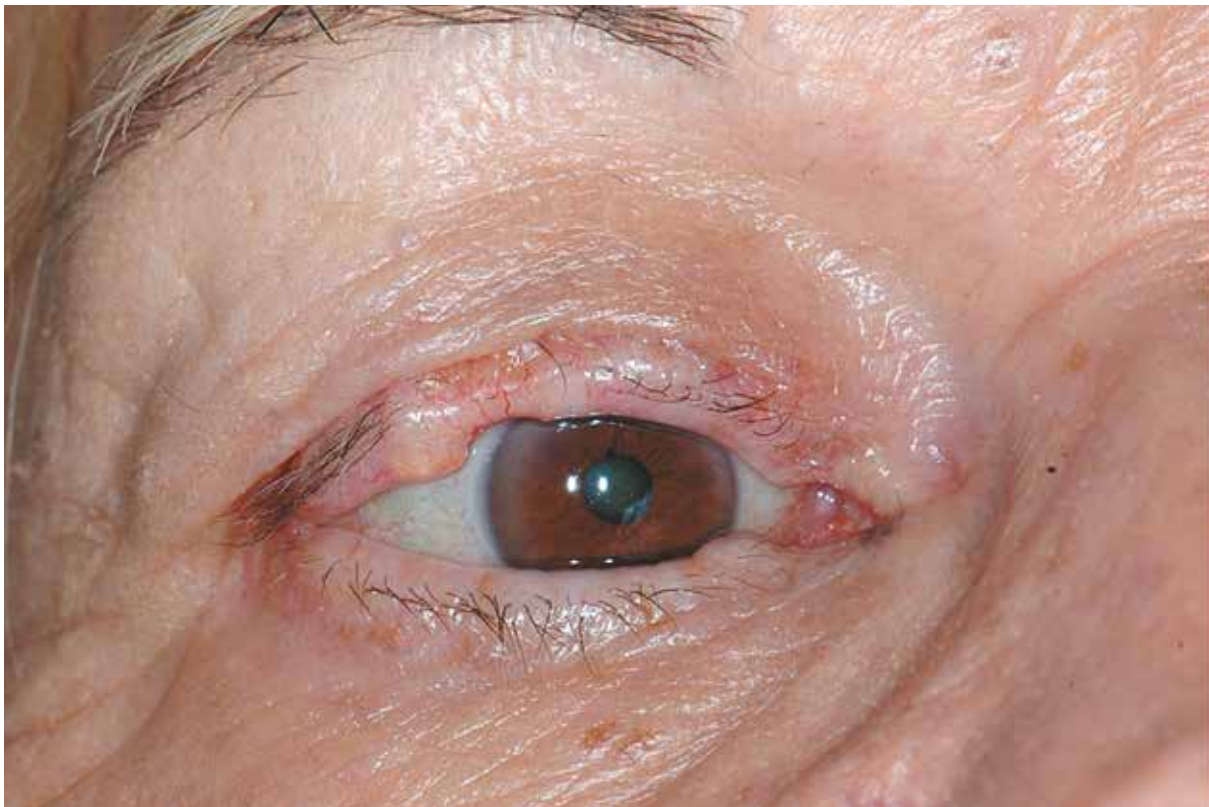
Sclerodermiform basal cell carcinoma of the tear trough in a young subject.

Sclerodermiform basal cell carcinoma



Sclerodermiform basal cell carcinoma on the free margin after a relapse.

Sclerodermiform basal cell carcinoma



With sclerodermiform types, the progression is more insidious, with here moderate madarosis compared to the invasion of the tarsus.

2. Sebaceous tumors

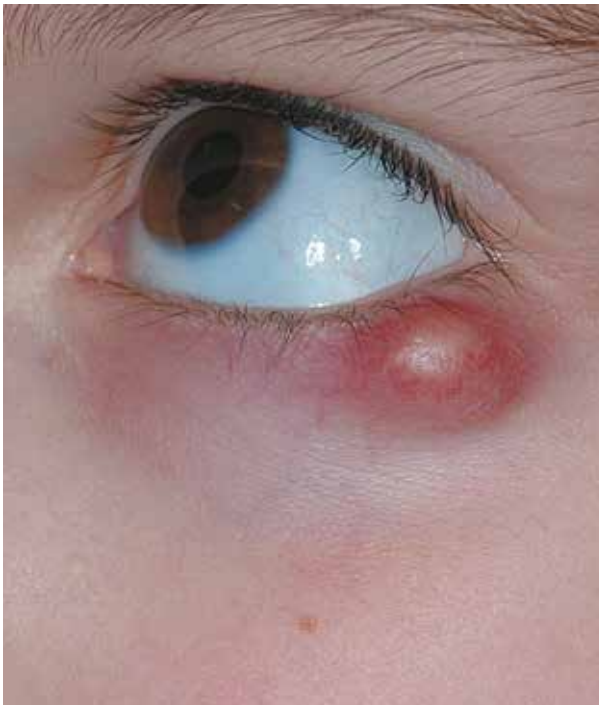Benign sebaceous tumors

The Glands of Zeis and the Meibomian glands secrete the lipid layer of the lacrimal film.

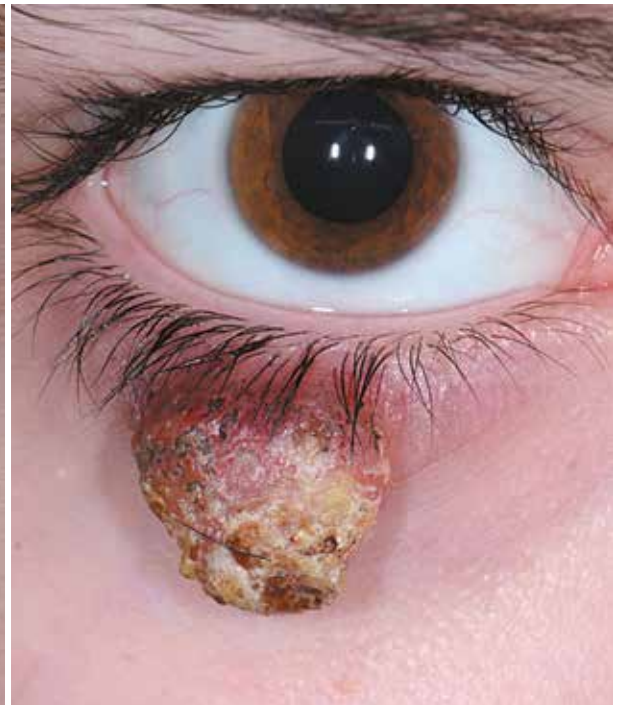During a blink, these secretions are spread over the surface of the aqueous layer of the lacrimal film.

These exocrine glands can result in a series of conditions from inflammation to palpebral tumors.

Chalazion



External Chalazion with redness of the eyelid and a bulge the size of a pea.

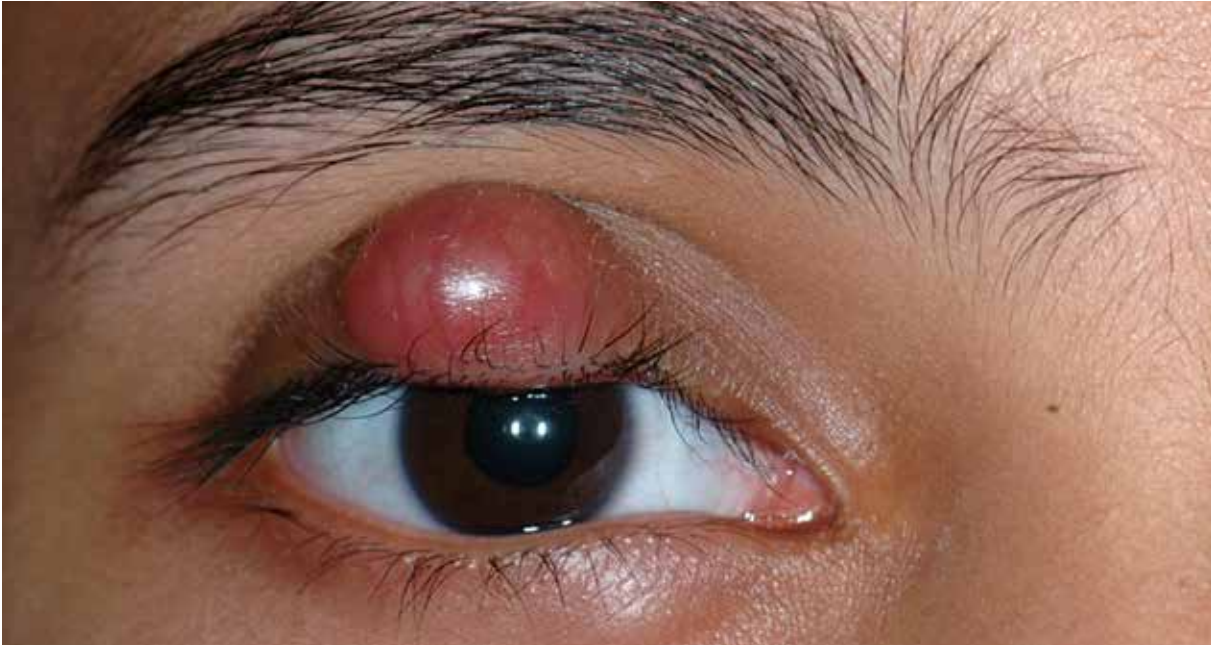

Pre-fistulated external Chalazion with ulceration and hyperkeratotic appearance.

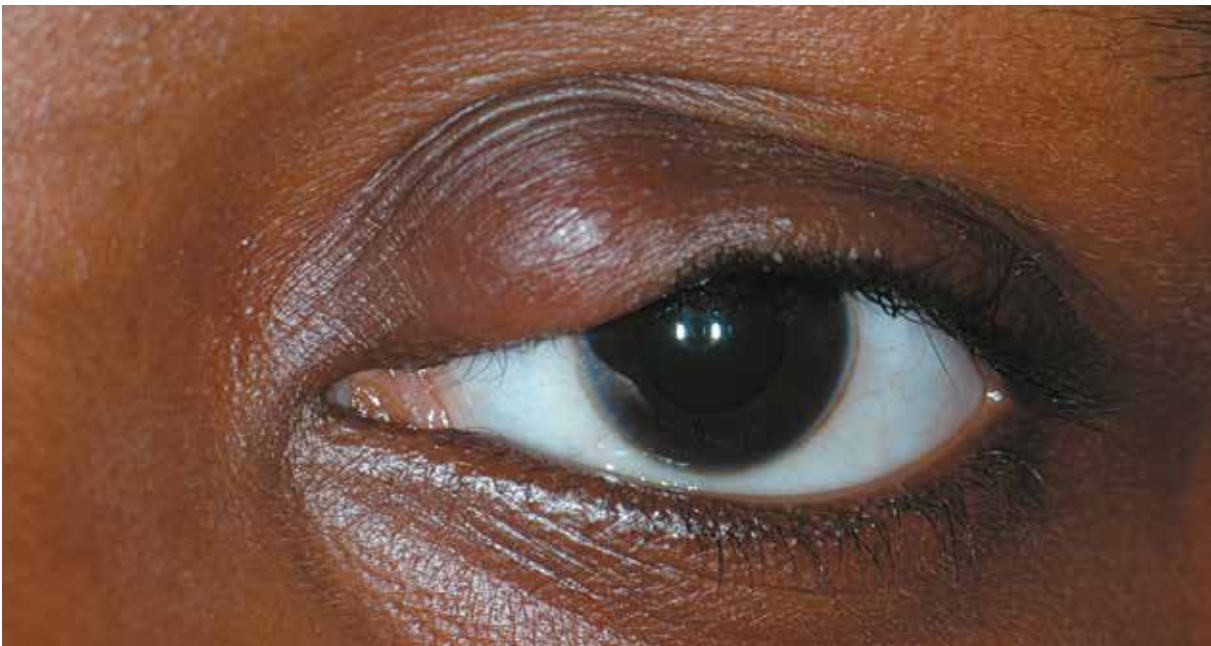
The chalazion is an anthogenic lipogranuloma of the tarsus, characterized by a granulomatous inflammatory reaction against the fat produced by the sebaceous glands, notably the Meibomian glands.

Chalazions are extremely common and there are several forms: external and internal chalazions.

Chalazion

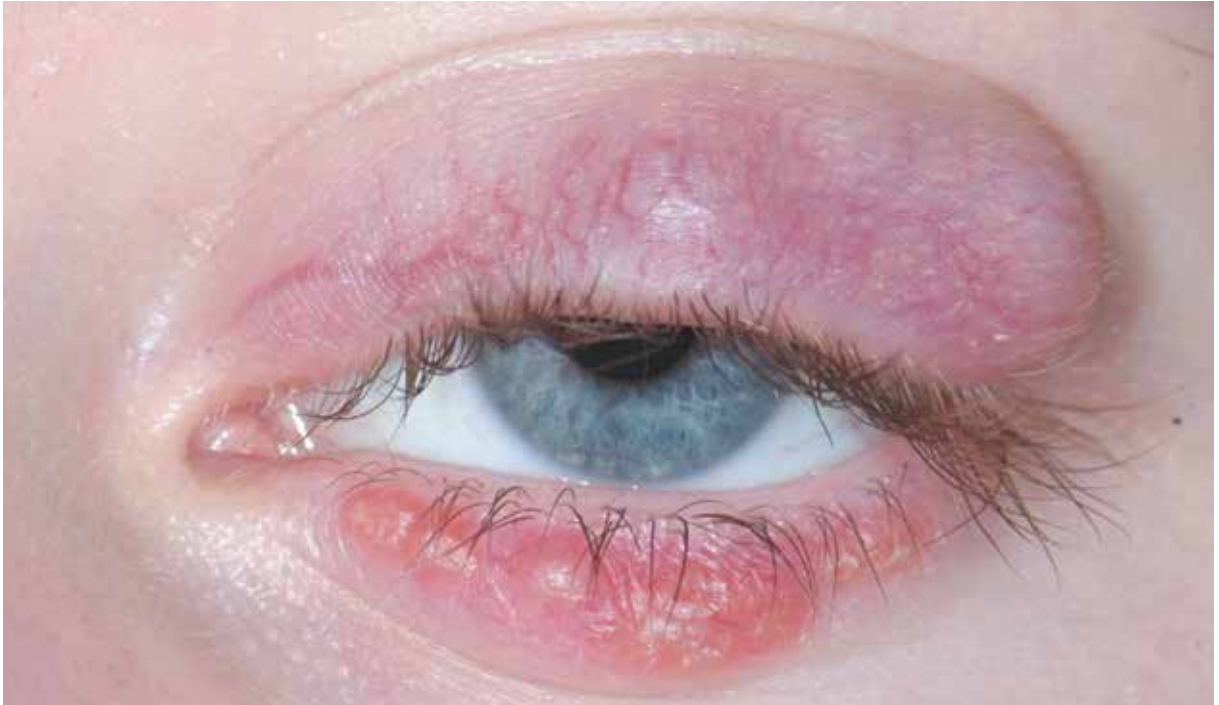

Mixed appearance, external chalazion of the upper eyelid and internal chalazion of the lower right eyelid.



External Chalazion of the inner third of the upper eyelid.

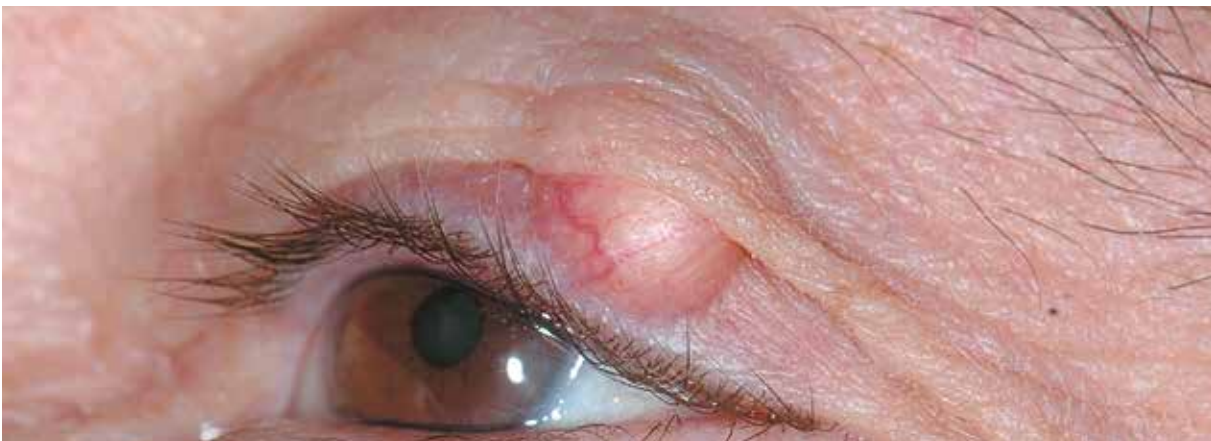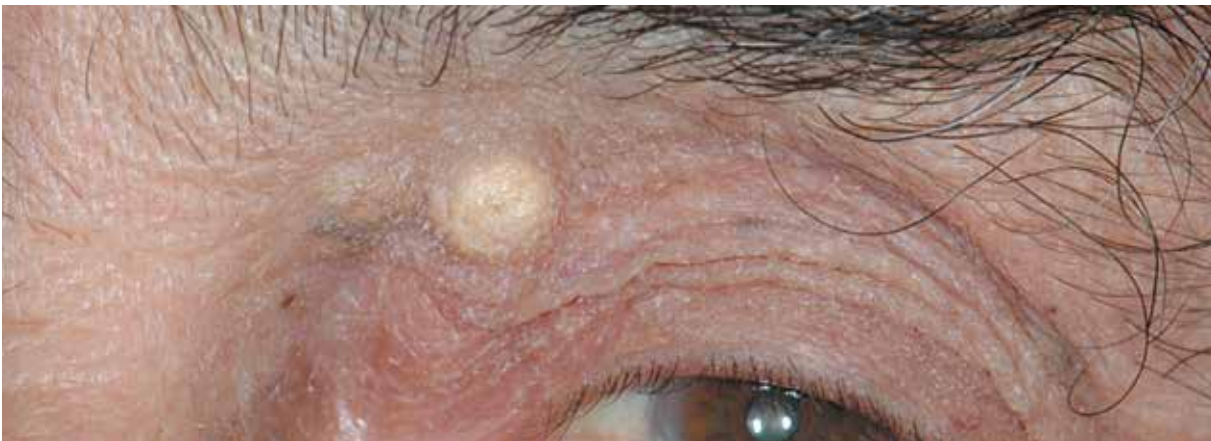
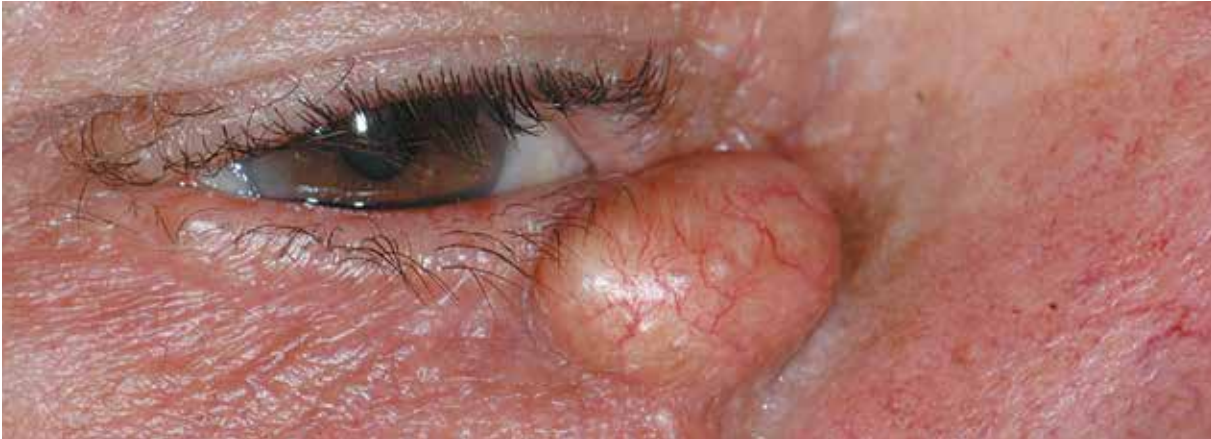Chalazion



Multiple chalazia:

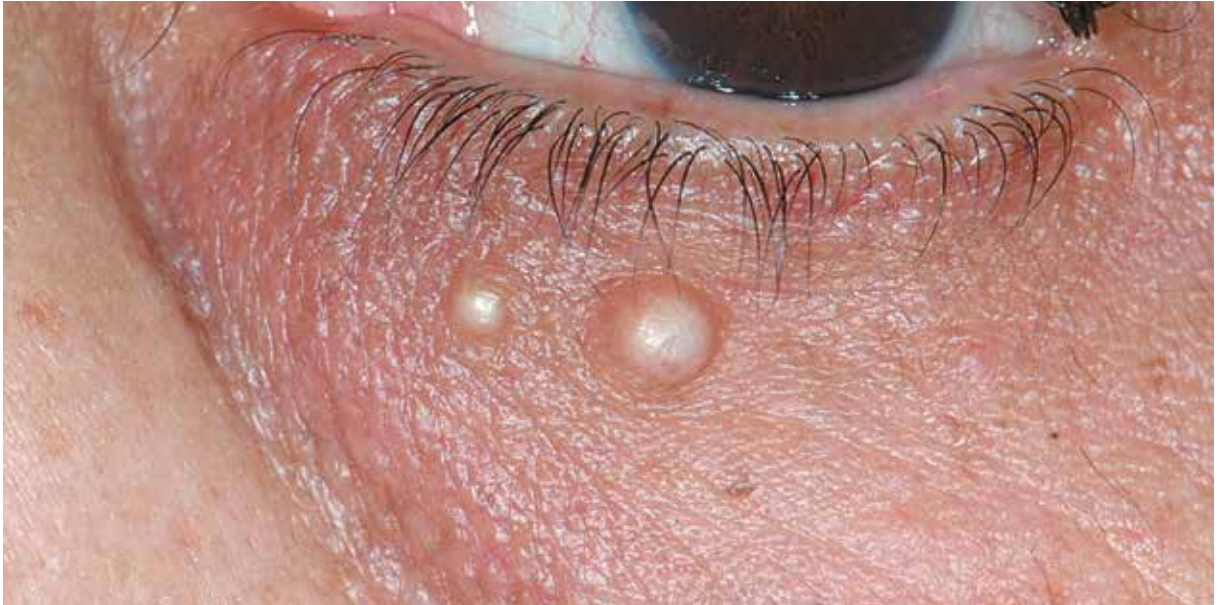- upper left eyelid: internal chalazia.
- lower left eyelid: appearance of confluent tarsitis.

Sebaceous cyst



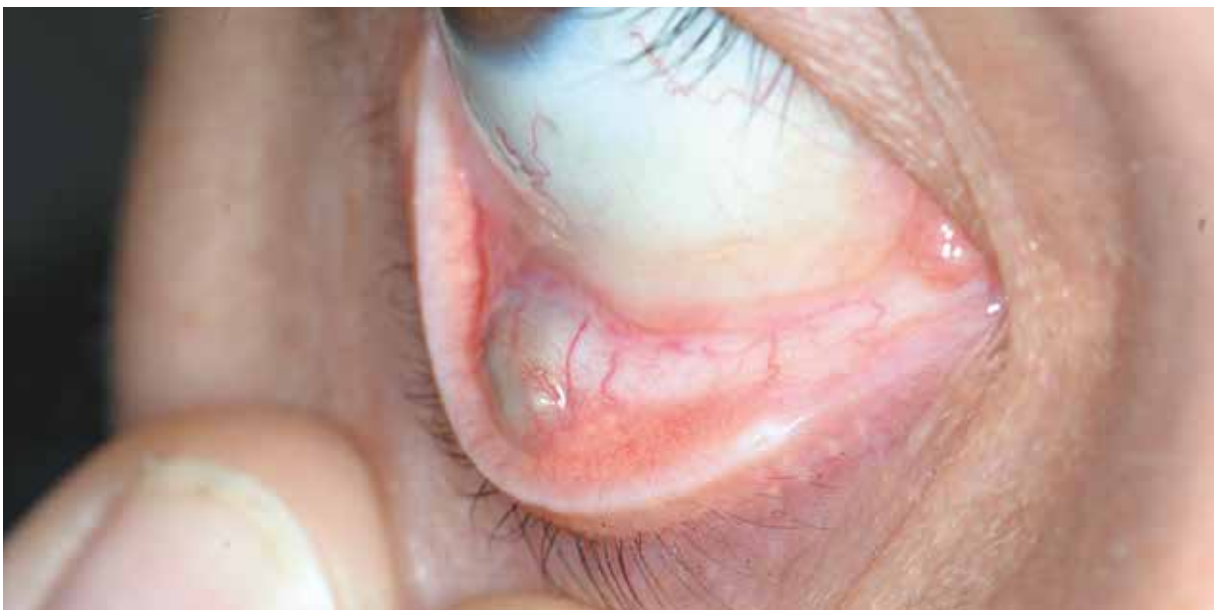Comprising a thin epidermal wall, it contains keratin and can burst spontaneously.
It develops within the epidermal sebaceous glands and is distinguished from a chalazion that develops within the meibomian glands.

Superficial sebaceous cyst



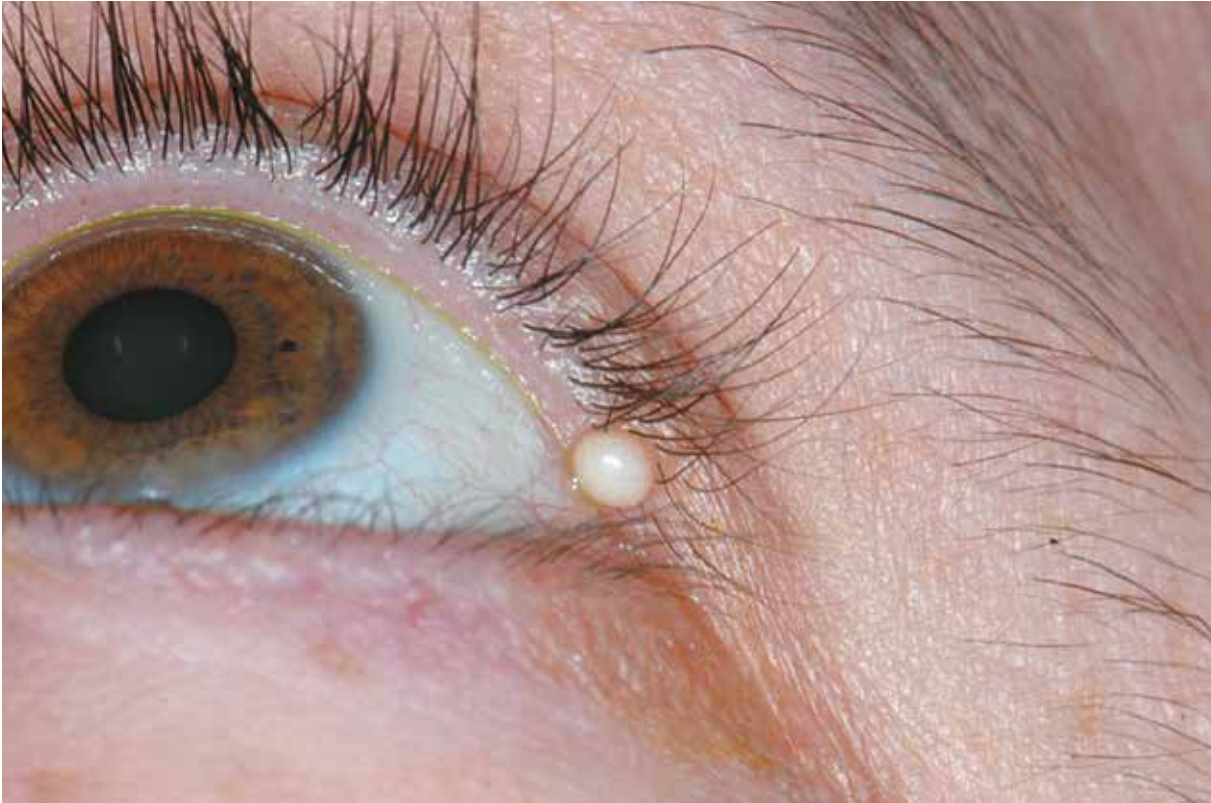Comprising a thin epidermal wall, it contains keratin and can burst spontaneously.

Treatment comprises surgical excision, sometimes perforation with a needle to remove the sebum is enough.



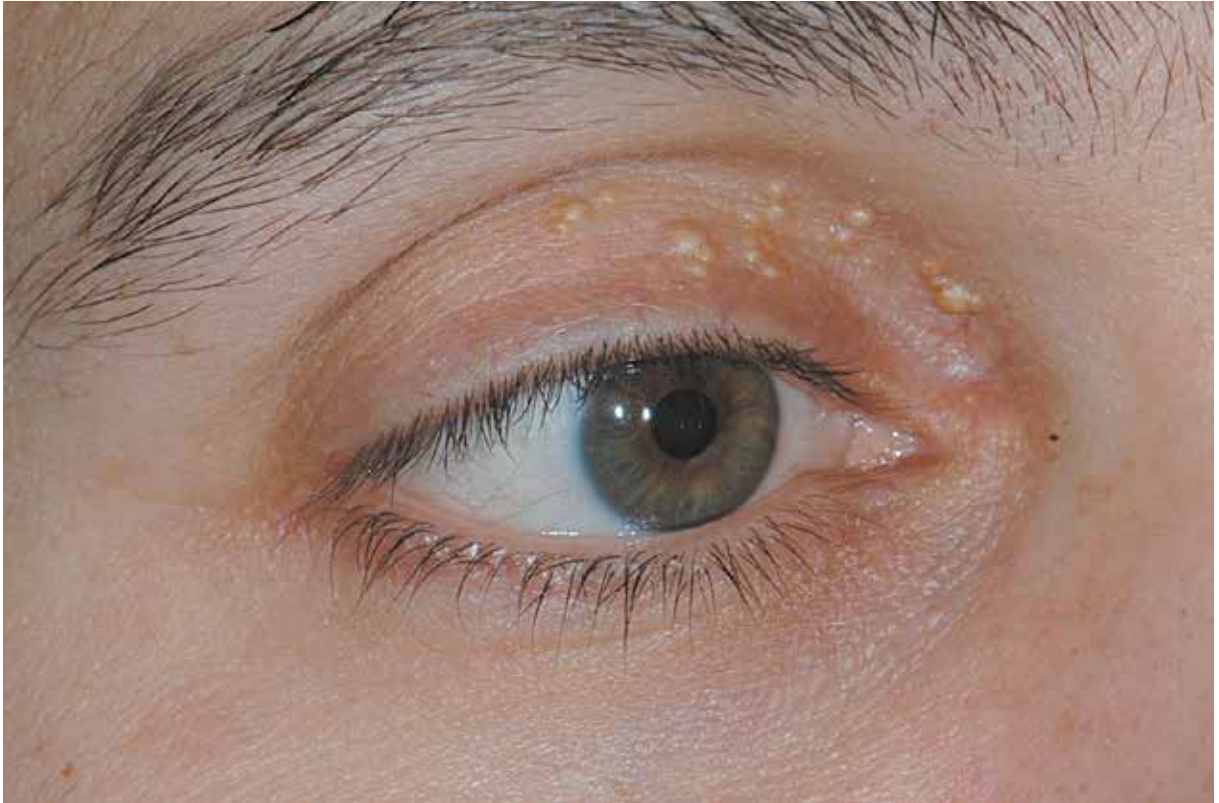Sub-conjunctival spreading sebaceous cyst.

Cyst of Zeiss



Swelling of a cyst of Zeiss on the free margin.

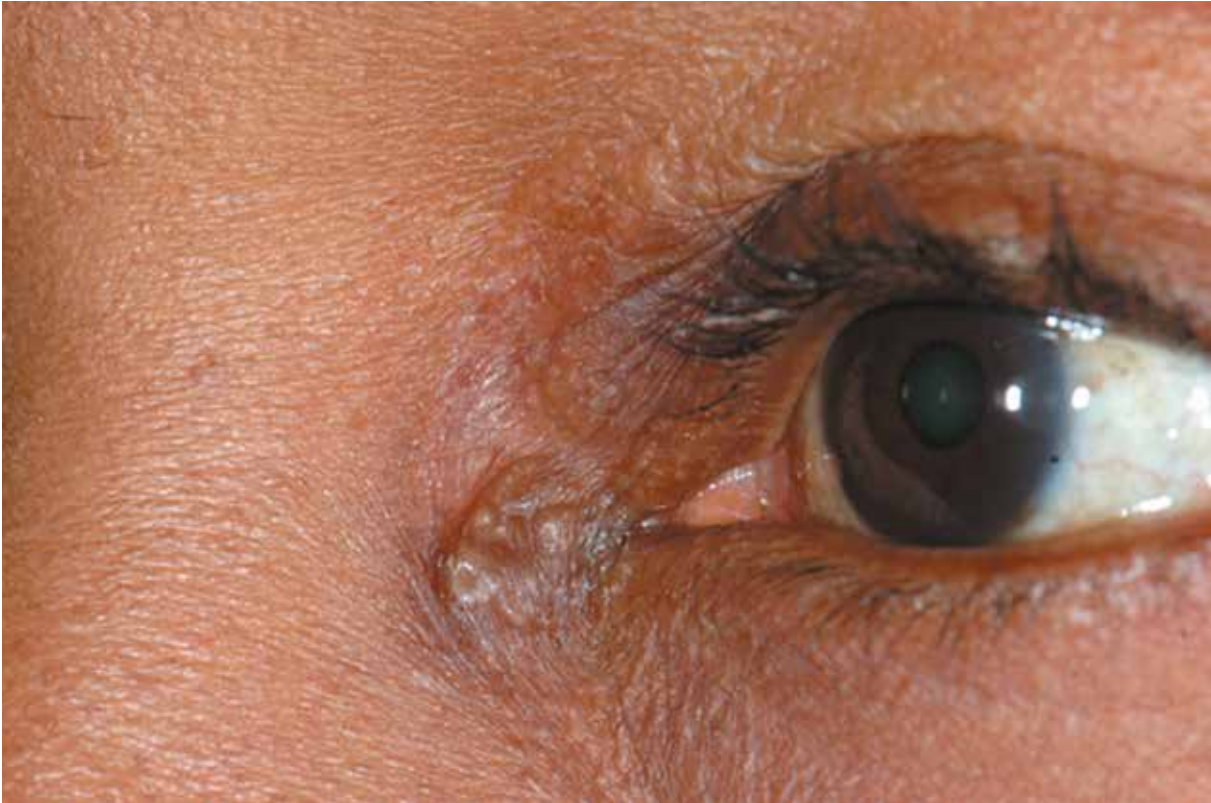
Milium



Milia are very small, superficial, yellowish-white epidermal cysts containing keratin.

They can occur at any age, including in children.

Sebaceous hyperplasia

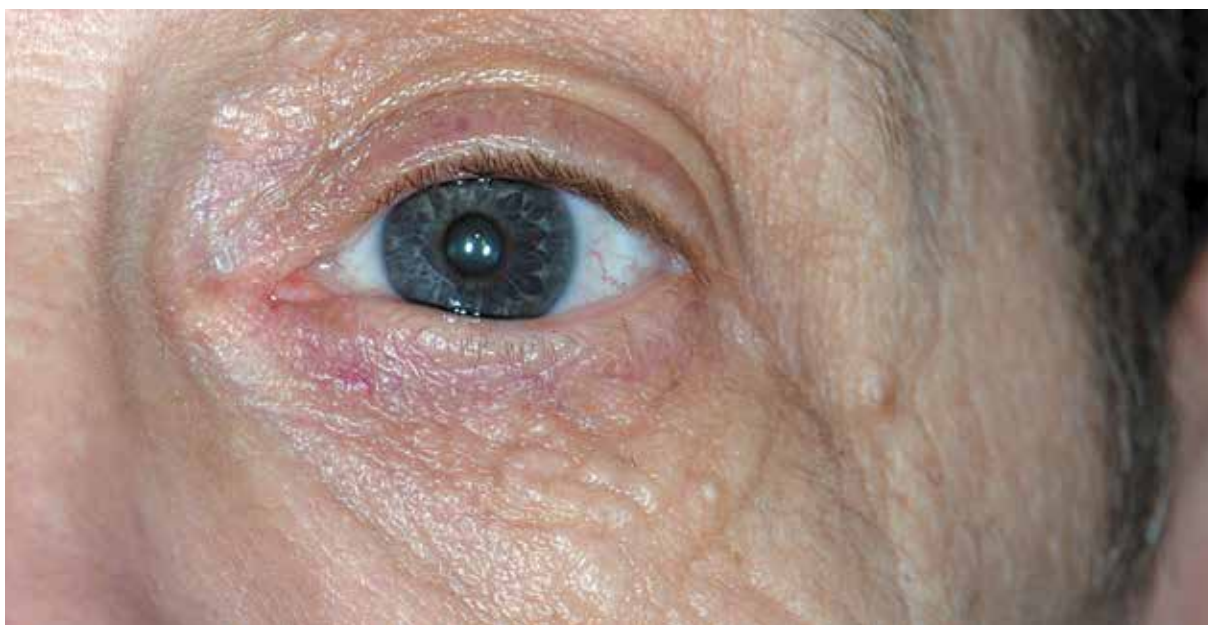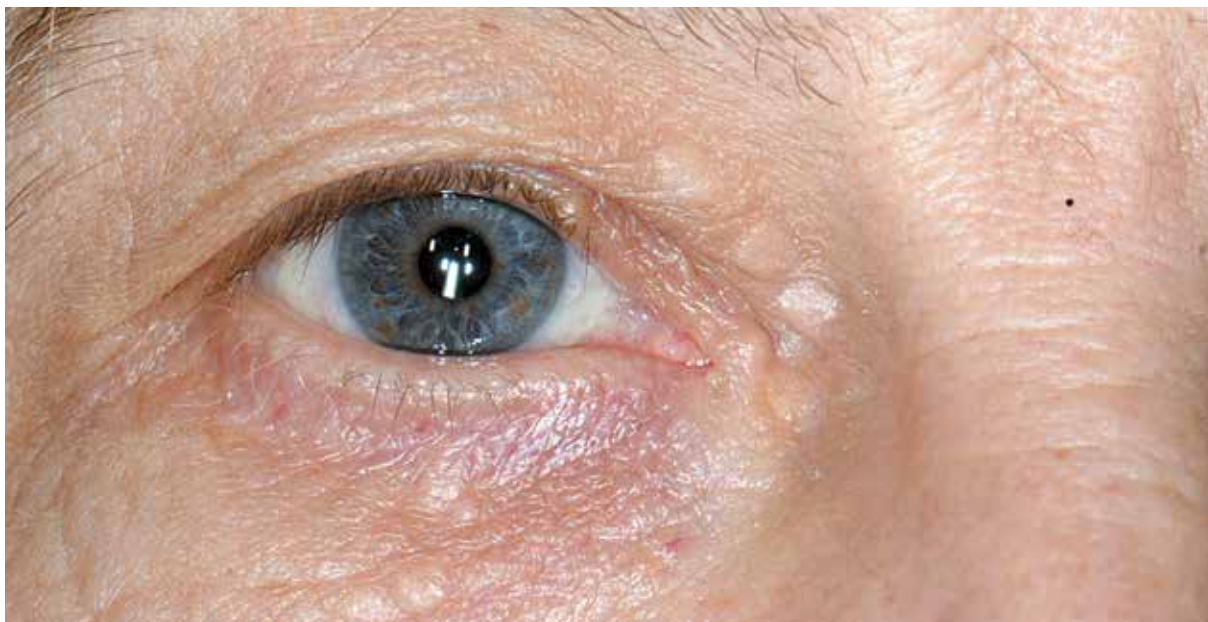


It can coincide with the Muir-Torre syndrome, sometimes associated with keratoacanthomas and basal cell carcinomas.

It requires diligent surveillance. In some cases, can be associated with the development of digestive carcinomas

Benign sebaceous tumors

Sebaceous hyperplasia



These are common lesions in the elderly, which can be confused with a basal cell carcinoma.

Umbilicated appearance sometimes covered with telangiectasia. Nevertheless, sebaceous hyperplasia is soft on palpation. These lesions can be destroyed by electrocoagulation.



Sebaceous carcinoma

It can occur within the glands of Zeiss, meibomian glands or the sebaceous skin glands and even sometimes in the caruncle.

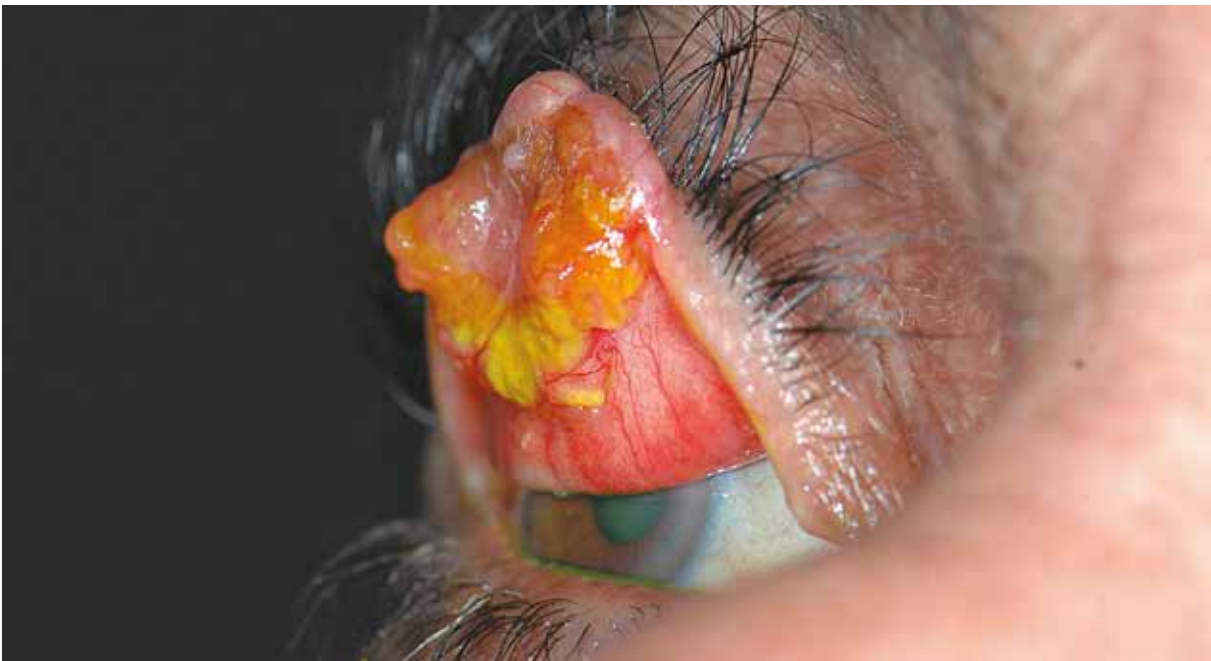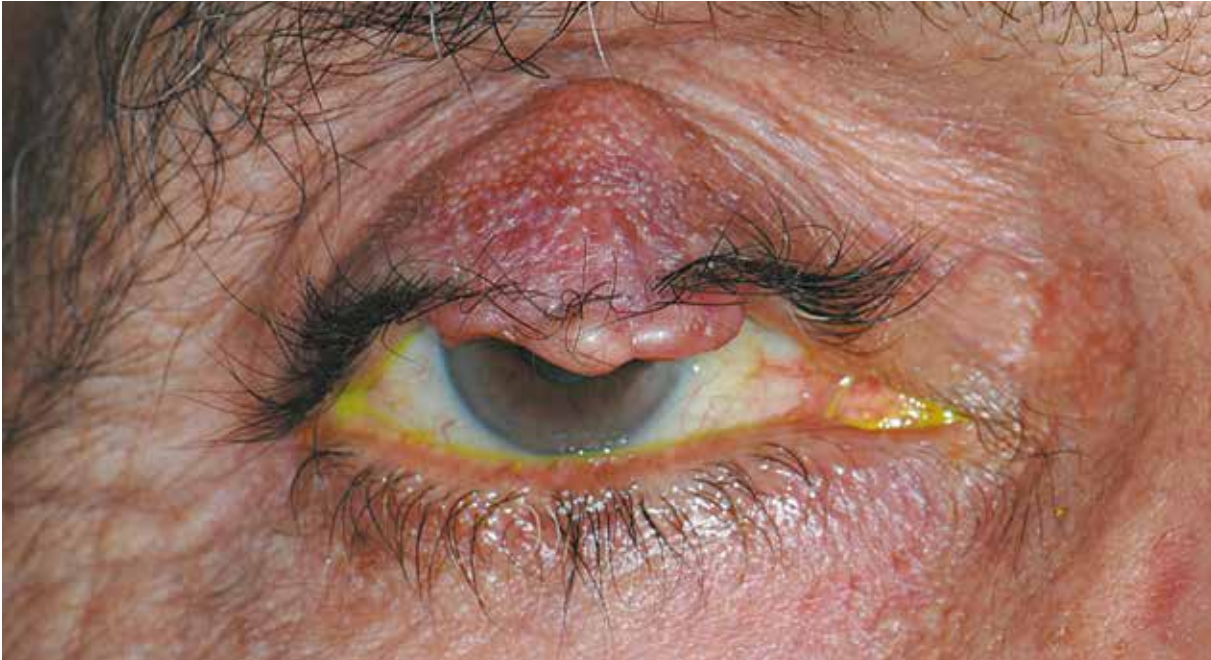It looks like a large, yellowish mass, which in a late stage modifies the tarsal and palpebral architecture.

The medical history often includes signs of recurrent incised chalazia.
A diagnostic biopsy must be performed for any recurrent sebaceous-like lesion.

The histological appearance is that of a mass grouping cells of «sebaceous» morphology, in balls, ovoid, containing lipid vacuoles.

This lesion can spread to the eye with invasion of the lymph nodes. Metastasis is common due to delays in the diagnosis.

Sebaceous carcinoma

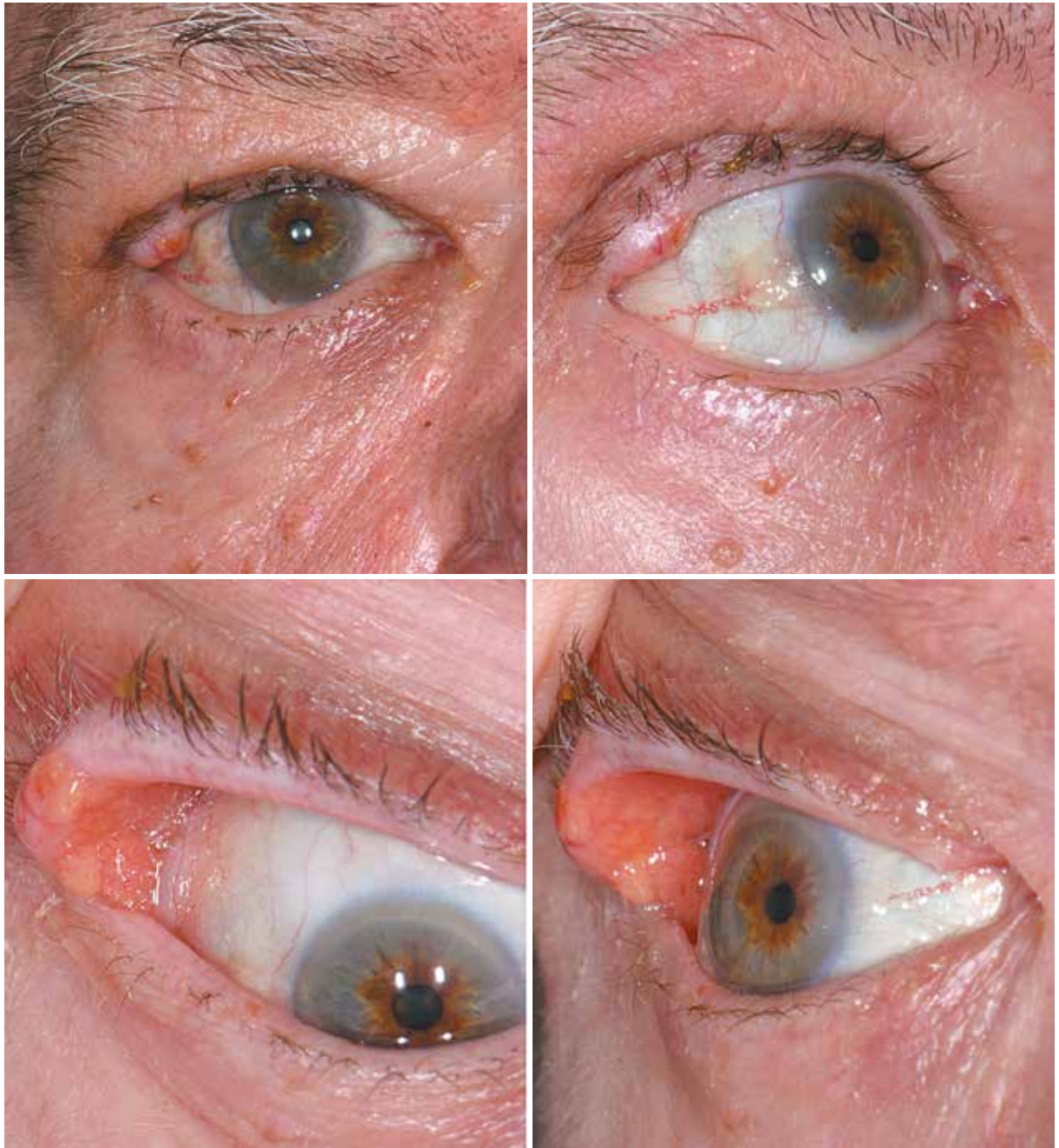

Infiltrating mass on the free margin of the upper eyelid with modification of the palpebral architecture and loss of lashes around the lesion.

When the eyelid is everted, characteristic clusters of sebaceous cells containing fat can be observed.

Malignant sebaceous tumors

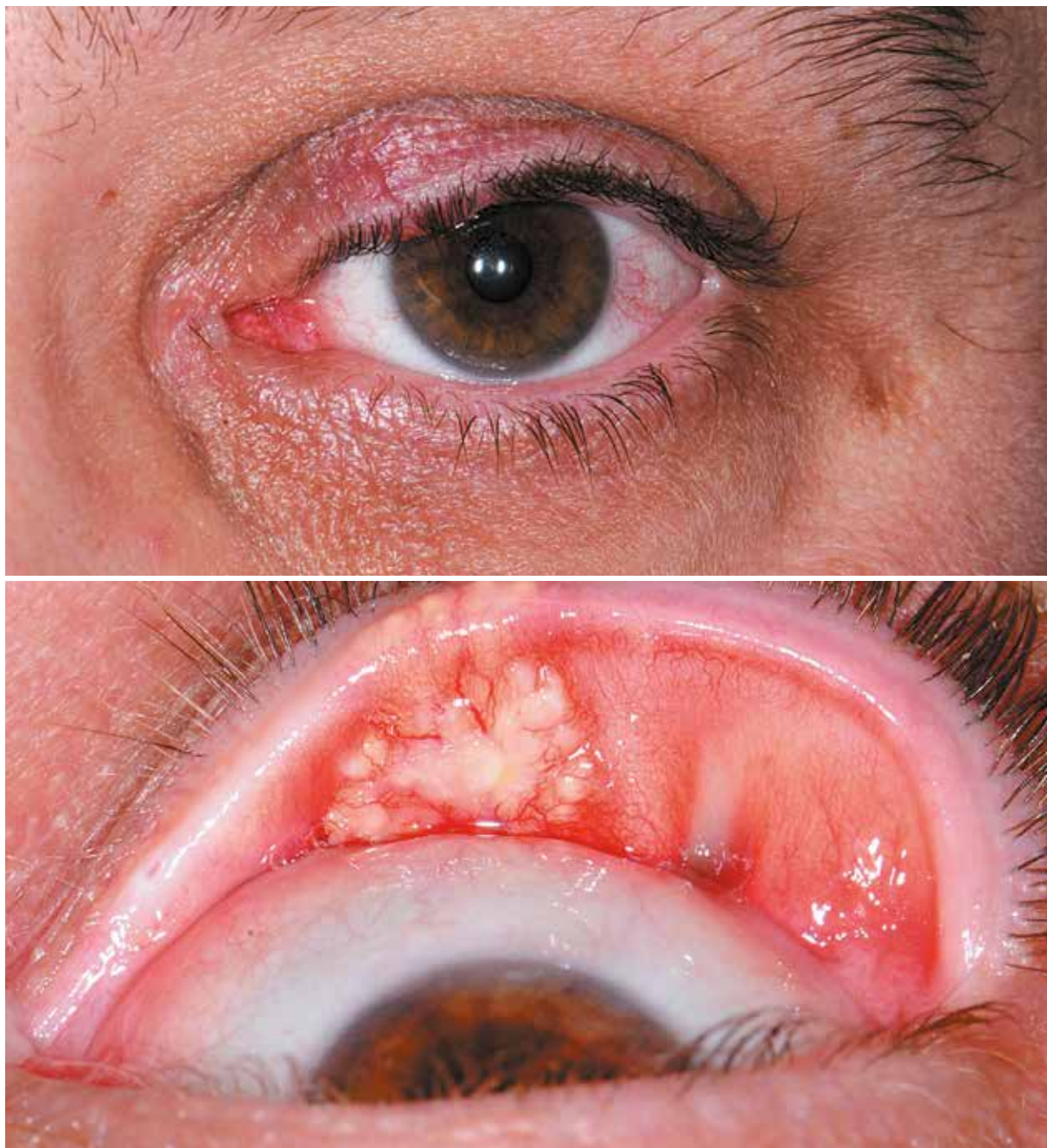Sebaceous carcinoma



More discreet lesion. Known history of chalazia.

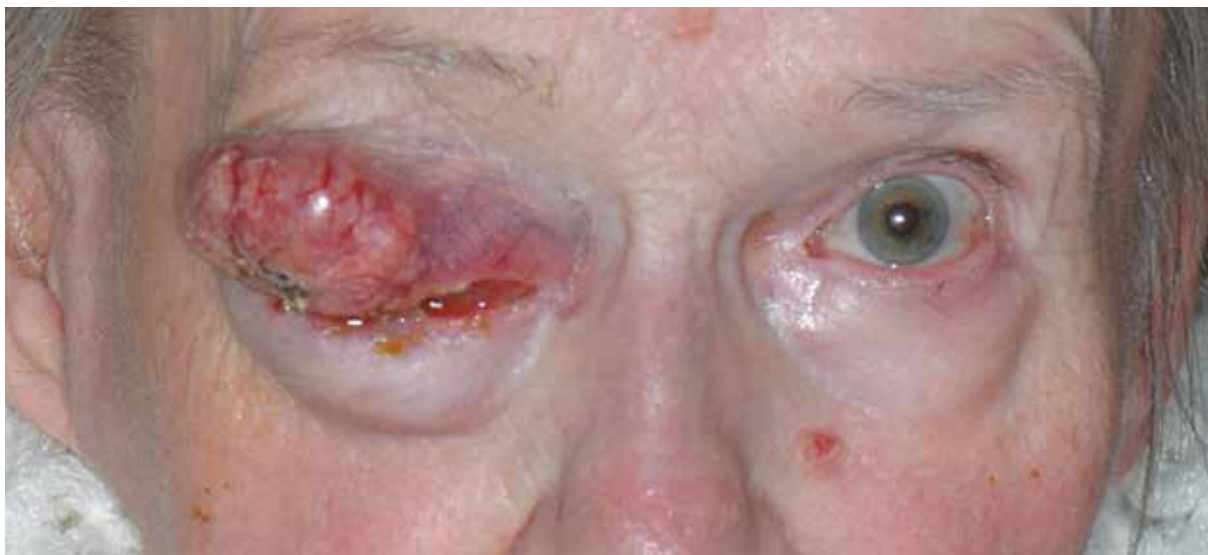There is a change in the tarsal architecture and characteristic clusters of decaying sebaceous cells can be observed when the upper eyelid is everted.

Sebaceous carcinoma



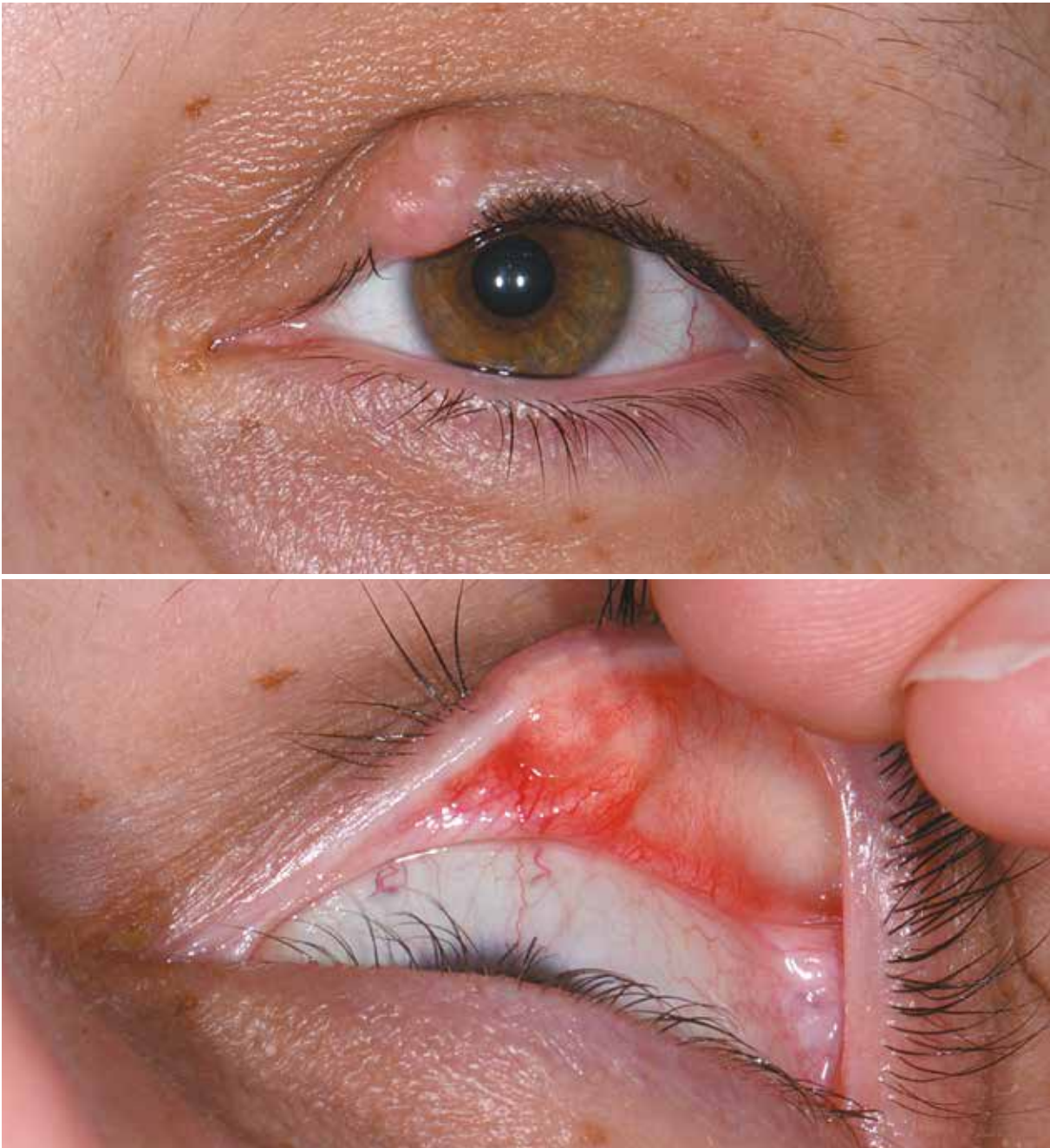Apparent infiltration away from the free margin, in a young patient. Proliferation of lipid-containing malignant cells when the eyelid is everted.

Sebaceous carcinoma



Advanced stage of sebaceous carcinoma. Late progression with infiltration of the entire upper eyelid.

Nodular adnexal tumor



Lesion of the free margin of the eyelid. Swelling encompassing the free margin and loss of lashes can be observed.

When the upper left eyelid is everted, a suspicious modification of the tarsal structure can be observed.

3. Adnexal tumors

Tumors of the hair follicle

The skin adnexa — hairs, sebaceous glands, and sweat glands — are located chiefly in the dermis and the hypodermis.

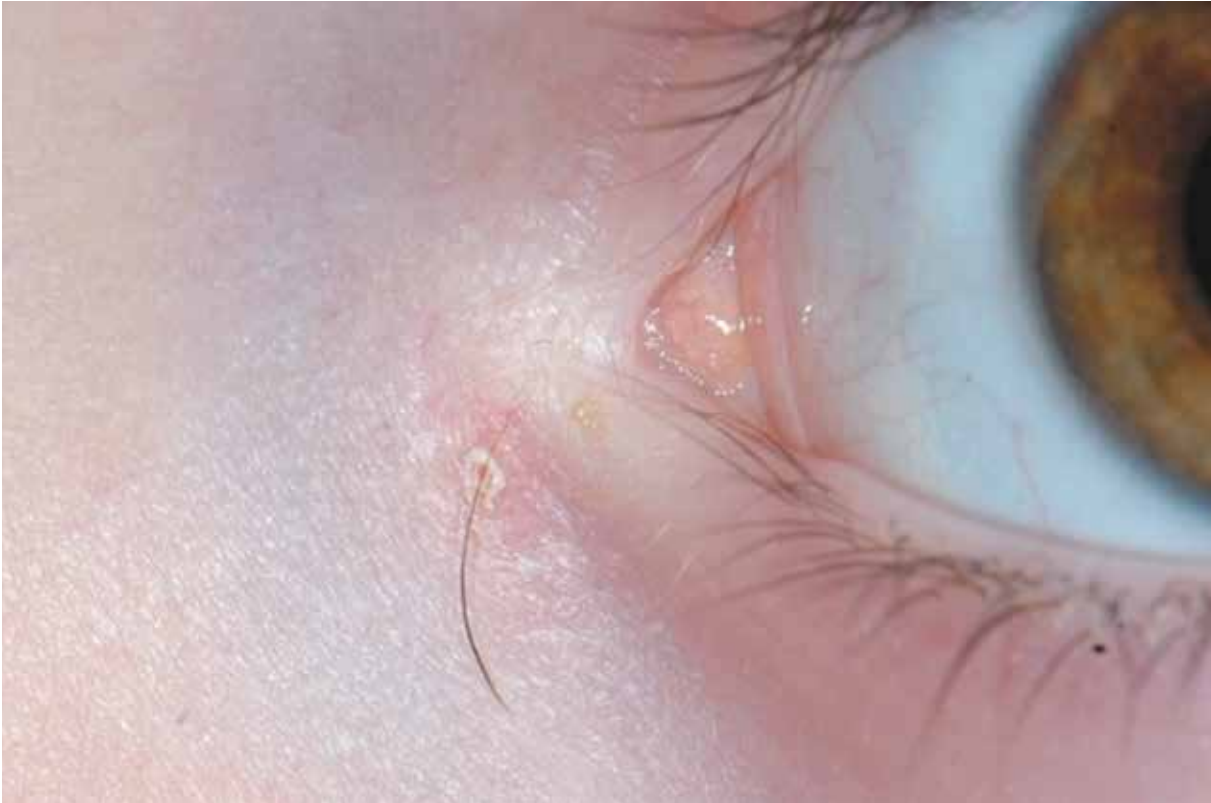The hair follicle, which contributes to thermoregulation, comprises three segments:

- the bulb deep within the dermis,
- the isthmus where the junction with the sebaceous gland is situated,
- the infundibulum segment which extends to the follicle orifice at the surface.

There are two types of sweat glands:

- Eccrine sweat glands on the surface of the skin. These are exocrine glands of which there are two types, a light superficial one and a darker deeper one.
- The structure of the apocrine sweat glands is similar to that of the eccrine glands. The difference is in their distribution, their characteristics, and their morphology (the excretory duct does not terminate directly at the surface of the epidermis but in a sebaceous hair follicle).

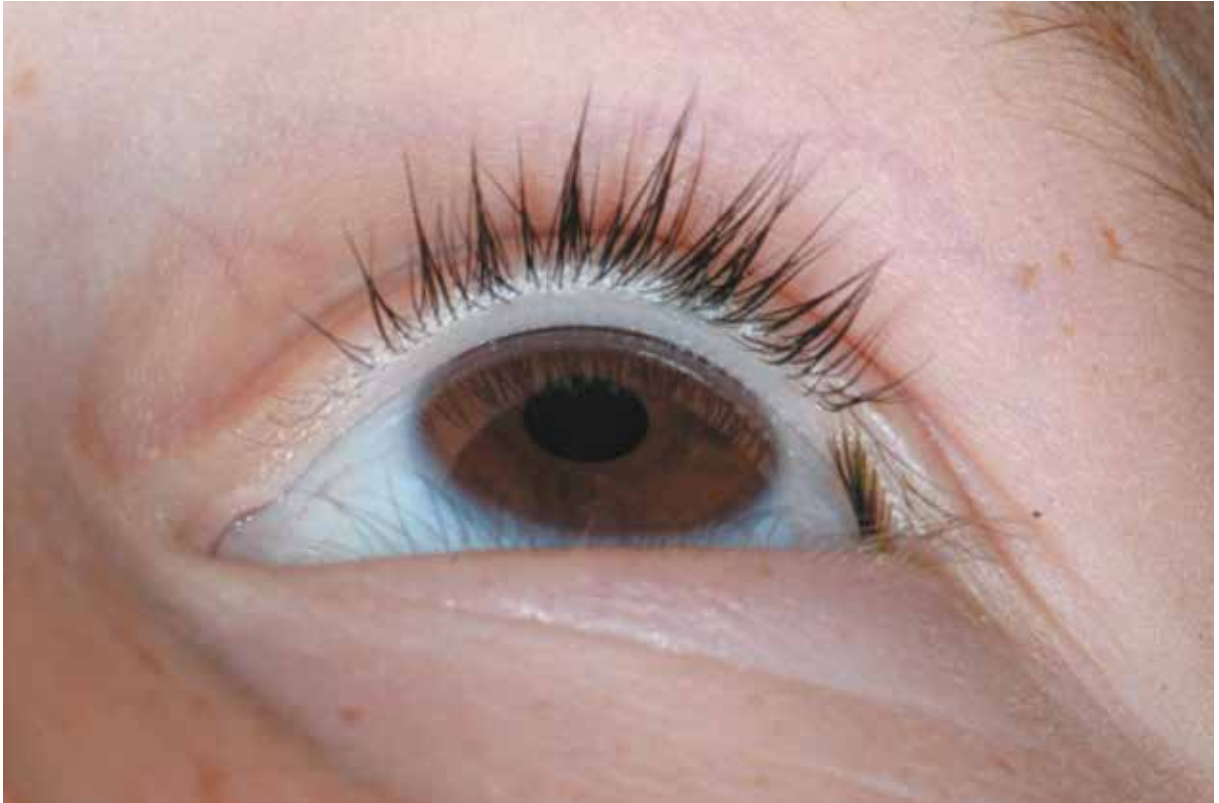Trichofolliculoma



It occurs most often on the face and presents as a skin nodule with a central point where the hair follicle emerges.

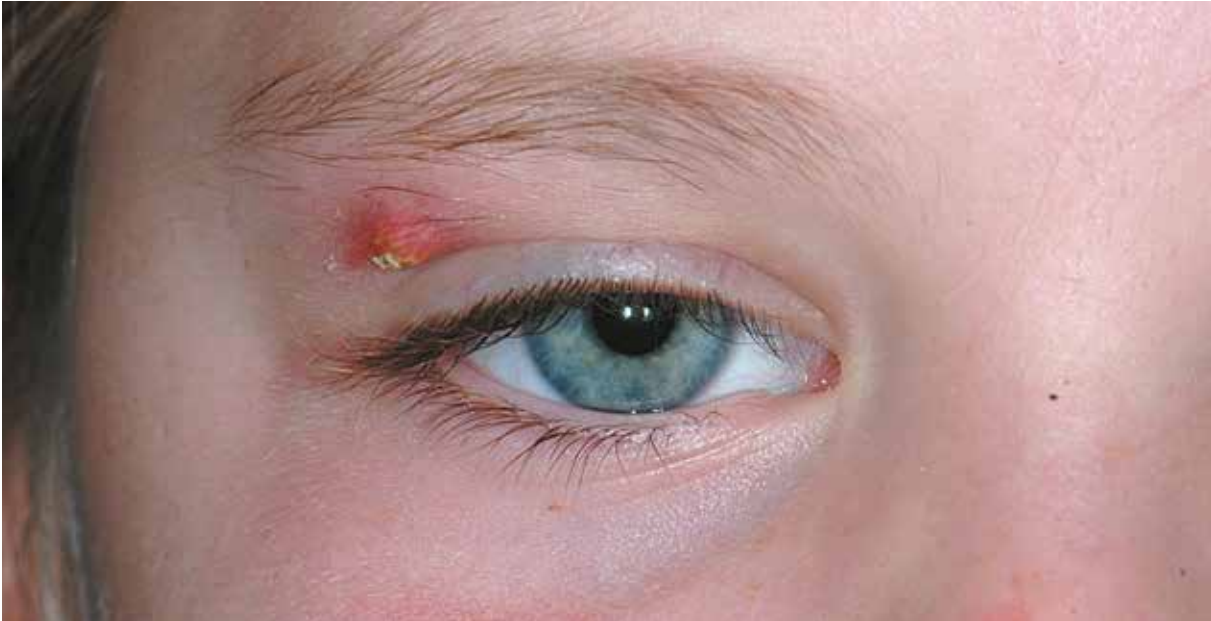In this photograph, the trichofolliculoma is located in the inner canthus, just above the tear ducts.

Trichofolliculoma



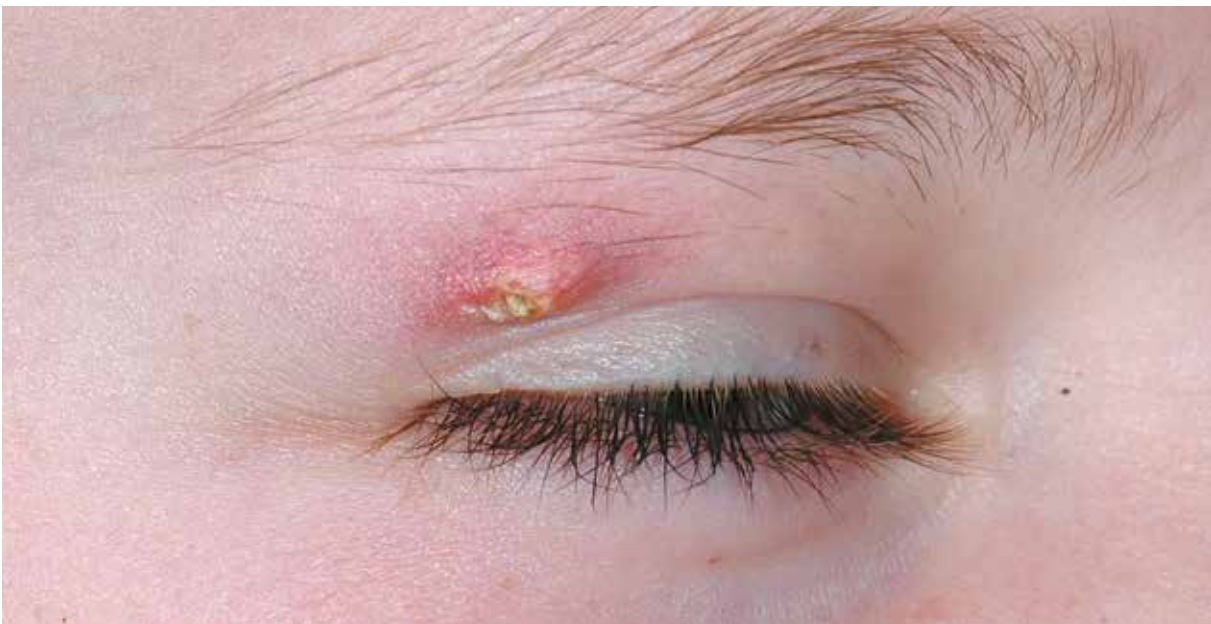Trichofolliculoma on the left palpebral free margin with numerous ectopic hairs.

Pilomatrixoma



Pilomatrixoma or calcifying epithelioma of Malherbe is predominant on the face, neck, and upper limbs of young subjects.

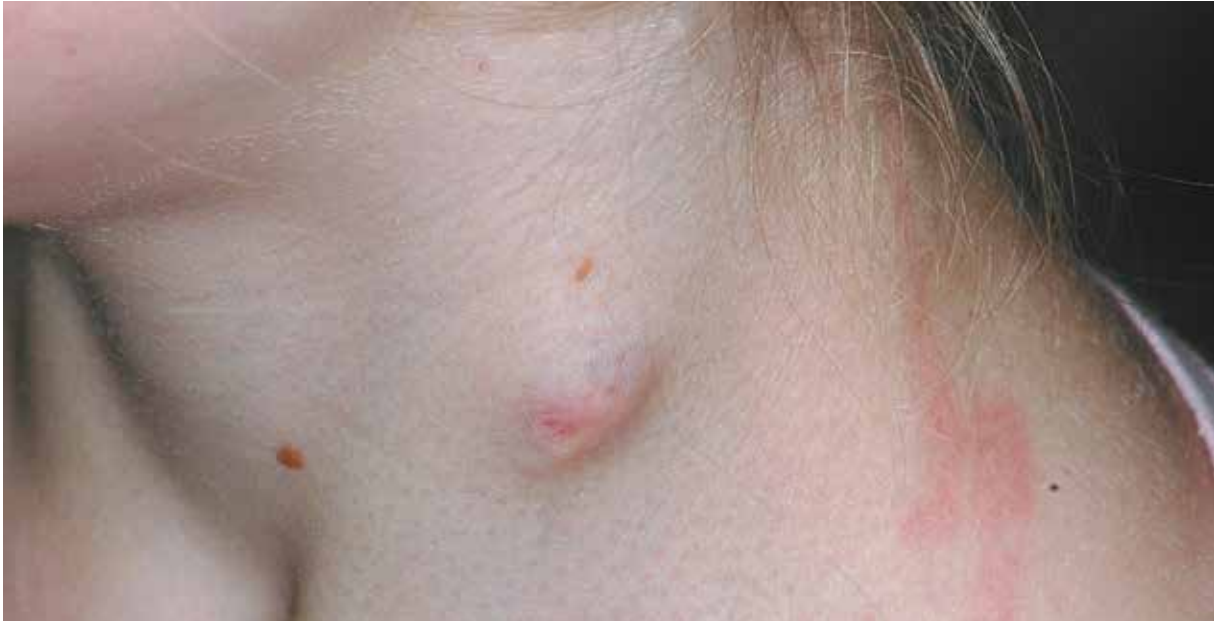This pink to bluish nodule is hard on palpation and can ulcerate and become painful.



Pilomatrixoma with ulceration.

It is pink around the edges and yellowish in the center where there is ulceration.

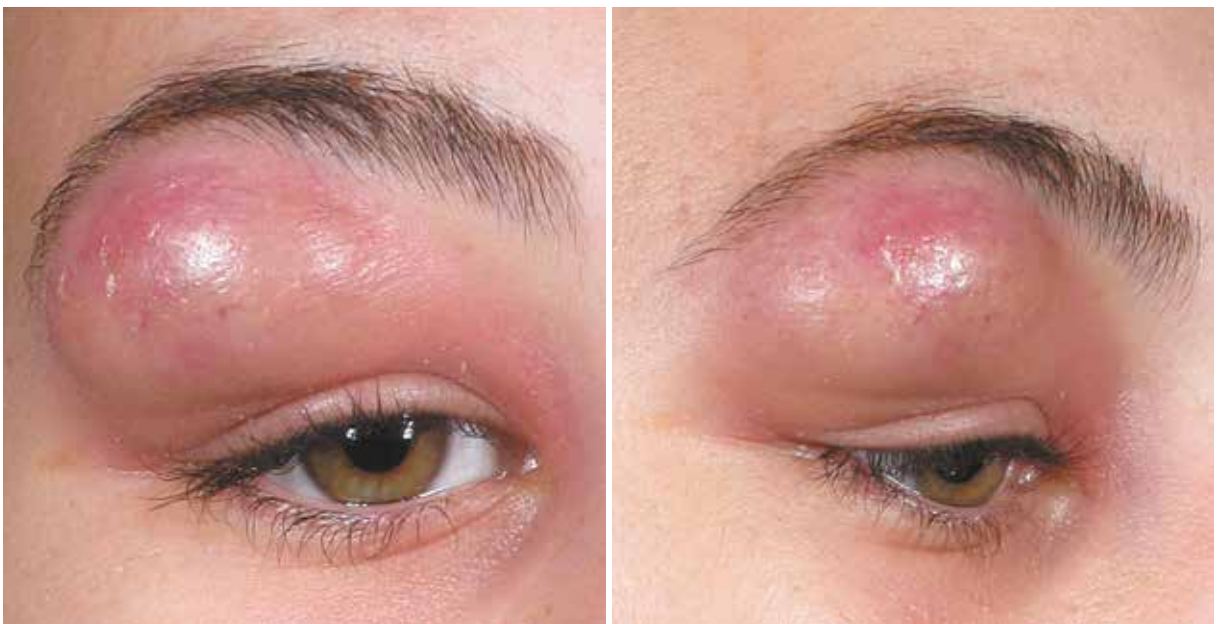Pilomatrixoma



Synchronous cervical pilomatrixoma.

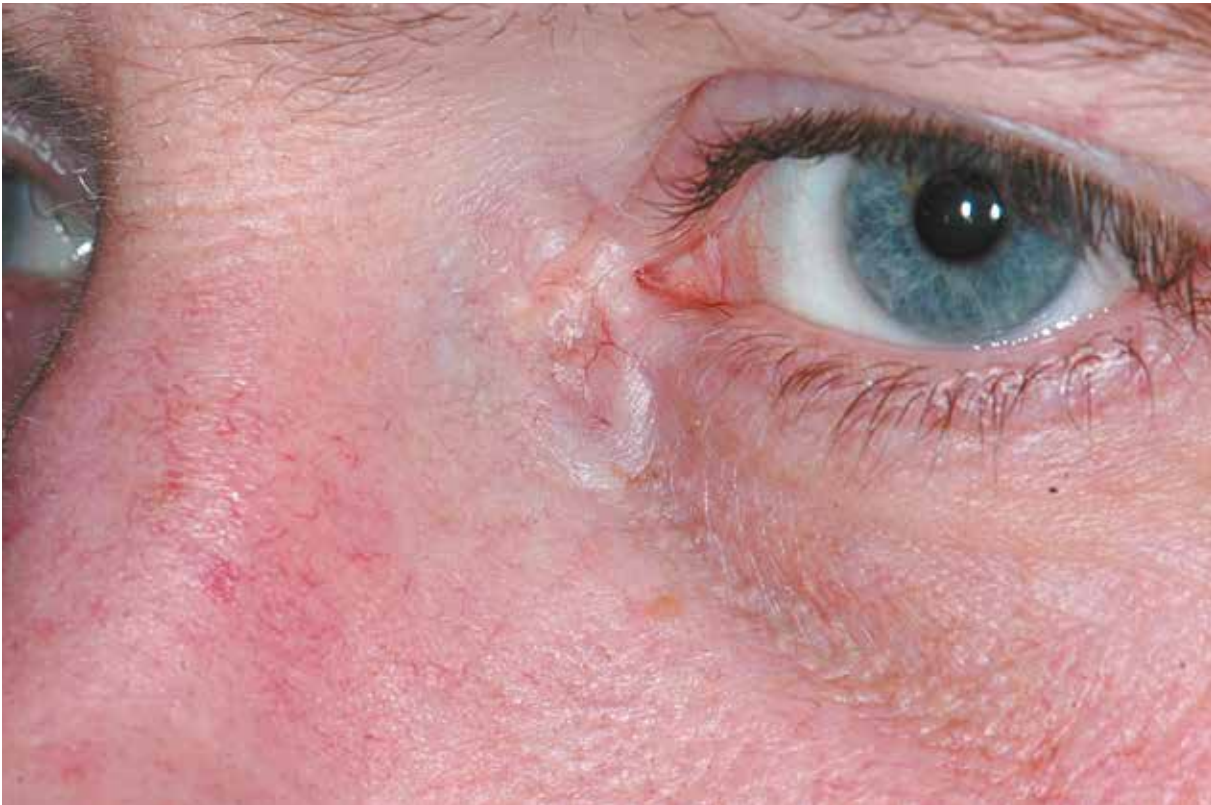Presence of a cervical pilomatrixoma in this same patient. The treatment consists in surgical excision followed by a histopathological examination.

The prognosis is good but some cases of malignant transformation have been reported.



Large advanced pilomatrixoma on the upper right eyelid, heterogeneous on the surface and very hard on palpation.

Trichoblastoma

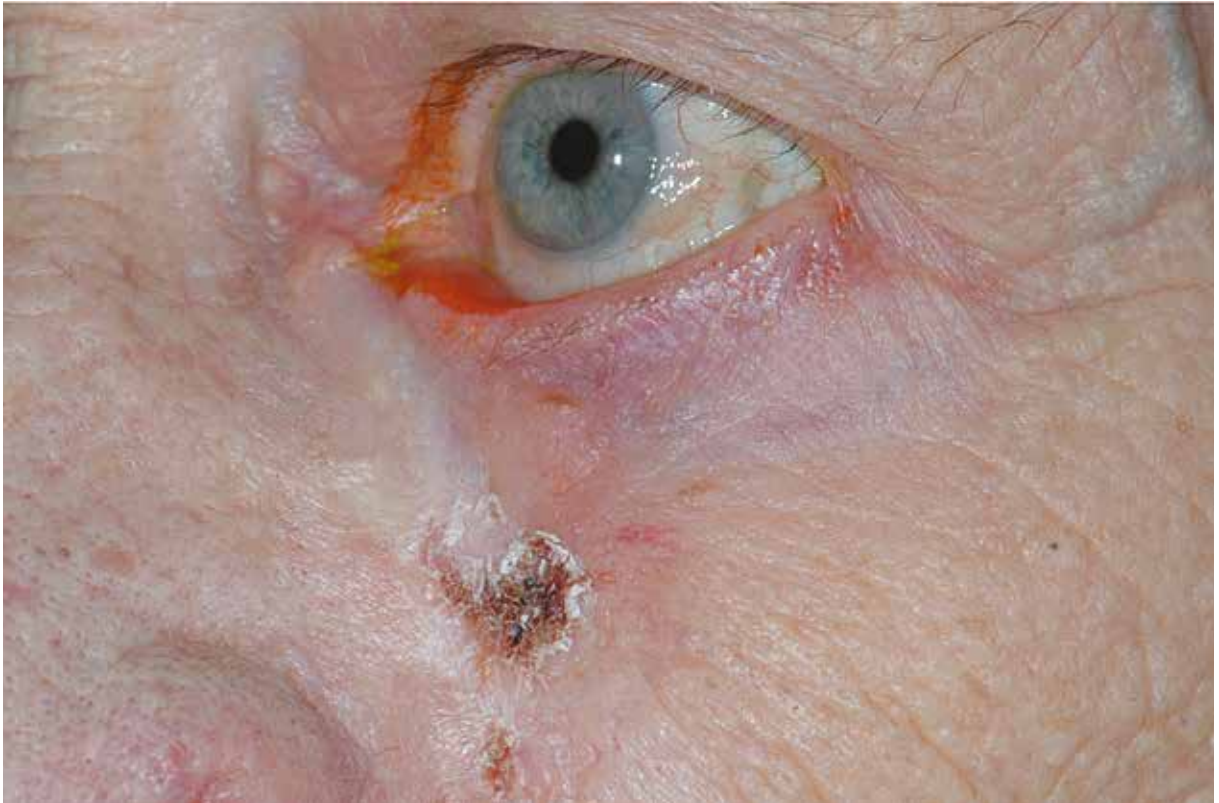

Trichoblastoma is a benign flesh-colored tumor, which occurs more often on the face. It is a telangiectatic beaded nodule.

From the clinical examination, the differential diagnosis with a basal cell carcinoma is very hard.

Surgical excision with histological analysis is recommended.

Desmoplastic trichoepithelioma

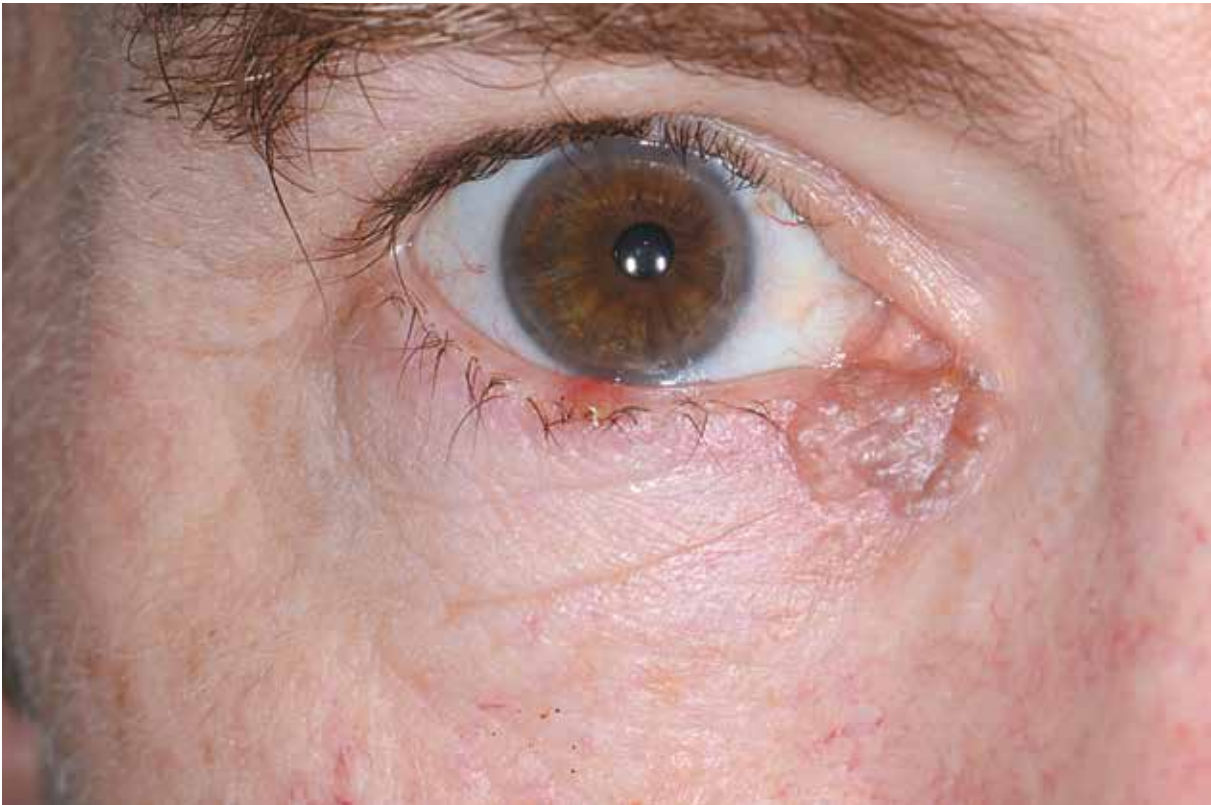

Desmoplastic trichoepithelioma is a tumor of the hair follicle; the differential diagnosis with a sclerodermiform basal cell carcinoma is very difficult.

It is found predominantly on the cheeks. On palpation, it is a firm plaque with a central indentation of varying color. In this case, hyperkeratosis of the lesion is observed.

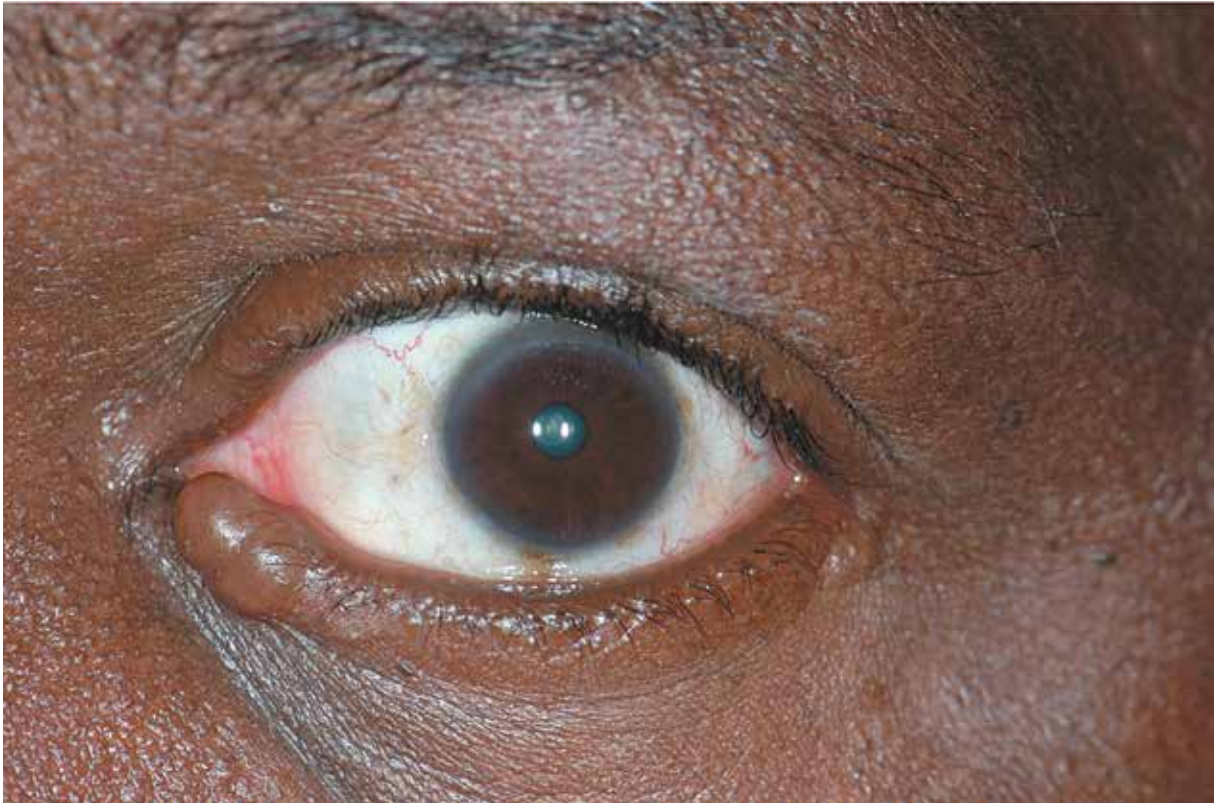Trichoepithelioma is a benign tumor occurring predominantly on the face, more often in adulthood.

Trichoepithelioma



Benign tumor in the hair adnexa, papules gradually increasing in number, isolated, in clusters, sometimes confluent which might indicate a basal cell carcinoma.

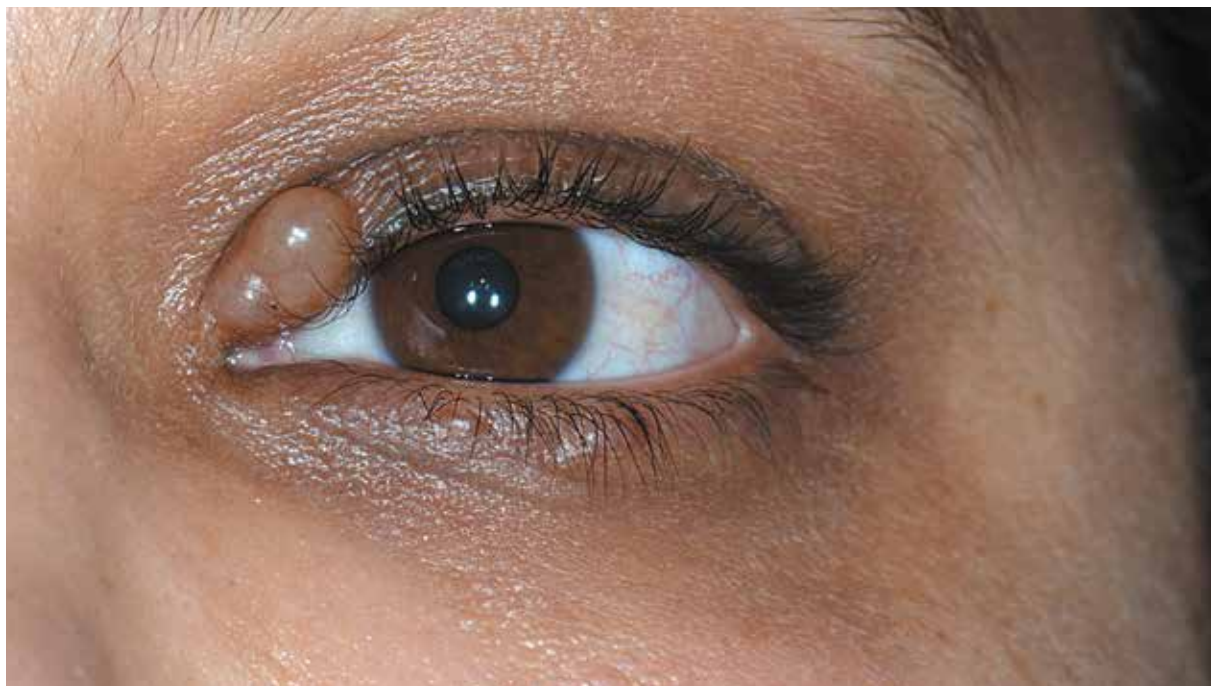Eccrine hidrocystoma



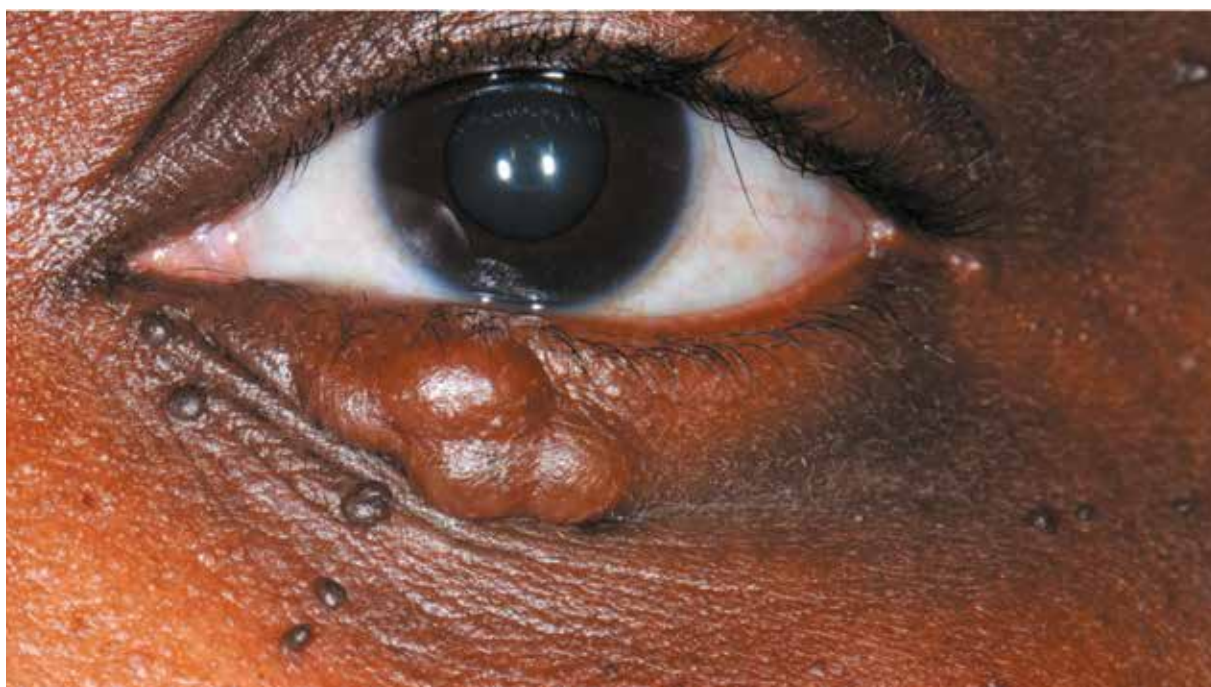Hidrocystomas of the outer canthus and two nodules on the the medial side of the lower eyelid.

Hidrocystomas are benign skin tumors of the sweat glands, predominantly palpebral. They are small retention cysts measuring a few millimeters to 1 or 2 centimeters occurring in normal eccrine glands.

Eccrine hidrocystoma

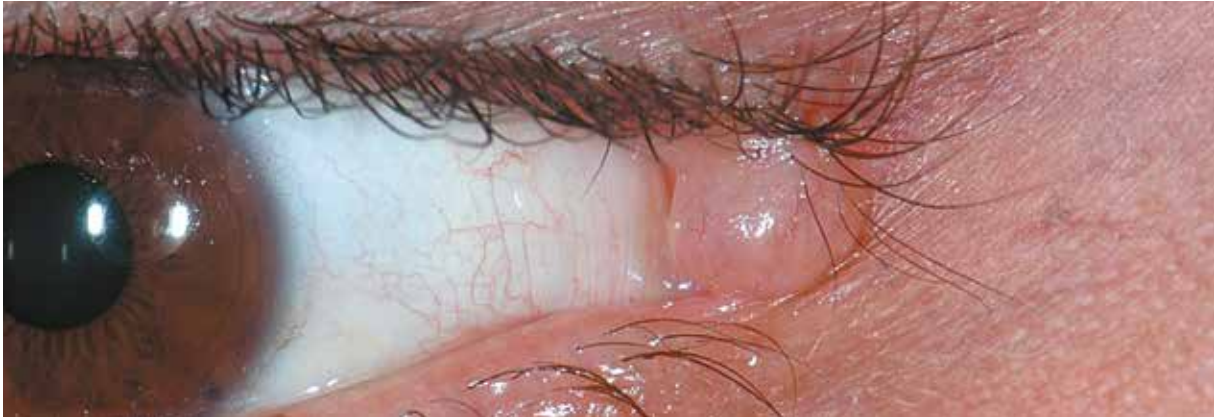

Hidrocystoma on the medial side of the upper eyelid.

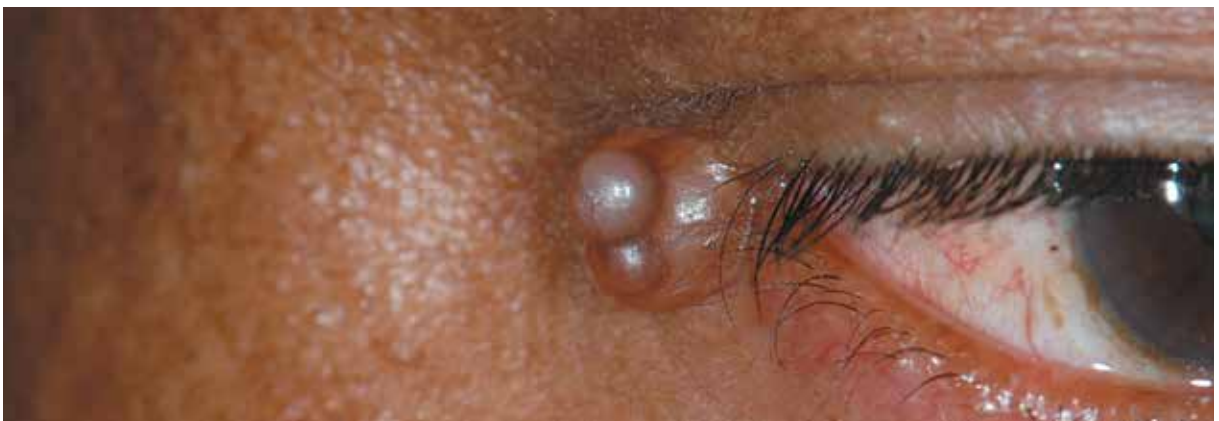

Hidrocystomas in the center of the lower eyelid, in a bunch.

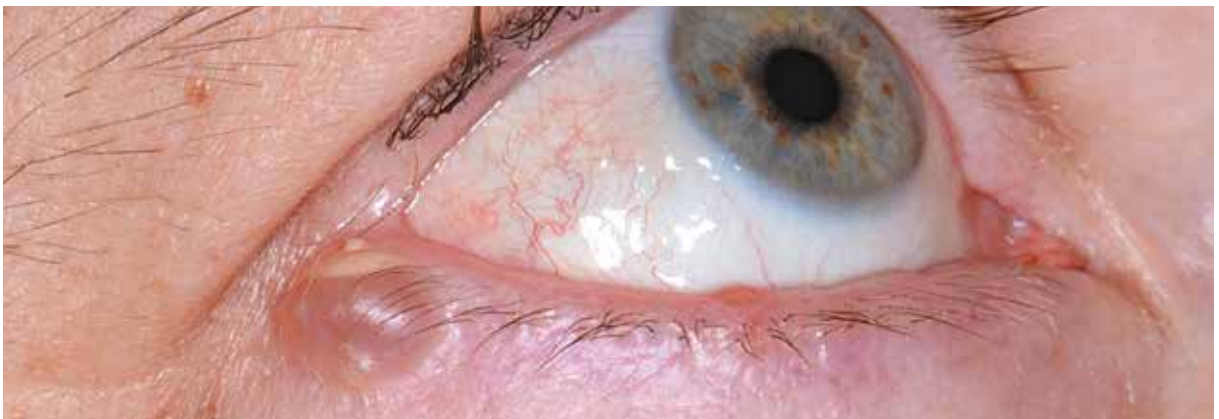
Eccrine hidrocystoma



Hidrocystoma on the outer canthus.

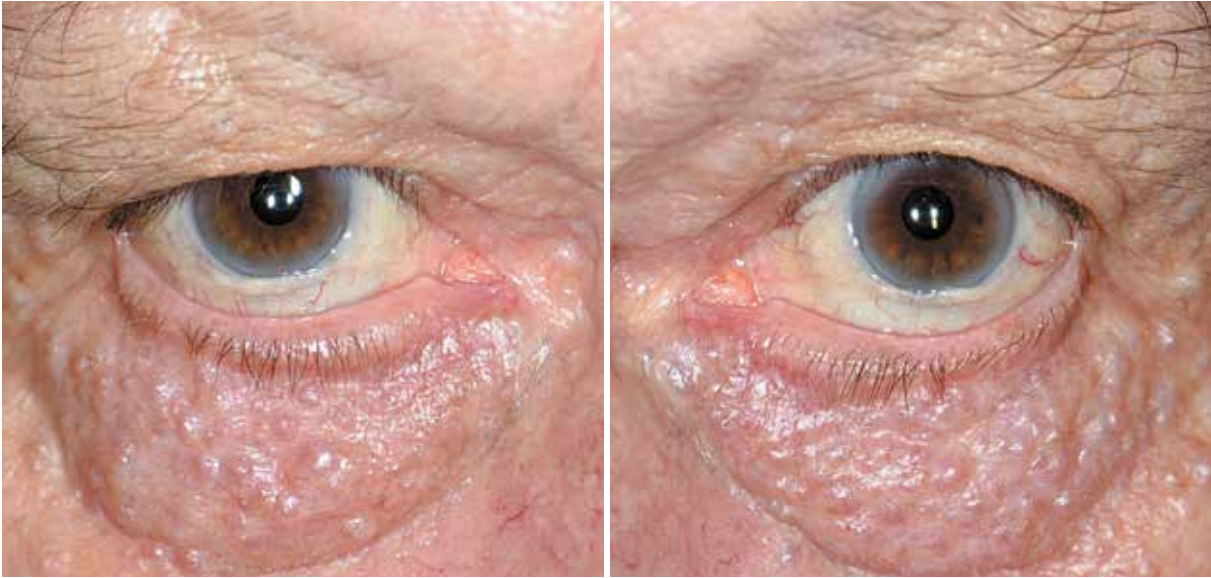


Hidrocystoma on the outer canthus in a bunch with lesions of varying size.



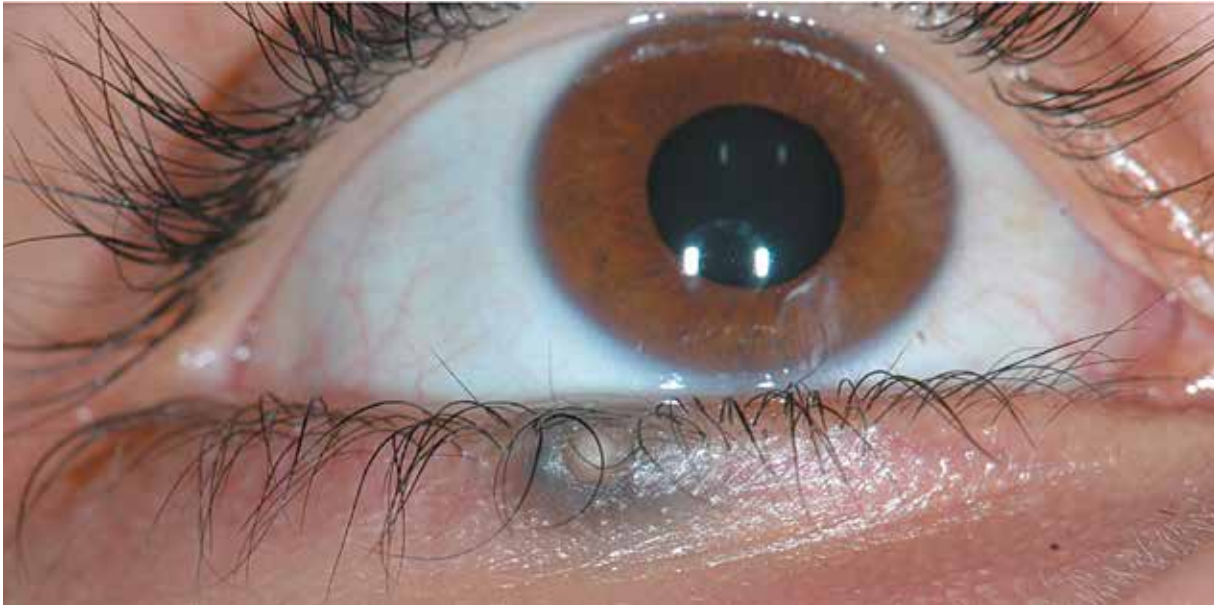
Hidrocystoma on the outer canthus containing heterogeneous translucent substance, clearly visible upon transillumination.

Eccrine hidrocystoma



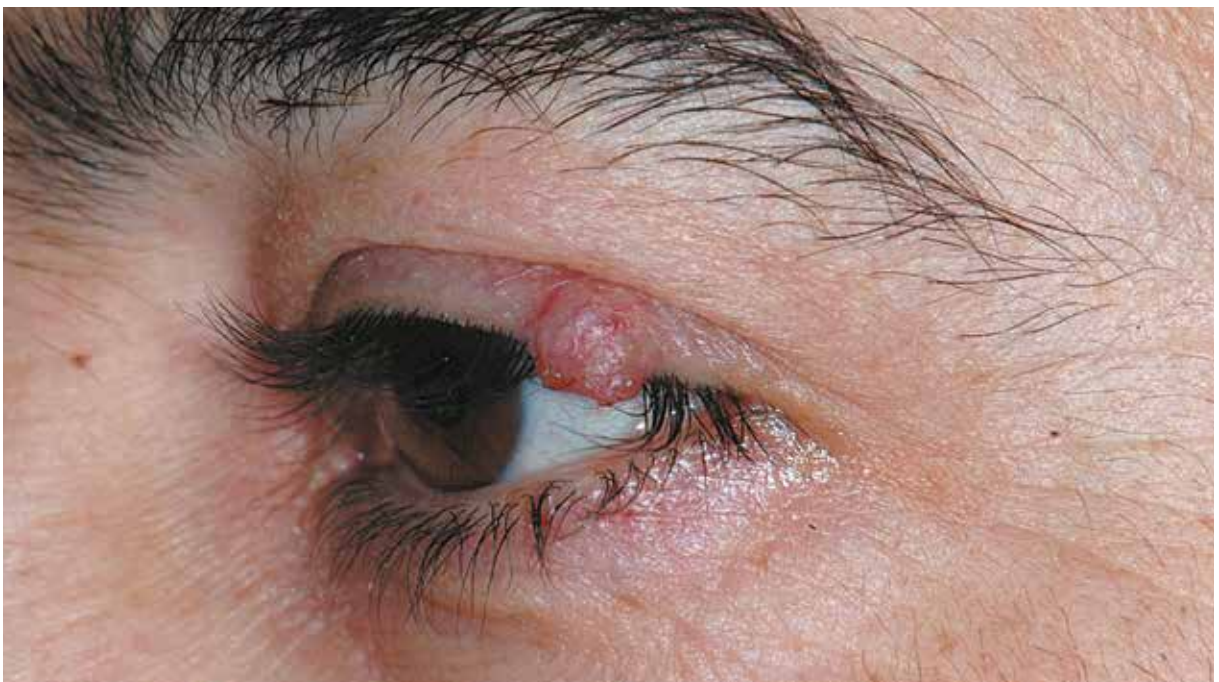Presence of multiple hidrocystomas on both eyelids.
Lesions soft and spongy on palpation.

Apocrine cystadenoma



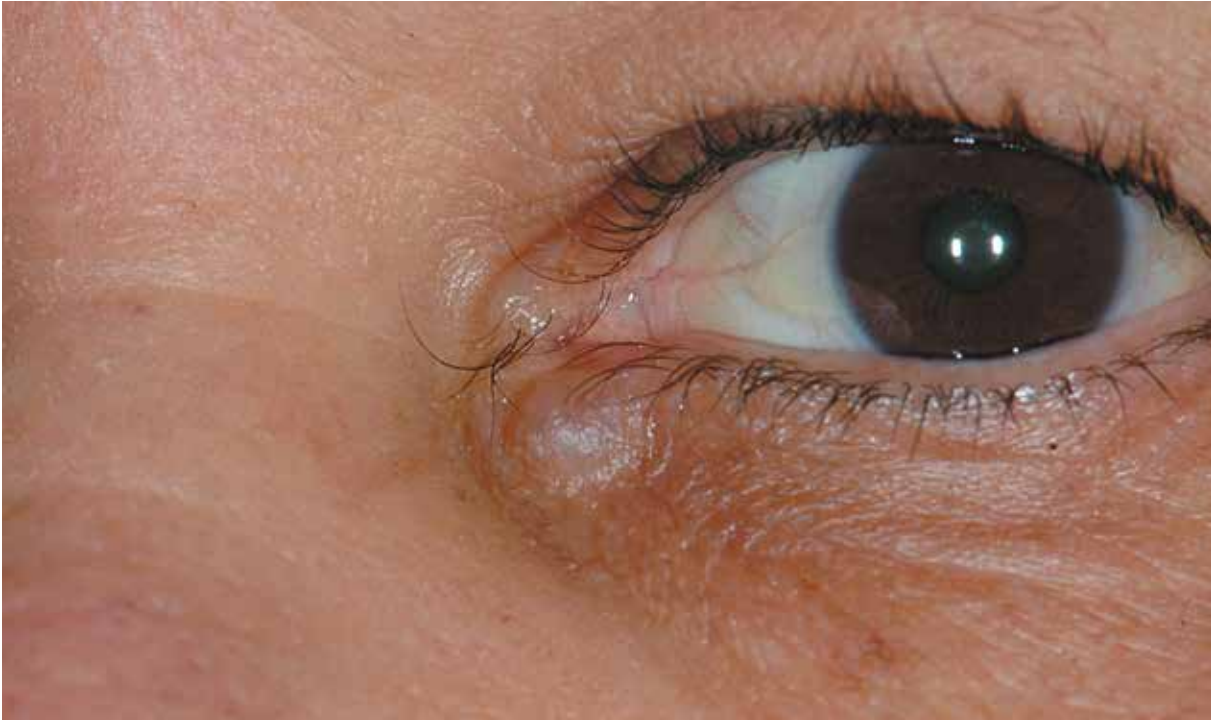Apocrine Cystadenoma of the lower eyelid with bluish deep underlying section.

Apocrine cystadenoma are located in the sweat glands. The eosinophilic content of these benign lesions can result in a bluish appearance.

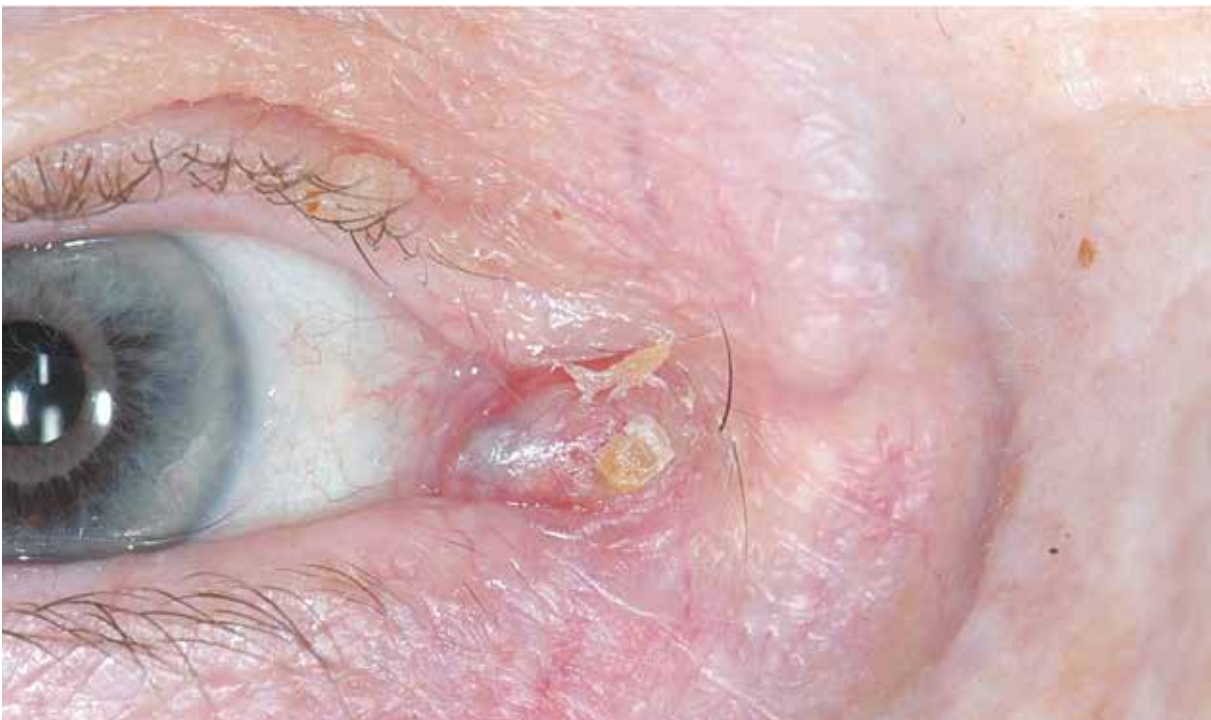

Apocrine cystadenoma with mainly proliferation of myoepithelial cells.

Apocrine cystadenoma

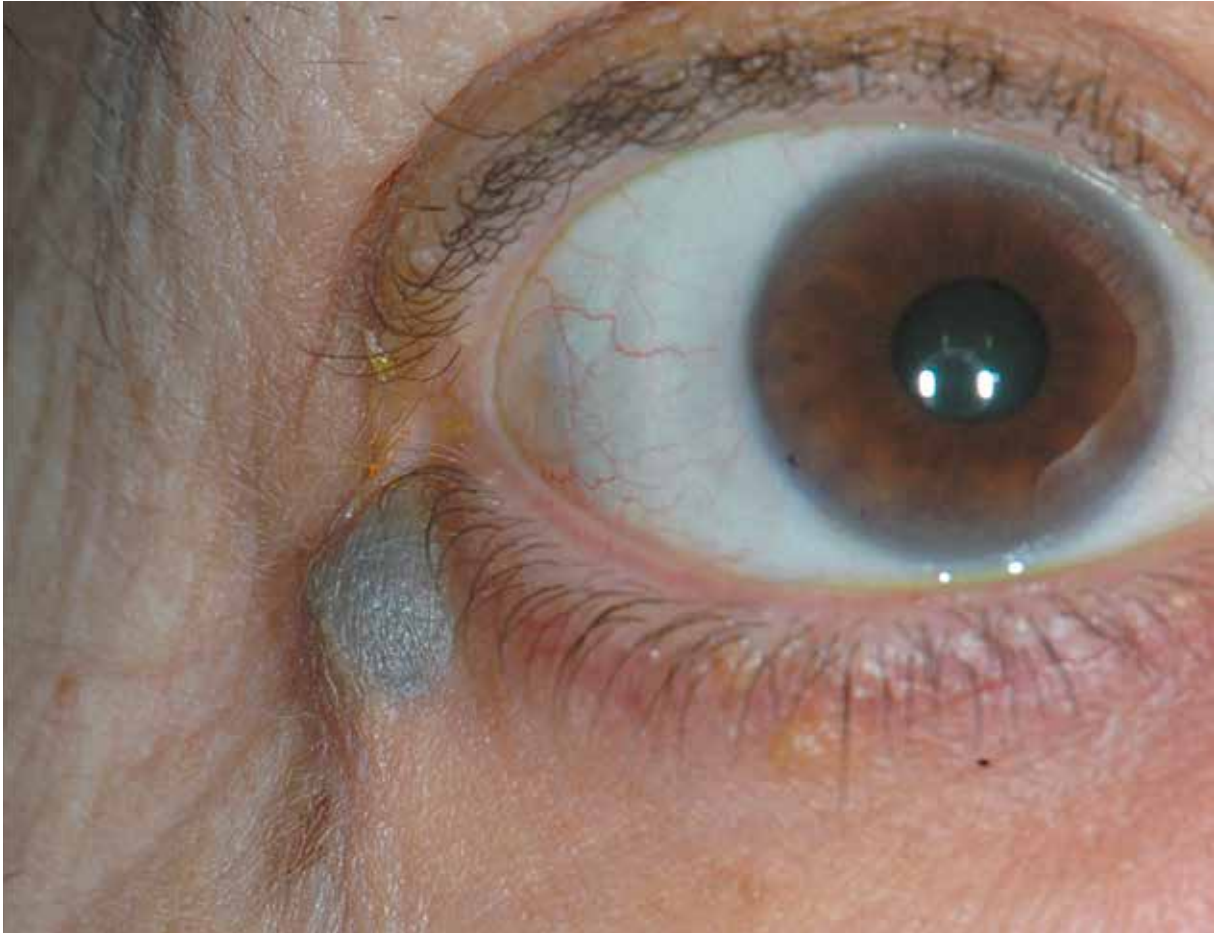


Apocrine cystadenoma on the medial side of the upper and lower eyelids.

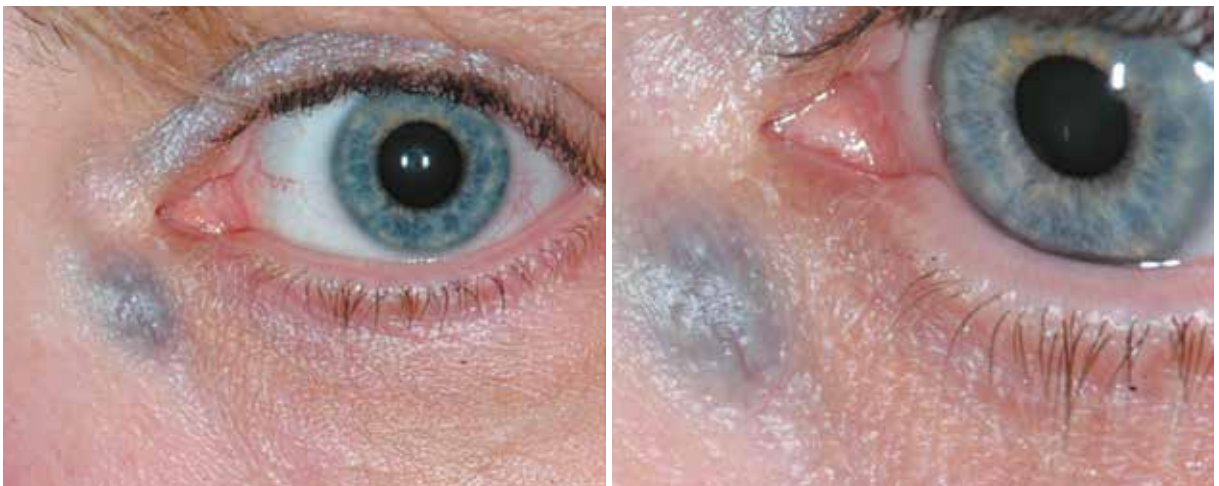


Apocrine cystadenoma on the caruncle.

Apocrine cystadenoma

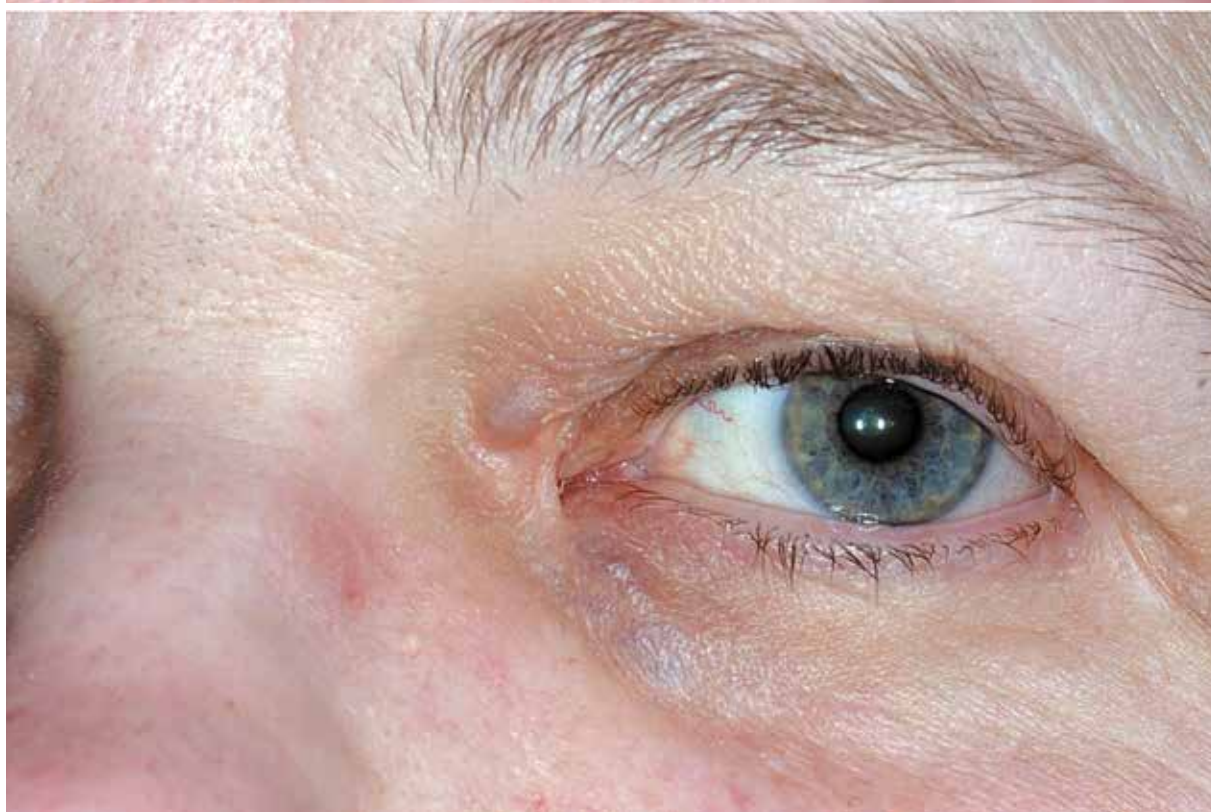
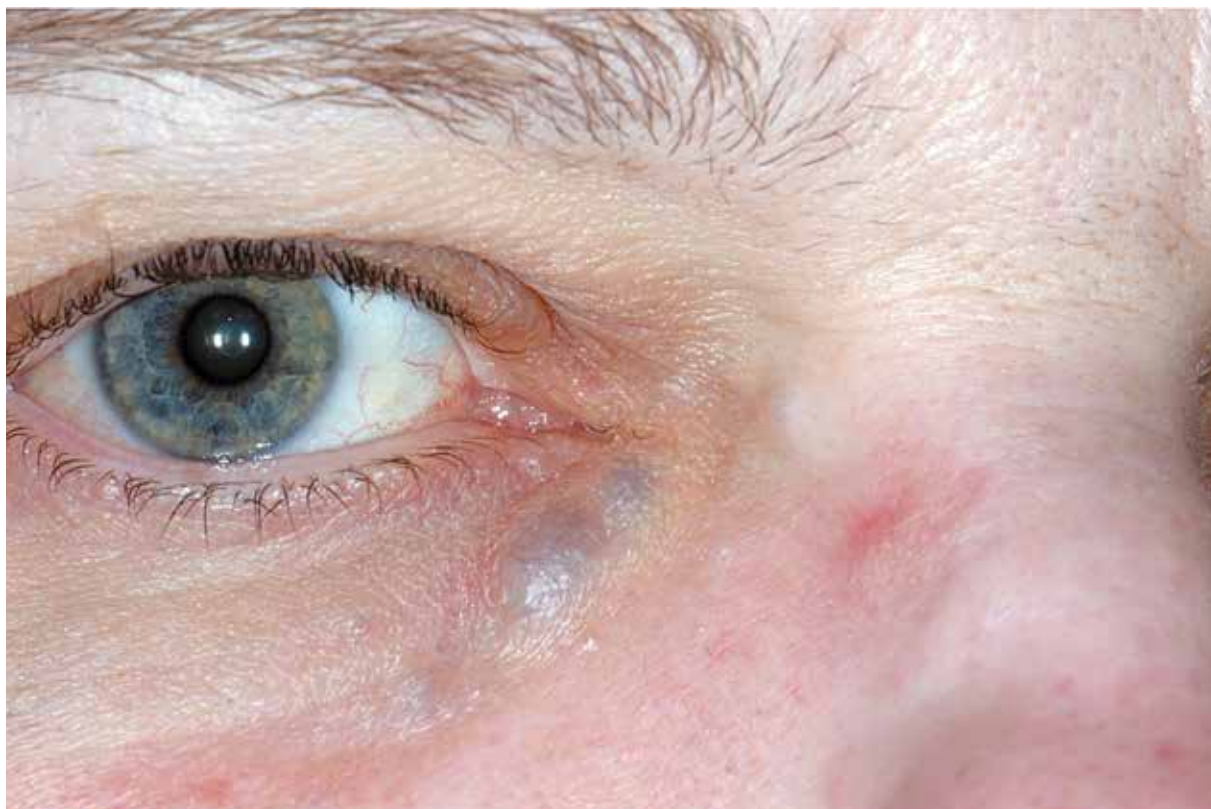
Apocrine cystadenoma on the outer canthus.

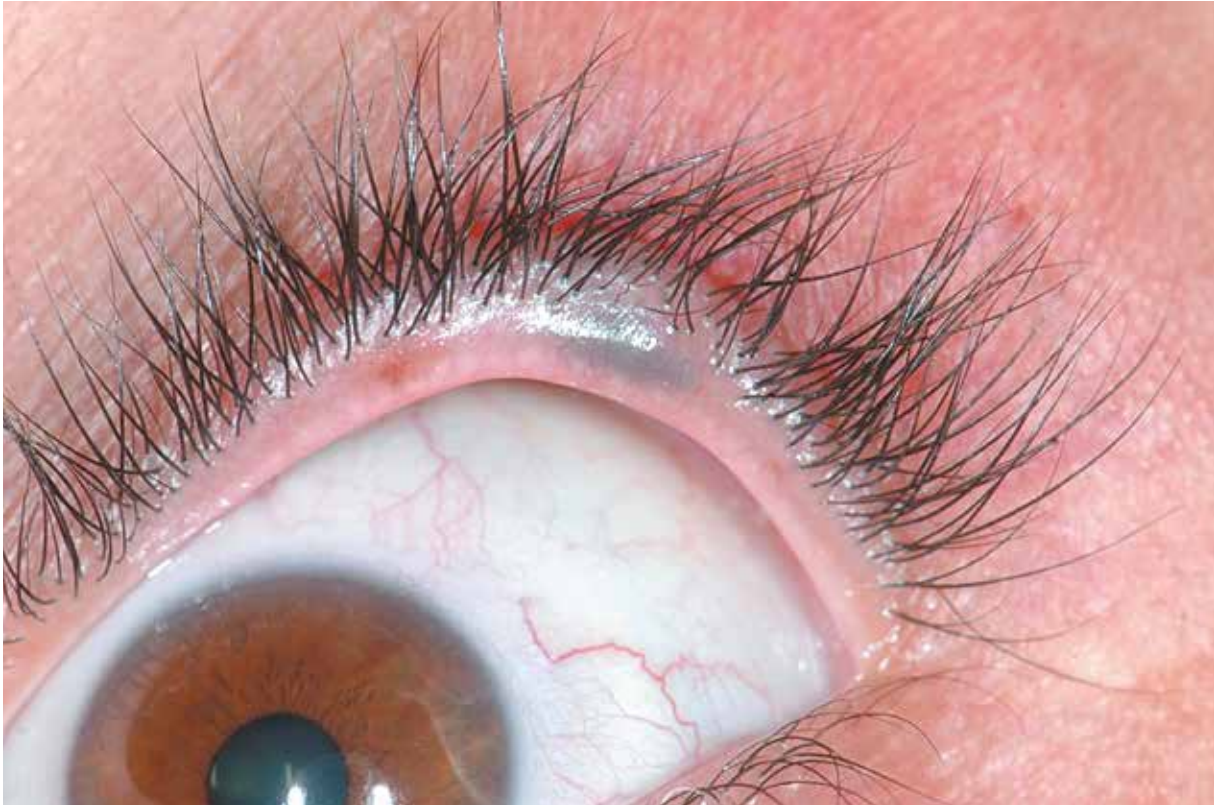

Apocrine cystadenoma on the inner canthus.

Apocrine cystadenoma



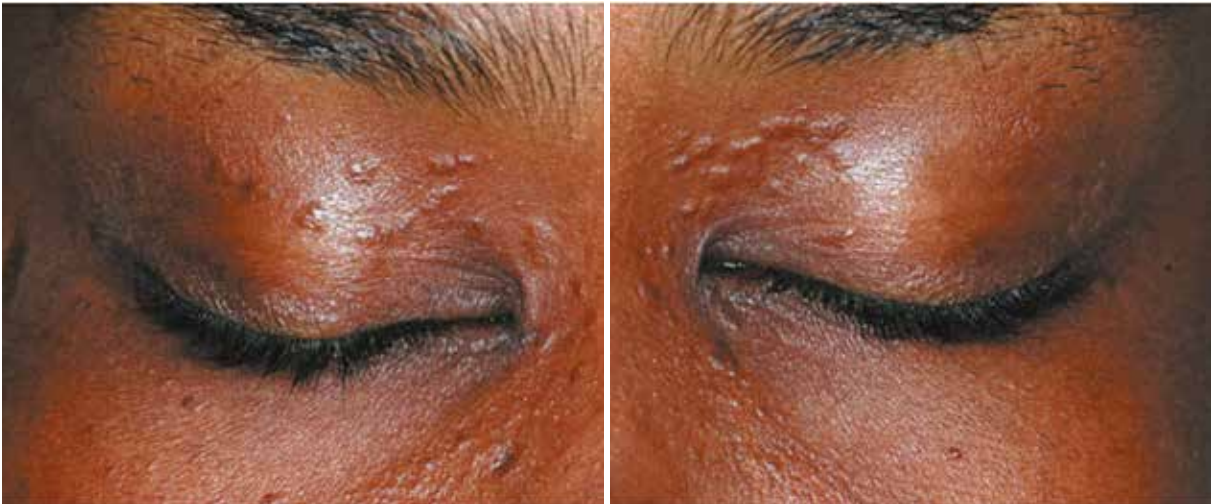Syringocystadenoma papilliferum



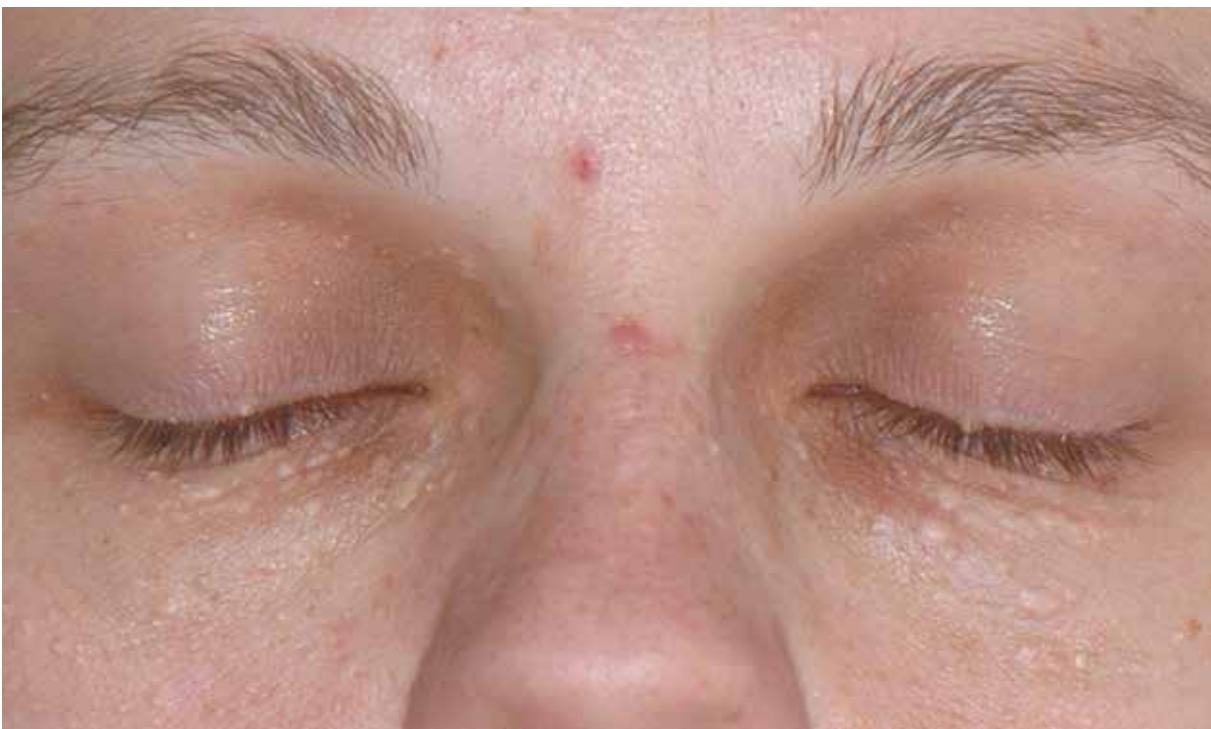The syringocystadenoma papilliferum is a skin hamartoma of the apocrine sweat glands.

It is rare and the diagnosis is difficult. Total surgical excision is recommended due to the risk of malignant transformation in 10% of cases.

Syringoma

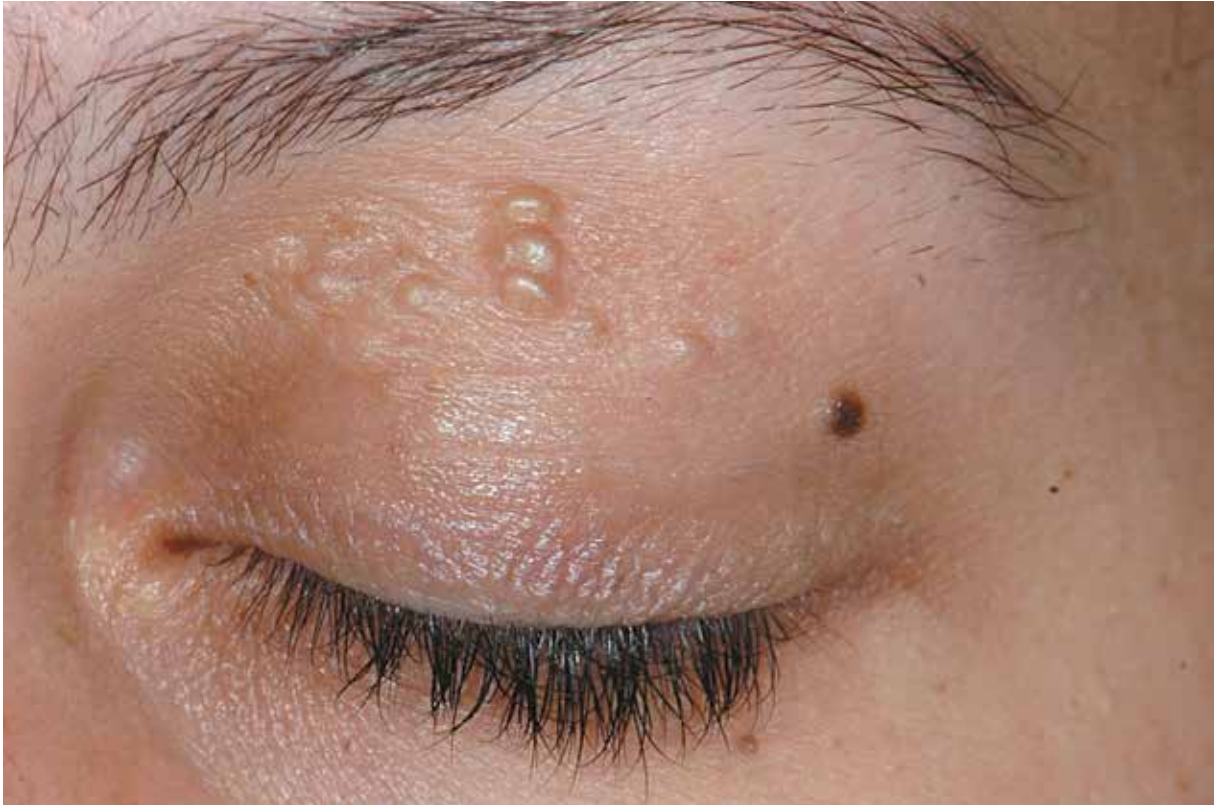

Benign tumor of the eccrine sweat glands, yellow or flesh-colored with smooth surface often occurring in young women during puberty, predominantly on the eyelids.



Presence of small, firm, smooth papules more or less confluent containing a colloid.

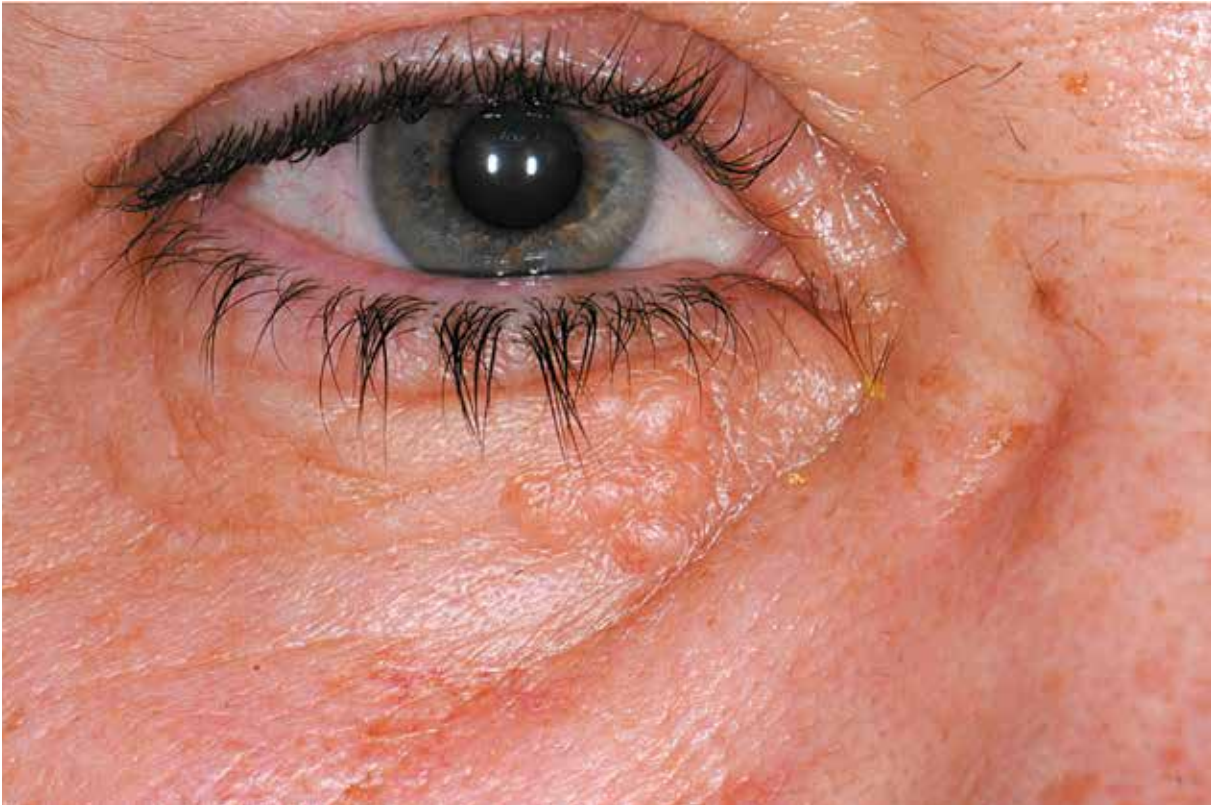Syringoma



Surgical treatment can be difficult due to the number of lesions.

As surgical excision might leave an unattractive scar, ablative laser resurfacing treatment is recommended.

Desmoplastic syringoma



Desmoplastic or chondroid syringoma are nodules found predominantly on the face.

They result from the proliferation of the sweat ducts with Malpighian metaplasia.
Surgical excision is recommended so as not to disregard a basal cell carcinoma.



4. Melanic tumors

Melanic tumors

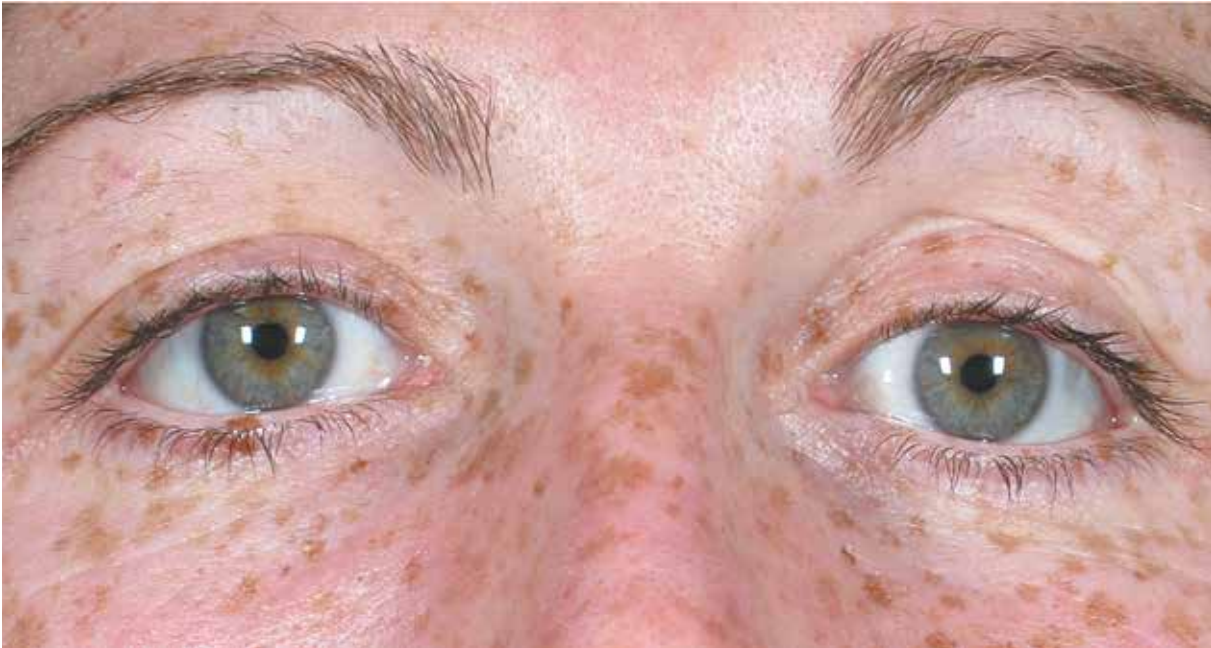Melanic lesions range from nevus to acquired melanosis and melanomas.

Melanosis is an abnormal proportion of intra-epithelial melanocytes, whereas melanocytic nevi are found at the dermal-epidermal junction.

Primary acquired melanosis is considered as a precancerous melanosis.

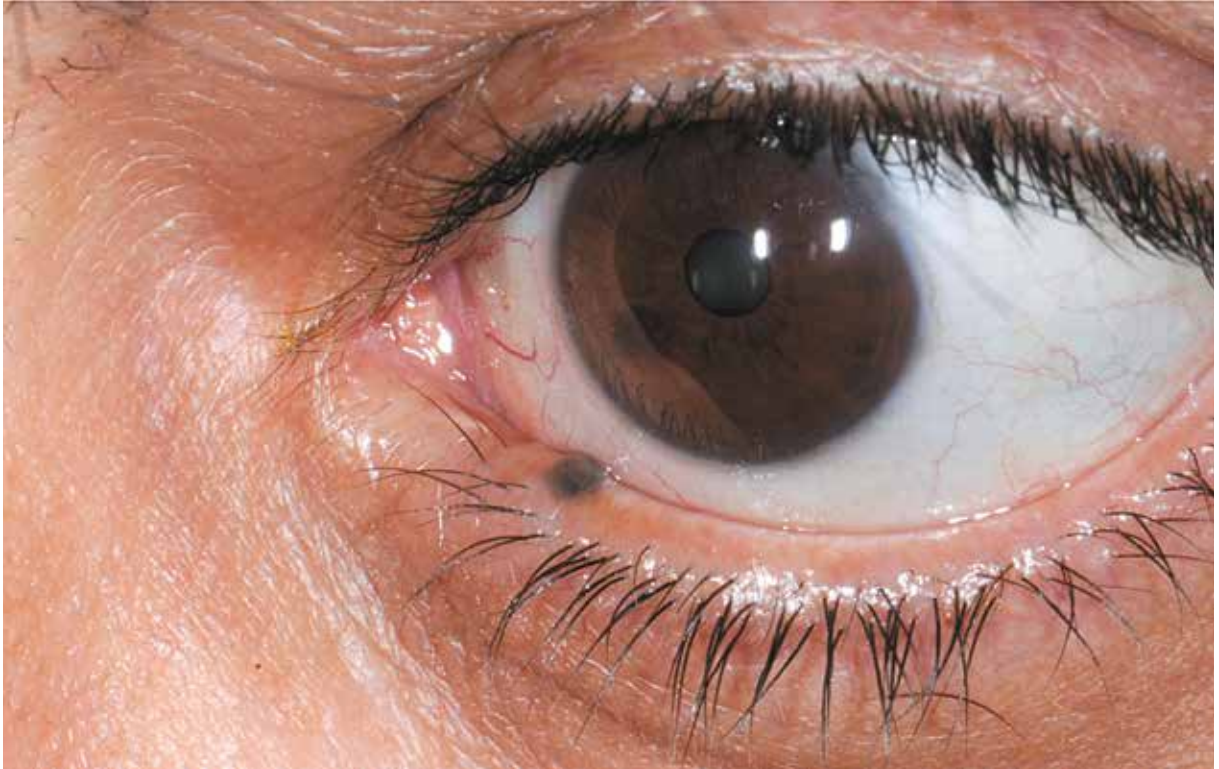
The risk factors of melanosis are phototype, age and amount of UV exposure.

Ephelides



Developing from childhood following sun exposure, ephelides are the densification of the pigment of normal melanocytes. Ephelides indicate a UV-sensitive phototype.

Junctional NCN



Nevocellular nevi (NCN) are pigmented papules comprising clusters of melanocytes in the epidermis, the dermis, and the hypodermis.

Sun exposure encourages NCN development.

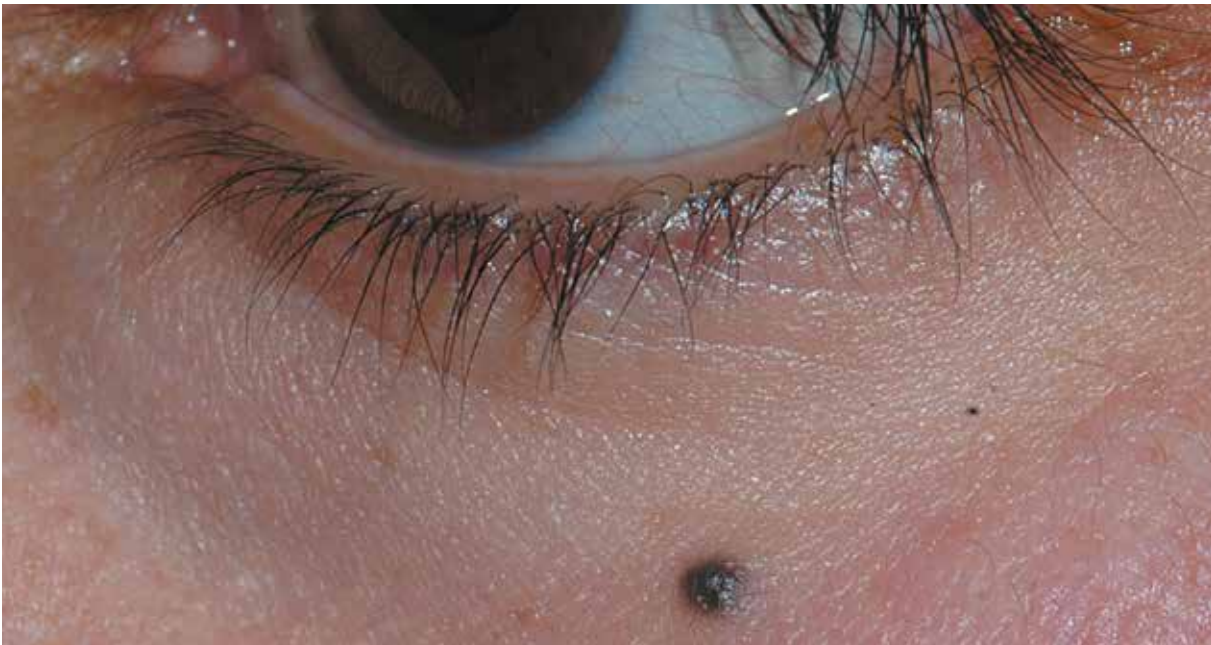
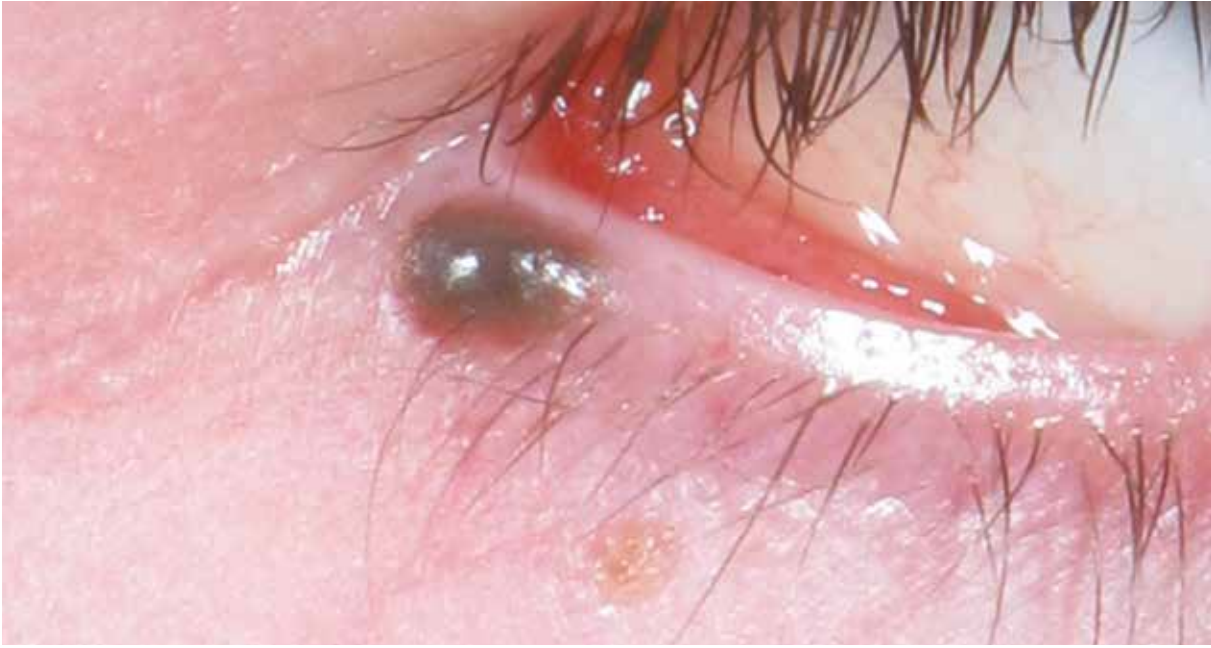They are classified according to their physical features:

- Junctional NCN: on the intra-epidermal side of the basal membrane
- Mixed NCN: epidermal and dermal
- Dermal NCN: entirely intradermal

Excision is recommended in the following cases:

- Rapid change in size
- Development of more heterogeneous pigmentation
- Uneven edges
- Ulceration
- Pruritus

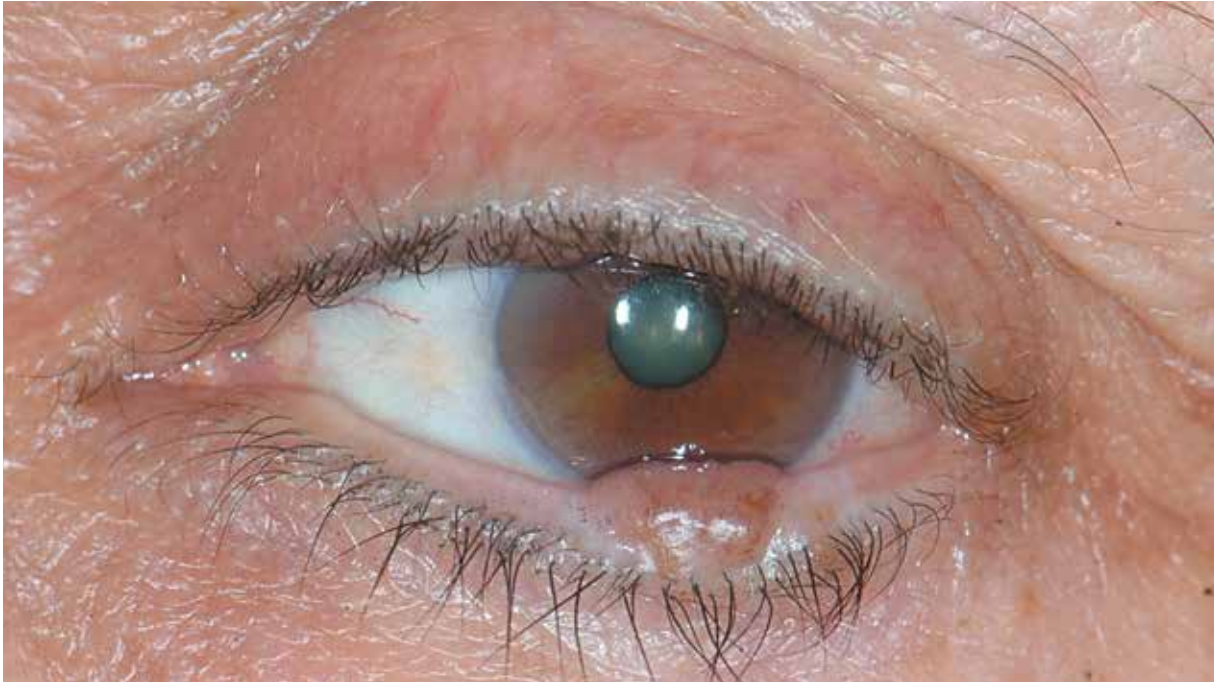Mixed or compound NCN



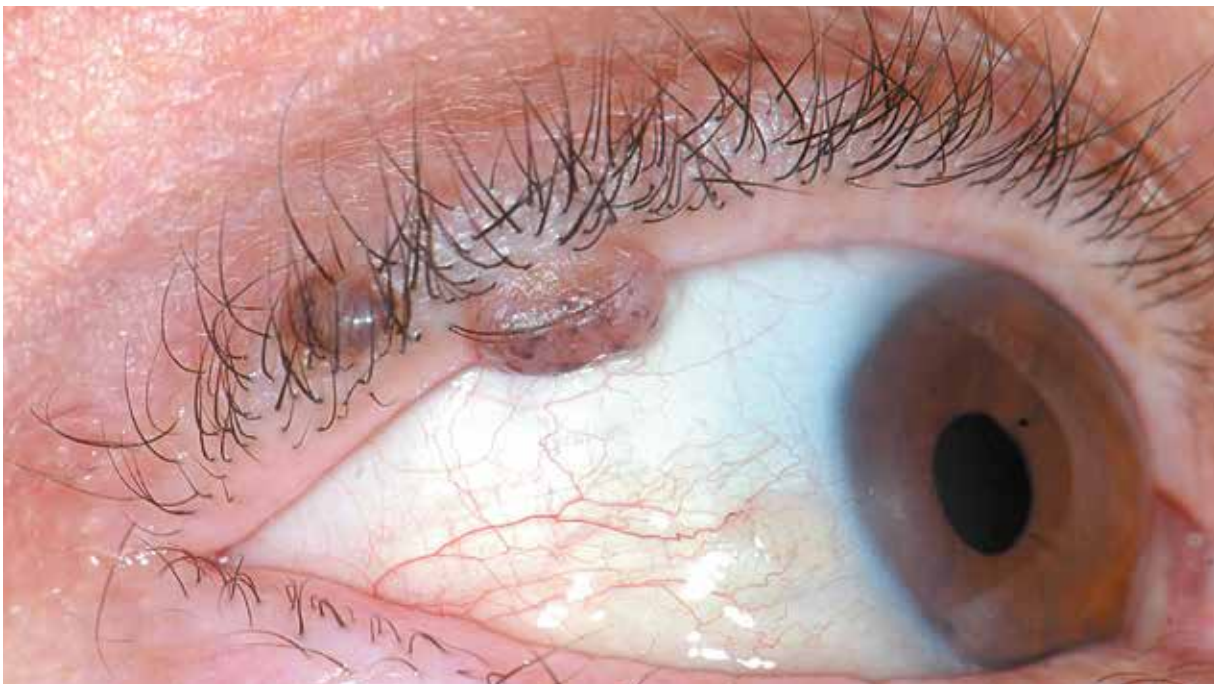Epidermal and dermal melanocytic clusters. Clearly defined small, dark brown or black papules.

Differential diagnosis: nodular melanoma, pigmented basal cell carcinoma, seborrheic keratosis.

Dermal NCN

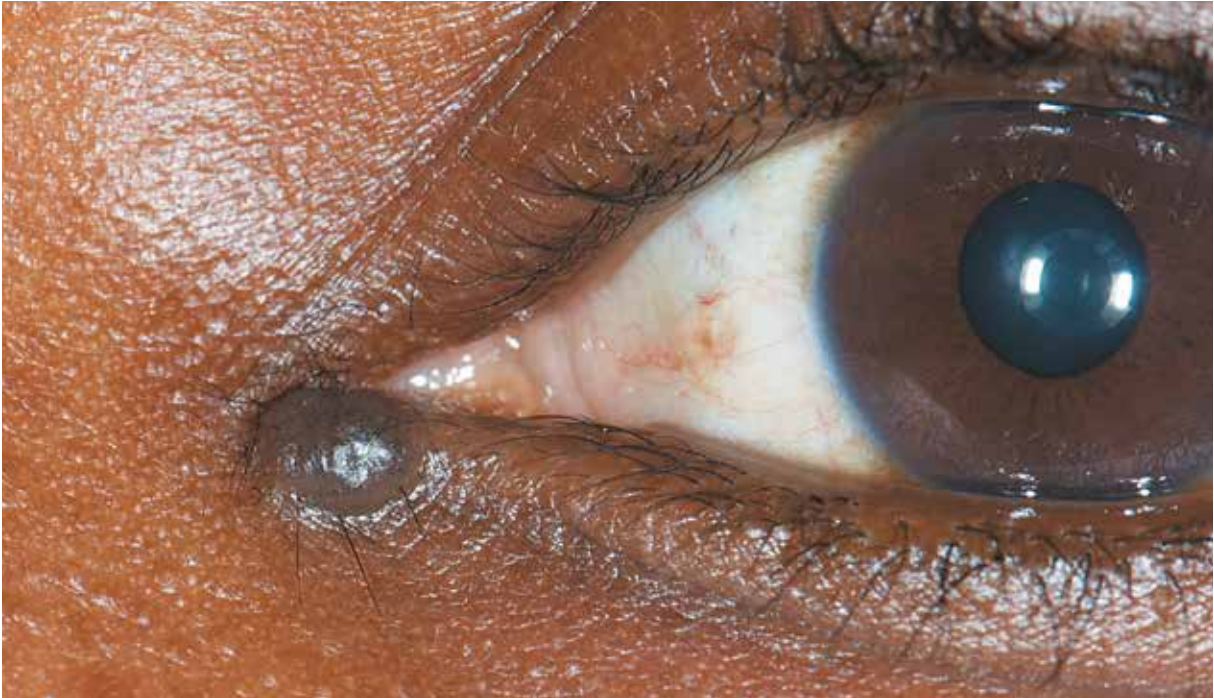

Clearly defined flesh-colored papule with brown marks and telangiectasia.
Differential diagnosis: melanoma, basal cell carcinoma.

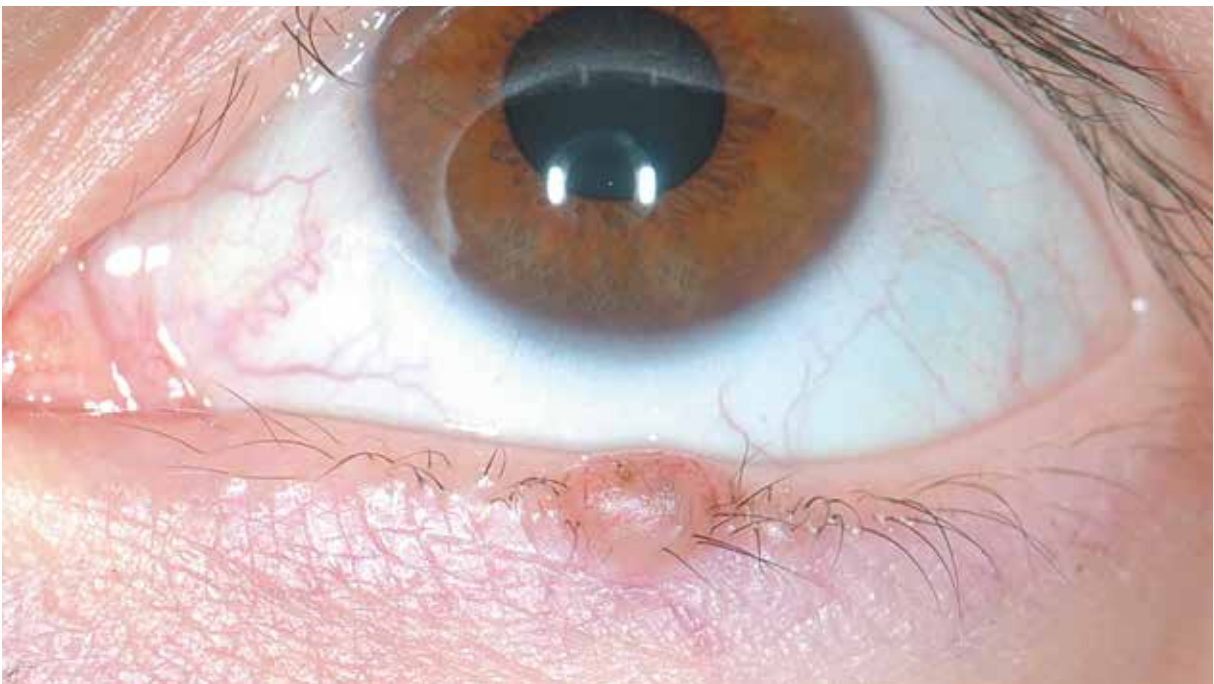

Lesions on the free margin and around the lashes.

Dermal NCN

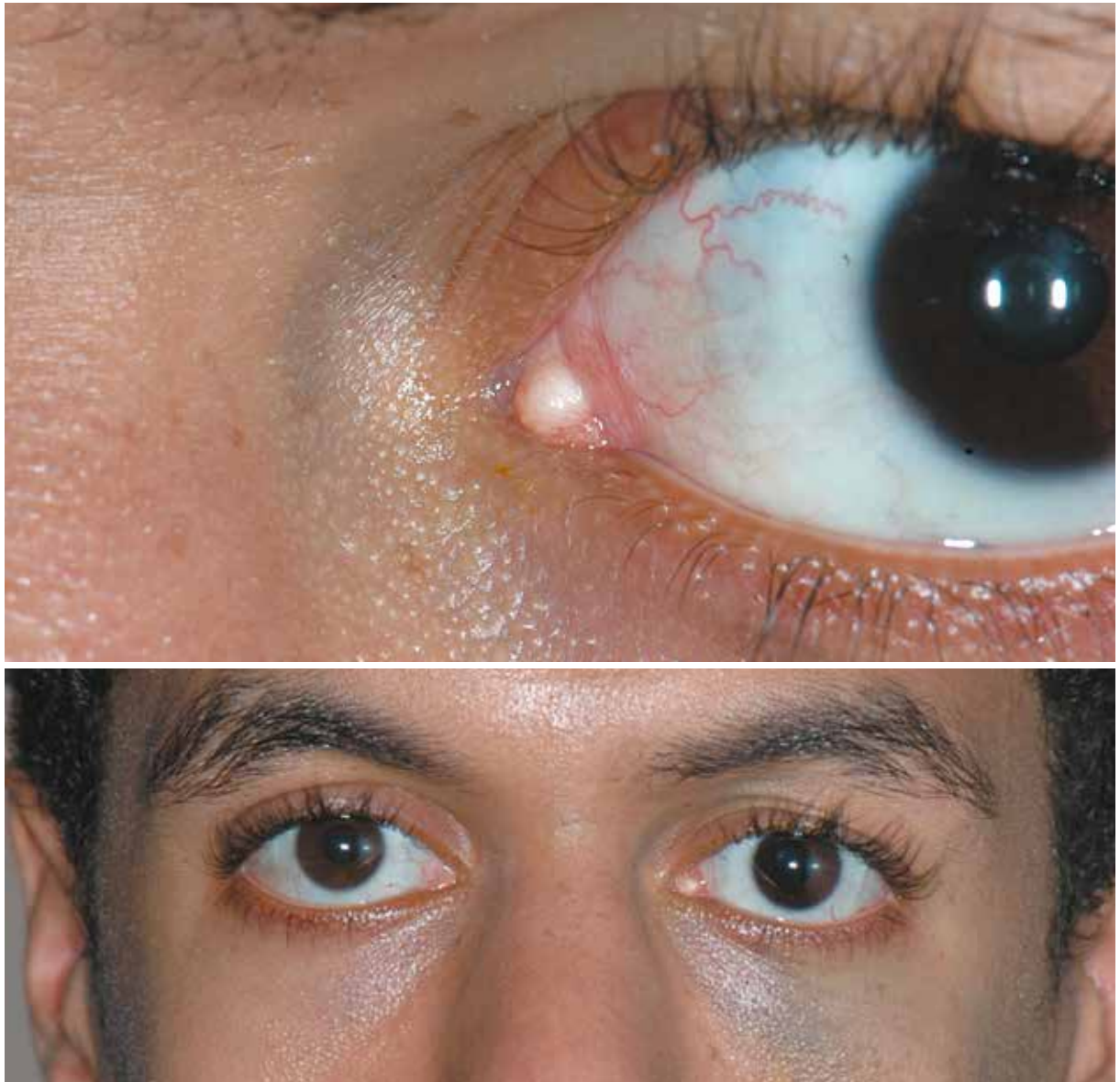

Possible presence of hairs.



Telangiectasia is more visible in light phototypes.

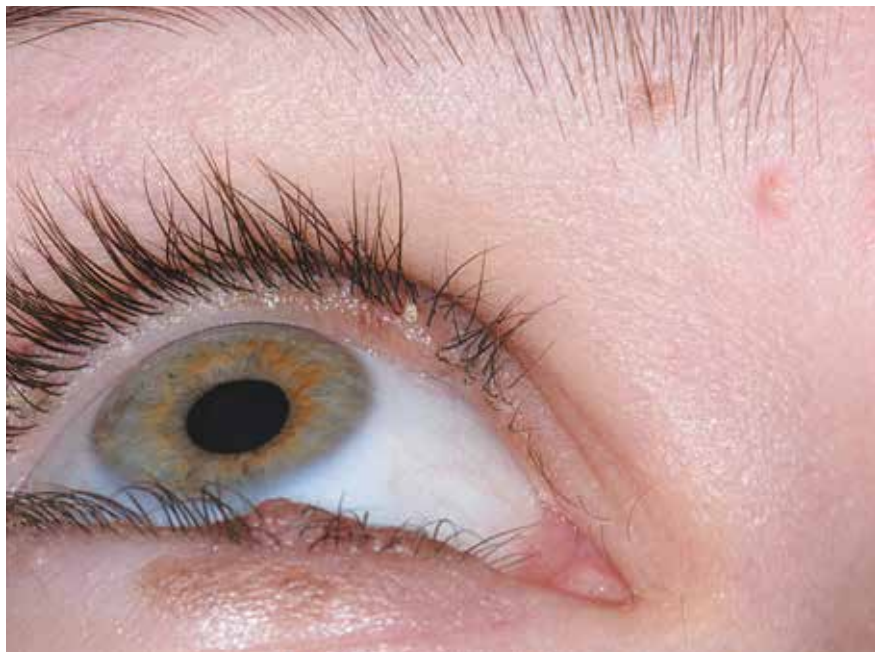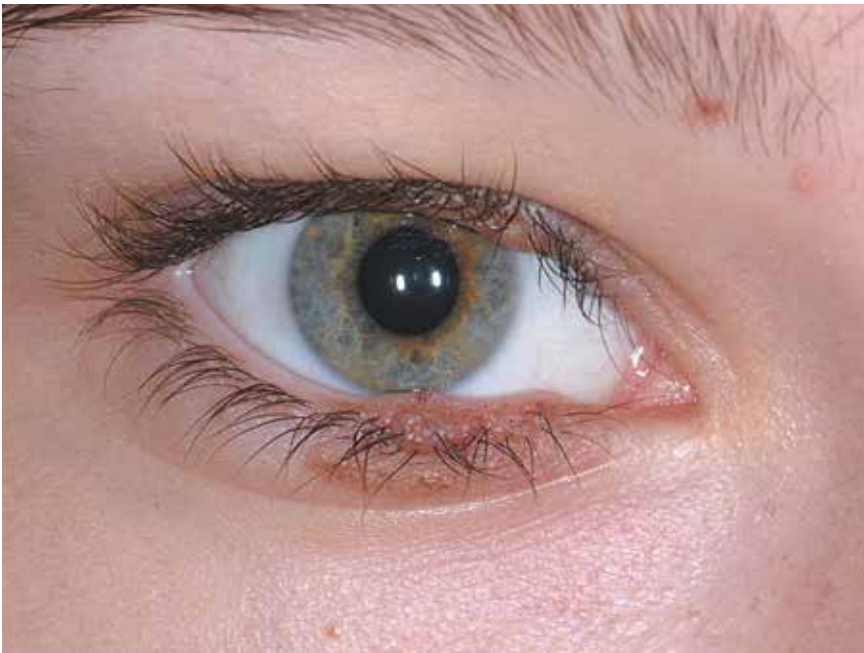Nævus d'Ota



Skin and mucosa hyperpigmentation, blue-gray, discreet to highly visible around a branch of the trigeminal nerve.

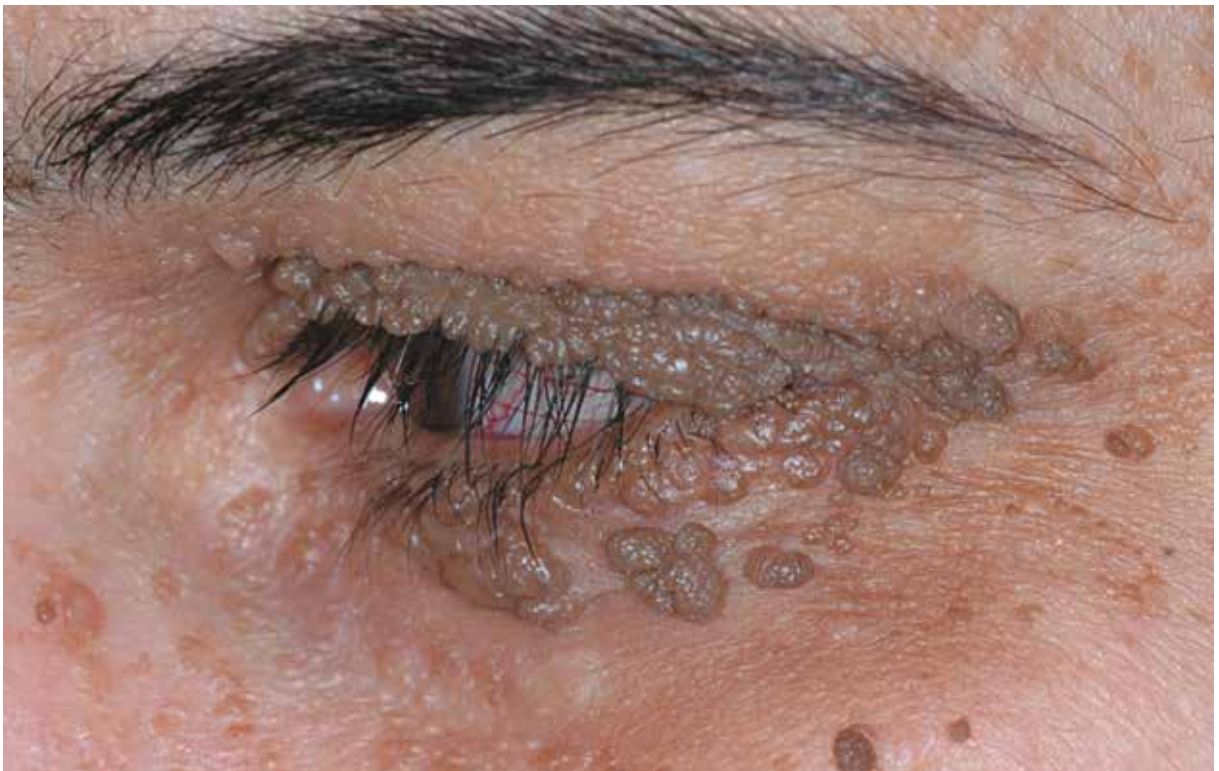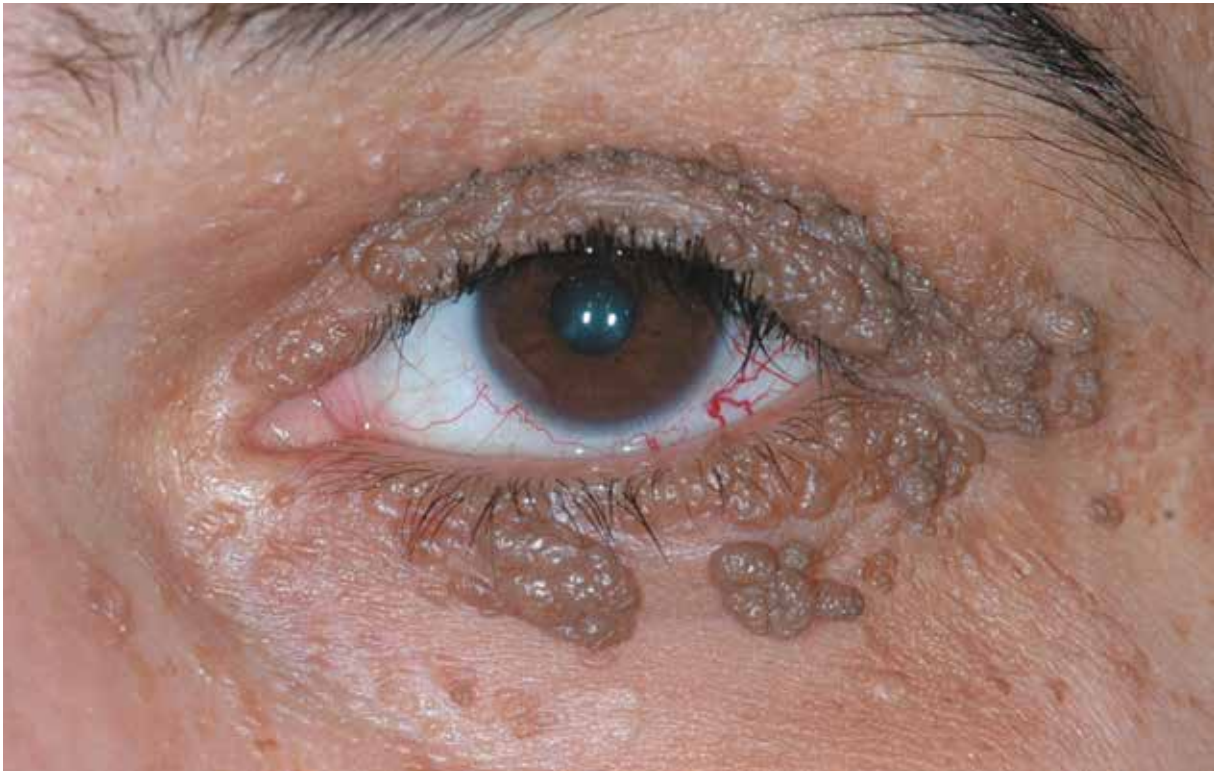The involvement of V1 is characterized by scleral pigmentation and an increased risk of developing a choroidal melanoma, thus justifying regular monitoring.

Split congenital melanocytic nevus of the eyelid or kissing nevus.

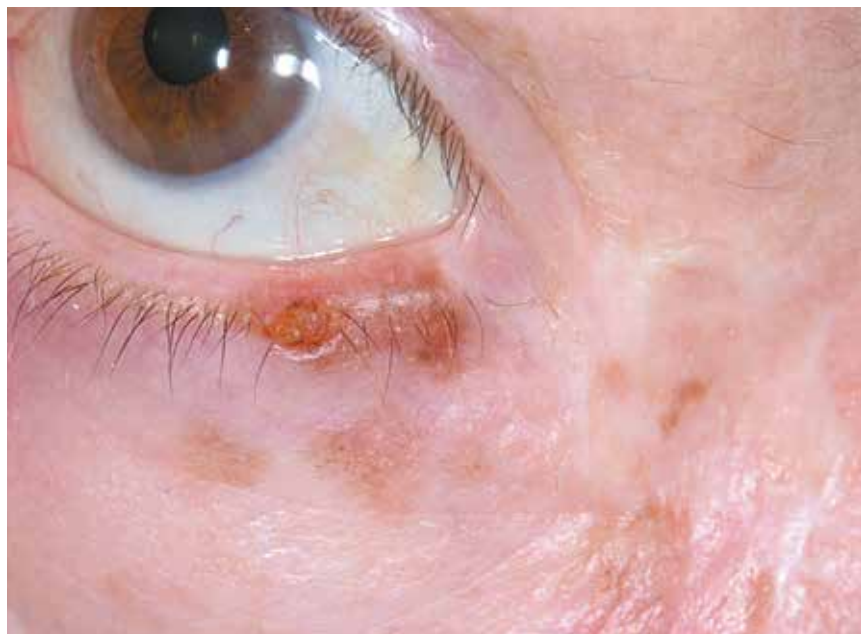
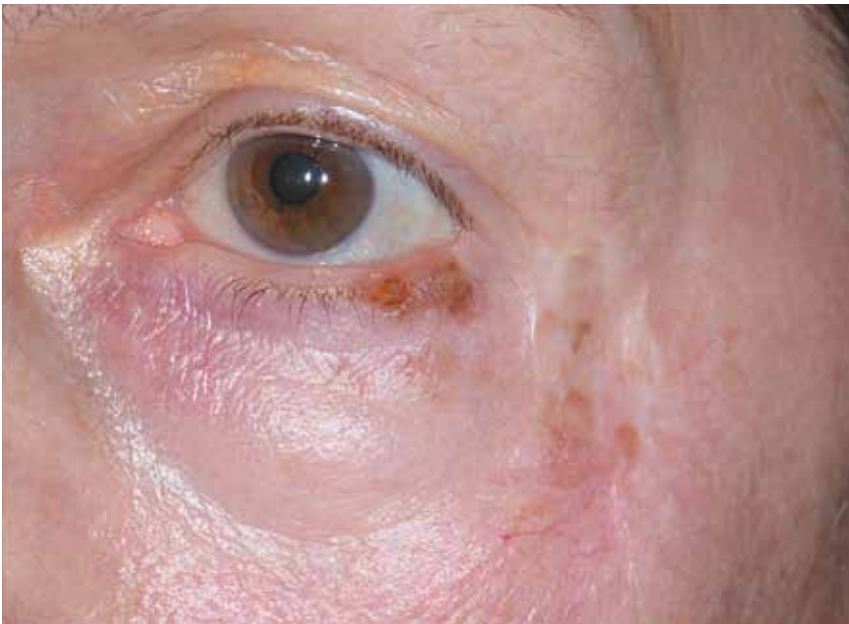


Occurs as it is a result of a problem during the migration of the cells from the neural crests in utero before the separation of the eyelids in the 24th week.

Split congenital melanocytic nevus of the eyelid or kissing nevus.



Lentigo maligna or Hutchinson's melanotic freckle.

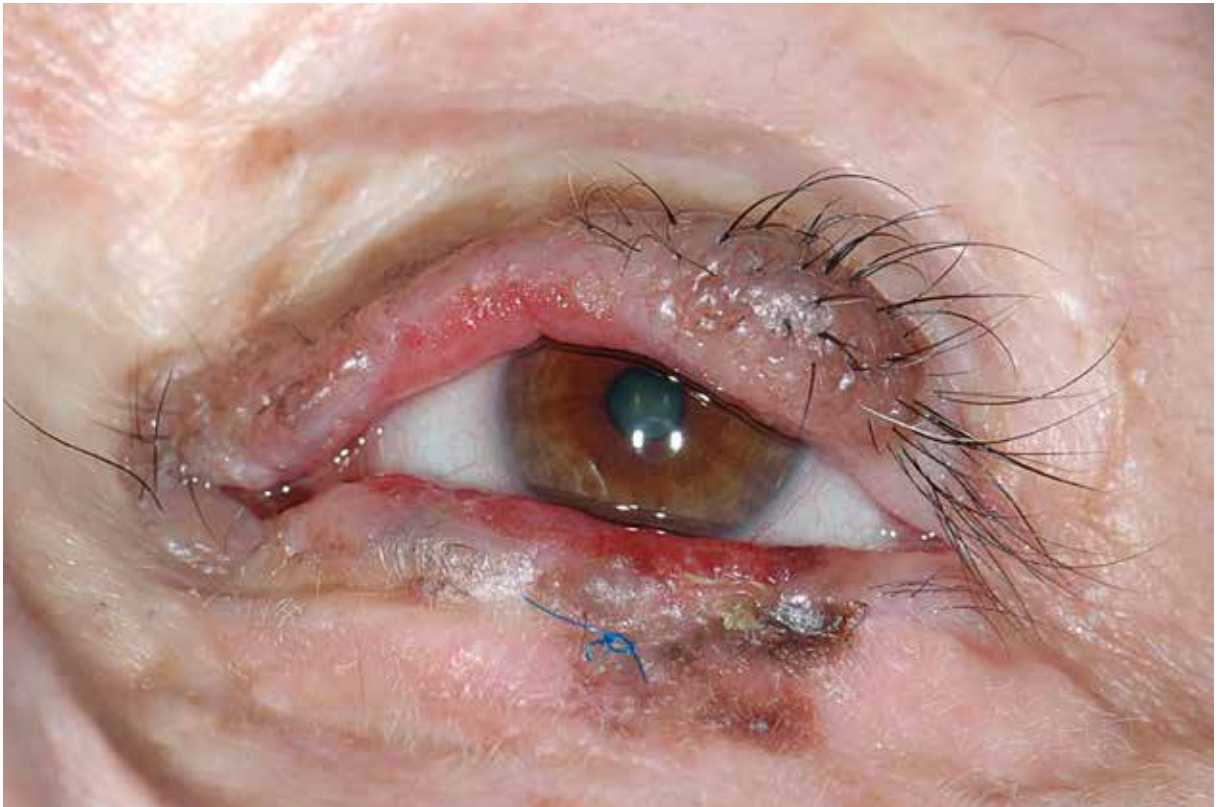

Develops in areas exposed to light, starts with intraepidermal tumoral proliferation.

The presence of papules or nodules indicates the onset of vertical extension and therefore dermal invasion.

Extensive superficial melanoma

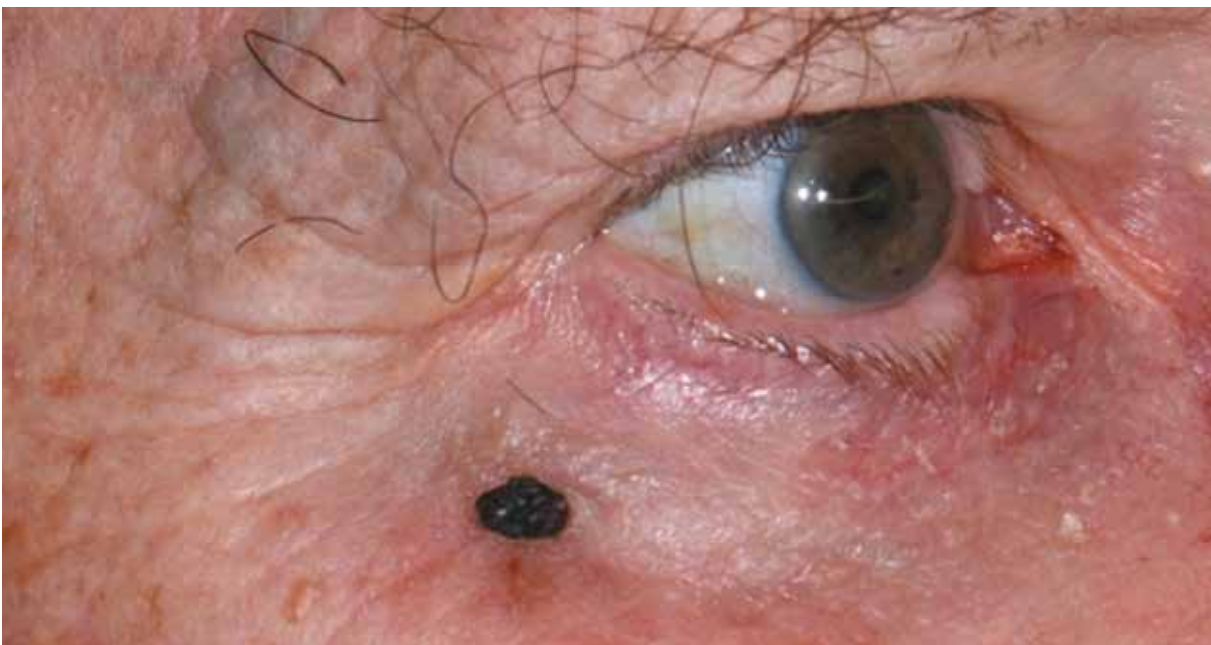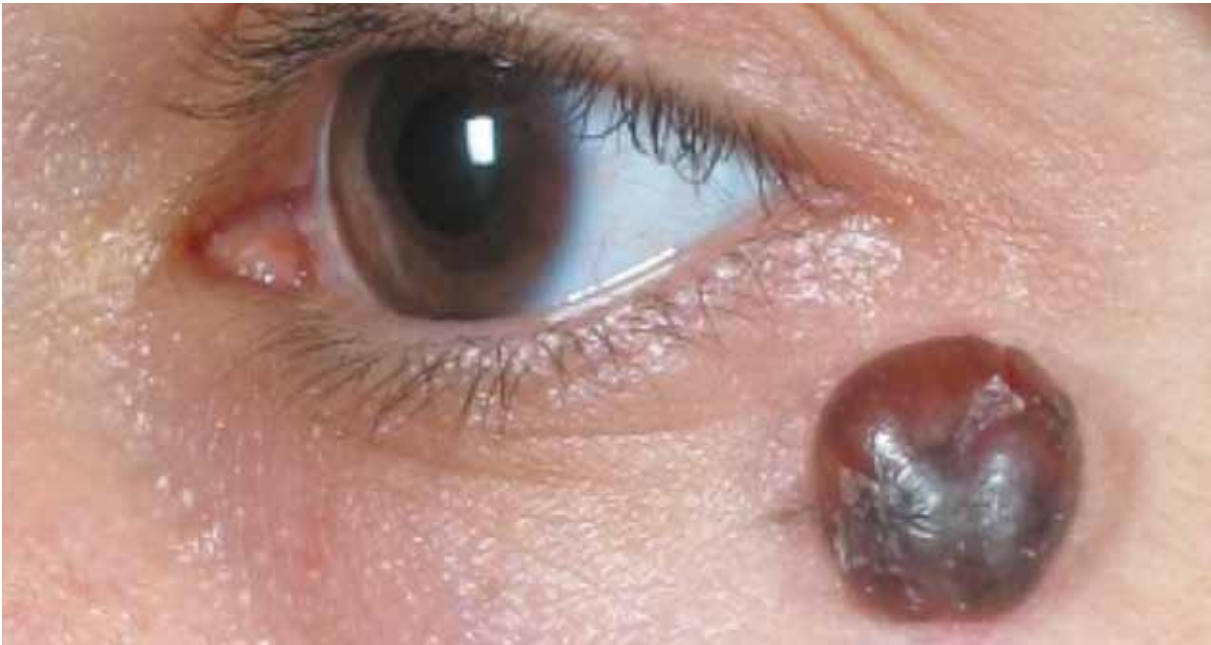Kissing nevus complicated with extensive superficial melanoma



An extensive, superficial malignant melanoma is the subsequent stage with horizontal and vertical growth, and is characterized clinically by a very irregular appearance with significant polychromy and a heterogeneous surface.

Nodular melanoma

Nodular melanoma



Lesion with deep invasion; can occur de novo.

Rapid progression over a few months; the characteristic lesion is a raised nodule that can be achromatic.



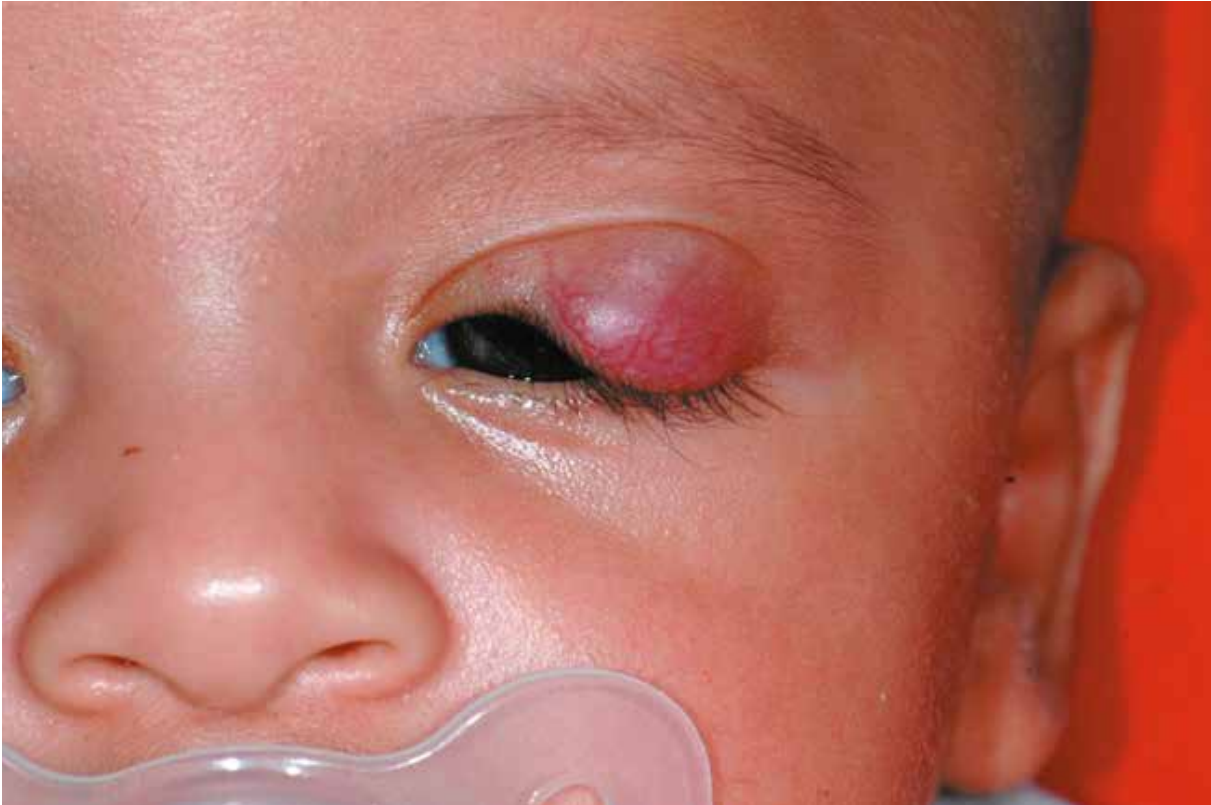5. Vascular tumors

Vascular tumors

Previously, the term «angioma» designated multiple vascular anomalies. Since the introduction in 1996 of the classification established by the International Society for the Study of Vascular Anomalies (ISSVA), vascular tumors are differentiated from vascular malformations.

They are characterized by the proliferation of endothelial cells and can be congenital or develop later, with phases of growth and regression. The most common are infantile capillary hemangiomas and congenital hemangiomas. Malignant forms are rare.

Subcutaneous infantile hemangioma



The most common vascular tumor, it can be present from birth in 20% of cases or develop after a few days or weeks. It is a fast-flow tumor.

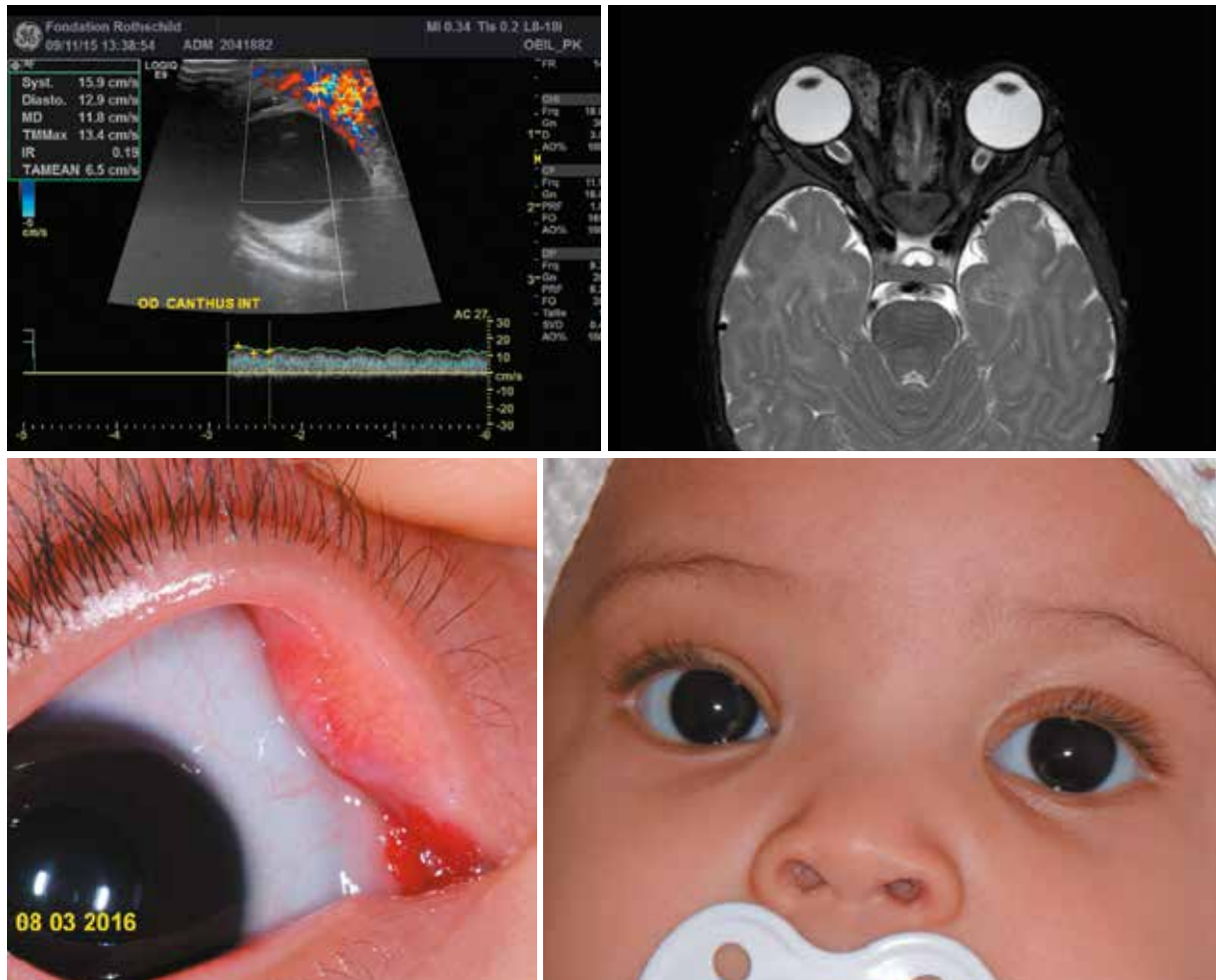
There are three forms: superficial, subcutaneous and mixed. It progresses in three phases with rapid growth, stabilization and then slow regression.

Glt-1 positive immunomarking differentiates them from congenital hemangiomas.

If there is a risk of amblyopia or complications, beta-blockers are now used as a first-line treatment. In the case of residual tissue or contraindications, surgical excision is still valid.

Involvement of the deep dermis. Hot elastic non-pulsating swelling lifting the healthy skin, bluish and pinkish in color and superficial draining veins. Risk of amblyopia by mechanic ptosis.

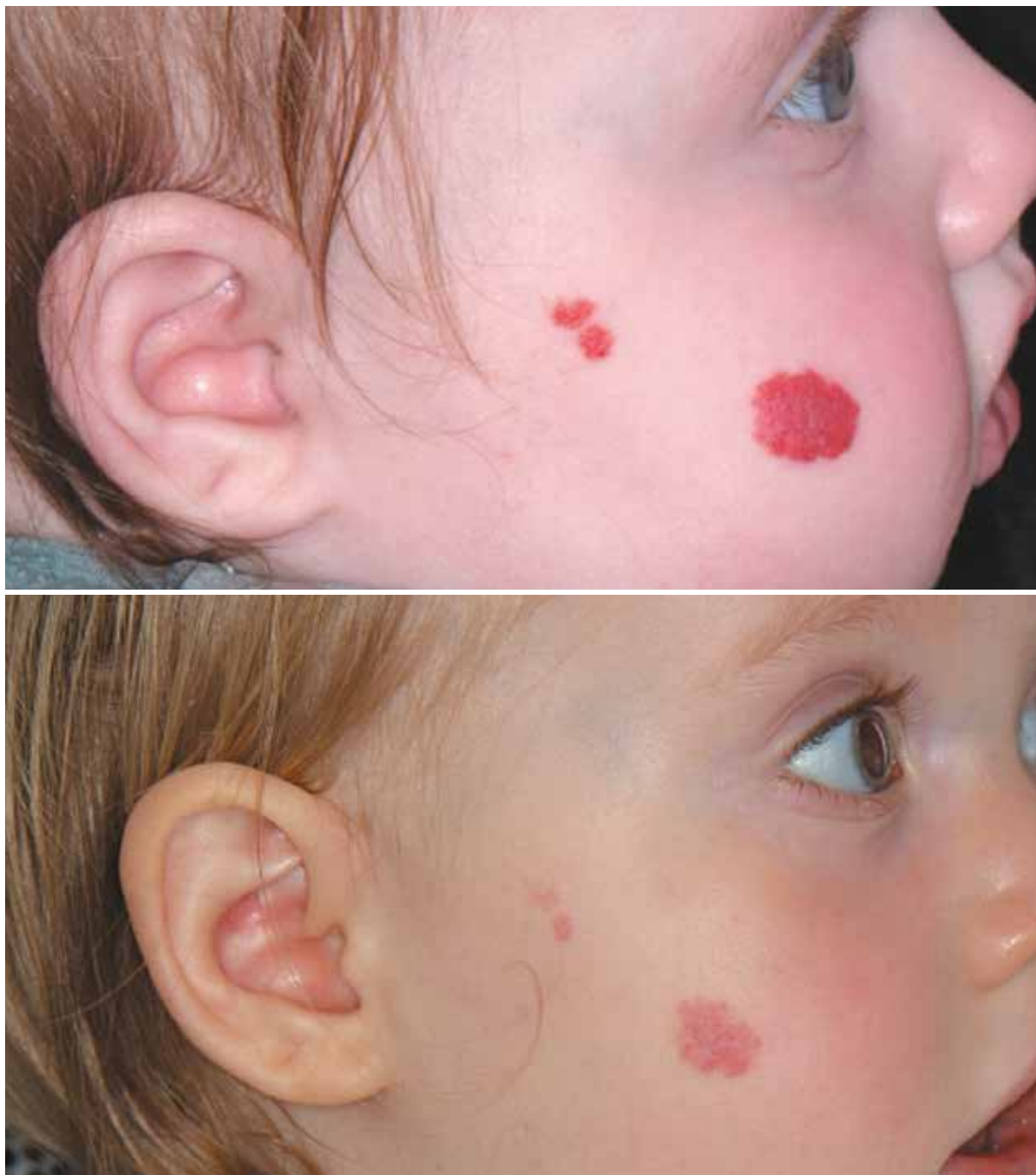Mixed infantile hemangioma



Superficial form visible on the inner canthus and the caruncle. Deep form under the inner canthus with intra-orbital extension.

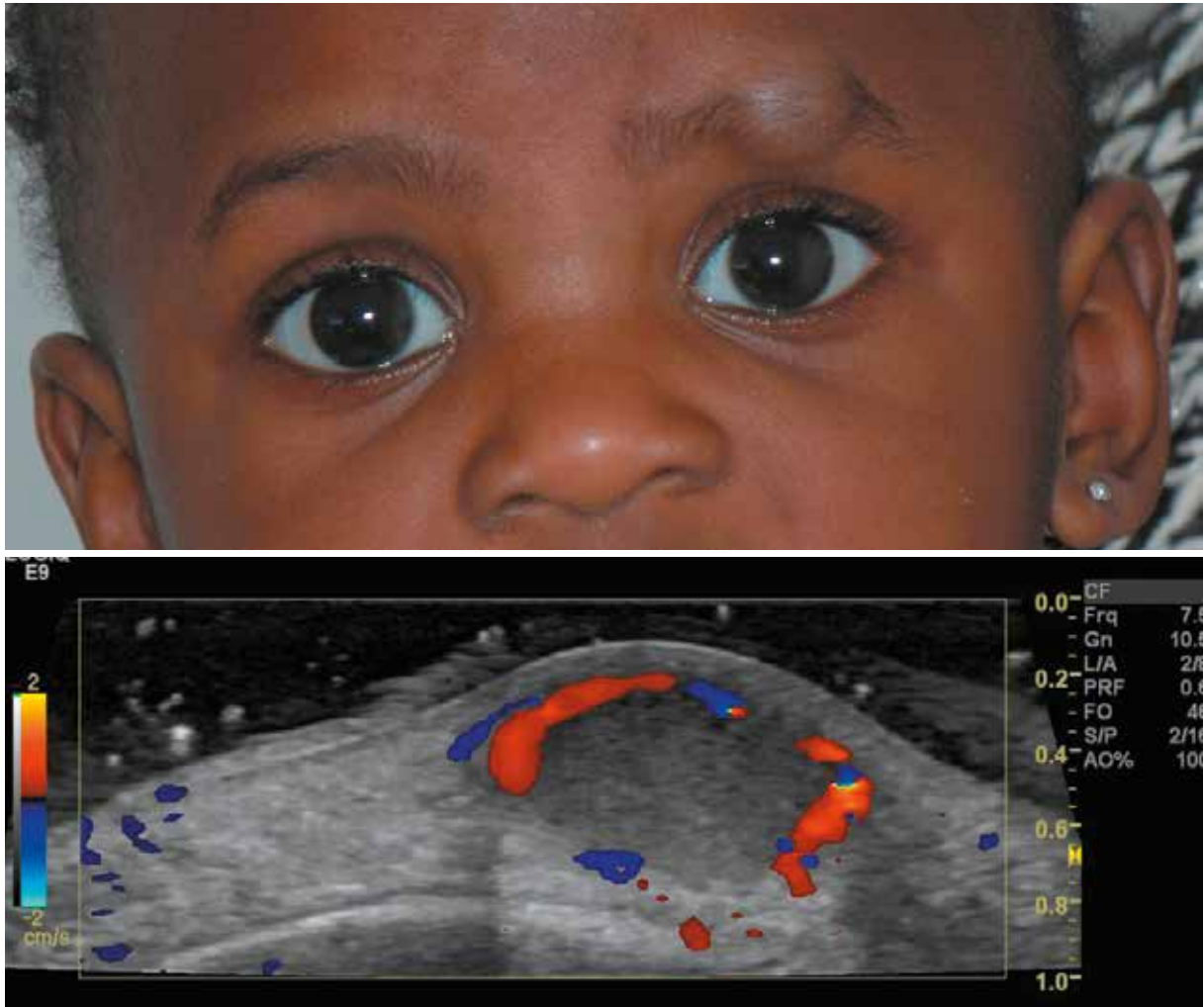
Characteristic appearance on Doppler Ultrasound, hypoechoic lesion with hypervascularization. Risk of amblyopia by induced strabismus.

Infantile hemangioma



Result after treatment with beta-blockers.

Congenital hemangiomas



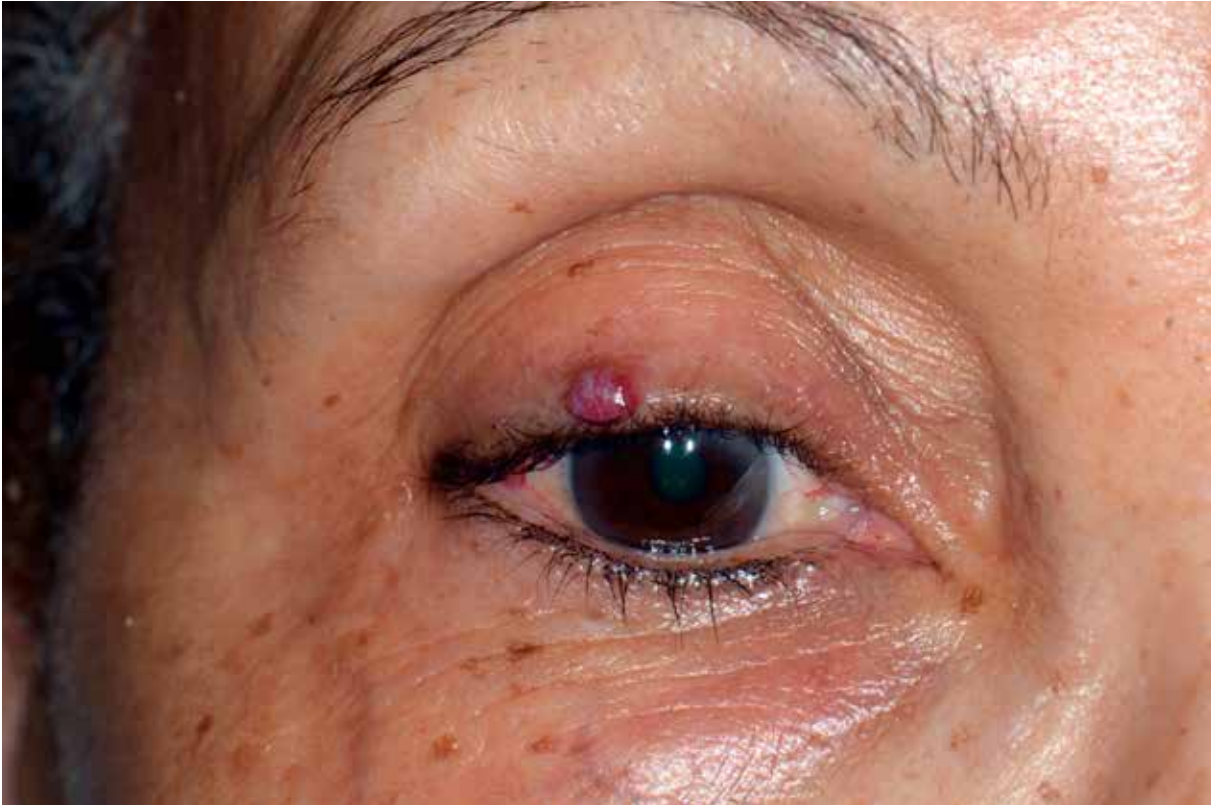Rare tumors that develop in utero; immunohistochemistry glut-1 negative.

Two main forms:

- RICH (rapidly involuting congenital hemangioma), purplish mass with rapid regression in 4 to 18 months with lipodystrophy scar
- NICH (non-involuting congenital hemangioma), unique clearly defined lesion, no regression phase and grows with the child.

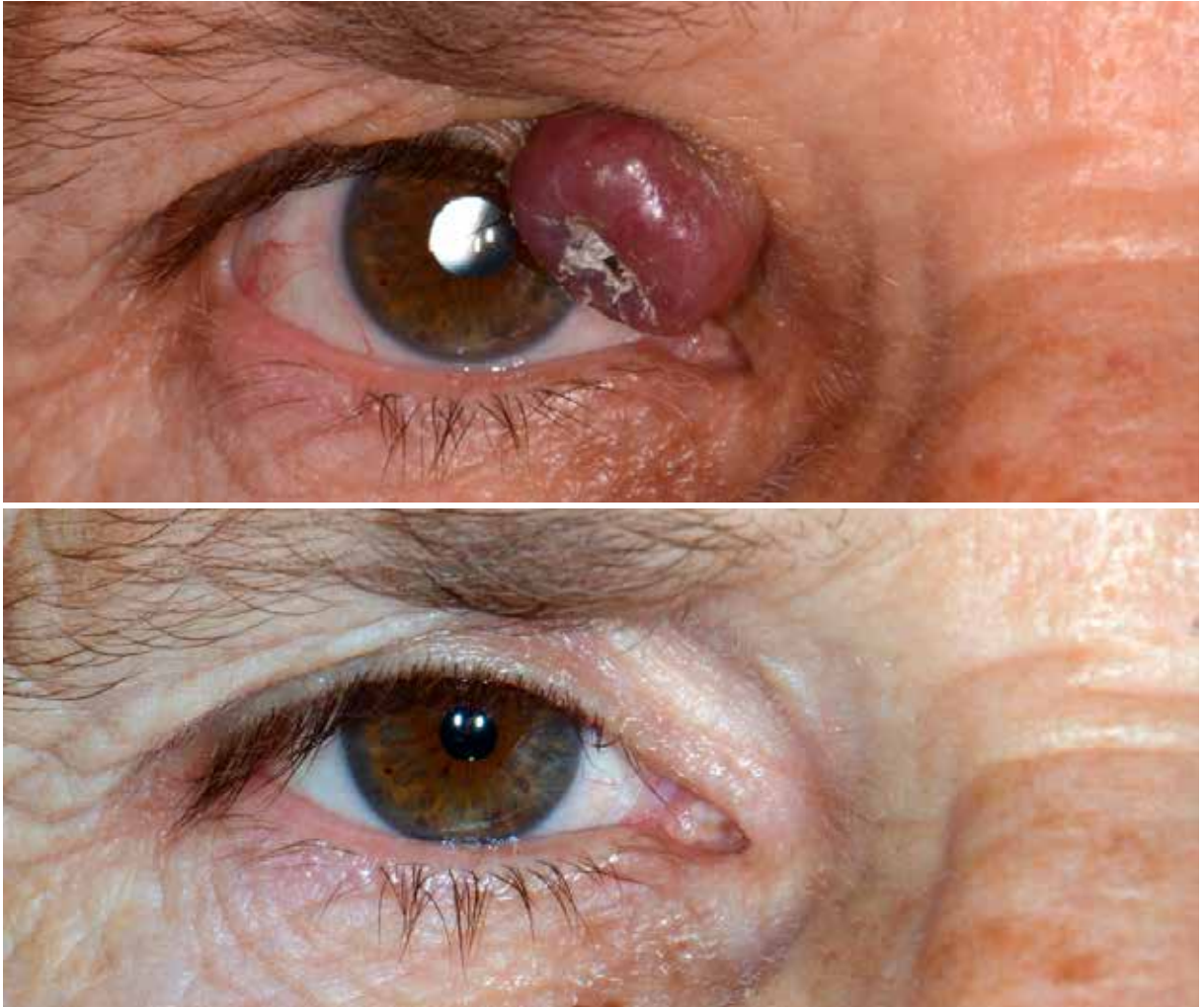
NICH of the left eyebrow. Clearly defined lesion present from birth without regression. Heterogeneous appearance on doppler ultrasound with arterial-venous microshunt and poorly vascularized.

Pyogenic granuloma



Vascular lesion linked to endothelial proliferation following a minor trauma. Bright red or brown nodule, isolated, smooth surface that bleeds easily and so can be covered in a scab.

Pyogenic granuloma



Pyogenic granuloma, right eyelid that has bled, treated by uncomplicated surgical excision.



Vascular malformations

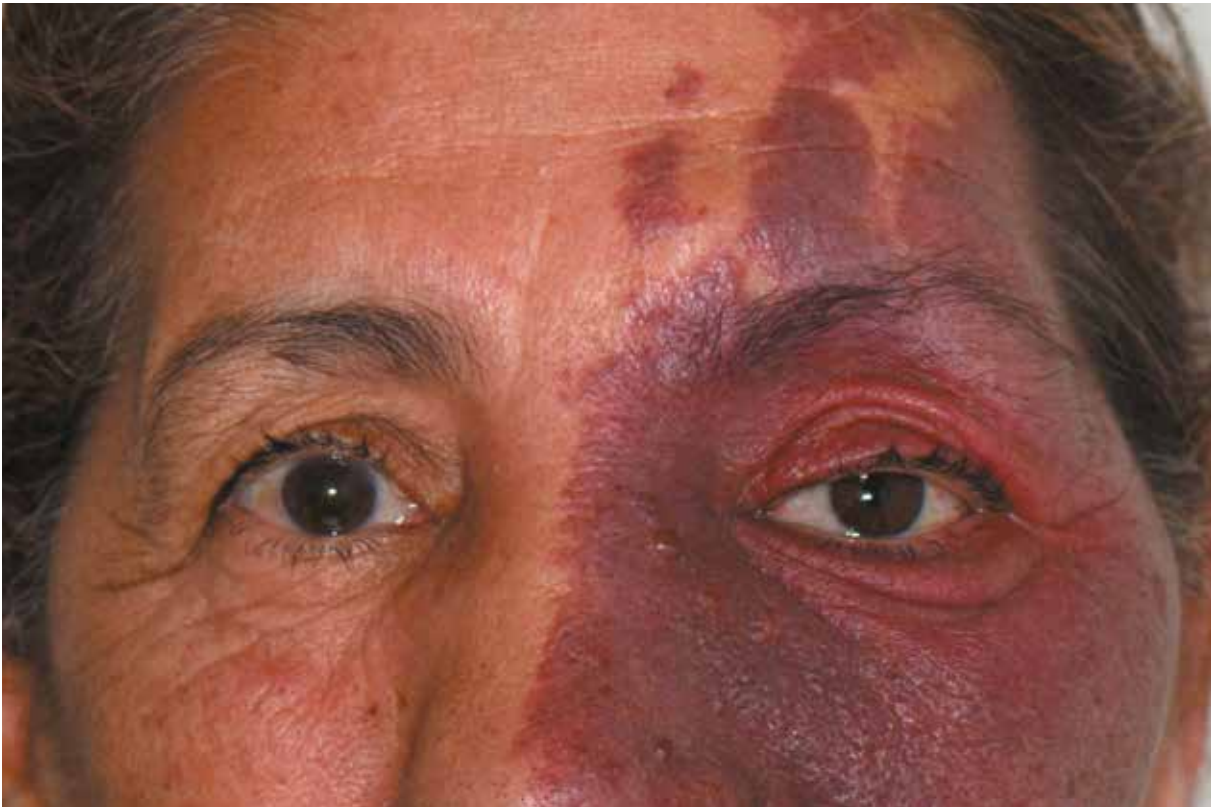These are structural anomalies of the vessels acquired during embryogenesis

They vary widely according to the type and size of the anomaly. They can potentially be progressive and spread to adjacent structures. They can be distinguished according to their origin, their hemodynamic characteristics and coincide with syndromes. The Hamburg classification system of 1988 considers the anatomy, the pathophysiology, the histology, the hemodynamics and the occurrence during embryogenesis.

Classification according to the predominant vascular form:

- Capillary malformations
- Lymphatic malformations
- Venous malformations
- Arterial malformations
- Arterial-venous malformations
- Combined malformations

Slow-flow malformation: capillary malformation

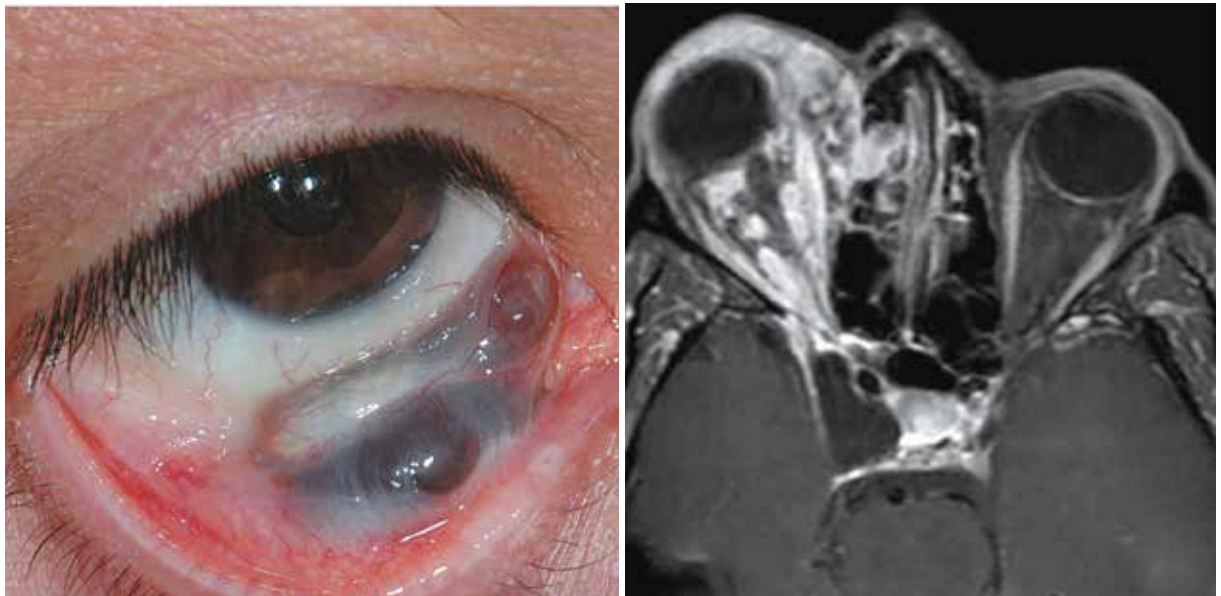


Most often involves the skin or mucosa.

The most common lesion is a «Port-wine stain» angioma. Intense red non-pulsatile lesion that thickens in adulthood with appearance of purplish papules and nodules. It can be associated with the Sturge-Weber syndrome. Involvement of the V1 area can be extended to V2 and V3 and even bilateral. Glaucoma is associated with 50% of choroidal and leptomeningeal vascular anomalies complicated with epilepsy. Doppler Ultrasound contributes little.

Vascular laser treatment is currently the best therapeutic option with more satisfactory results the earlier the treatment is carried out.

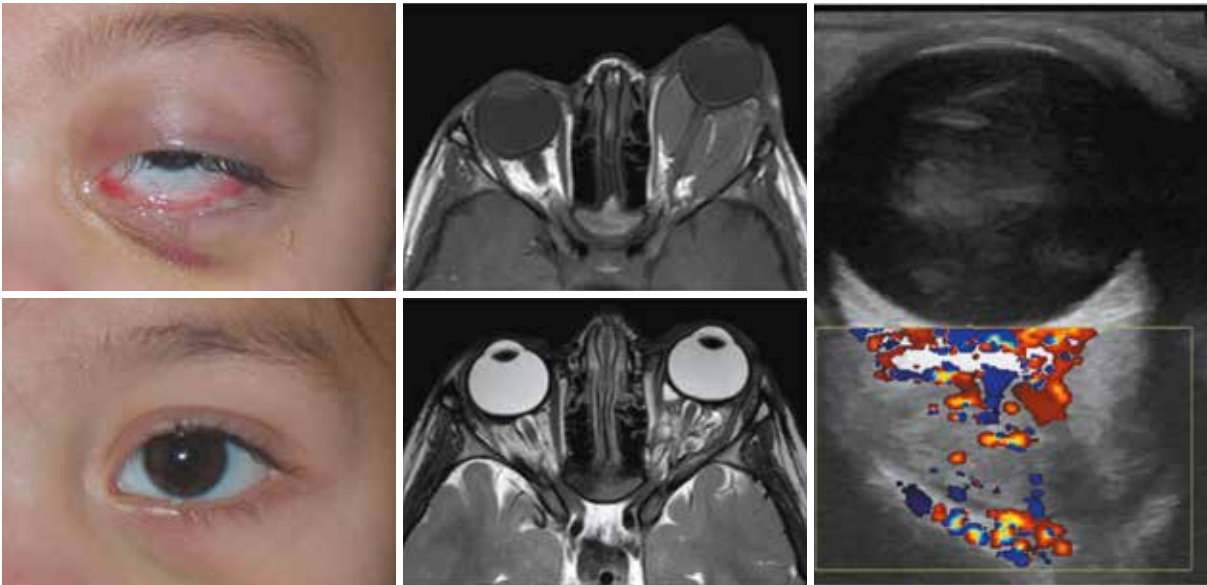
Lymphatic malformation: lymphangioma



Visible varicose content on the conjunctival surface.

Infiltration of the entire orbit with extension to ethmoid sinus. Presence of microcyst and macrocyst. Treatment involves sclerotherapy and partial surgical excision to be discussed according to the extension.

Lymphatic malformation: lymphangioma



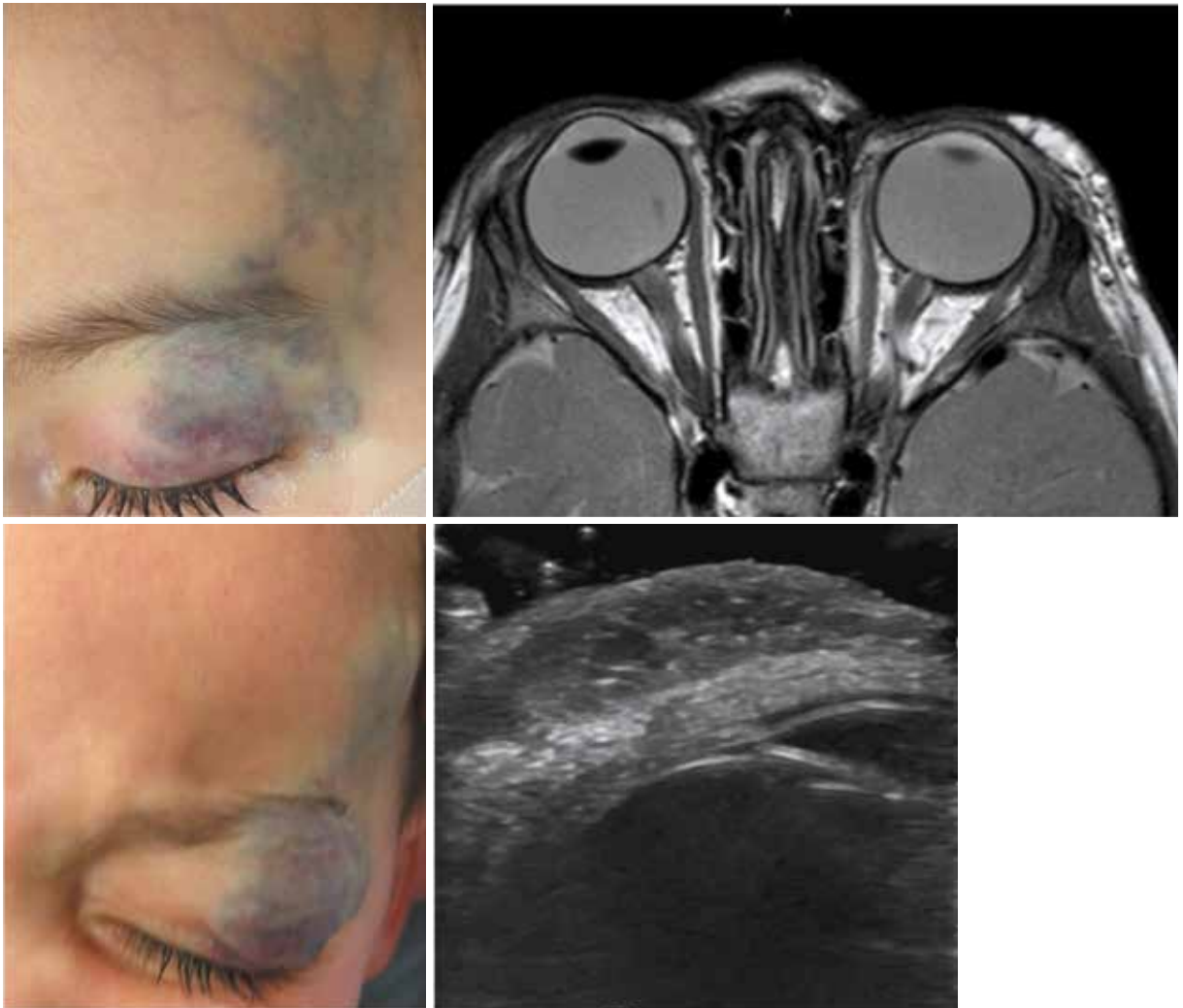
Hemorrhagic complication in the macrocysts.

Acute exophthalmos with compression and elongation of the optic nerve. Post-operative appearance of draining, persistence of cyst in the orbital apex.

The progression varies with possible spontaneous regression or complications with hemorrhages in the macrocysts, even infections.

Vascularization in the walls can be visualized with Doppler Ultrasound.

Predominant superficial venous malformation

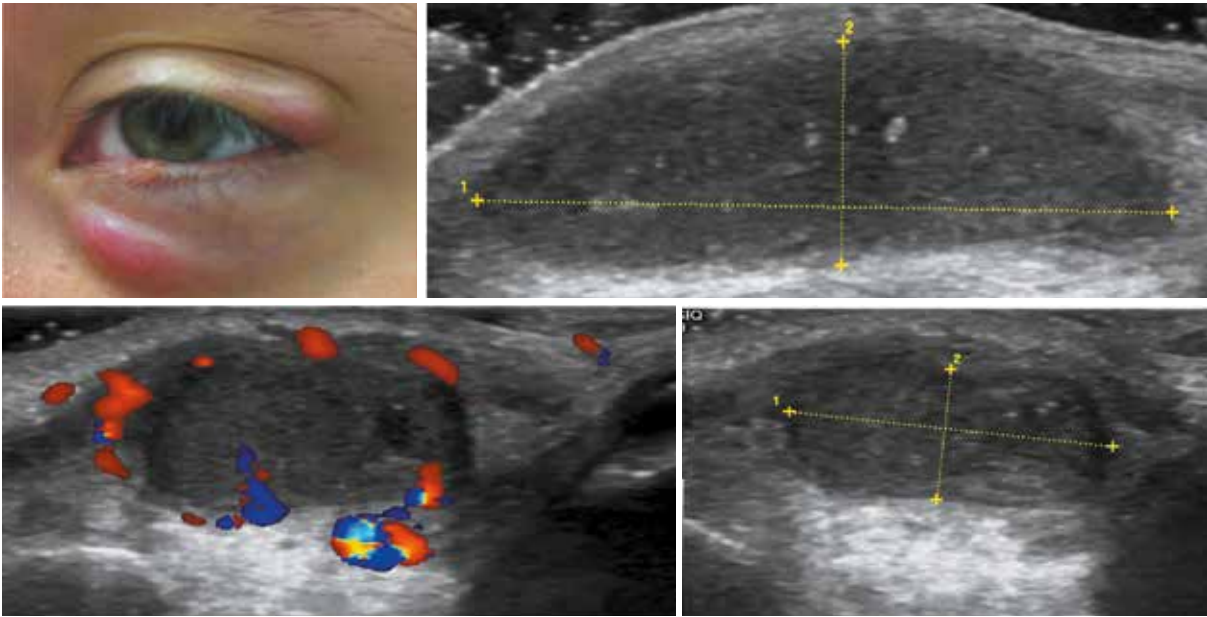


Lesions with heterogeneous edges following the vein network with possible deep extension.

Contrary to hemangiomas, these malformations have no potential for regression. They are slowly progressive with possible complications such as bleeding or thrombosis.

On Doppler Ultrasound, the venous malformation is anechoic with numerous cavities that can contain phleboliths or thrombi.

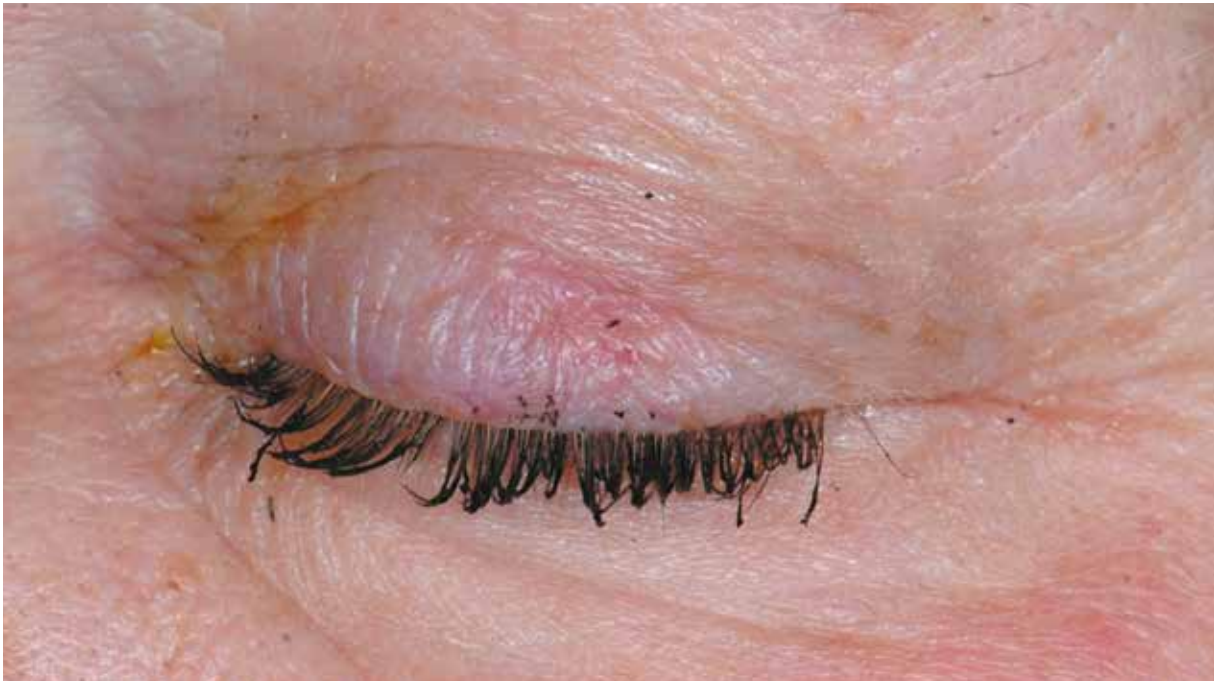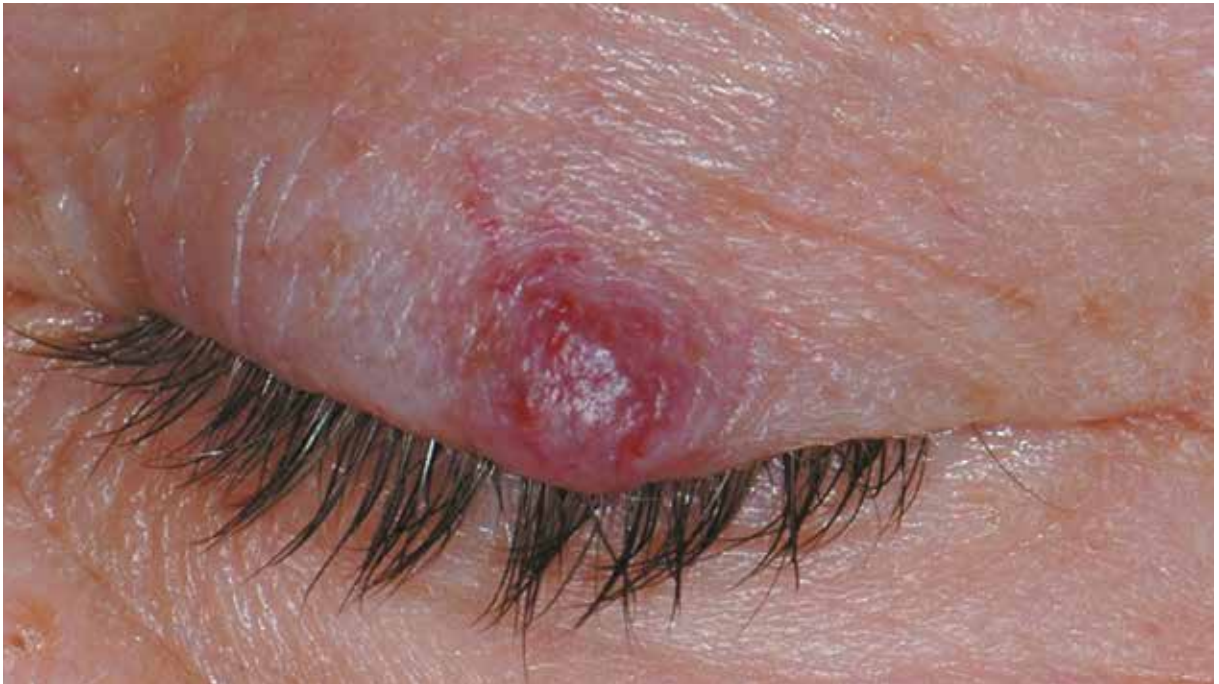Predominant superficial venous malformation



A Doppler Ultrasound is ideal for exploring vascular malformations.

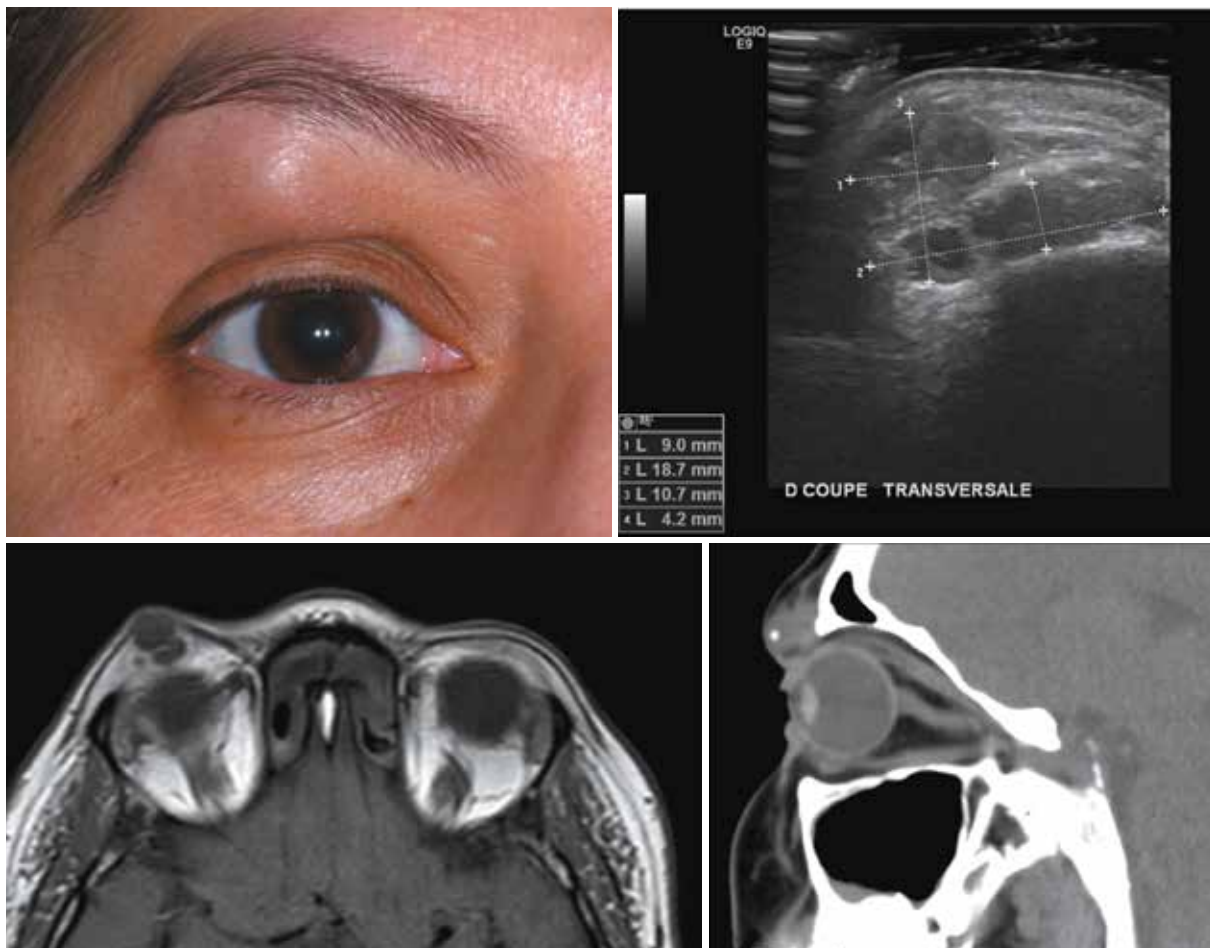
Non-invasive, painless, non-irradiating, it provides a wealth of information on hemodynamics.

Predominant superficial venous malformation complicated with thrombosis



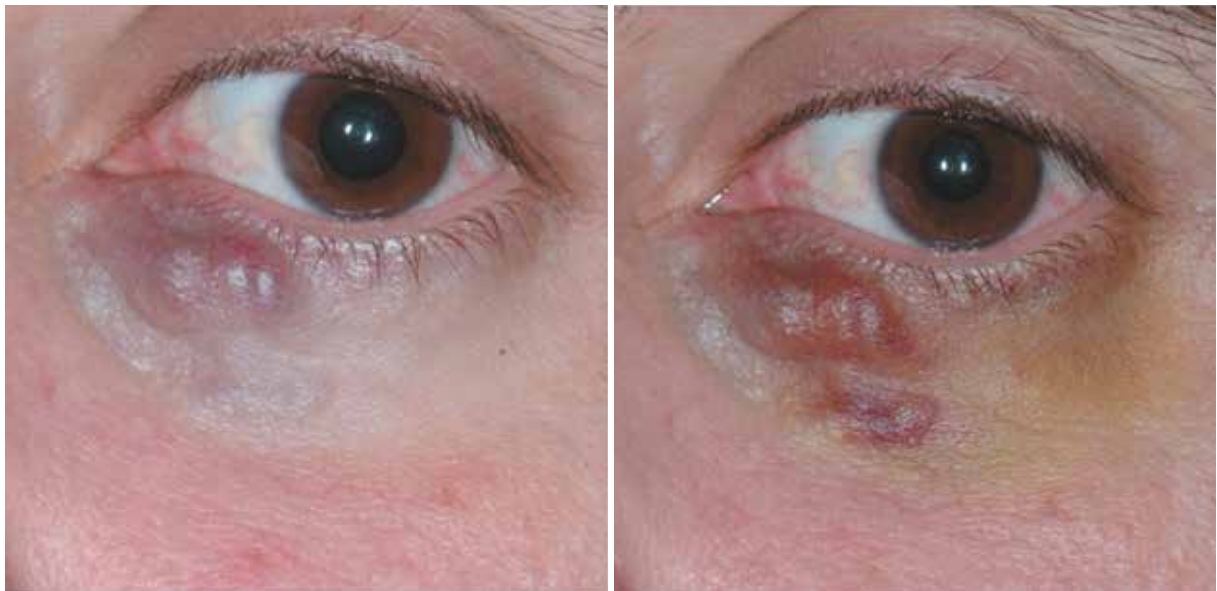
Post-operative result.

Predominant deep vein malformation



An MRI is useful to assess deep extension.
CT scan: presence of phlebolith.

Arteriovenous malformation



Hemorrhagic complication with venous and arterial malformation.

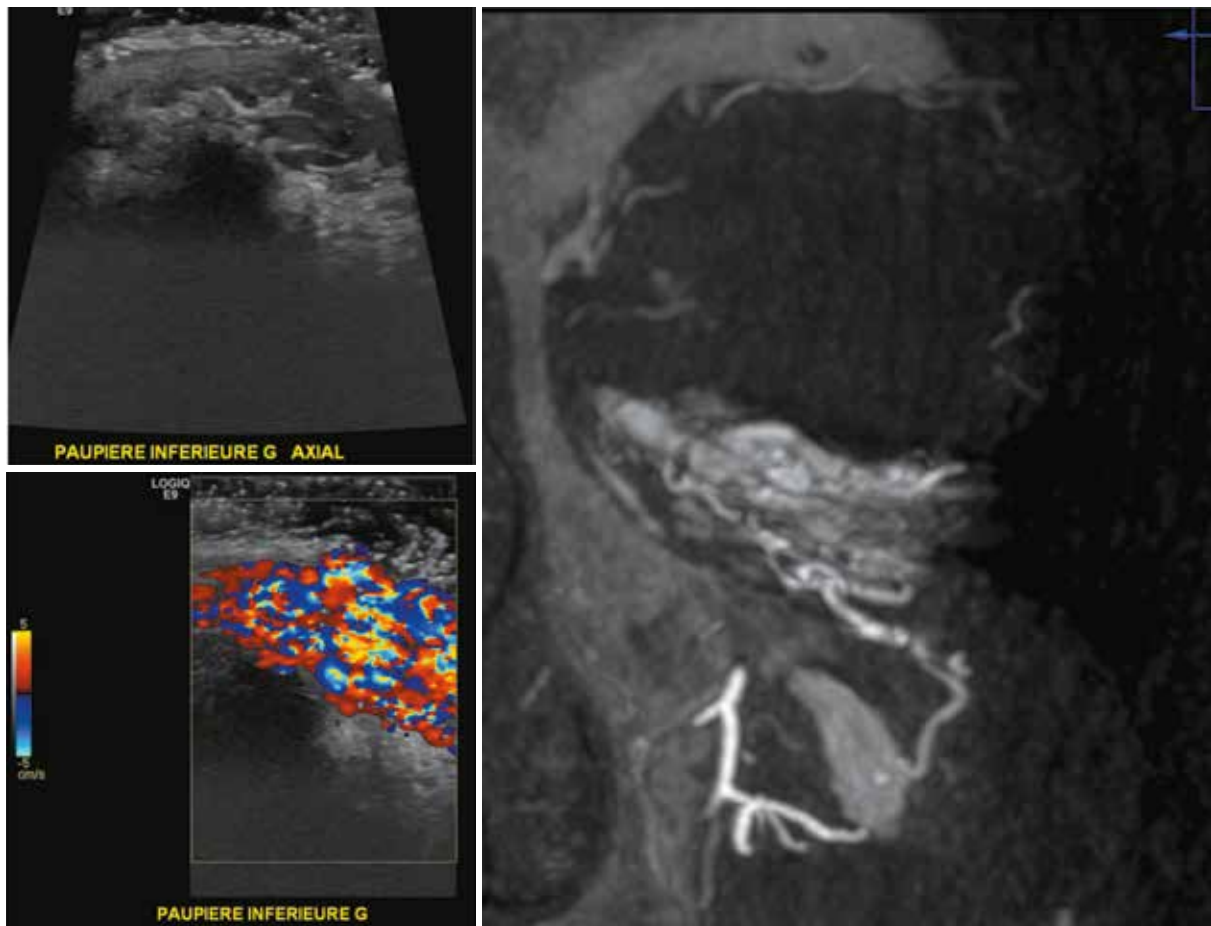
Active hemodynamic lesions, present from birth but rarely visible, often develop after a trauma.

They are hormone-responsive and potentially serious: hemorrhage, necrosis, cardiac involvement for very big forms.

Progression in phases:

1. Dormancy phase: «false flat angioma with thrill»
2. Extensive phase: redness and drainage veins dilated
3. Destruction phase with complication: necrosis, ischemia, hemorrhage
4. Cardiac involvement phase

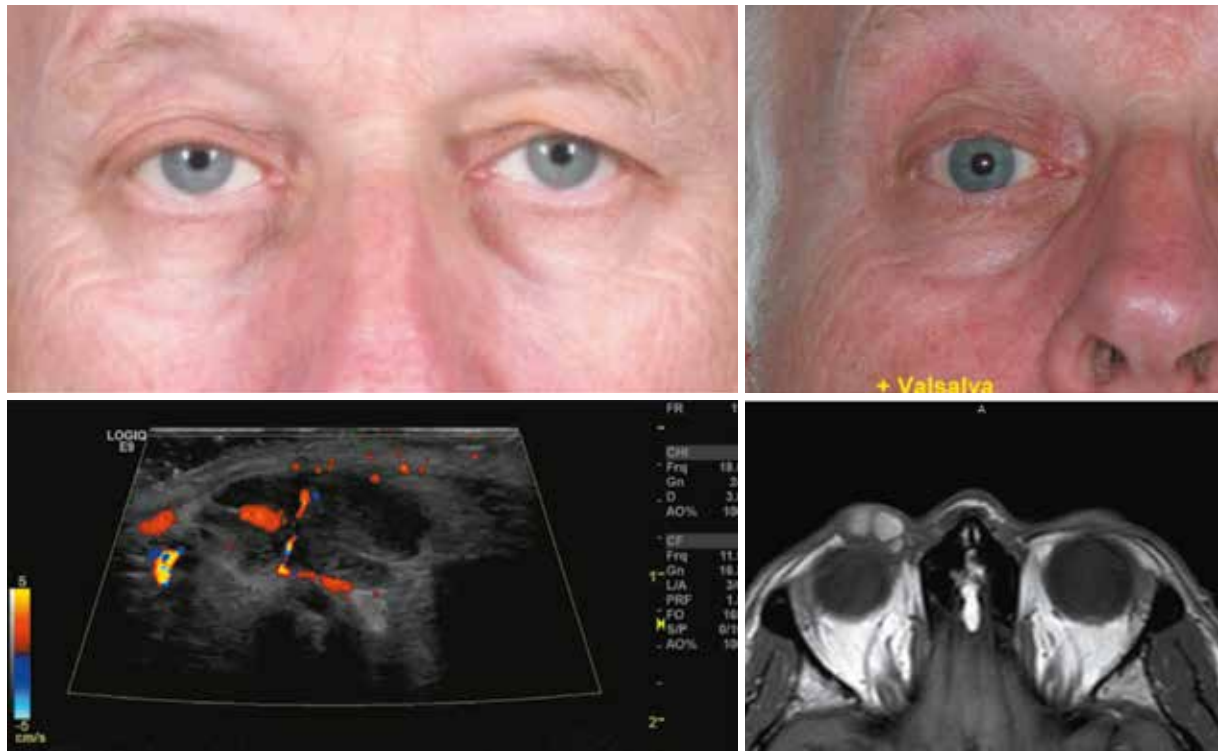
Arteriovenous malformation



Ultrasound and MRI appearance, glomus supplied by a branch of the internal maxillary artery. Hypervascularized nidus on Doppler.

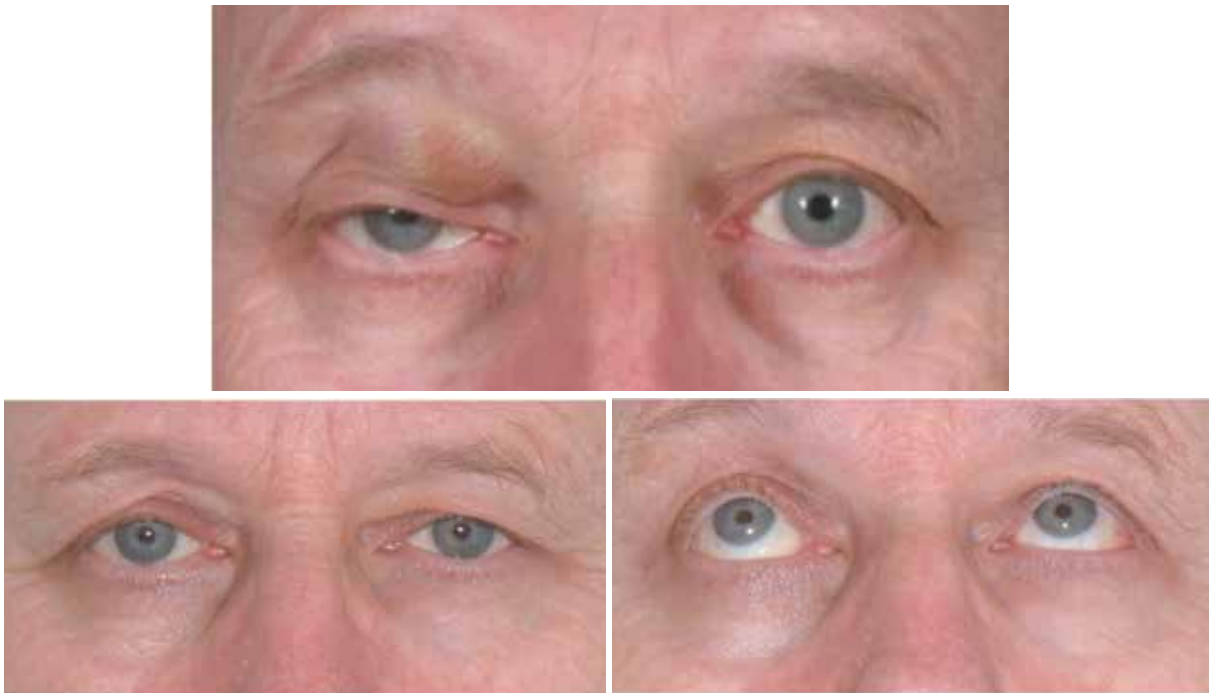Vascular malformations

Arteriovenous malformation



Variation in volume during the Valsalva maneuver.

Arteriovenous malformation



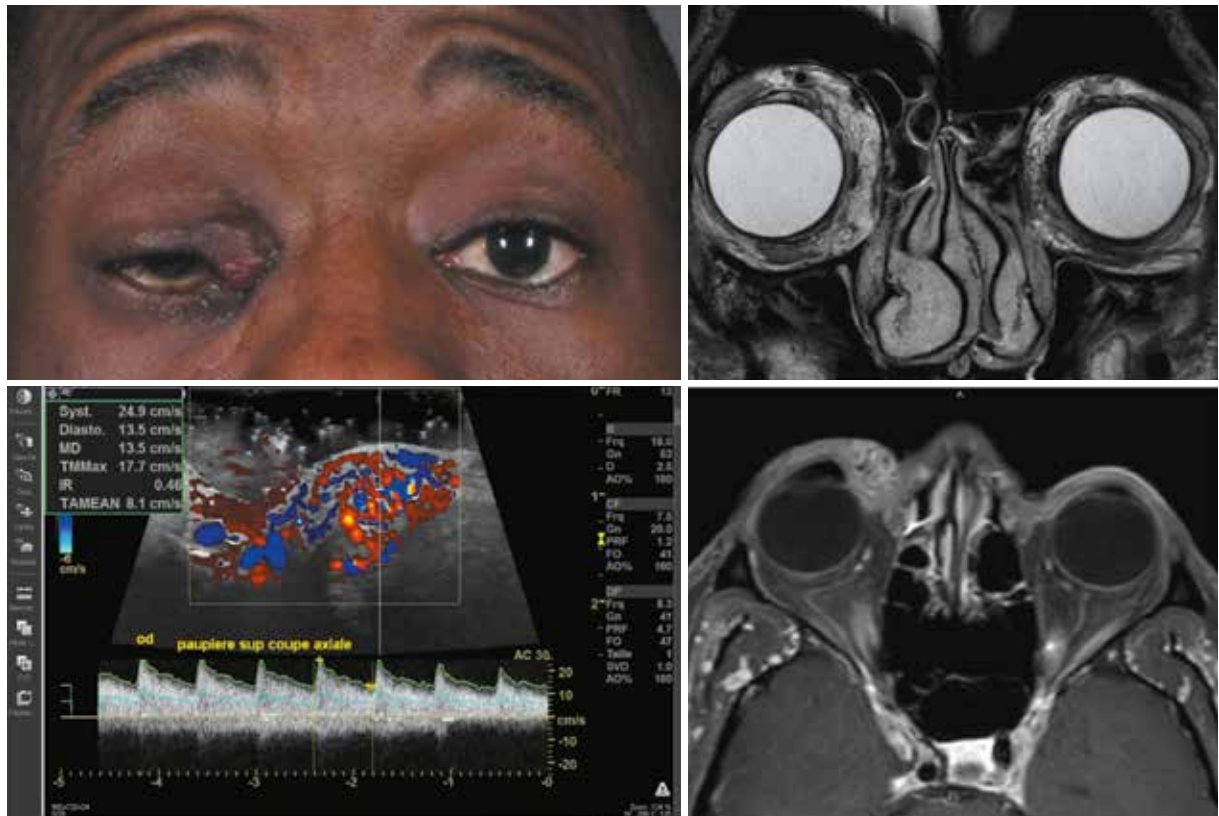
Complicated with thrombosis in CAM.

Post-operative appearance after embolization and surgical excision.

Treatment involves embolization with total surgical excision to limit recurrence.

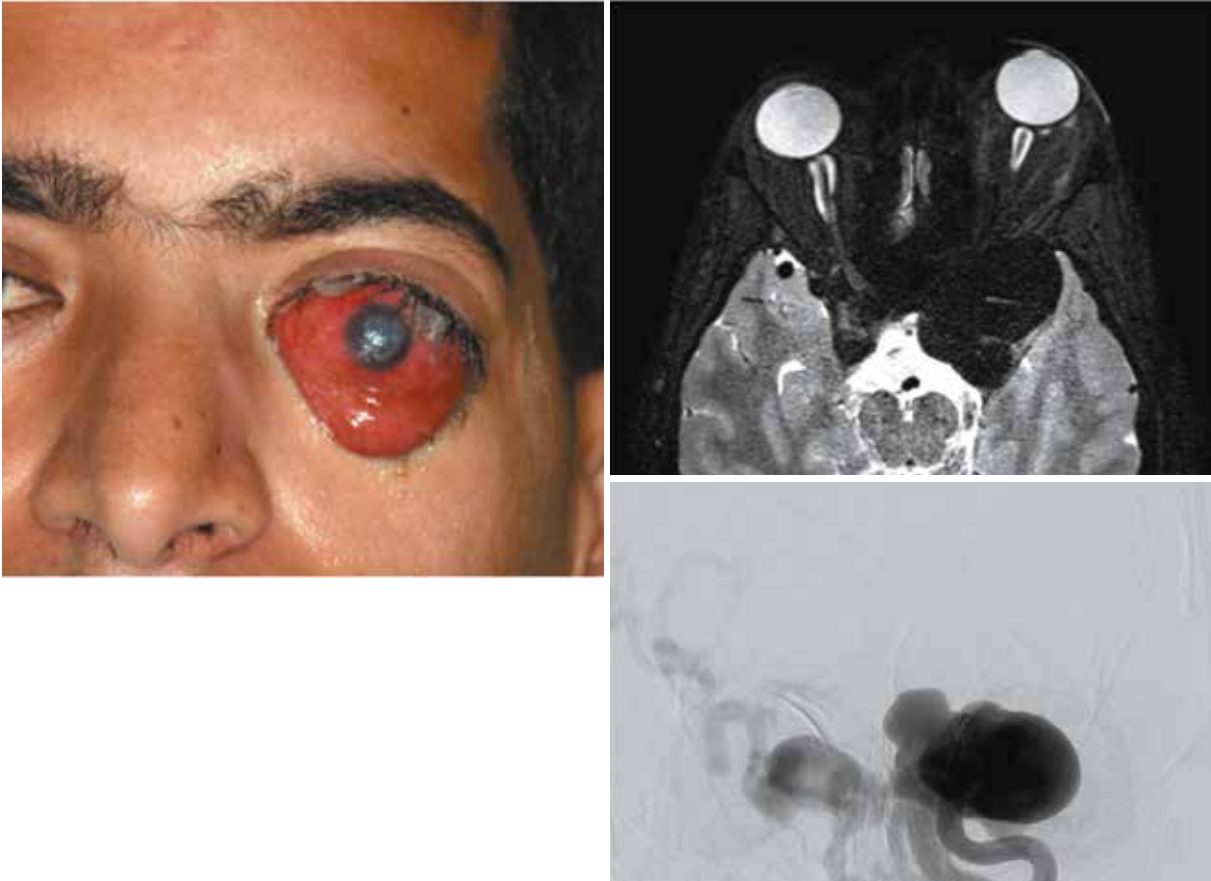Vascular malformations

Predominant arterial malformation



Fast flow with dilation of the superior ophthalmic vein, objectively local hemodynamic involvement.

Direct arteriovenous fistula

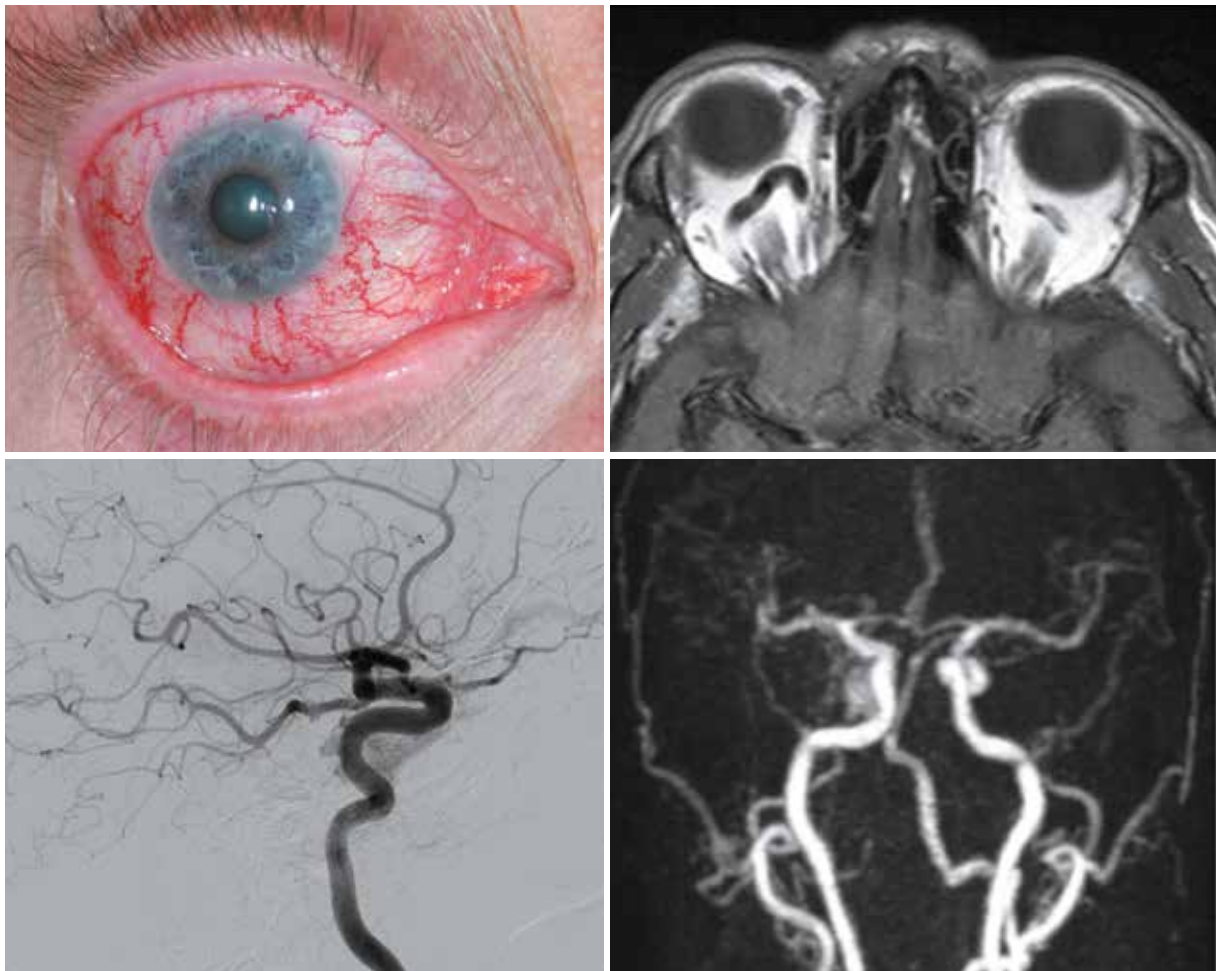


Major exophthalmia with lagophthalmia, loss of ocular mobility.

Dilation of the cavernous sinus on MRI and arteriographic appearance (front view).

Arteriovenous fistula

Indirect arteriovenous fistula



Dilation of episcleral vessels with Caput Medusae appearance.

Dilation of the superior ophthalmic vein and contrast uptake in arterial phase of right cavernous sinus on MRI.

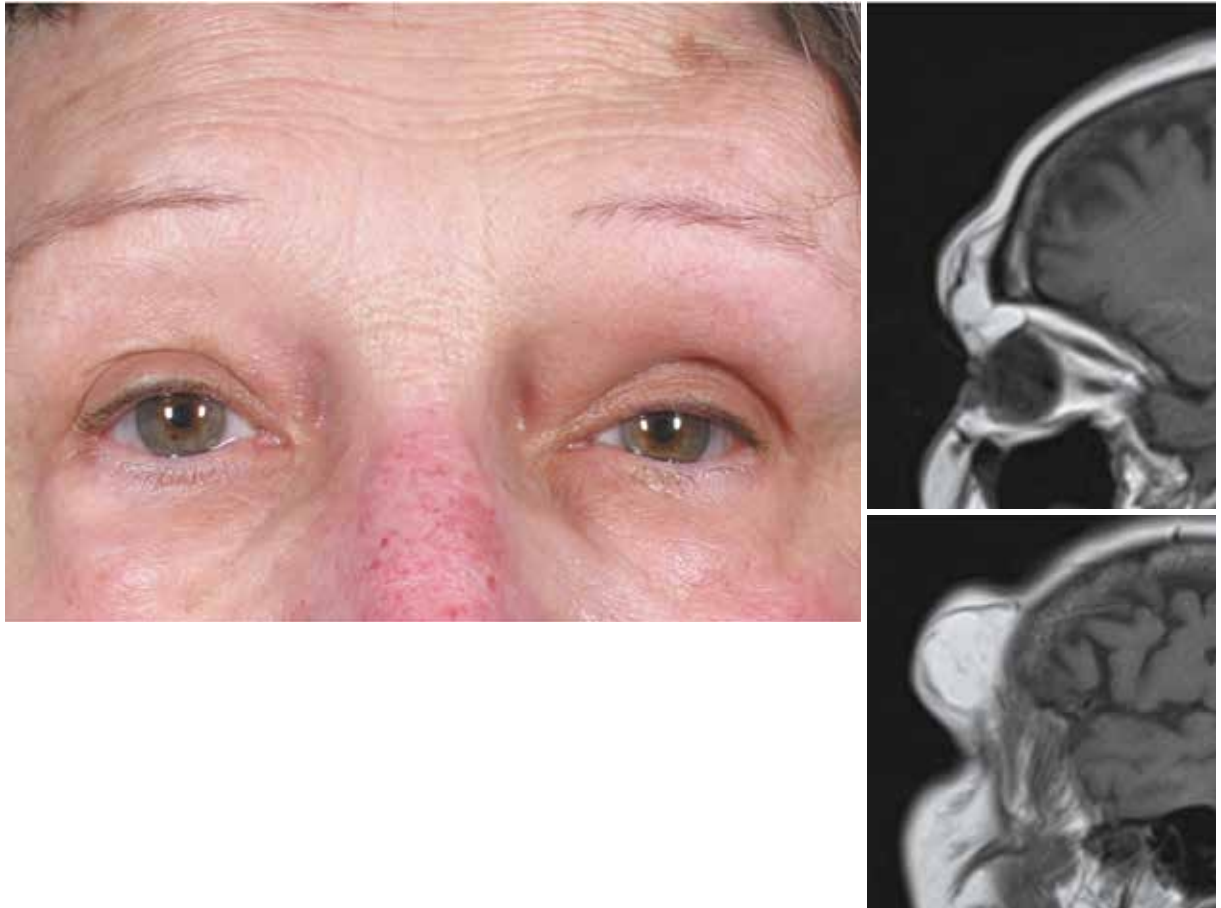
Lateral arteriogram, arterial blush around the internal carotid during passage through cavernous sinus.





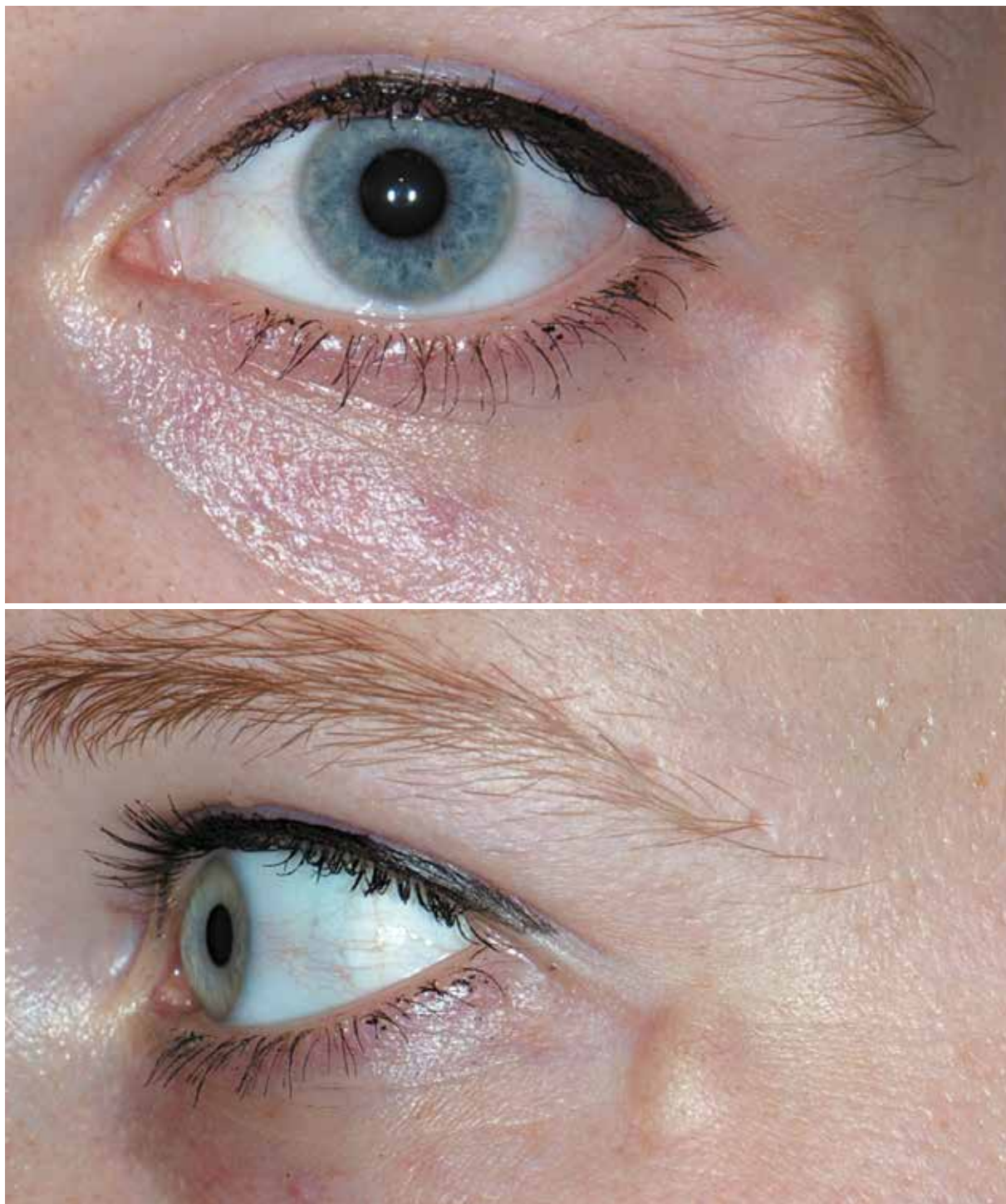6. Fibro-muscular tumors

Lipoma



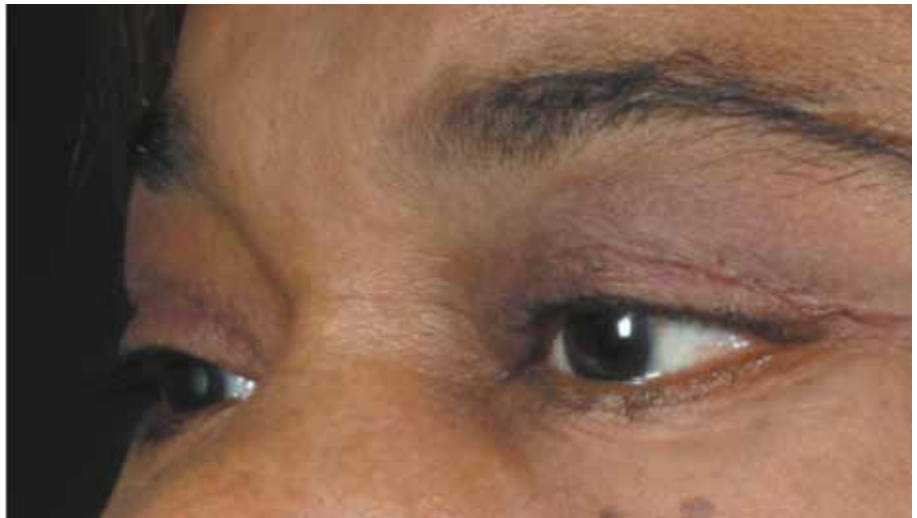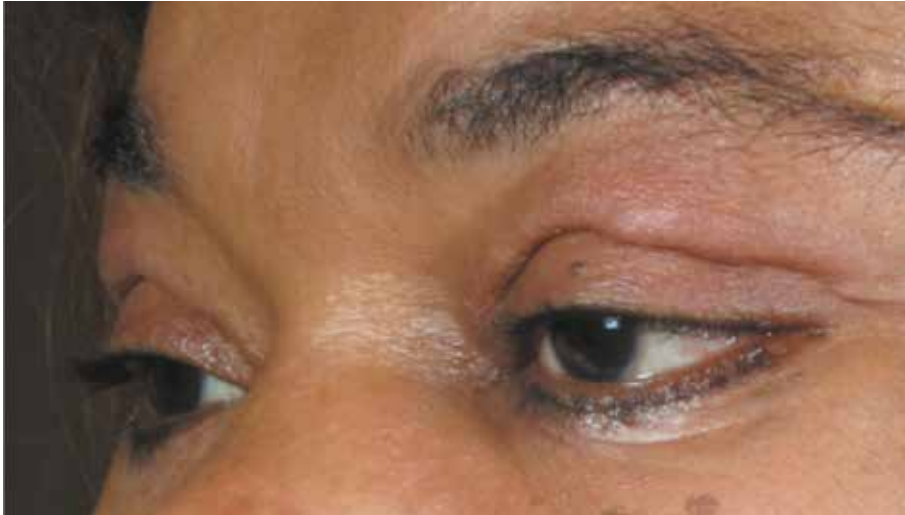Fat cell tumors in subcutaneous connective tissue. The size varies.
Here a frontal lipoma with palpebral and orbital extension.

Lipoma



Lipoma of the outer canthus with visible subcutaneous prominence.
The lesion is soft and mobile on palpation.

Keloid



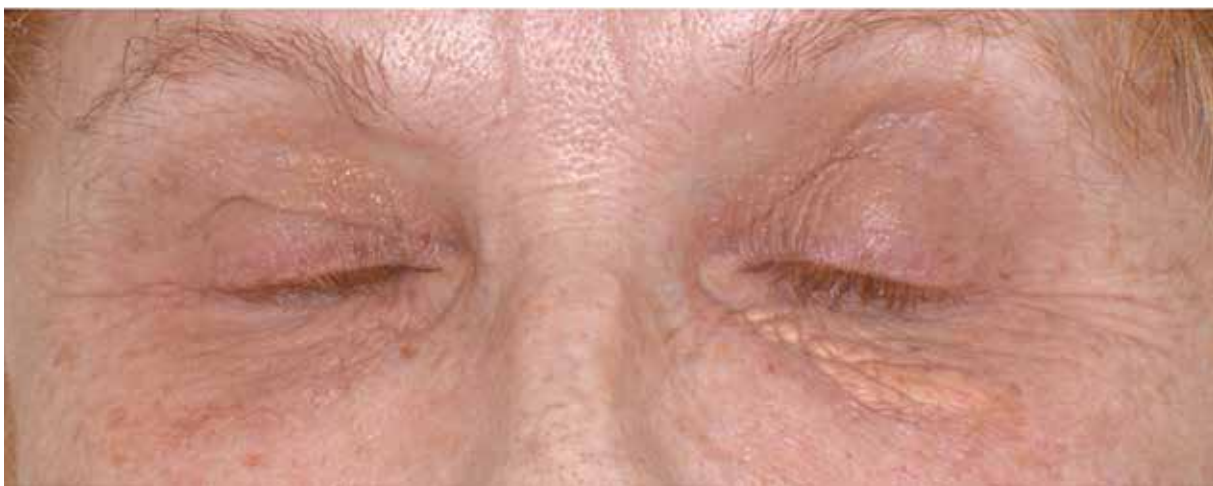Keloid scar on the crow's feet secondary to an upper blepharoplasty.

Keloid scars correspond to hypertrophic healing of the dermis with proliferation of fibroblasts and excessive secretion of collagen tissue. On palpation, the presence of a smooth hypertrophic nodule is observed, which may initially be inflammatory. Spontaneous regression is rare. Treatment consists in surgical excision combined with adjuvant therapies to limit recurrence. The appearance of a keloid scar on the eyelid is very rare due to the thinness of the palpebral skin.

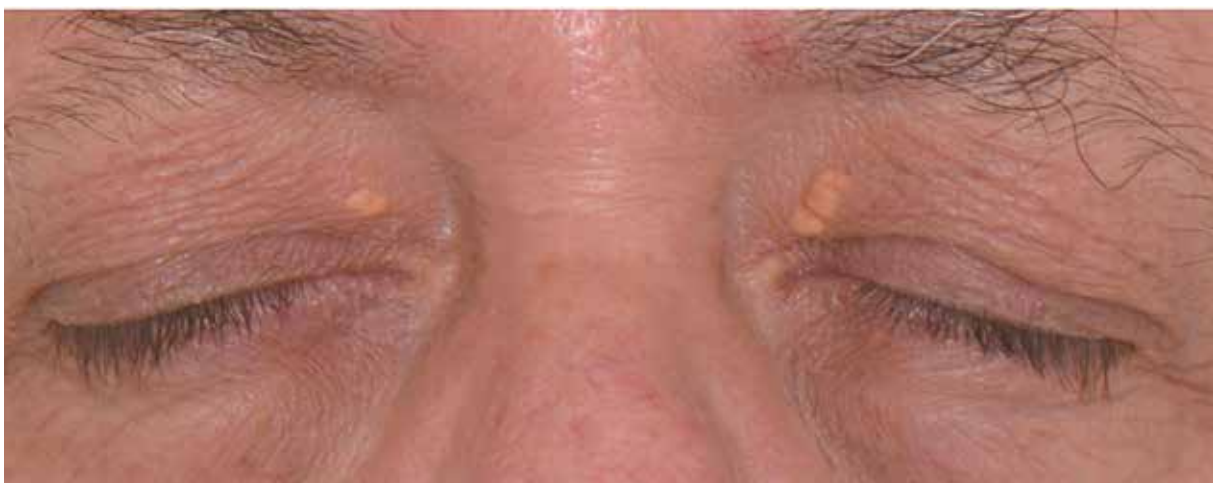Xanthelasma

Due to the thinness of the skin, palpebral deposits are visible with the presence of confluent yellowish layers with defined edges and gradual growth.

Dyslipidemia screening is systematic notably with type IIA and in 50% of cases no biological hypercholesterolemia is found.

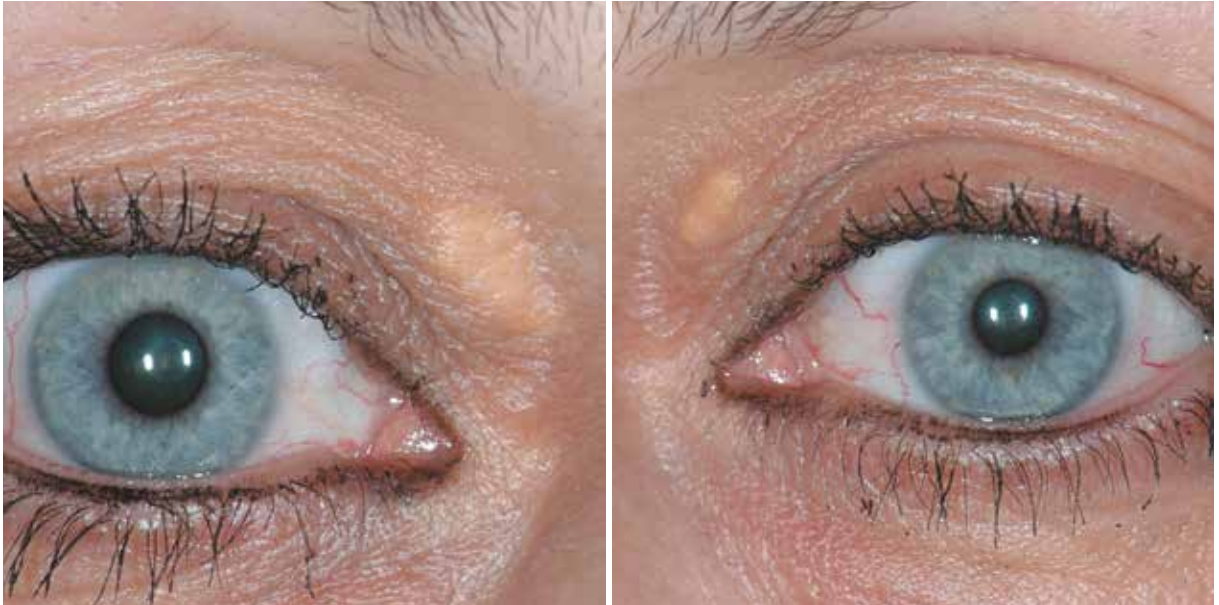

Plaque xanthelasma restricted to the lower left eyelid.

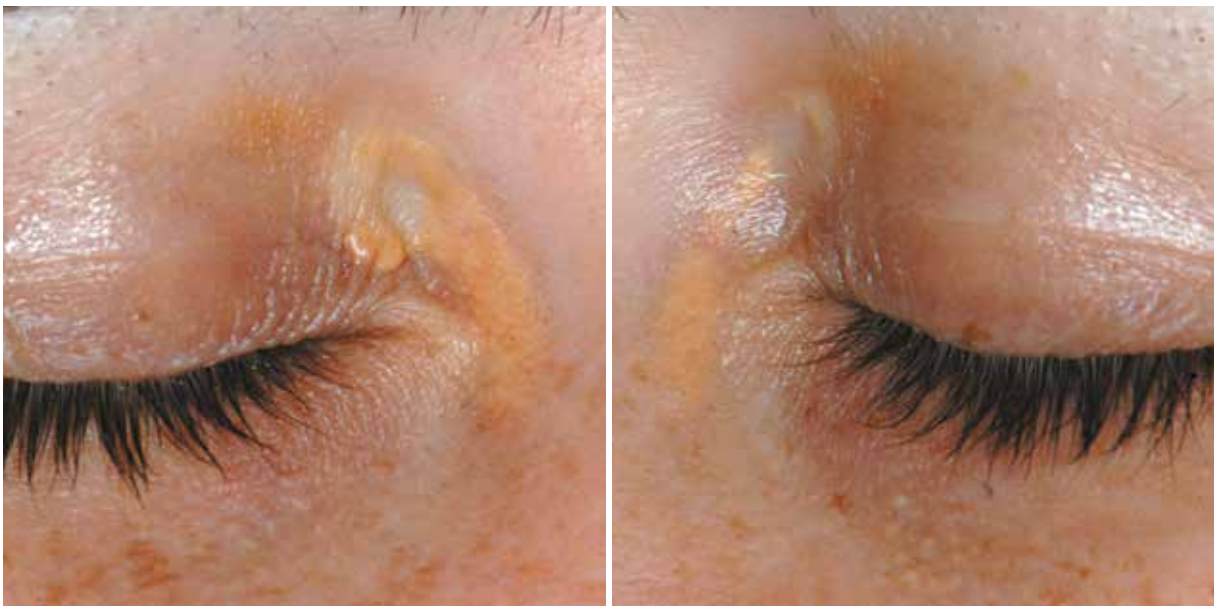

Initial raised punctiform lesions on the inner canthus of the upper eyelids.

Xanthelasma

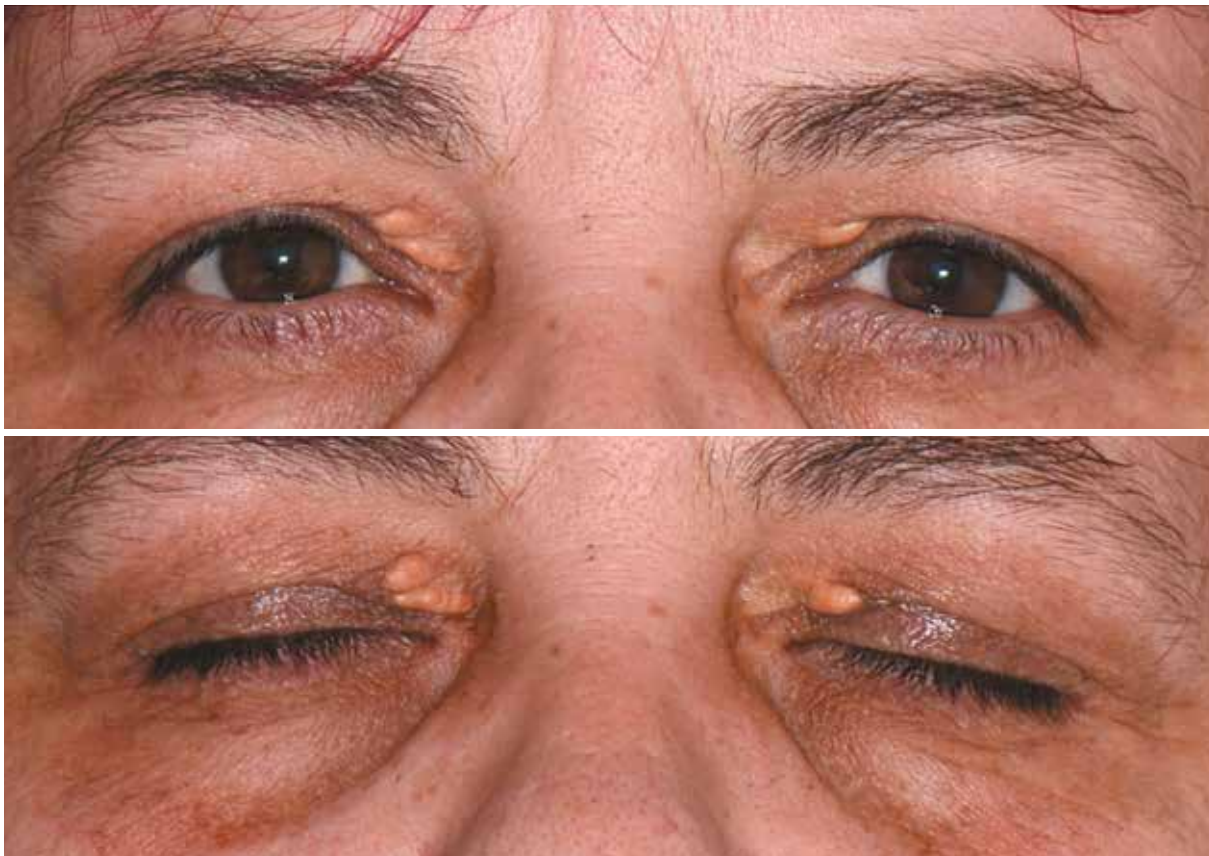

Lesion increasing in size. When the deposit is the same color as the skin, it is barely visible.



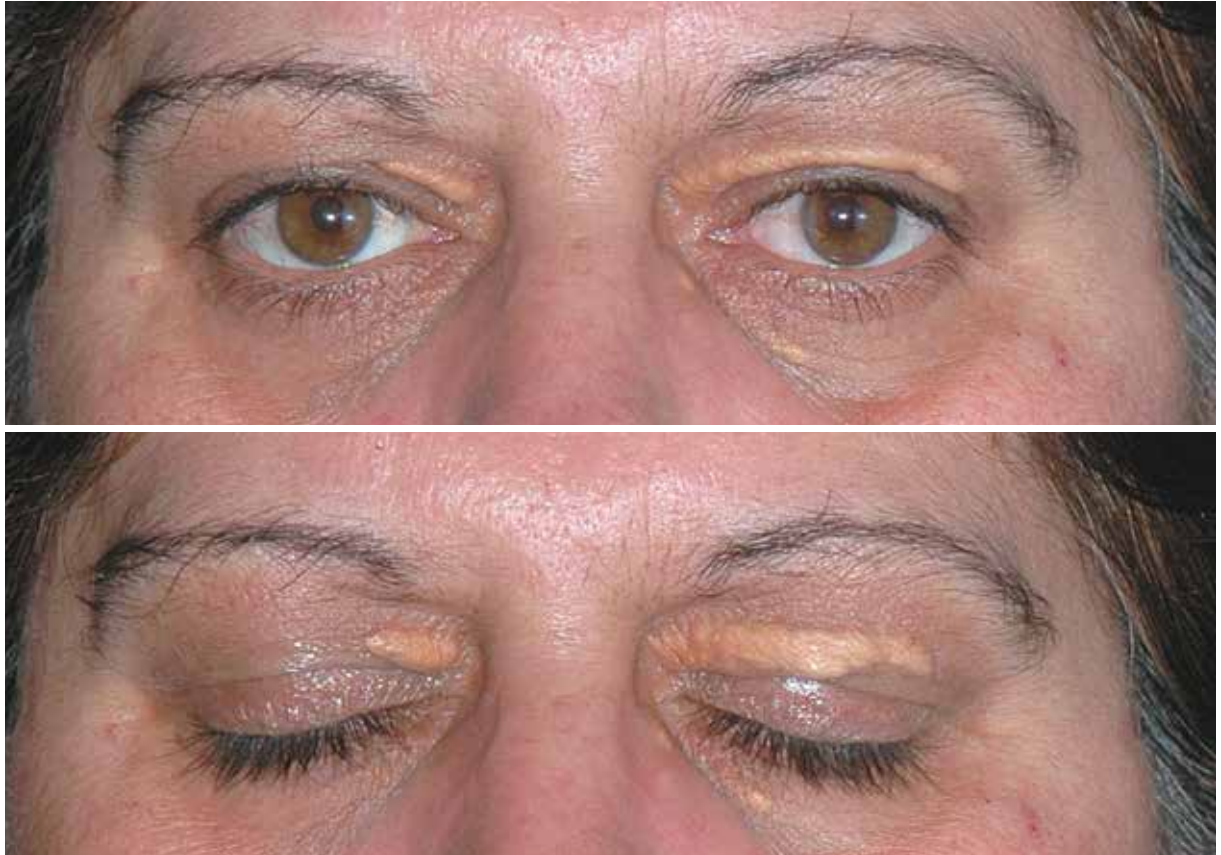The patient received laser treatment with hypo-pigmentation and now presents a recurrence of the xanthelasma. The concomitant scar and recurrence of xanthelasma can be observed.

Xanthelasma

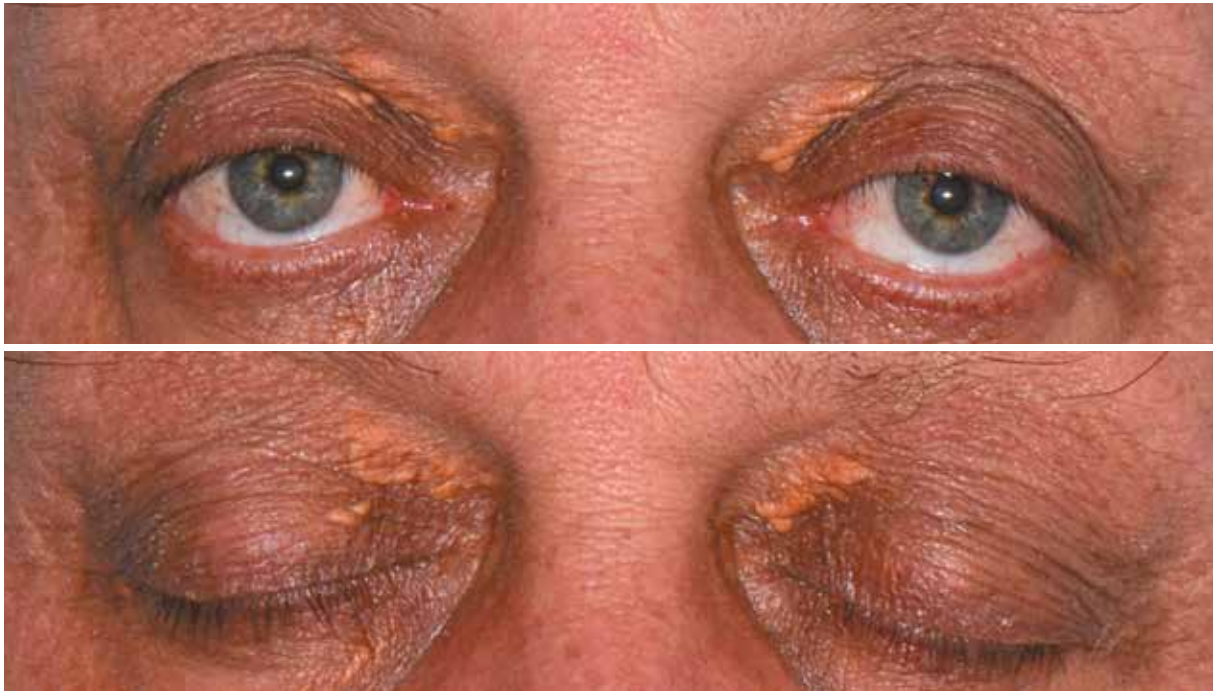

On a pigmented dark circle, the yellowish deposits are even more visible.

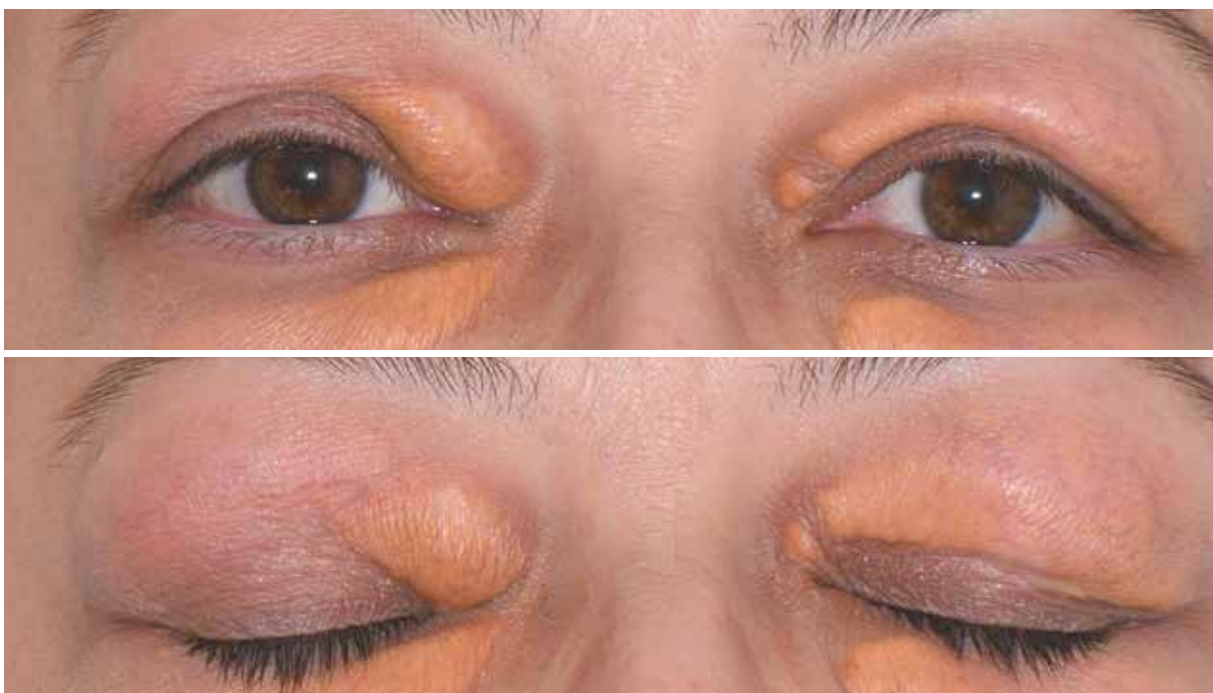Xanthelasma



Xanthelasma

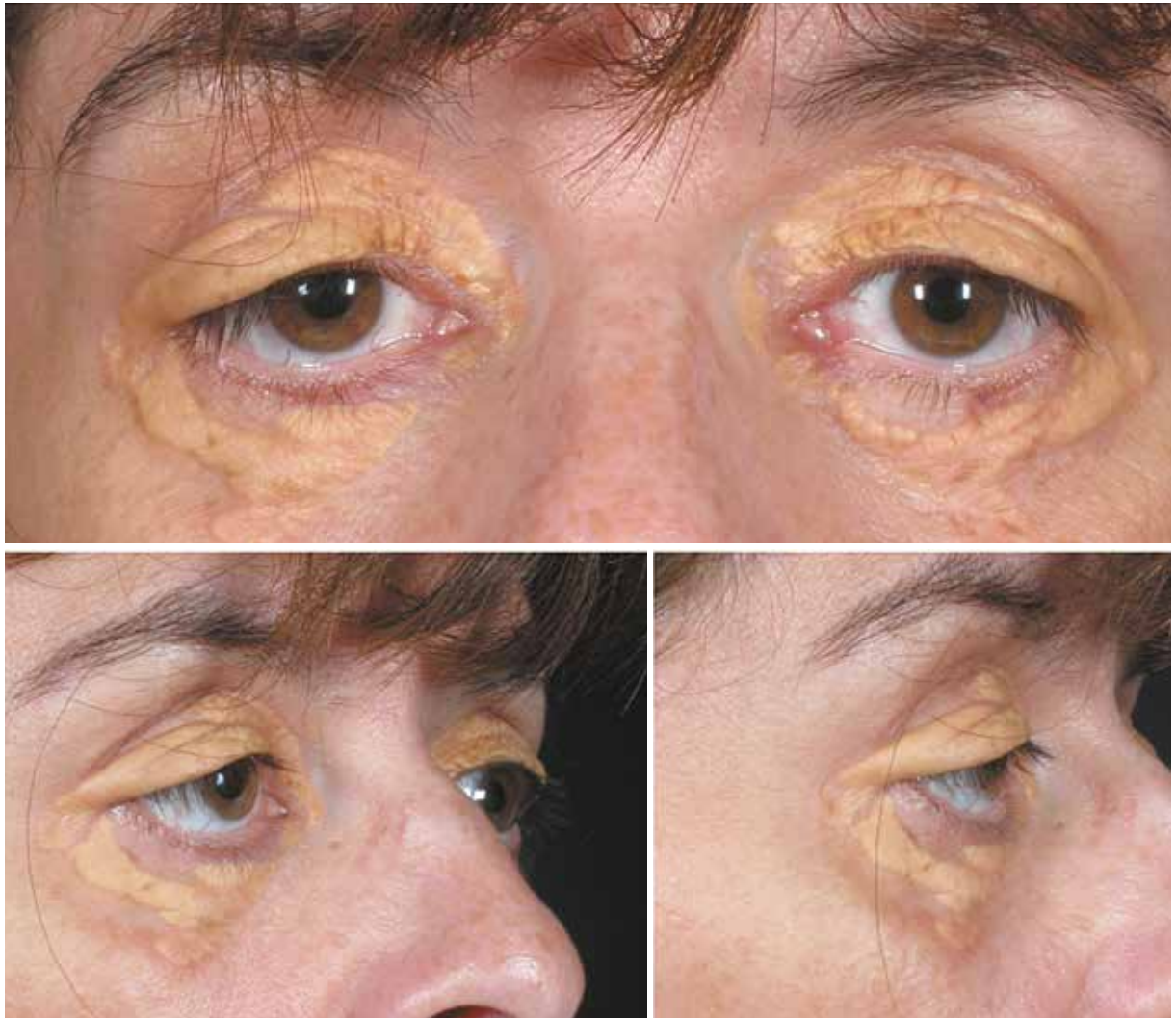

Flat punctiform xanthelasma on the 4 eyelids.



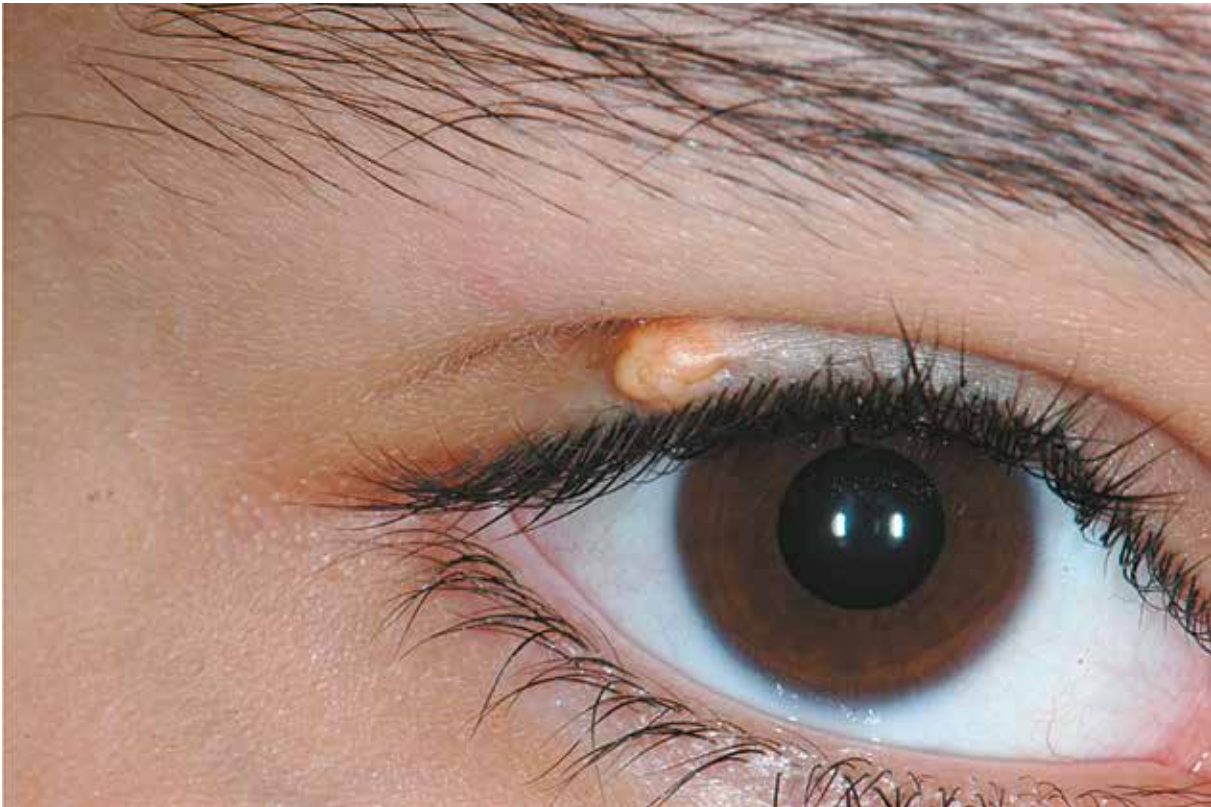
Raised, swollen xanthelasma on the 4 eyelids.

Xanthelasma



Flat, extensive xanthelasmas on the 4 eyelids like glasses.

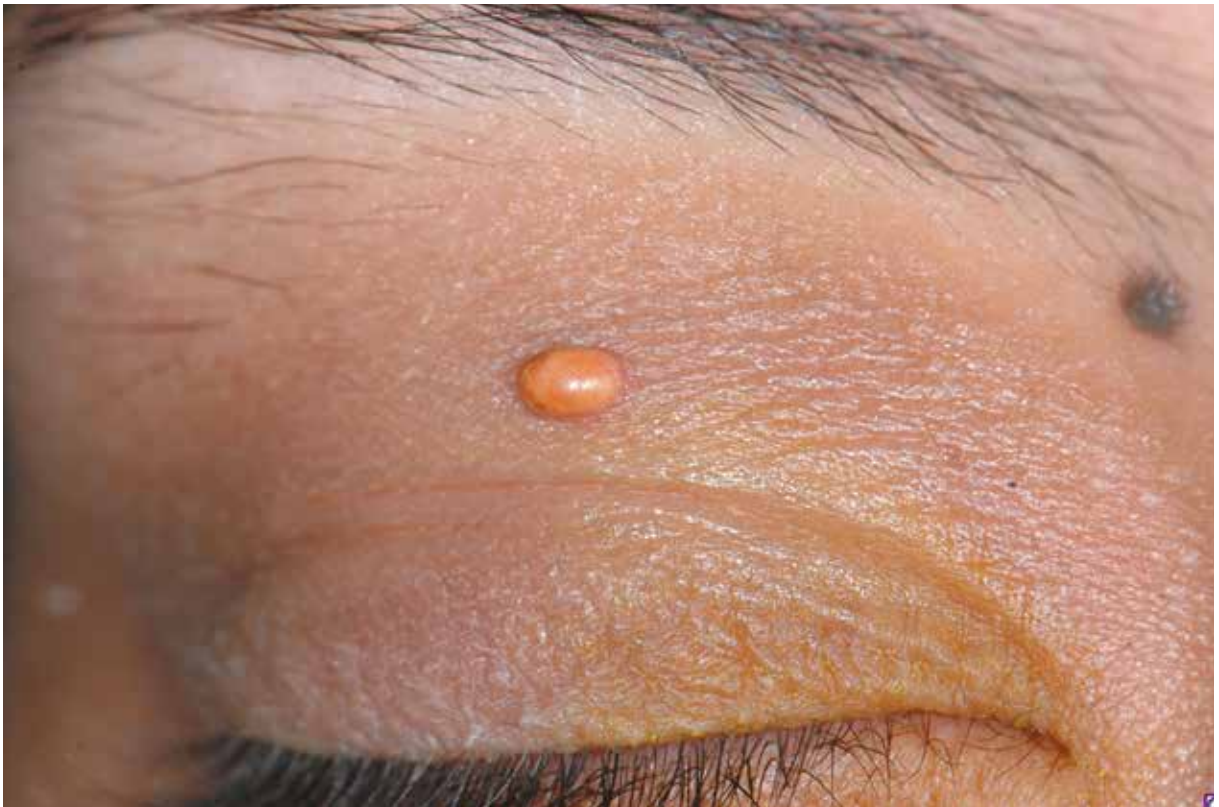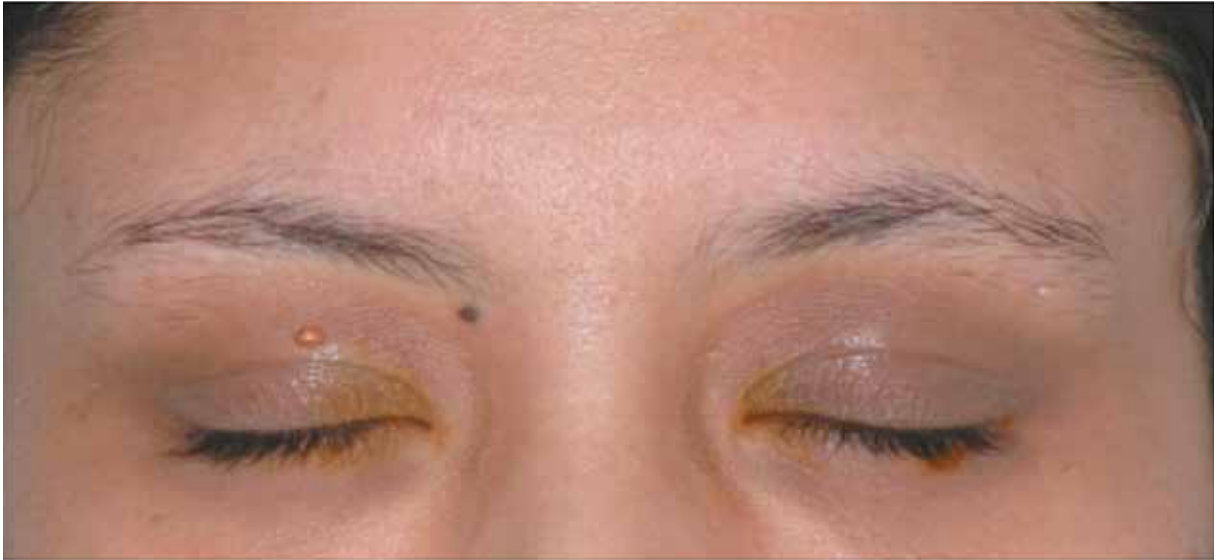Juvenile Xanthogranuloma



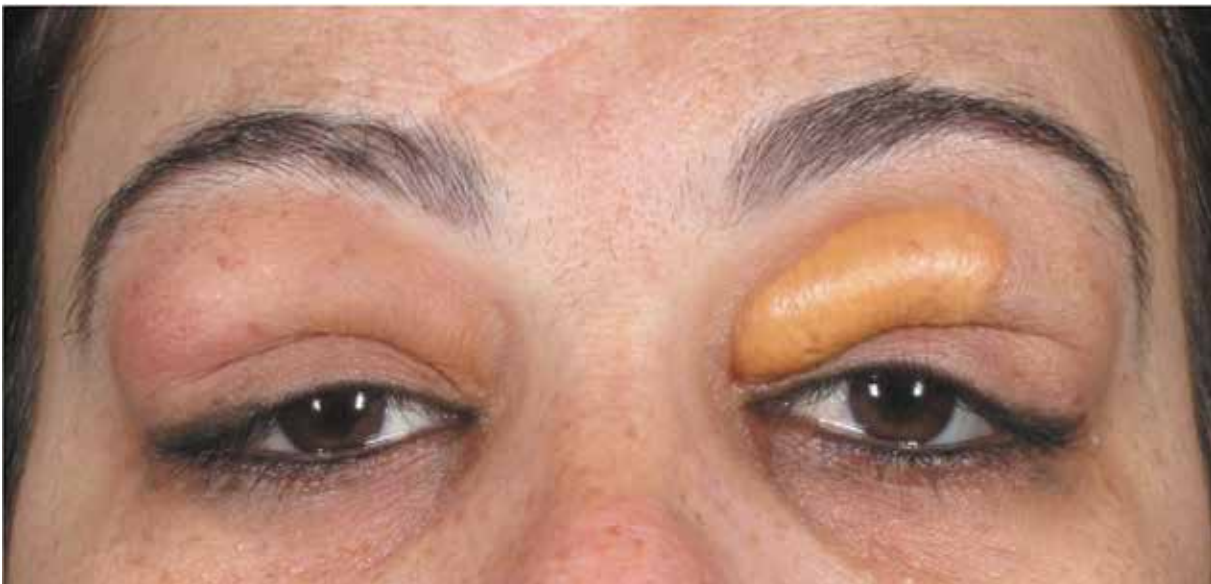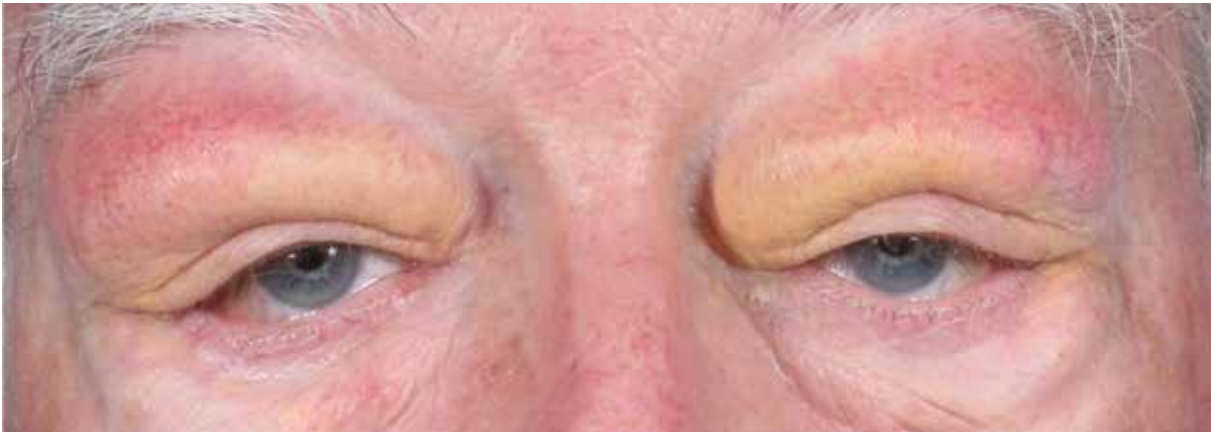Juvenile xanthogranuloma is a benign non-Langerhans cell histiocytosis occurring as smooth, firm papules.

It is an accumulation of lipid-rich macrophages in young subjects.
Ocular involvement is rare.

Punctiform xanthogranuloma



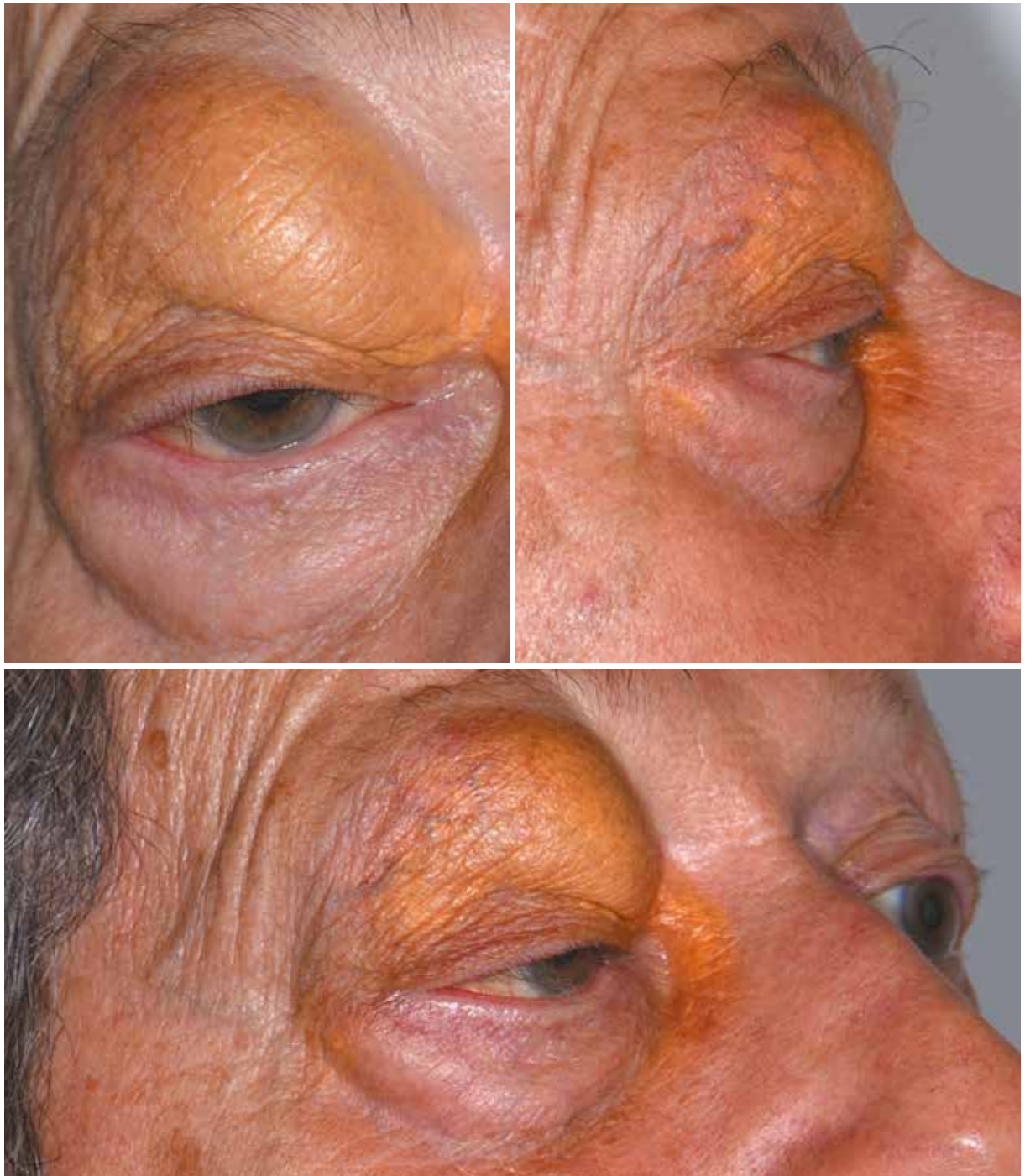
Xanthogranulomatosis



Xanthogranulomatosis is a rare condition. It is a non-Langerhans cell histiocytosis often associated with a monoclonal gammopathy.

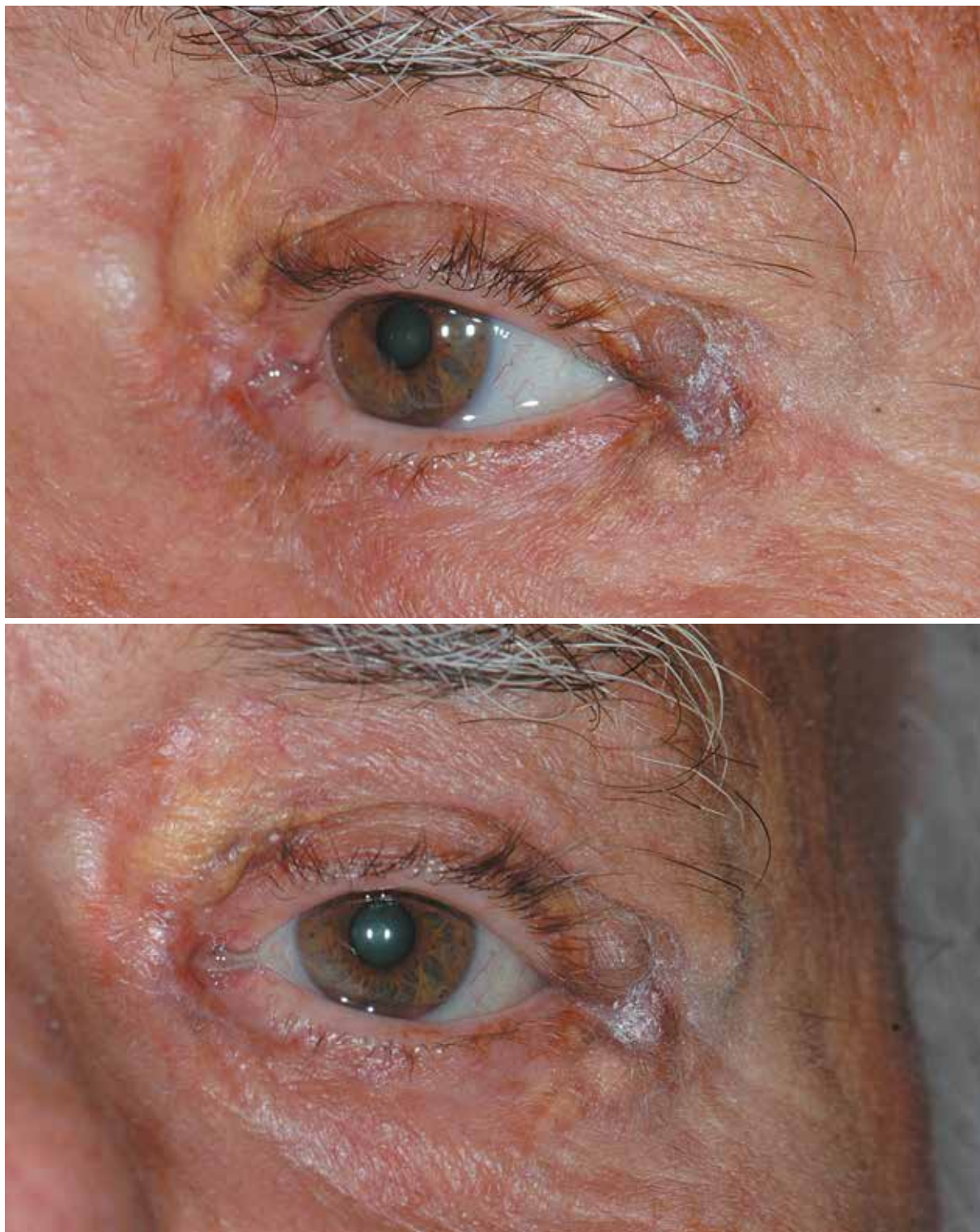The diagnosis is based on a histological examination and treatment is initiated in collaboration with an internist. Contrary to xanthelasma, deep palpebral and orbital infiltration is observed.

Xanthogranulomatosis



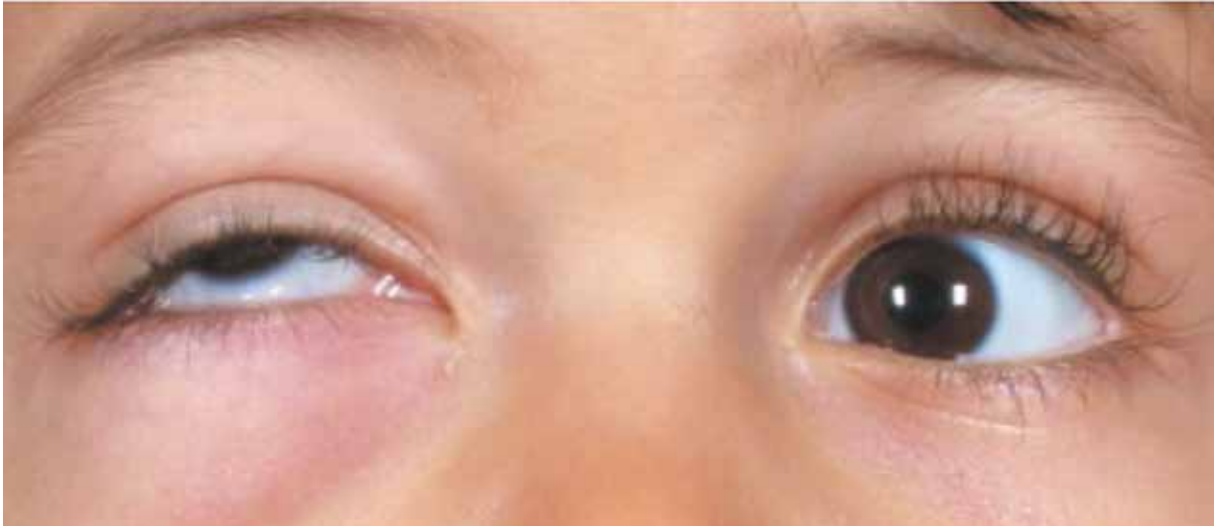Xanthogranulomatosis of the upper eyelid with cutaneous and sub-cutaneous involvement creating an upper palpebral mass.

Xanthogranulomatosis



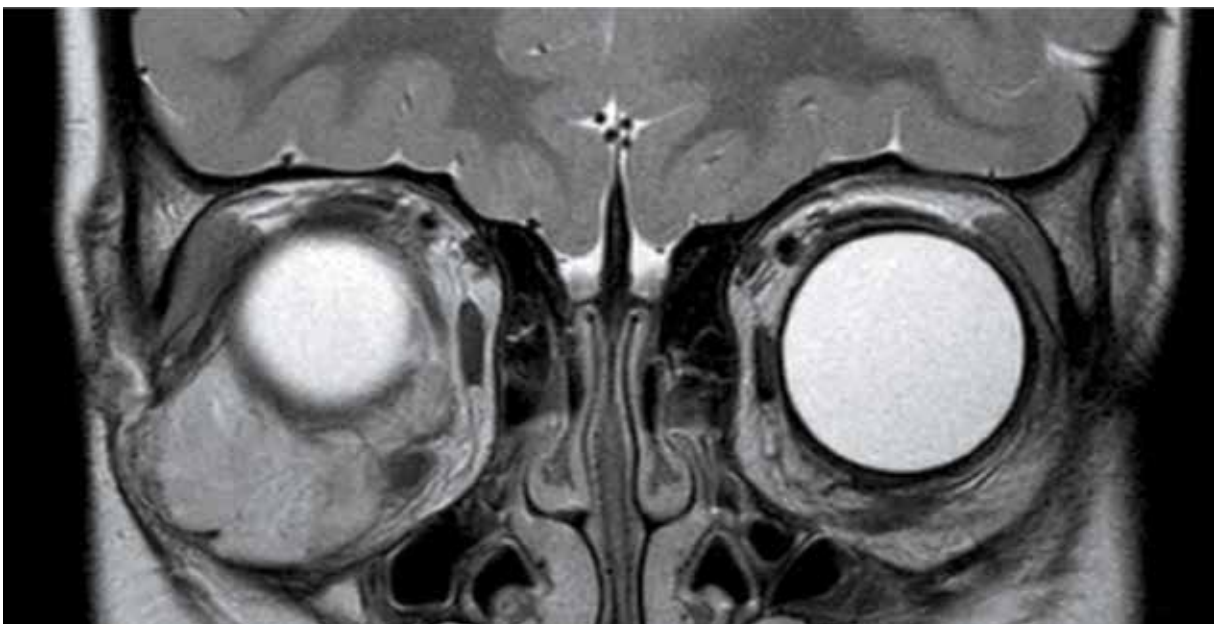
Planar xanthogranulomatosis with no deep invasion.

Rhabdomyosarcoma



It is a malignant tumor that develops within the striated muscles. There are two histological types: embryonic (the most common) and alveolar.

The diagnosis must be suspected with any rapidly progressing tumor in a child. The prognosis depends on how quickly the chemotherapy and/or radiotherapy is initiated.
Lower right palpebral swelling, infiltrating the orbit and causing orbital dystopia.



Kaposi sarcoma with multiple involvements

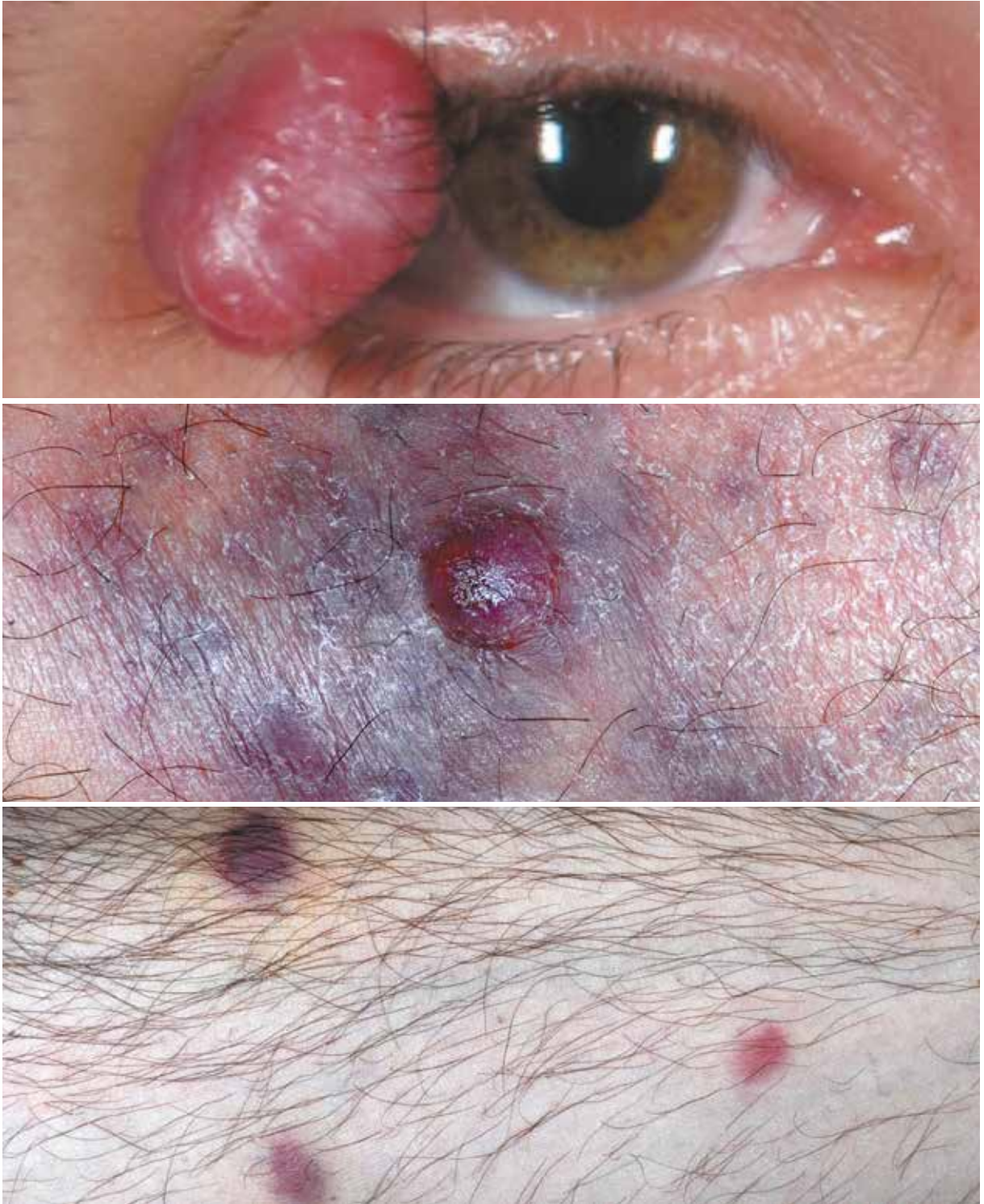Multisystemic involvement is concomitant and characteristic of this pathology.

Kaposi sarcoma usually develops in the skin and mucosa. The distinctive characteristic of this sarcoma is the possibility of several organs being involved at the same time.

There are 4 main types:

- Kaposi sarcoma linked to AIDS (epidemic Kaposi sarcoma)
- Classical Kaposi sarcoma, which is very rare and can subsequently lead to a lymphoma
- Kaposi sarcoma in transplant patients linked to long-term immunosuppressive therapy
- African Kaposi sarcoma (endemic), which most often affects children

Kaposi sarcoma with multiple conditions

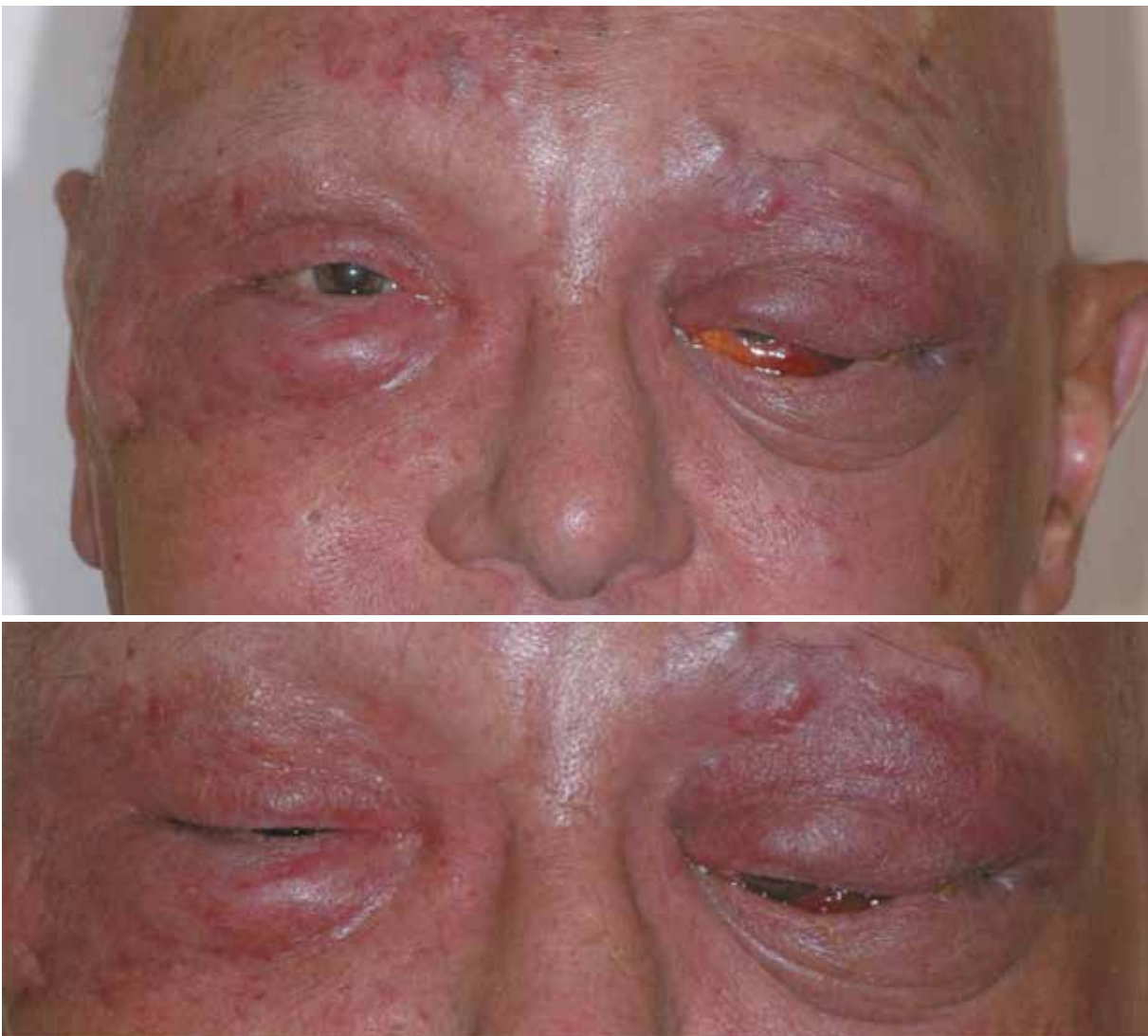

Kaposi sarcoma linked to AIDS with multi-systemic involvement: located on the palpebra and forearms. Concomitant flat and tumoral appearance can be observed.

Cutaneous and palpebral fibrosarcoma

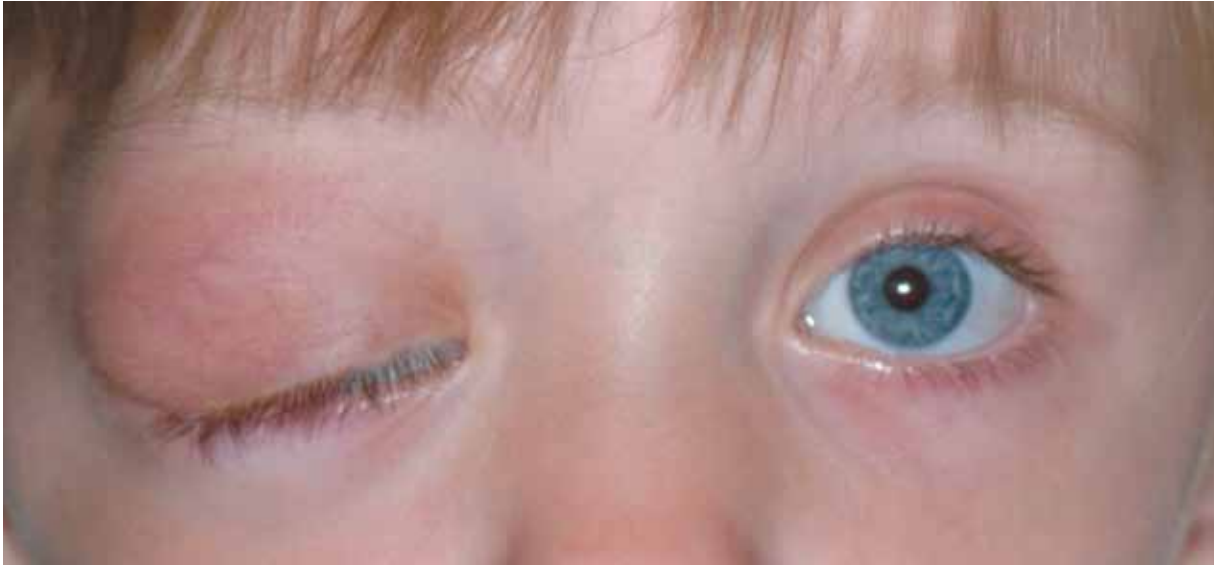Rare, slow growing cutaneous tumor.

First line treatment is surgical excision, which will be easier the earlier the diagnosis. It is an indolent lesion pink to dark red in color that progresses gradually and is characterized by cutaneous thickening that can ulcerate. Metastasis is rare, in less than 5% of cases.



Widespread on the face and affecting the forehead, the four eyelids, and left orbital invasion. Being so widespread makes surgical excision impossible.

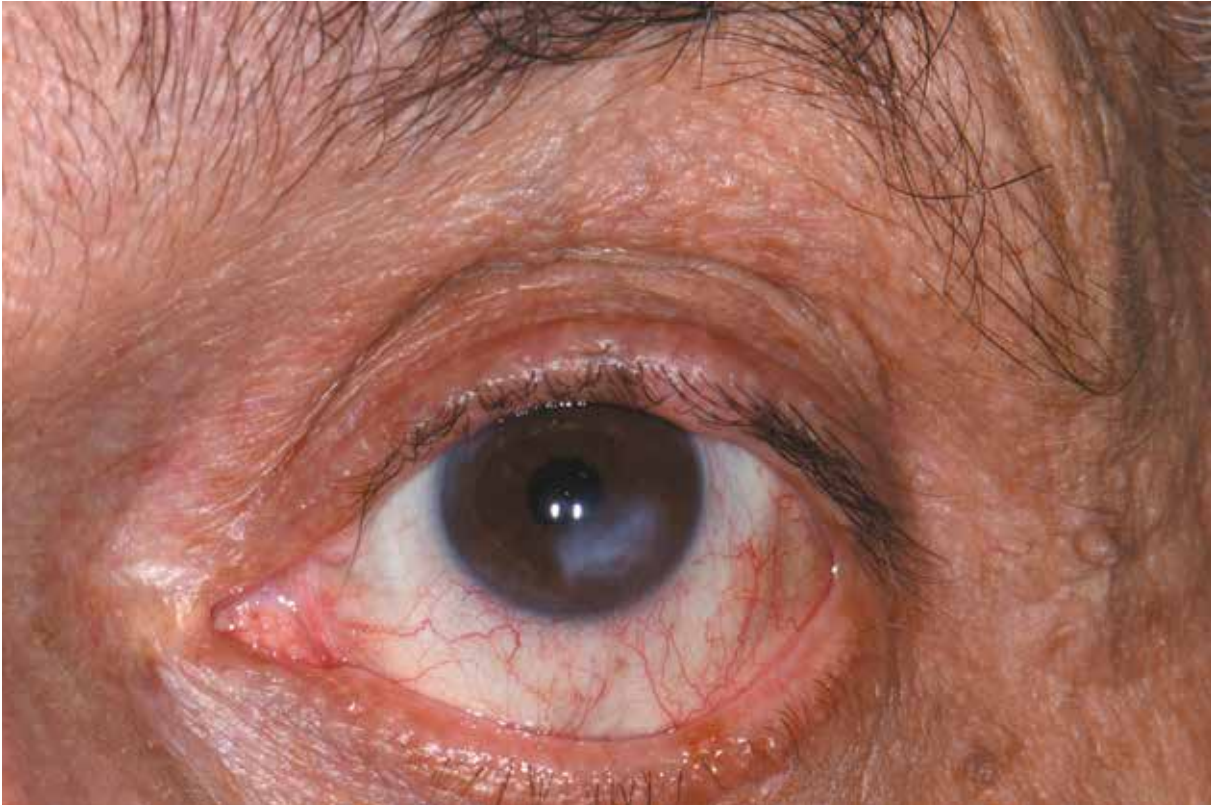Plexiform neuroma



Plexiform neuroma is observed in 50% of cases of type 1 neurofibromatosis.

Growing lesion progressing in stages especially during childhood and infiltrating all the tissues. Repeated surgical excision, often incomplete due to the absence of dissection plane linked to the deep diffuse infiltration.

Neurofibroma



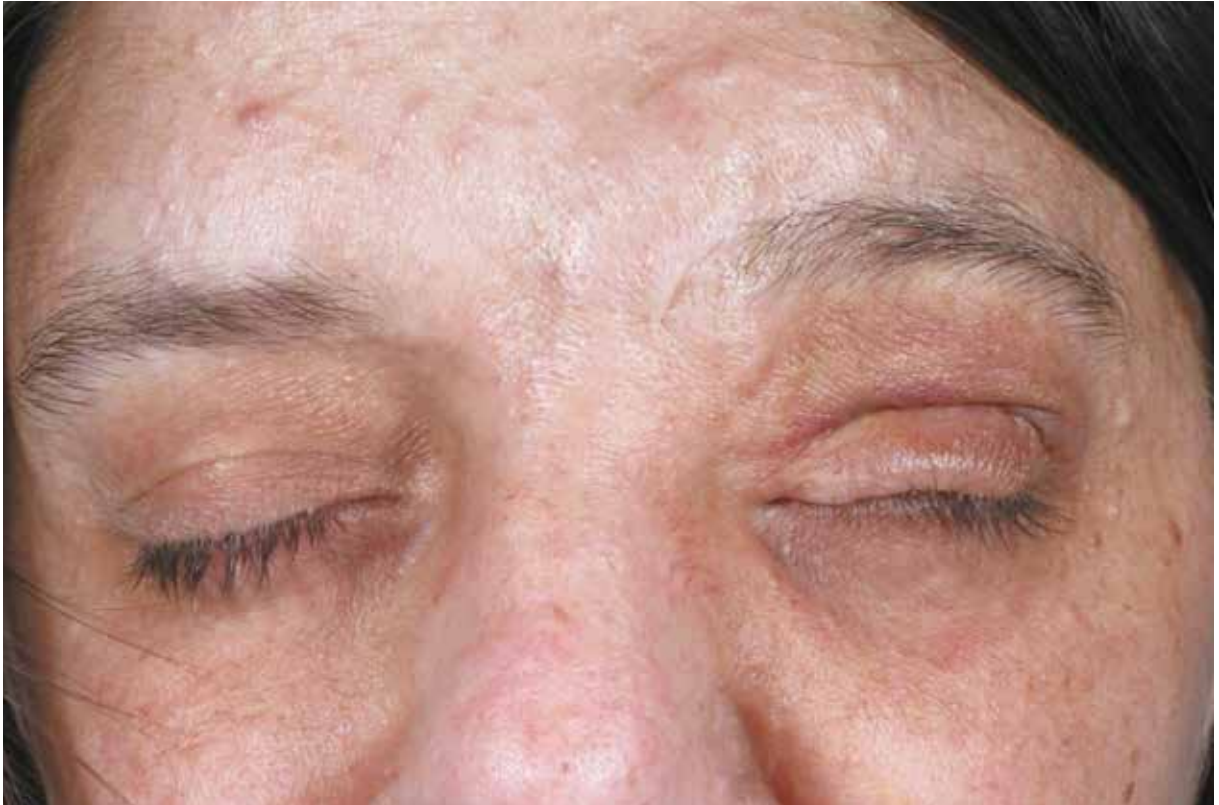Presence of a neurofibroma on the free margin of the upper left eyelid.

Cutaneous symptoms of type I neurofibromatosis are light brown spots that can be present from birth, lenticular spots, but also flesh-colored cutaneous or sub-cutaneous neurofibromas.

They are soft, rare in childhood and develop later.

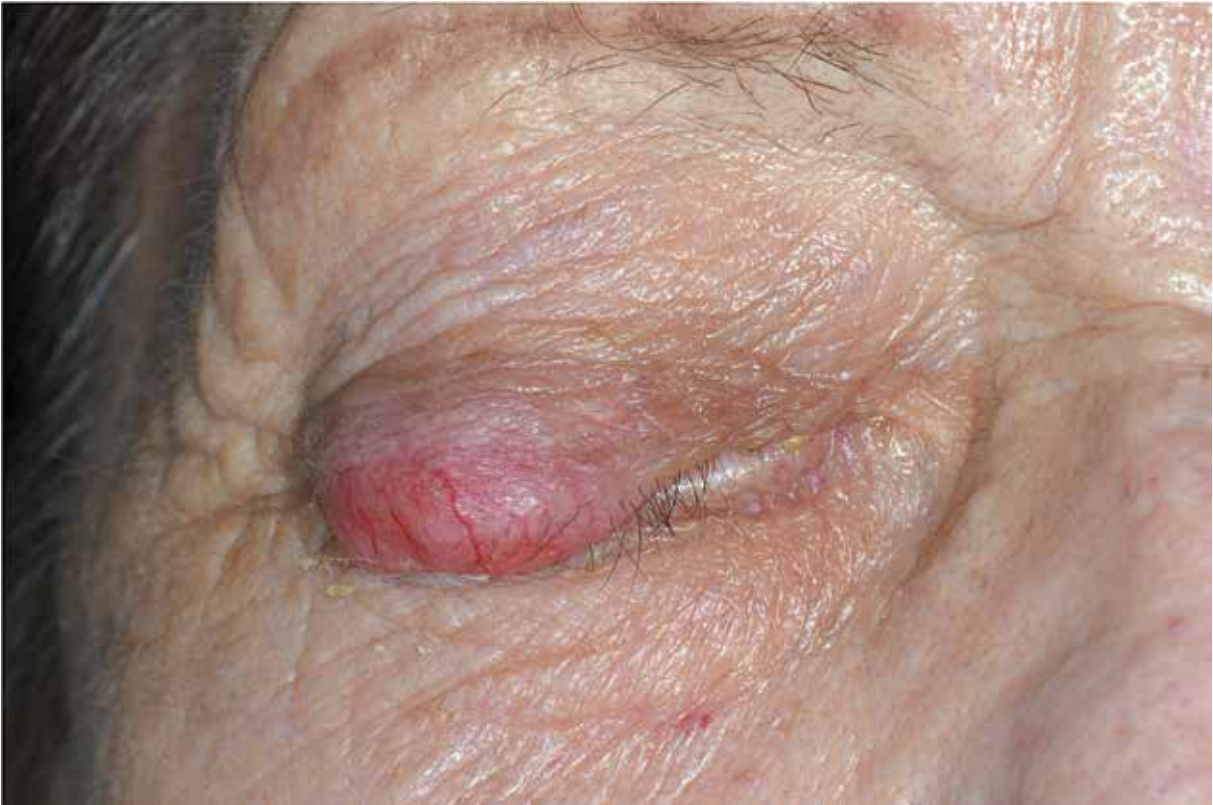There is no risk of malignant transformation, whereas transformation can occur with subcutaneous neurofibromas.

Neurofibroma



Multiple cutaneous and sub-cutaneous neurofibromas affecting the face and eyelids.

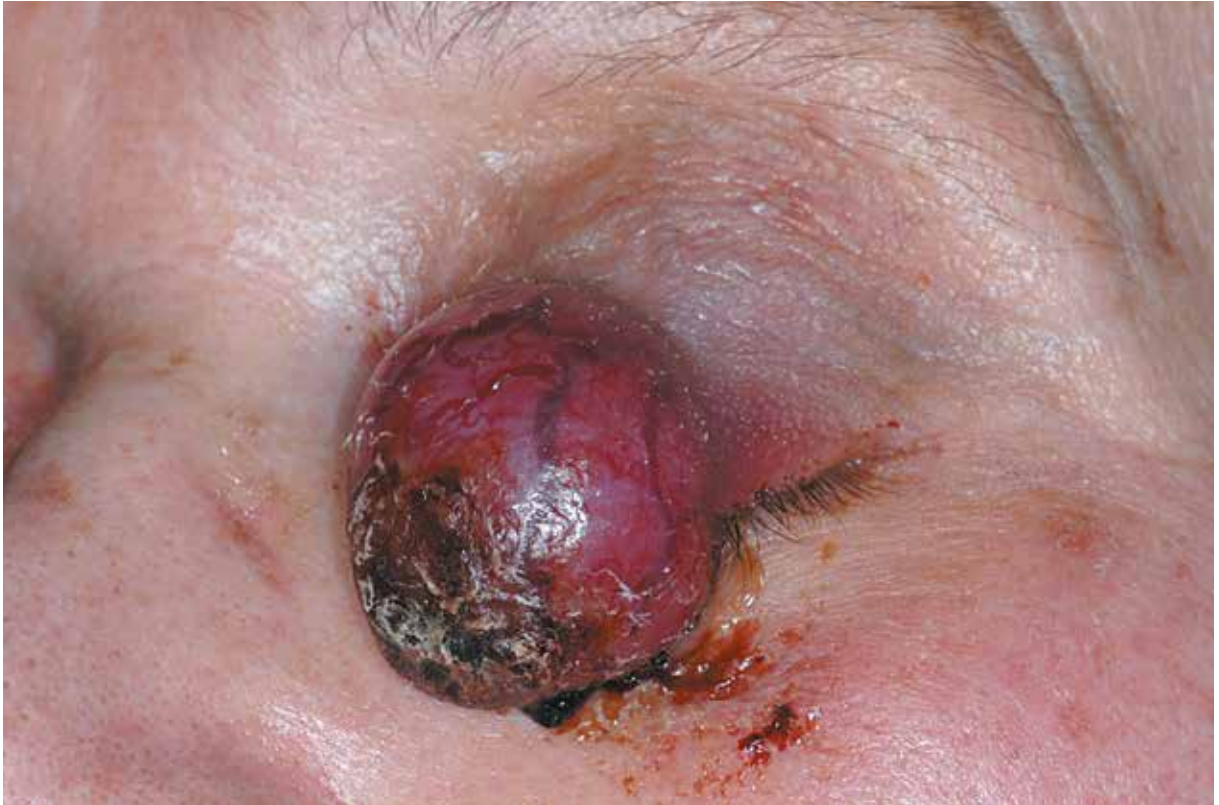Merkel cell carcinoma



Rare but very aggressive malignant neuro-endocrine tumor linked to the proliferation of Merkel cells in the epidermis.

Purplish nodule growing rapidly in a few days occurring in elderly subjects.

Merkel cell carcinoma



Very rapid growth requires an early diagnosis as significant local and general metastatic potential.





8. Lymphoid tumors

Lymphoid tumors

Lymphoid tumors result from the proliferation of clonal cells from the B or T lymph lines. The ocular adnexa are a rare location of lymphoma (orbits and ocular adnexa: 5 to 10% of extra-nodal lymphomatous locations).

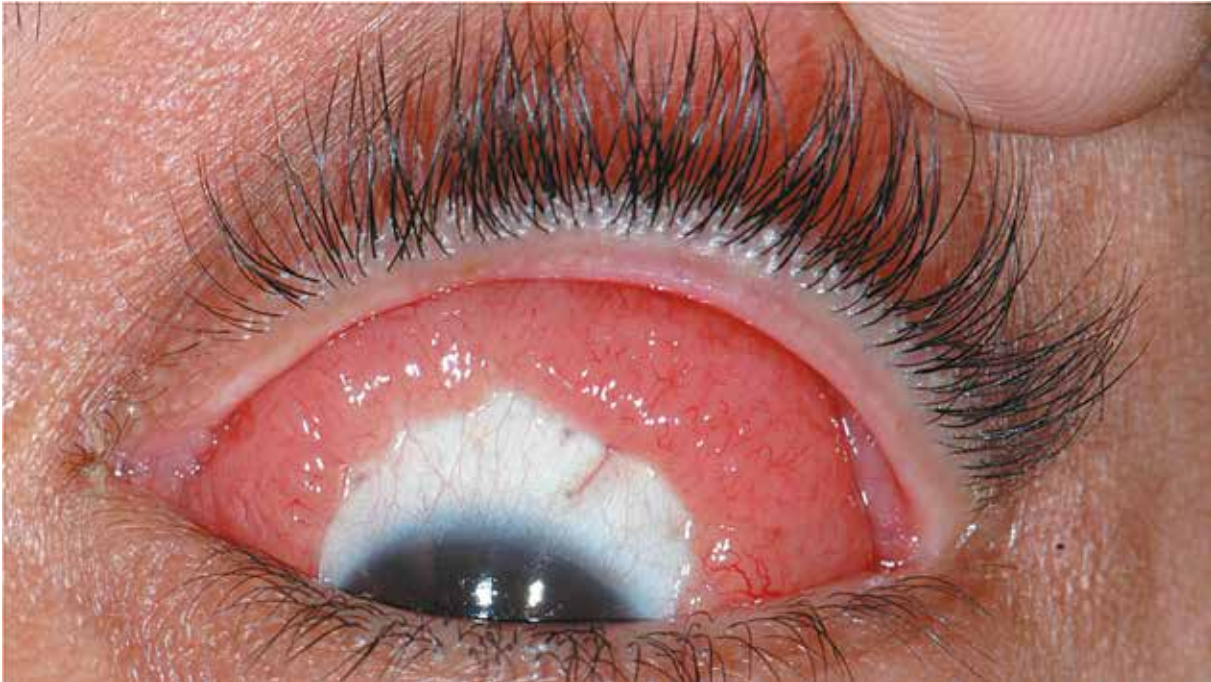The prognosis varies according to the type of lymphoma.

A MALT lymphoma is more common with a good prognosis after radiotherapy or chemotherapy.

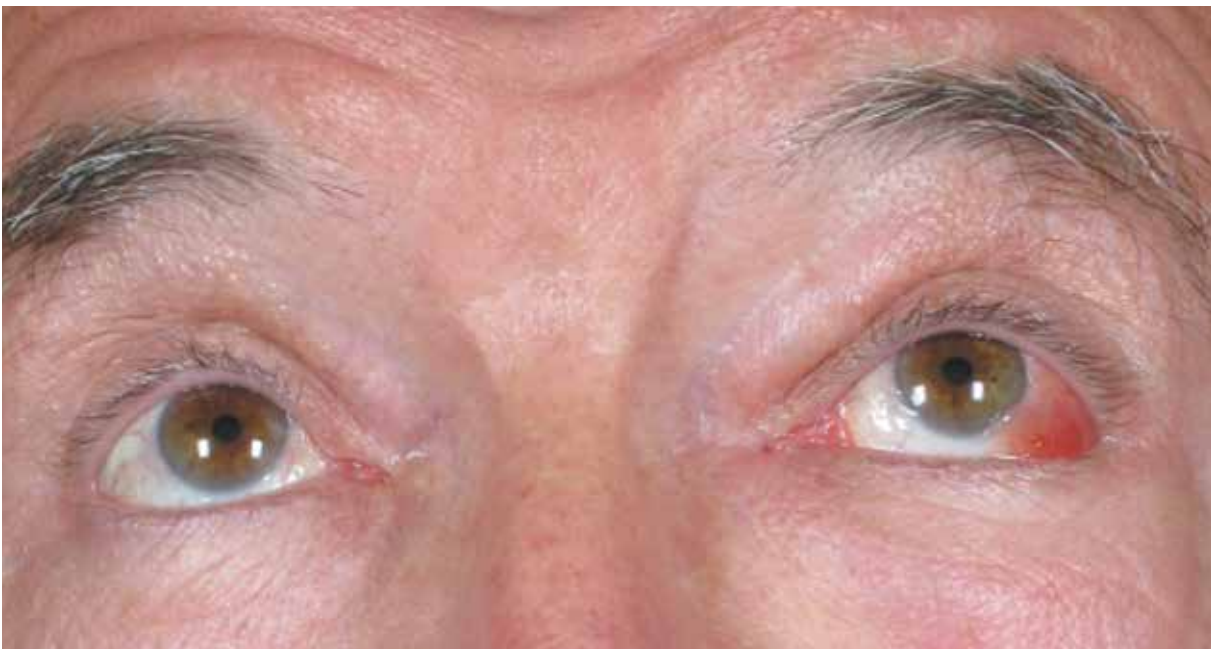High-grade B-cell lymphomas are life-threatening in the short term and require urgent treatment.

A diagnostic biopsy is necessary for any suspected lymphoproliferative lesion.

MALT Lymphoma

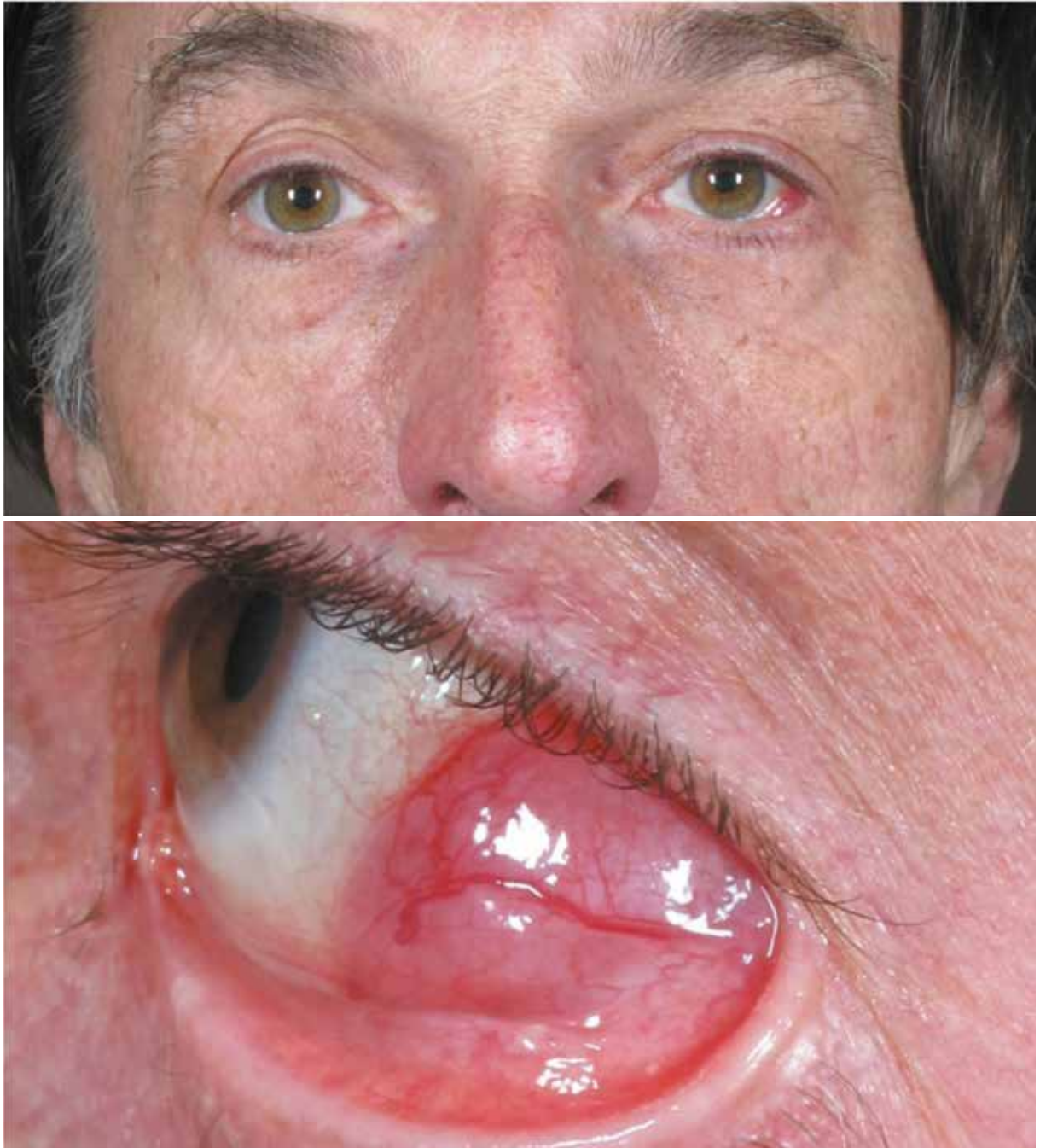


Salmon pink proliferation within the bottom of the upper conjunctival sac between the eyeball and the eyelid. Characteristic appearance of lymphomatous lesion.



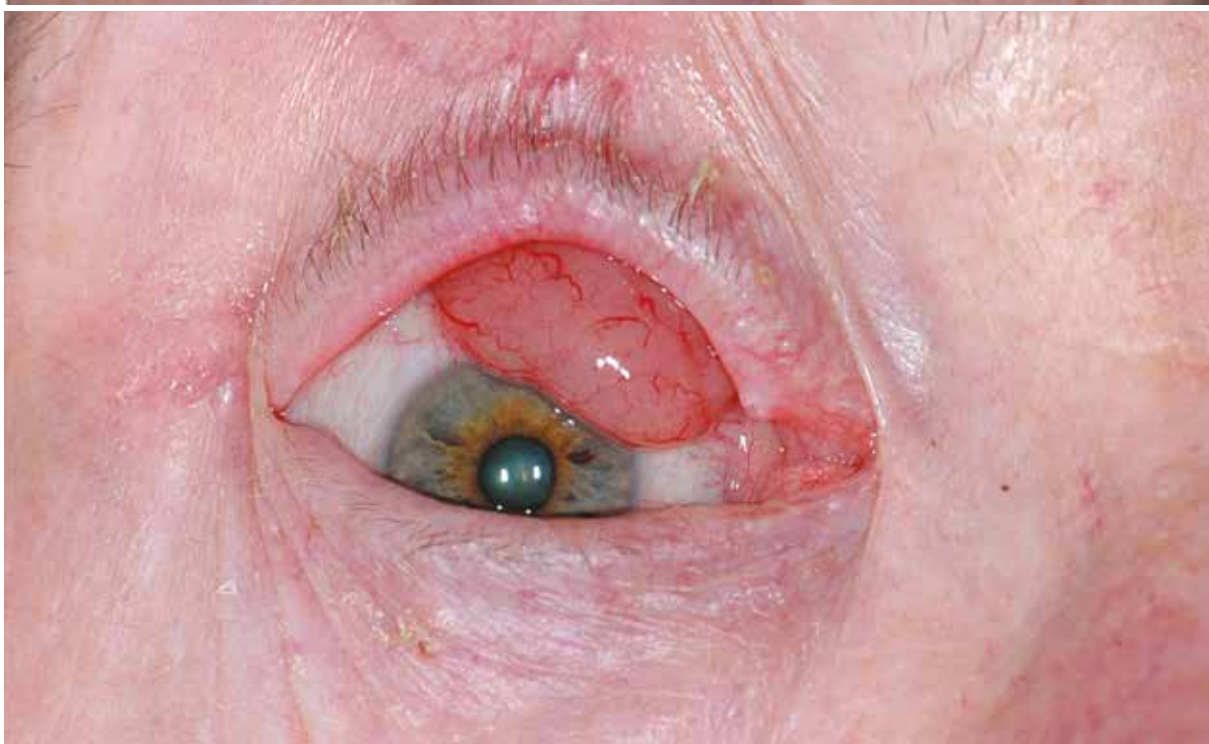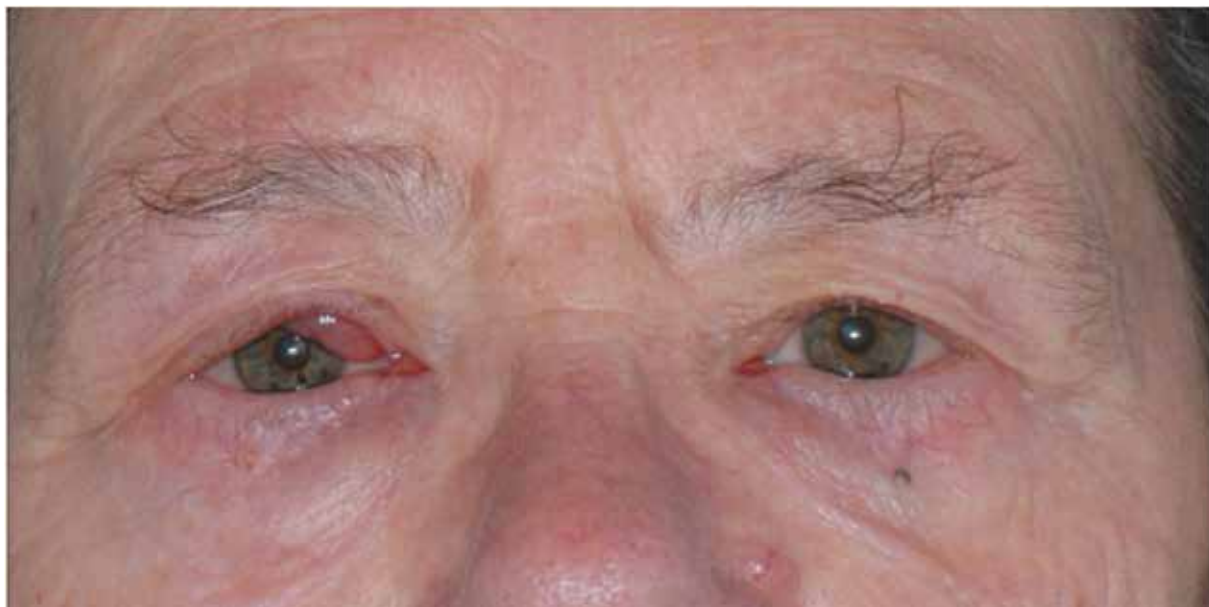Lesion more discreet on the ocular surface, subconjunctival in the temporal quadrant of the left eye.

MALT Lymphoma



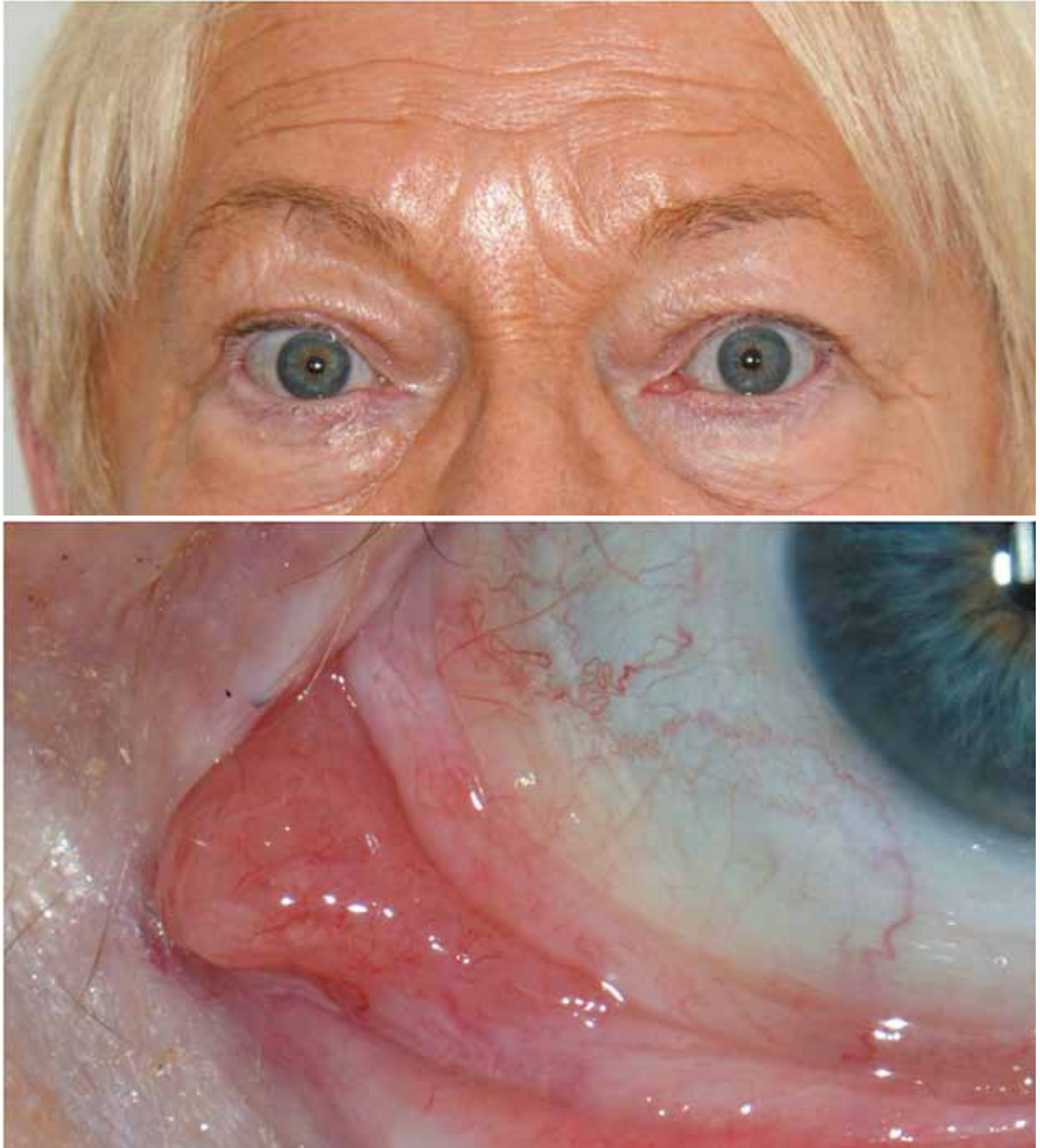
Ectropion of the lower left eyelid. The eyelid is pushed back by a salmon pink mass, characteristic of Malt lymphoma.

MALT Lymphoma



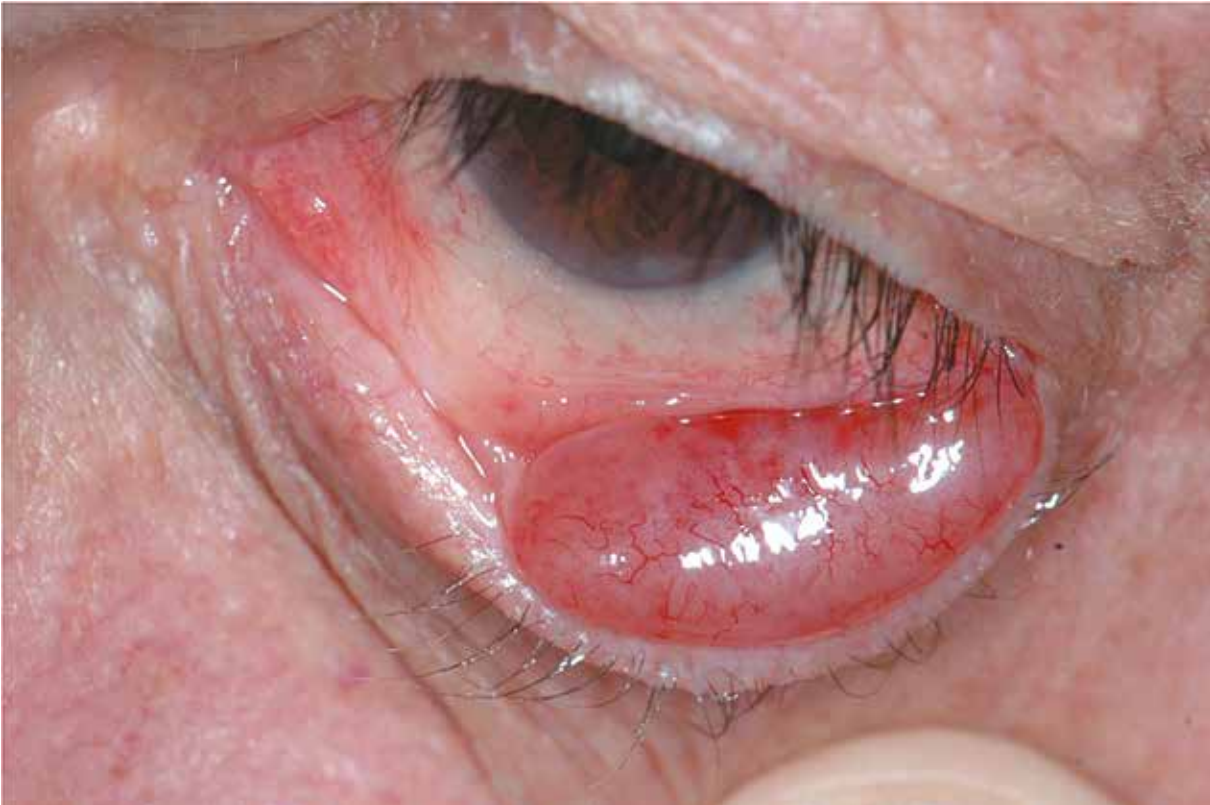Appearance that can mimic upper conjunctival chemosis on the right side. Do not hesitate to lift the eyelids to reveal the characteristic mass.

MALT Lymphoma



Discreet caruncular bulge on the left eye. At high magnification, salmon pink caruncular ectasia characteristic of the lymphoma.

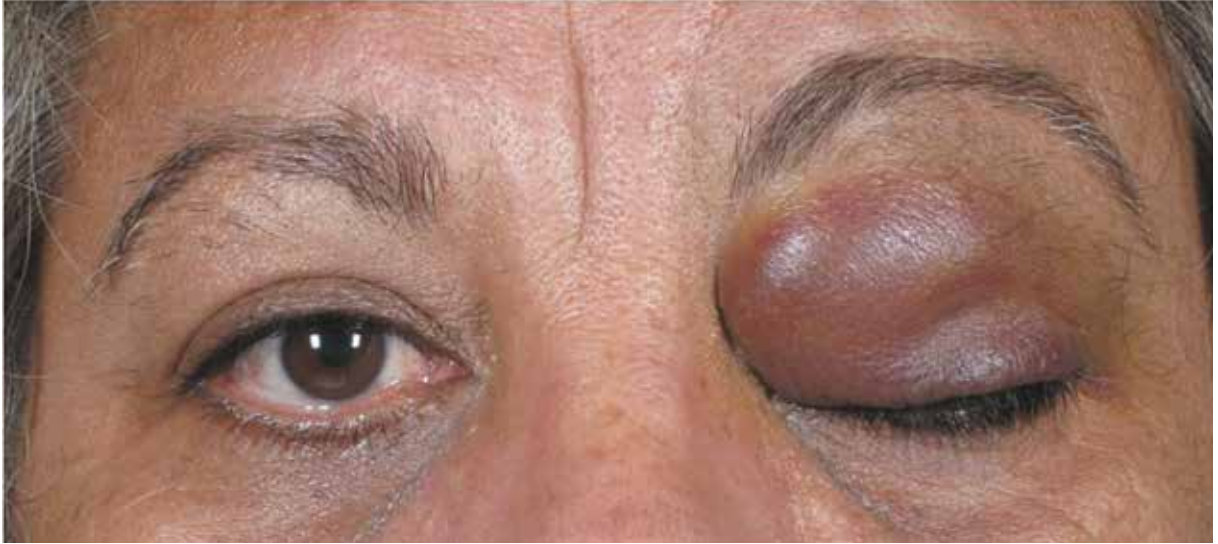Follicular B Lymphoma



Nodular lesion developed within the conjunctival and tarsal side of the lower eyelid.

This time, the lesion is not bulbar subconjunctival. The diagnostic biopsy will enable the diagnosis to be established with certainty.

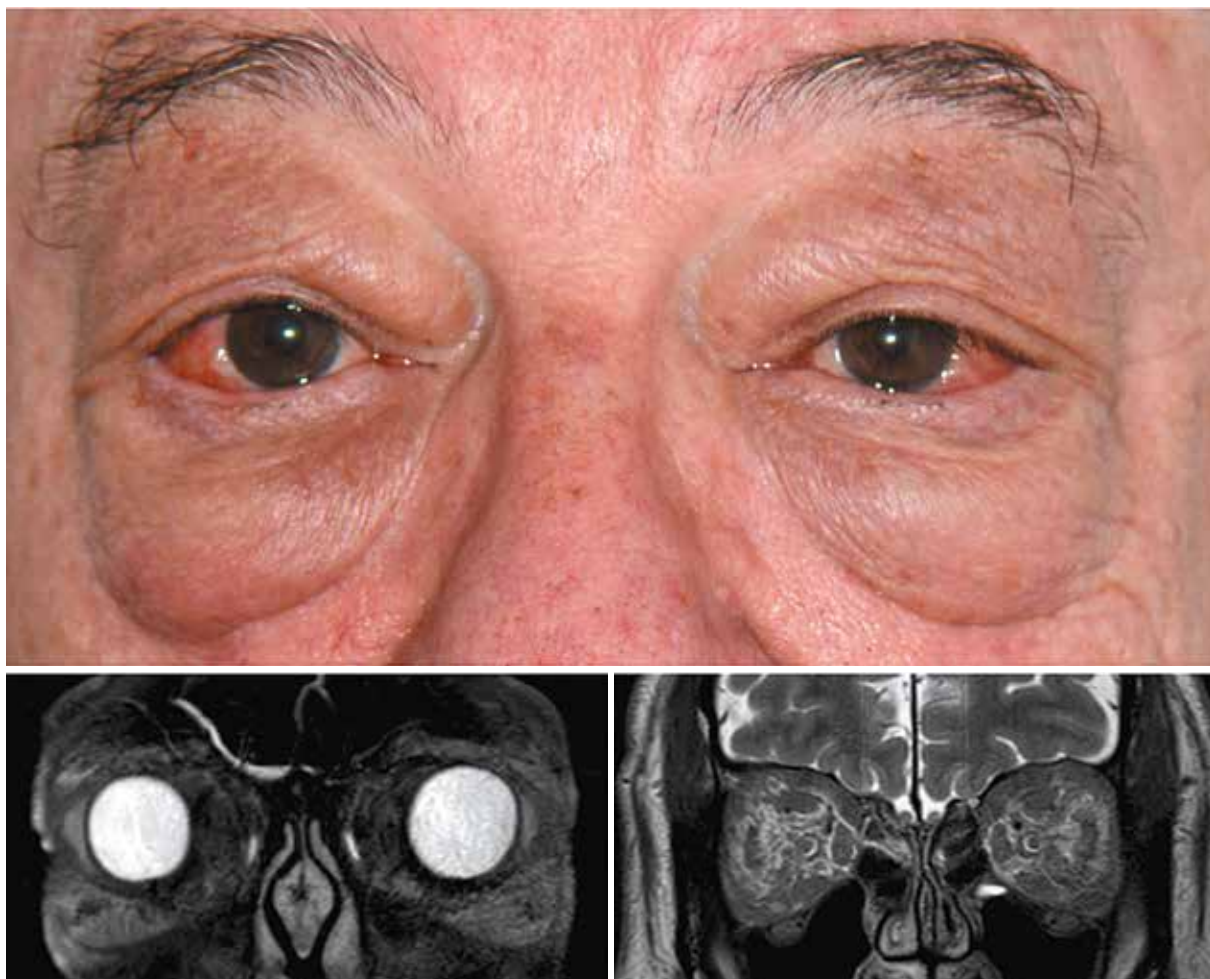
Mantle cell lymphoma



High-grade lymphoma with rapid tumoral growth in a few days.

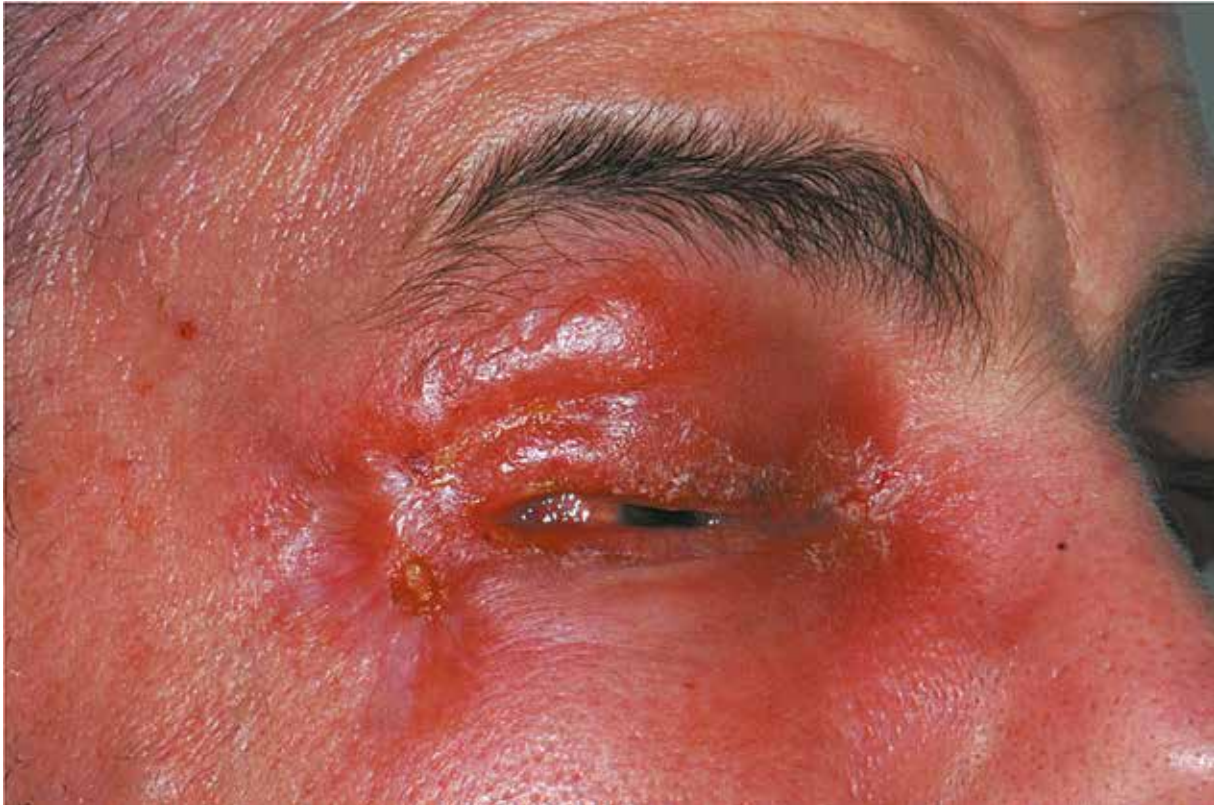Mass with intra and extra-orbital extension causing ocular dystopia (left eye pushed down and outwards), as well as mechanical ptosis.

Lymphocytic lymphoma



Appearance of bilateral orbital infiltrate; only a diagnostic biopsy will enable the diagnosis of lymphocytic lymphoma to be established.

Cutaneous T-cell lymphoma



Clonal proliferation of CD4+ T cells initially cutaneous, with secondary lymphatic extension. Erythematous lesion poorly limited with some scaly patches.

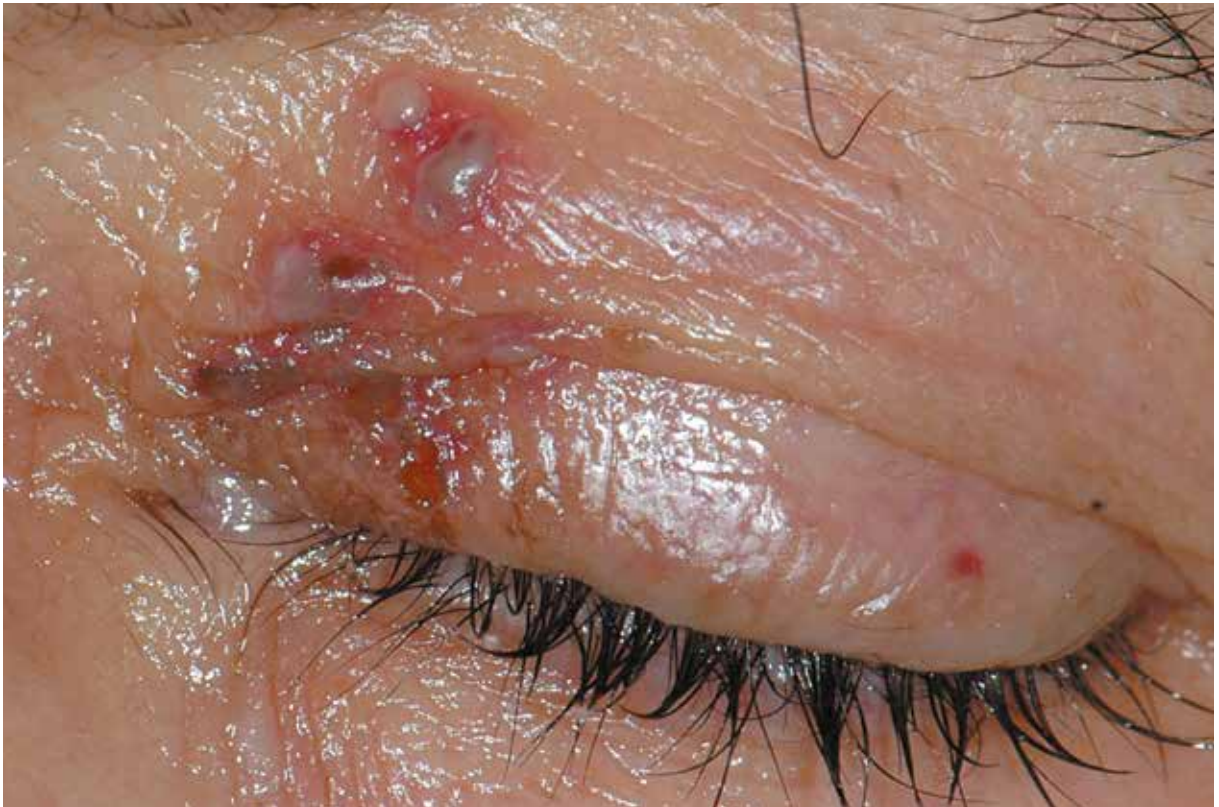The infiltrating appearance of cutaneous T-cell lymphoma is very different from the appearance of Malt lymphoma in the form of salmon pink mass.





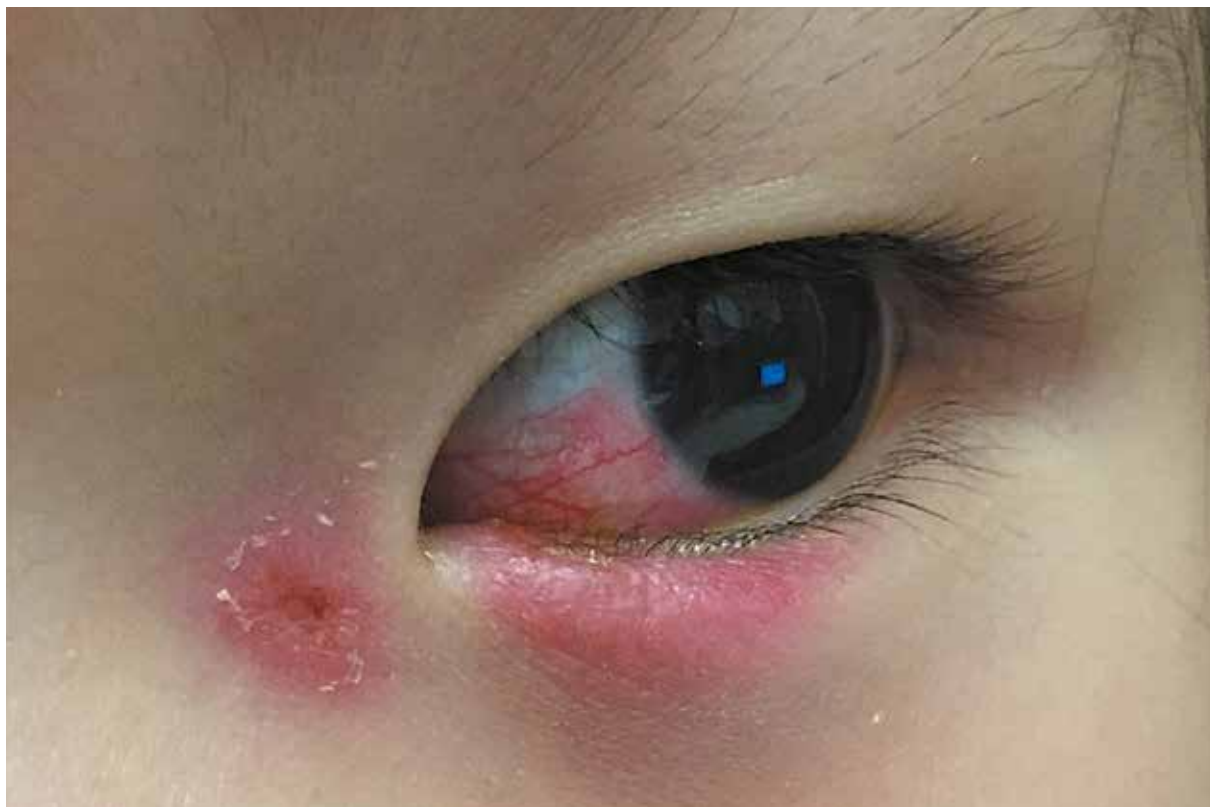9. Infectious diseases

Herpes



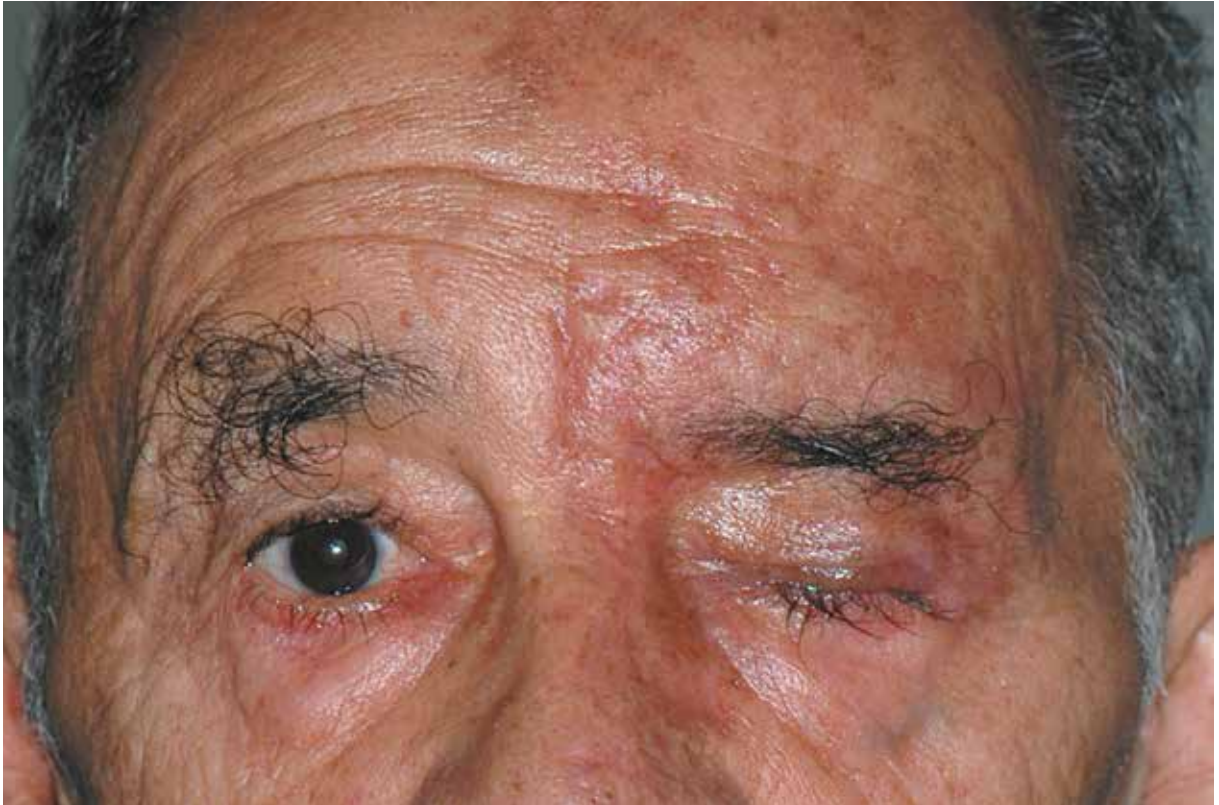Non-confluent vesicles containing serous fluid, with subsequent ulceration. Screen for associated intraocular involvement.

Chickenpox

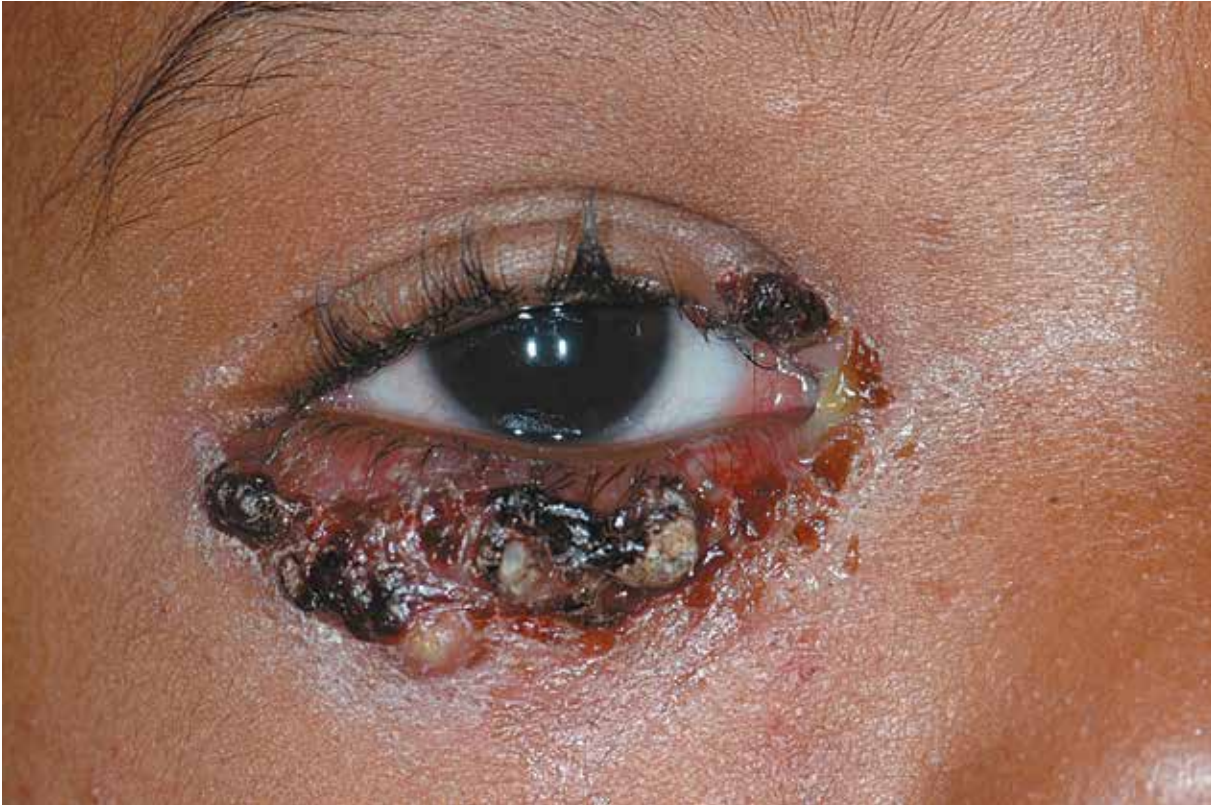

Vesicular rash in the context of chickenpox with cutaneous and conjunctival involvement. Screening for associated intraocular involvement in the V1 area is necessary.

Post-herpetic sequelae



Impetigo



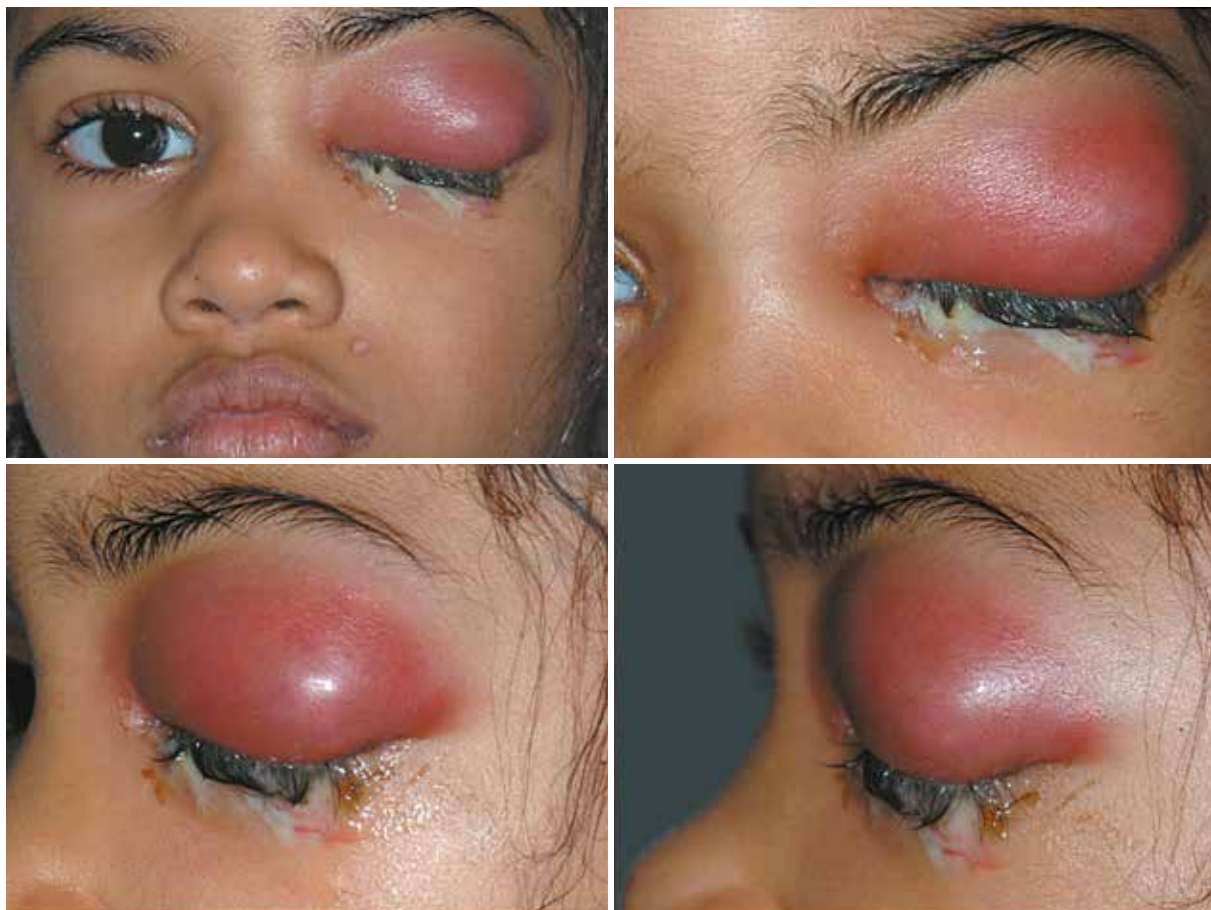Secondary cutaneous staphylococcal bacterial infection.

Preseptal cellulitis



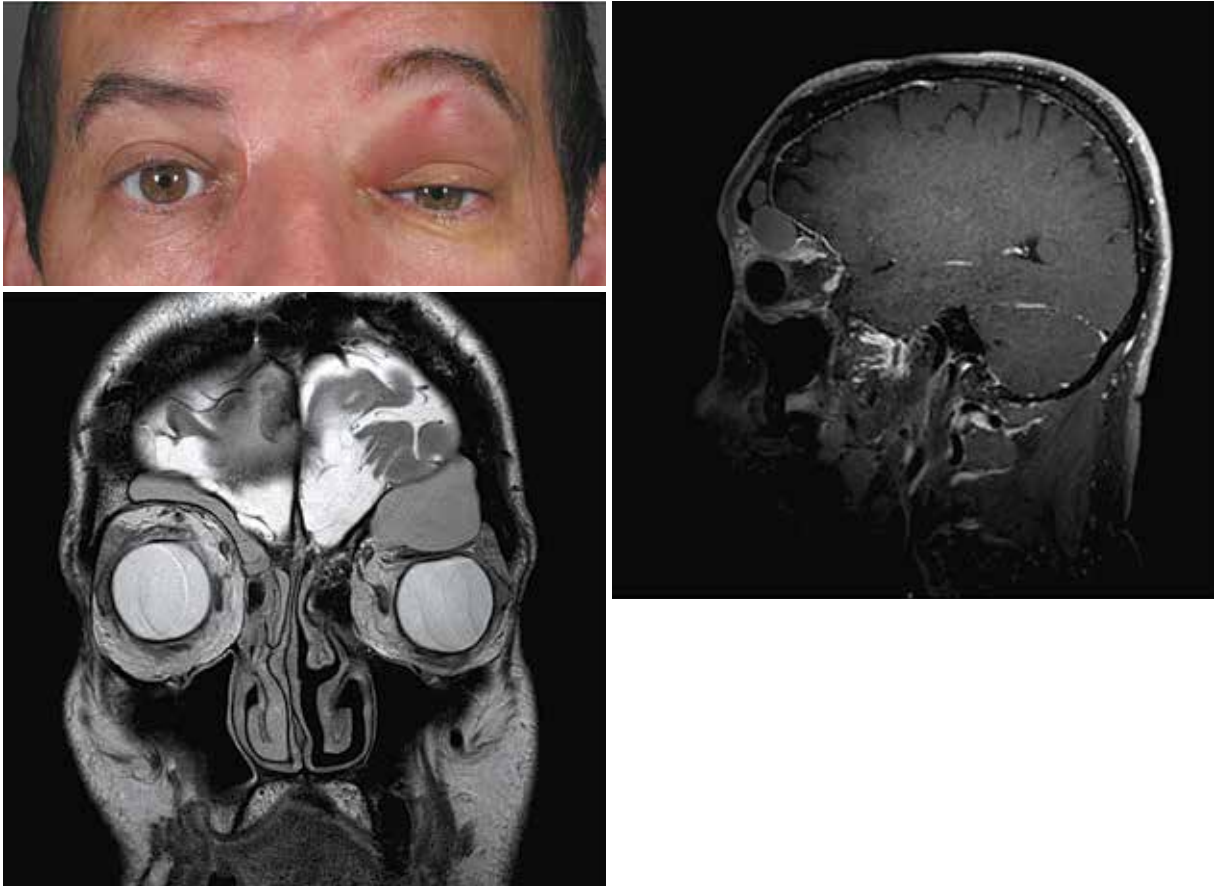
Warm erythema with non-compartmentalized swelling.

Palpebral abscess



Painful swelling with fever and compartmentalized purulent content.

Meningocele



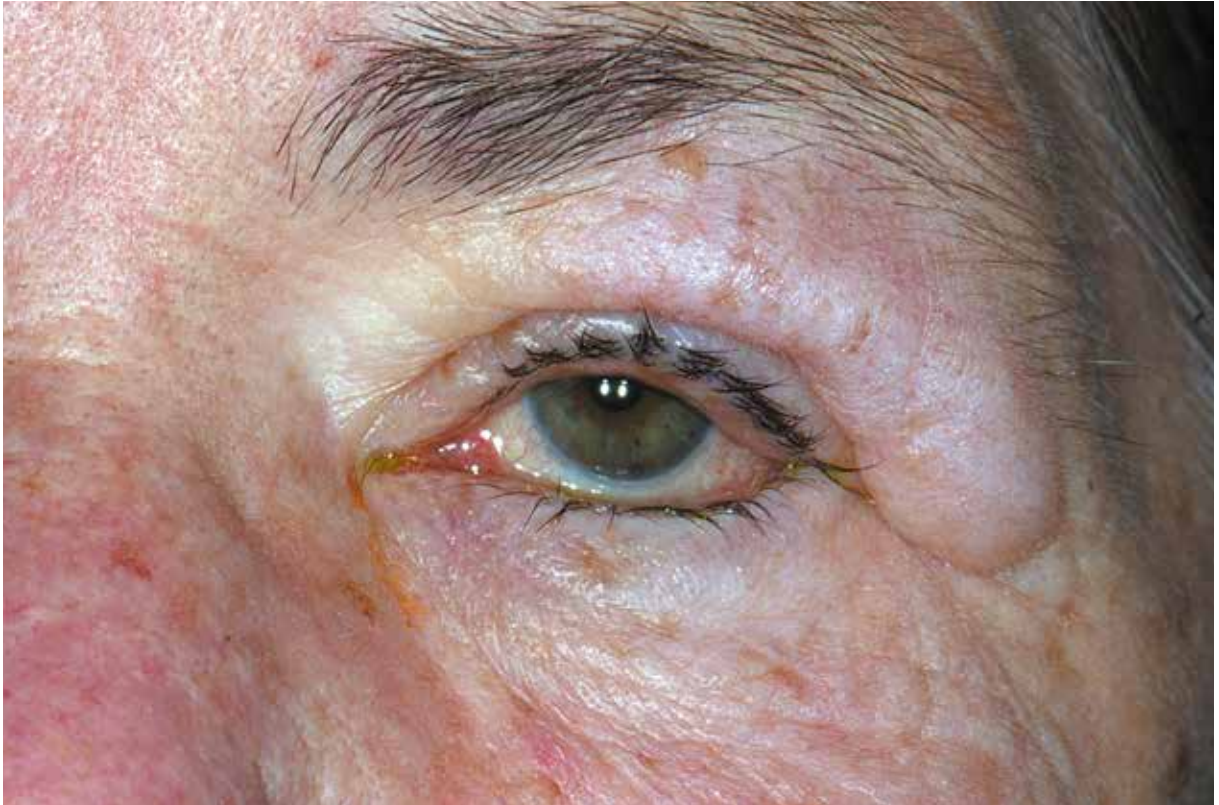Meningocele is a hernia of the meninx (dura mater and arachnoid) of which the occurrence is congenital or post-traumatic.

In this case, it is a meningocele with orbital extension. Neurosurgical treatment is necessary.



10. Inflammatory diseases

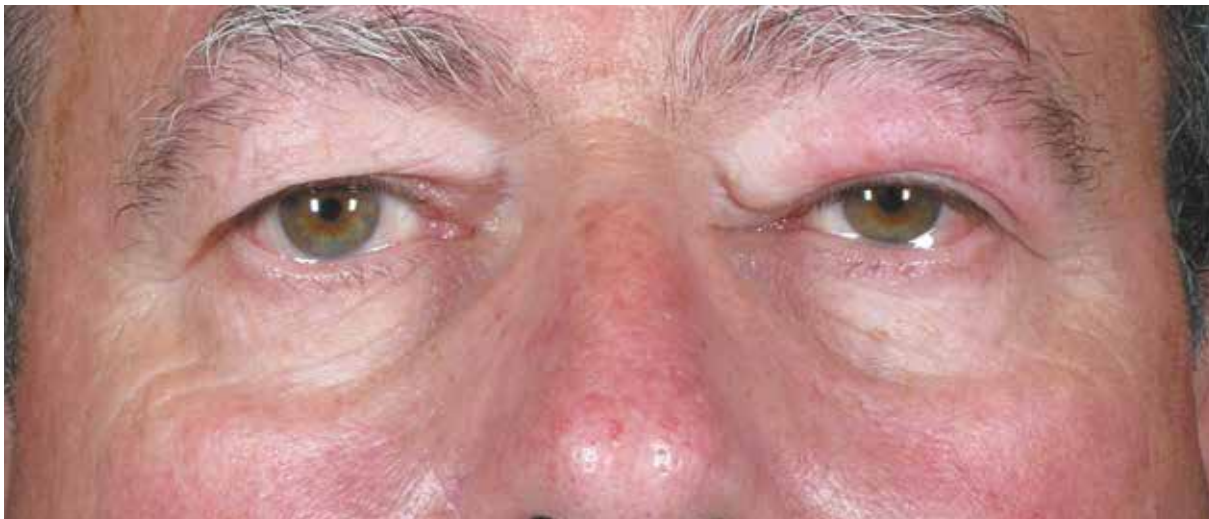Rosacea



Chronic condition combining erythema with telangiectasia and acne-like lesions.

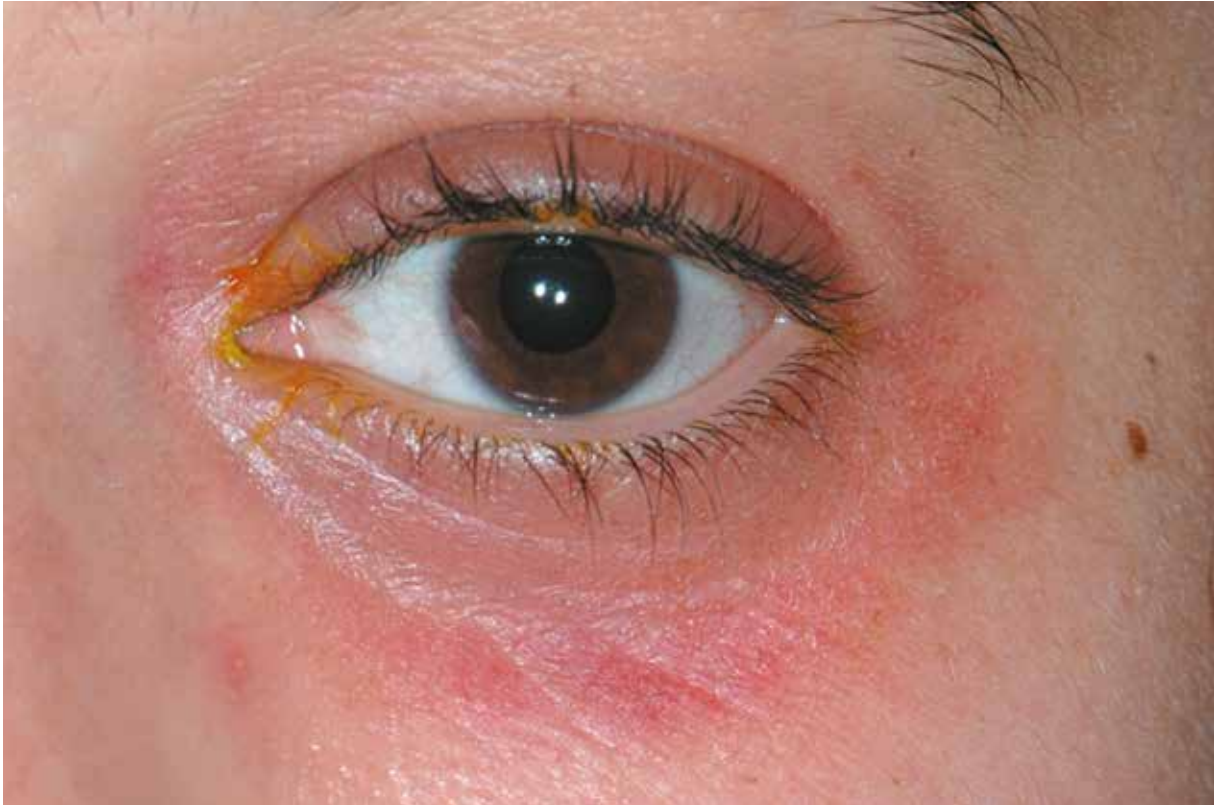In chronic stage 3, a hard edema can develop due to hyperplasia of the sebaceous glands.

Rosacea



Morbihan syndrome: idiopathic palpebral inflammation.

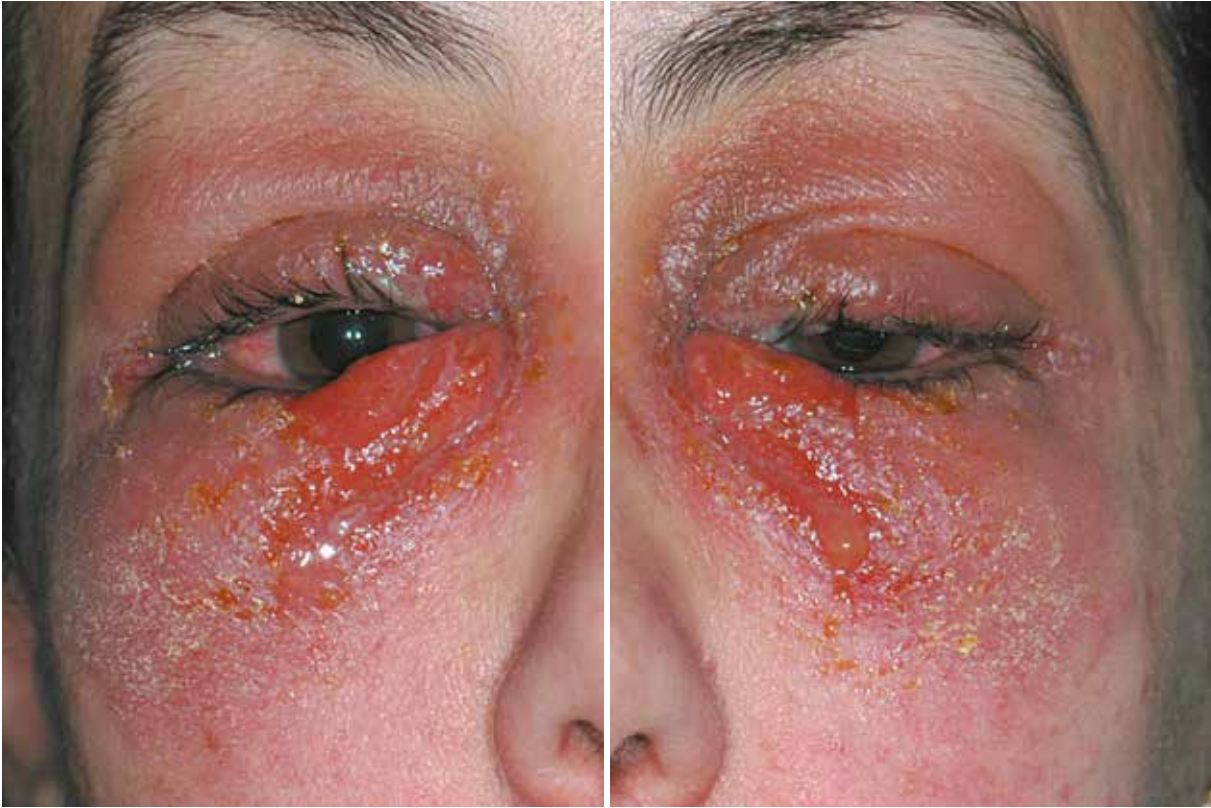Eczema



Eczema or contact dermatitis is linked to a type IV allergic reaction (cell-mediated).

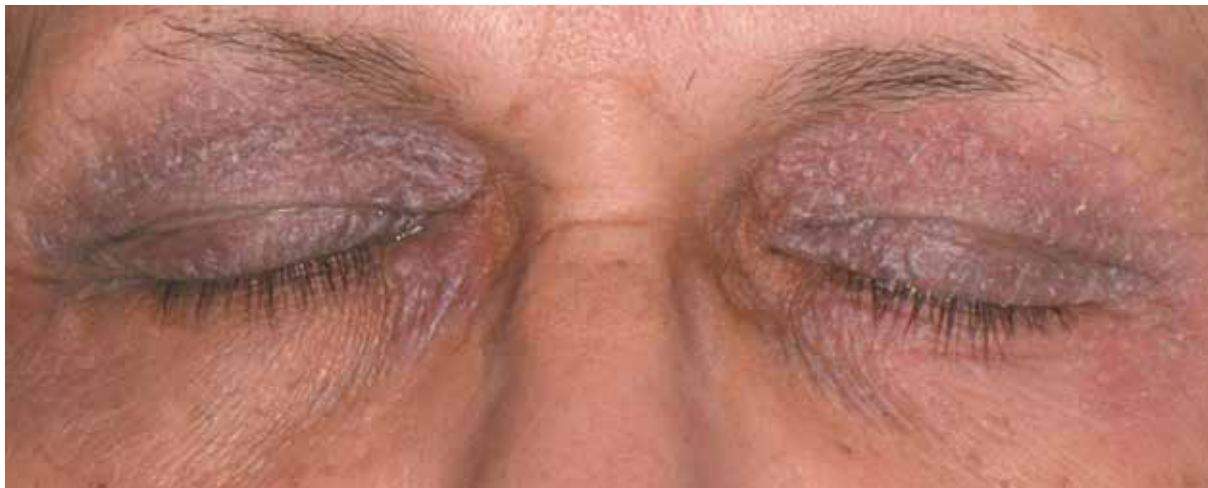Progression of the lesions with initial erythema, appearance of vesicles, erosion, scabs, desquamation.

Eczema



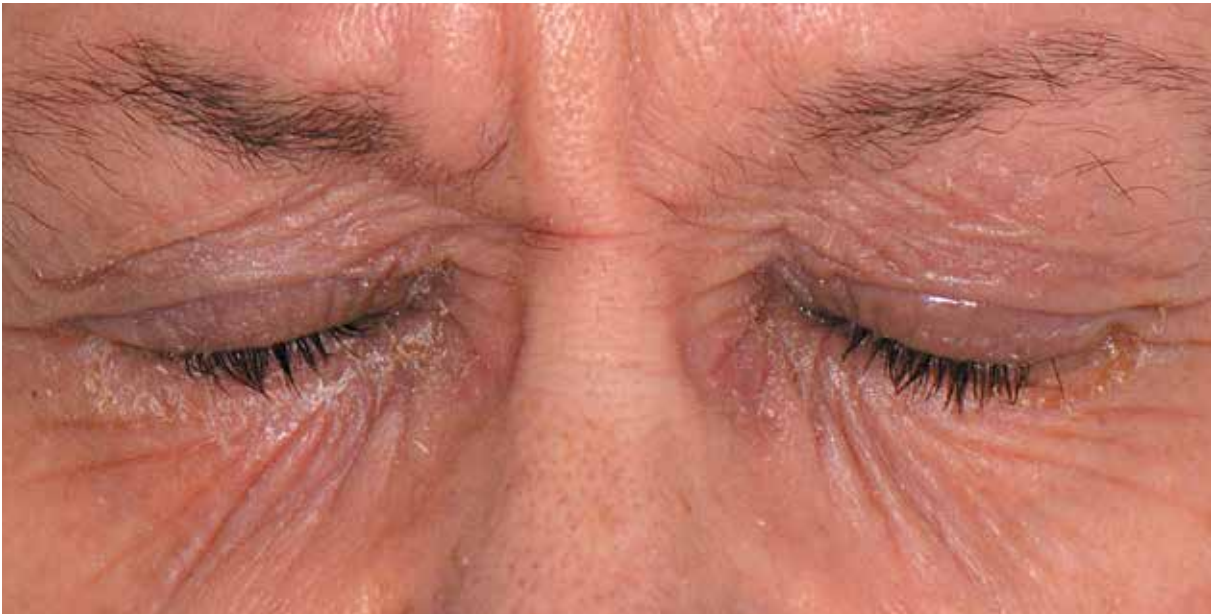Eczema lesions are susceptible to secondary infection, impetiginization here.

Eczema



In the case of chronic eczema, hyperkeratosis develops with lichenification and hyperpigmentation due to scratching.

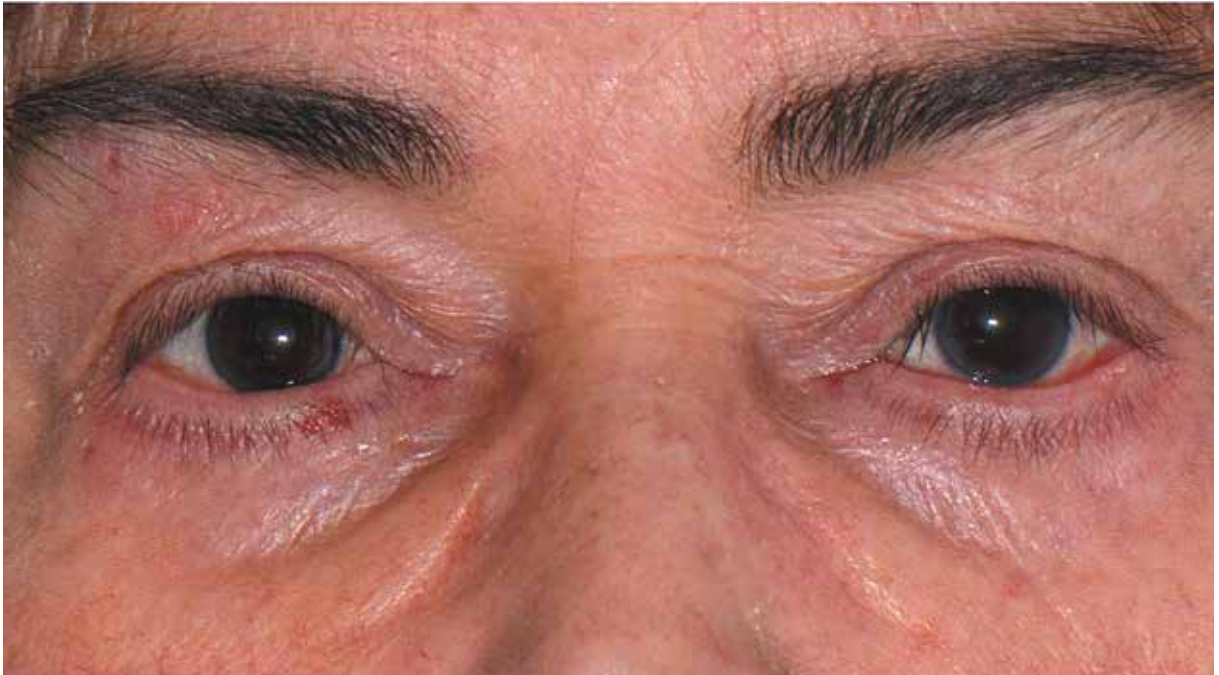Atopic dermatitis



Atopic dermatitis is a chronic inflammatory disease and an increase in serum IgE levels is observed in 90% of cases. The lesions can be acute (edema, erythematous plaques, erosion, pustules, scabs) or chronic (lichenification, eyelash alopecia, periocular pigmentation).

Cutaneous lichenification with palpebral scabs and palpebral cracks leading to a Dennie-Morgan fold.

Psoriasis



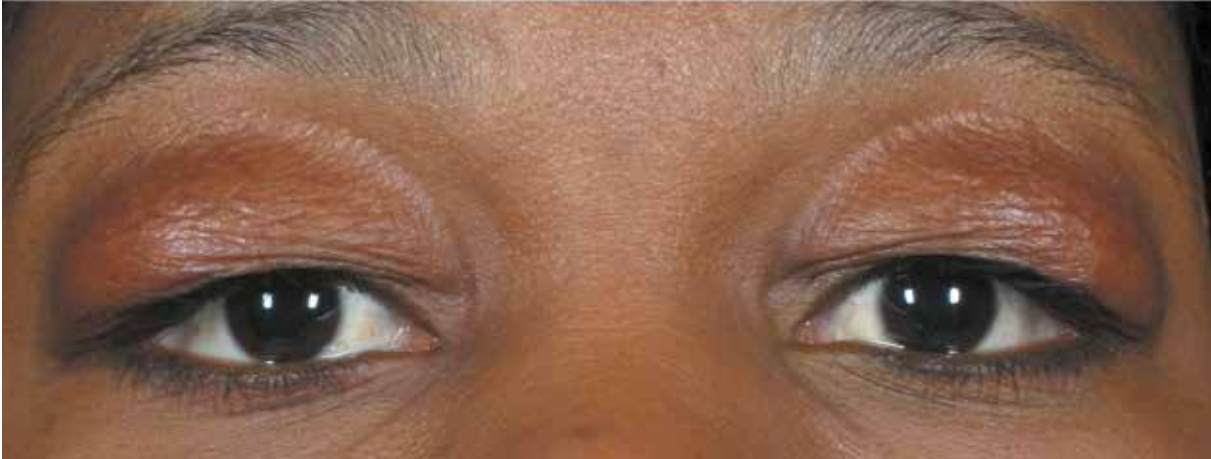Psoriasis is linked to an acceleration of the renewal of keratinocytes.

It is linked to a T-cell-mediated inflammation. Flare-ups can be localized or generalized. The face is usually spared and palpebral involvement is rare.

Confluent erythematous-squamous plaques can be observed. Common triggering factors are drugs (corticosteroids, antimalarial drugs, beta-blockers), stress, alcohol or an acute streptococcal infection.

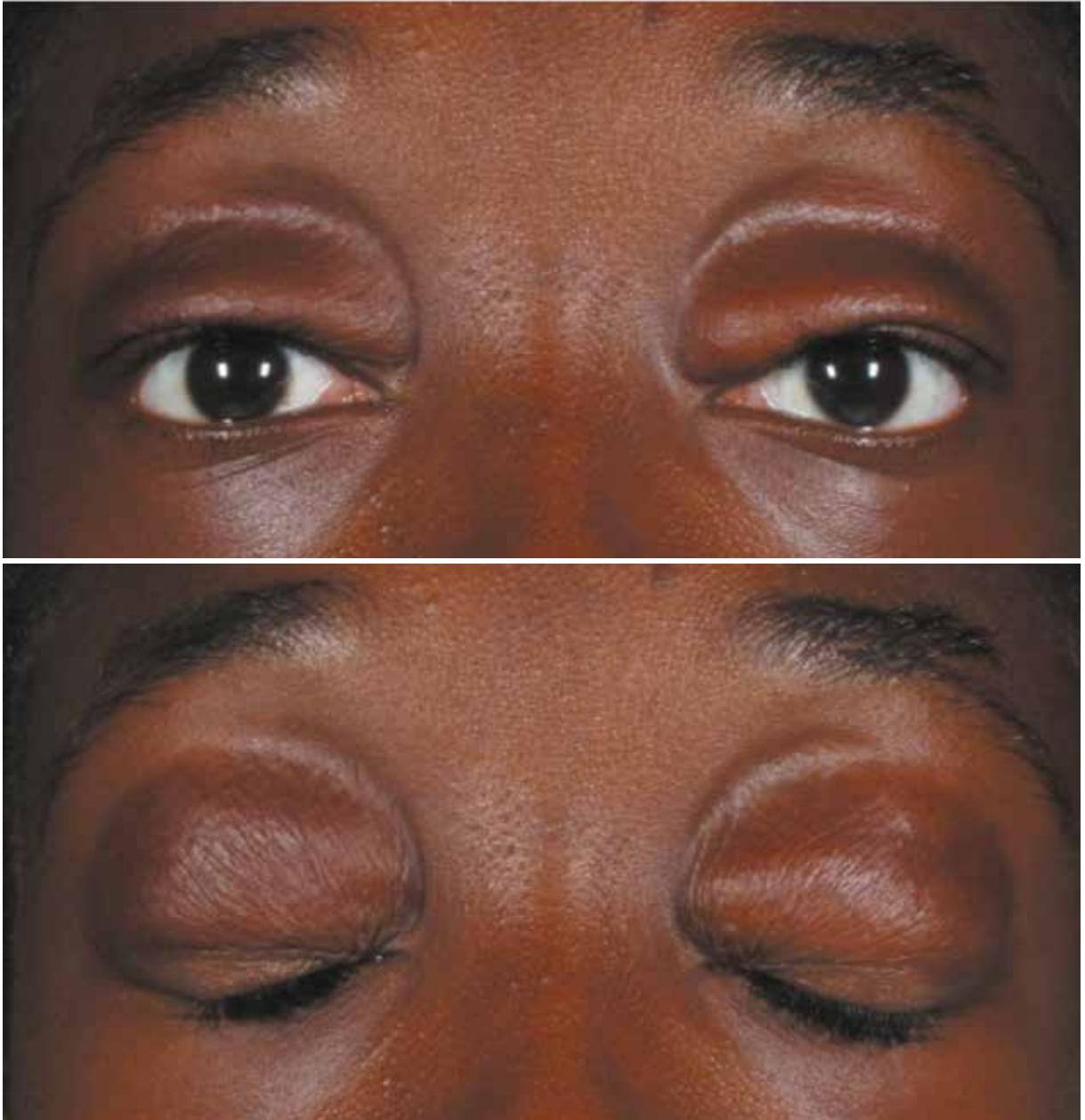
A trauma can also be a triggering factor, even several years later (Koebner phenomenon). Any pruritus is a contributing factor.

Blepharochalasis syndrome



Rare pathology of unknown etiology involving primarily the upper eyelids. The involvement is marked by recurrent acute flare-ups of palpebral edema with painful erythema.

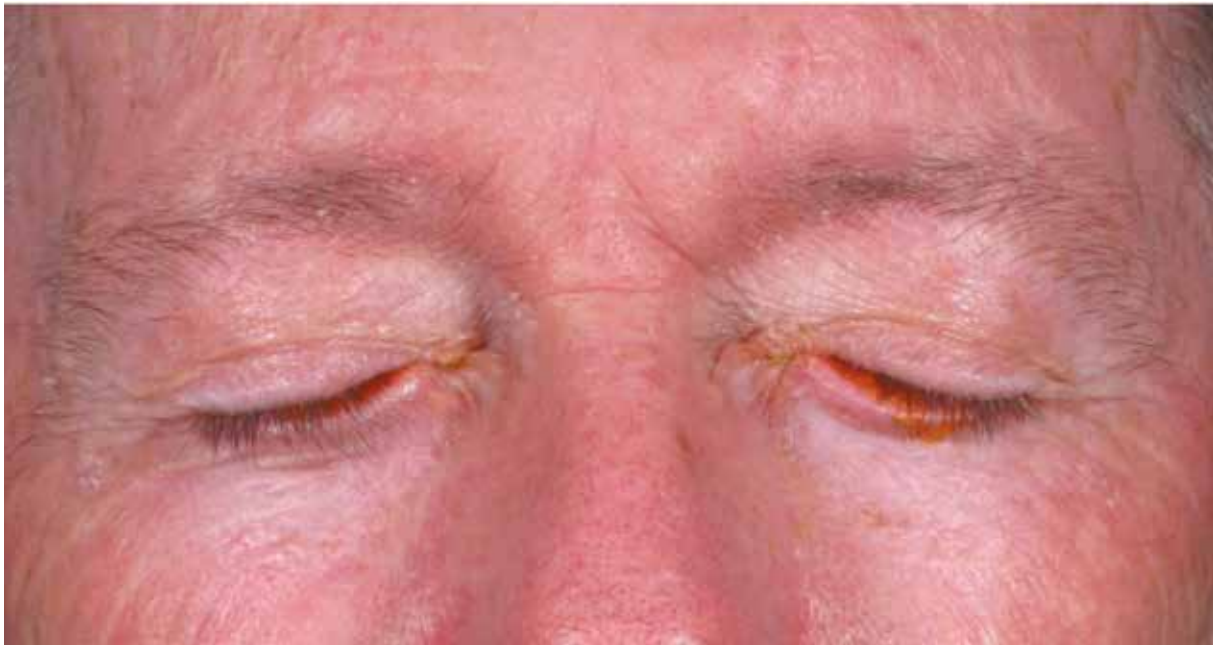Blepharochalasis syndrome



Skin dilation persists during the dormant phase with possible hernia and sequellar ptosis.

Treatment currently involves reconstructive surgery.

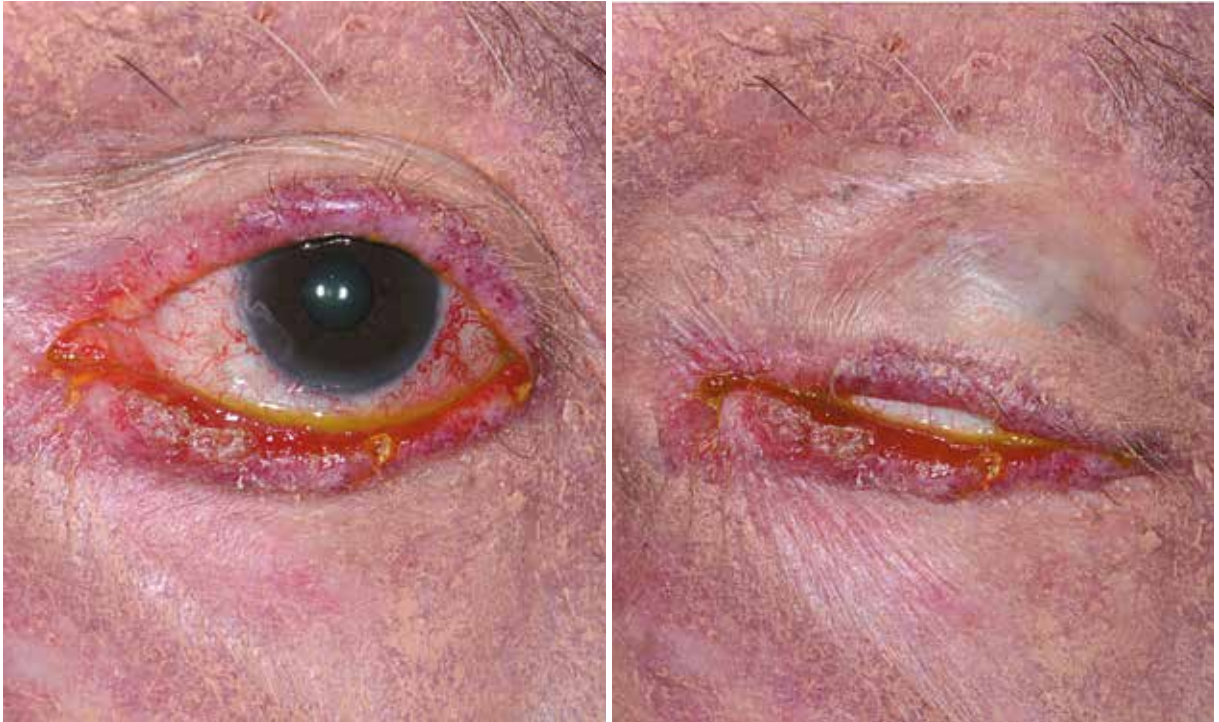Seborrheic dermatitis



Chronic erythematous-squamous dermatitis predominantly affecting the face.

Clearly defined lesions covered with orange scales, with blepharitis and predominant involvement of the glabella and upper eyelids.

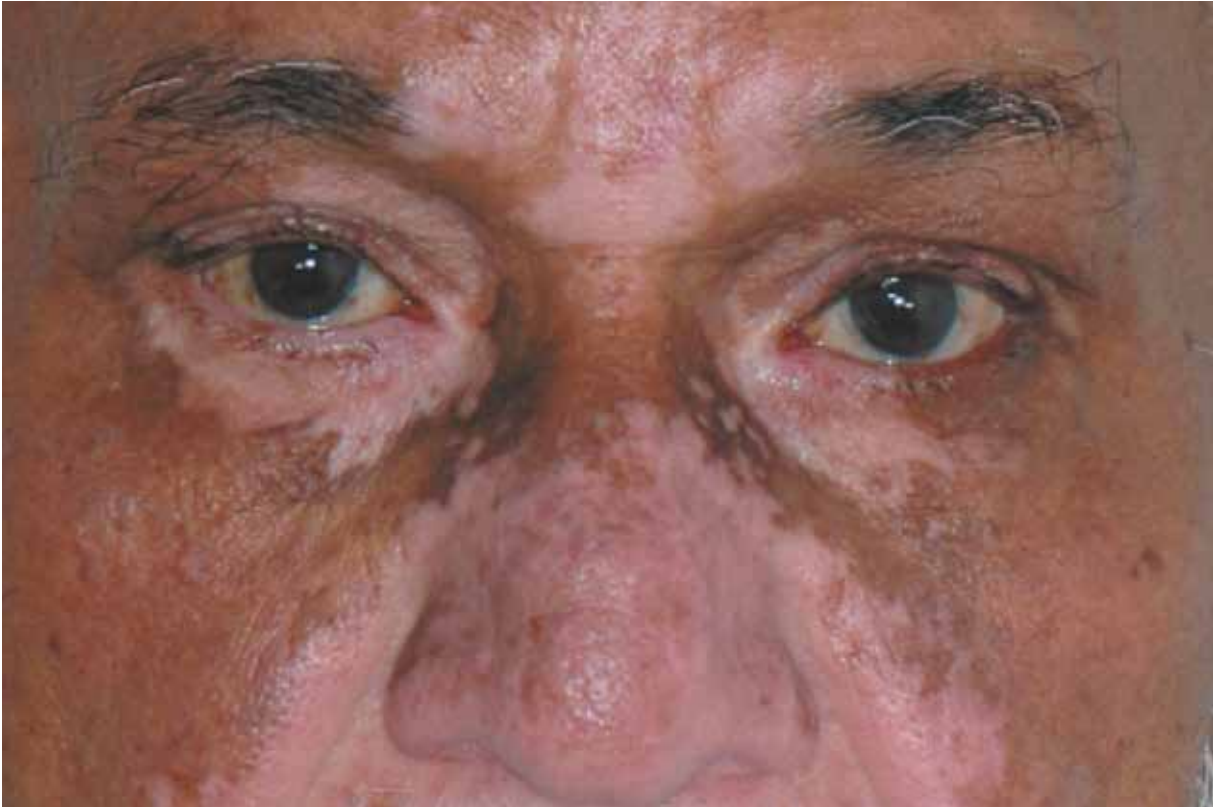Ichthyosis



Condition linked to a disorder of keratinization, more often congenital but can be of paraneoplastic or iatrogenic origin.

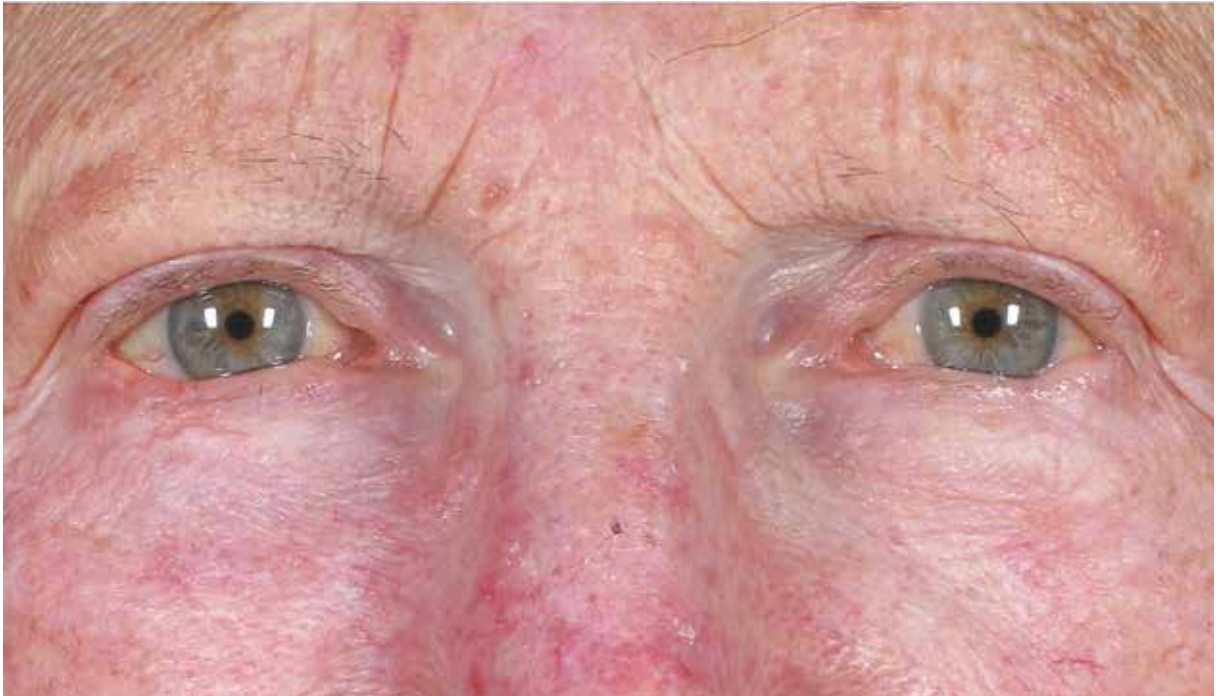It is characterized by xerosis with numerous scales and ectropion of the eyelids.

Vitiligo



Emergence of white macules linked to depigmentation.

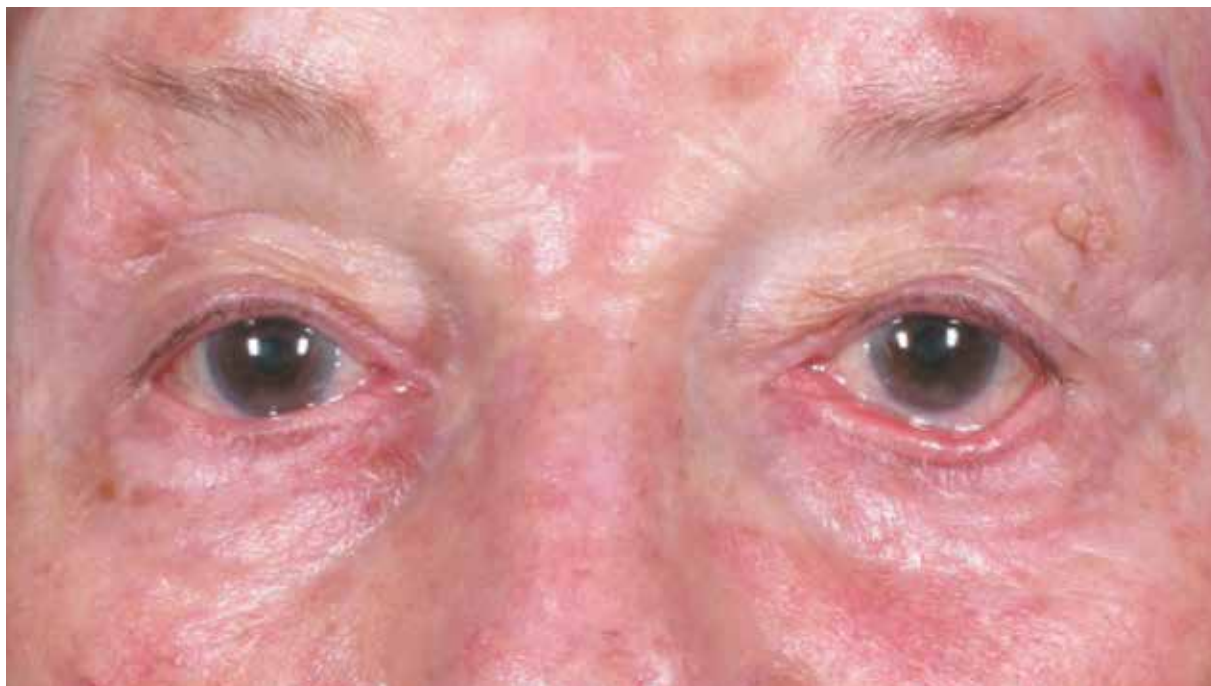Heliodermy



Heliodermy or photoaging is characterized by modifications of the skin linked to UV exposure resulting in precancerous predispositions.

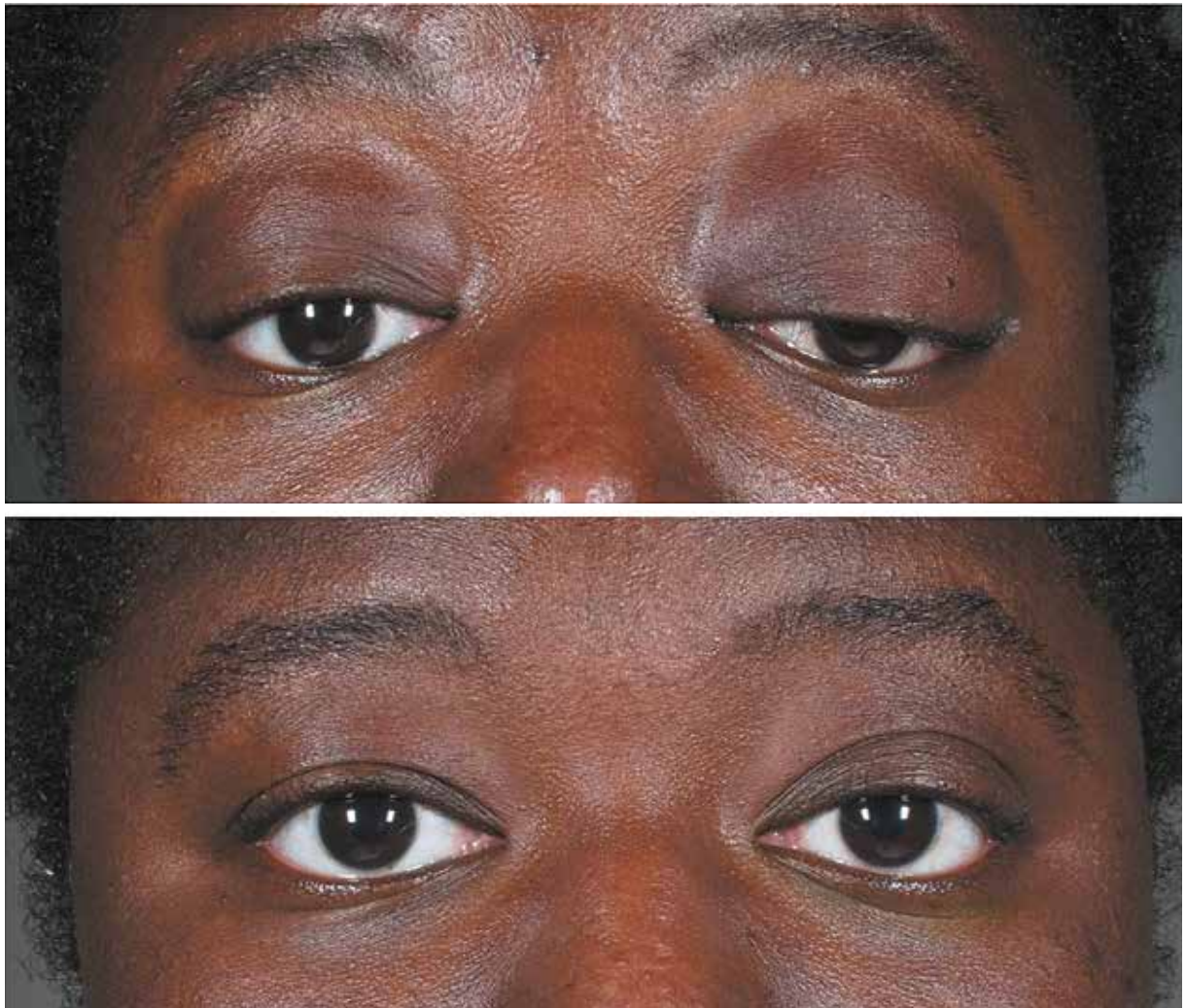The skin is thicker and rough with actinic keratosis, heterogeneous pigmentation with hypopigmented areas and other yellowish areas speckled with telangiectasia. Involvement varies according to the phototype.

Heliodermy



Heliodermy in darker phototypes.

Sarcoidosis

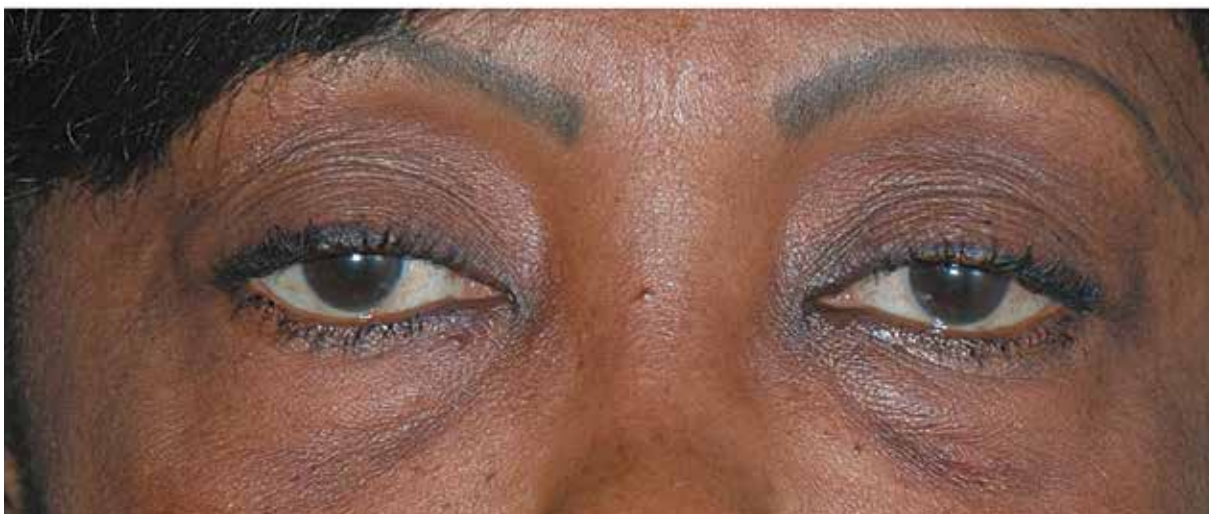
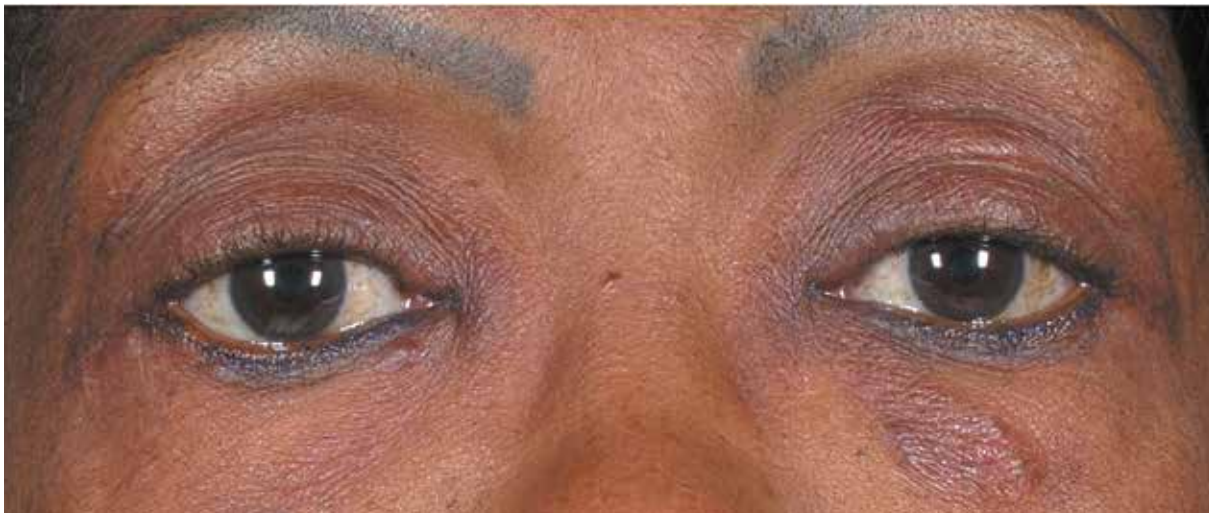
Infiltration of the lacrimal and orbital glands and diminution after corticosteroid treatment.

Sarcoidosis is an autoimmune condition of unknown origin.

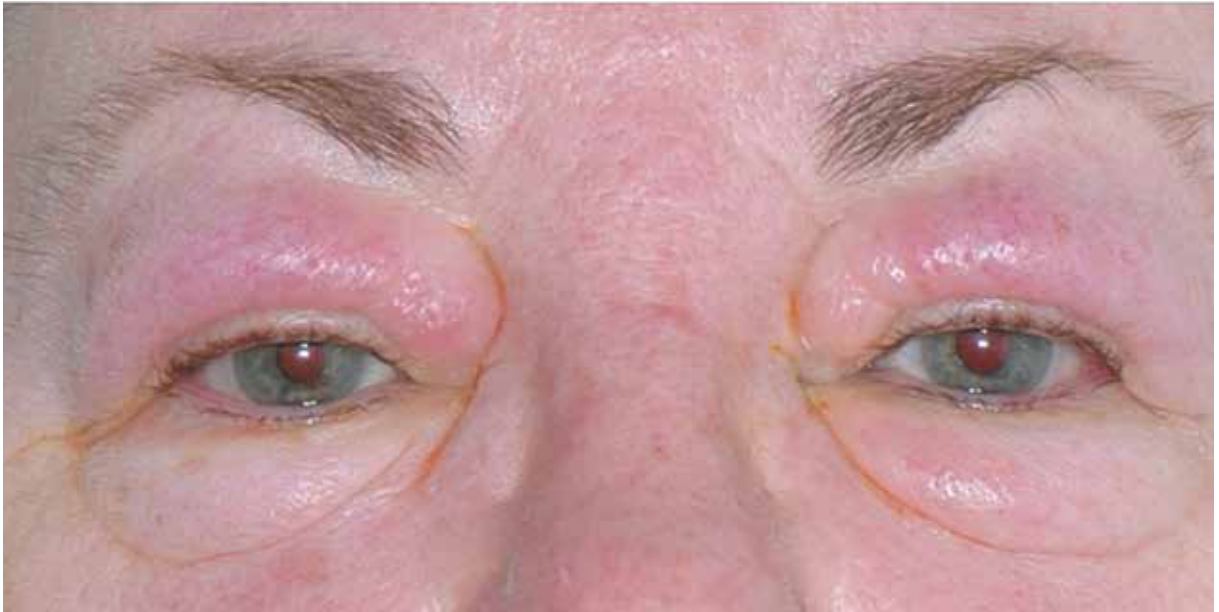Symptoms include the presence of sarcoid nodules with no caseous necrosis that can affect primarily the lacrimal glands with orbital infiltration.

Sarcoidosis



The skin can also be affected with the presence of cutaneous sarcoid nodules.

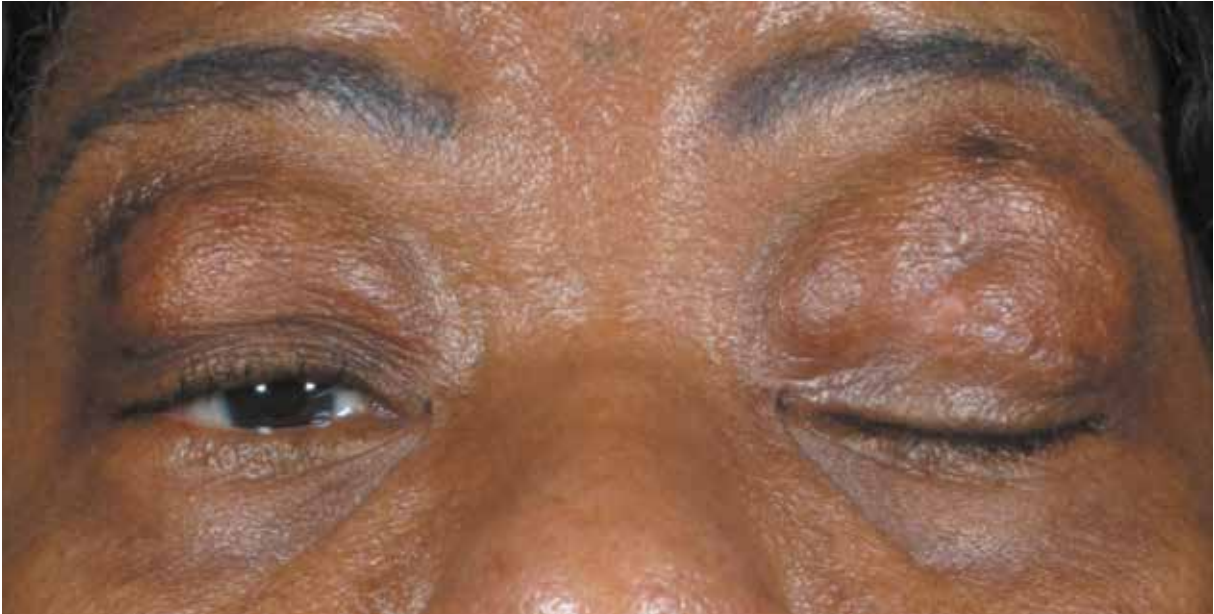Dermatomyositis



Dermatomyositis is an idiopathic inflammatory disease involving the muscles and skin.

Chronic palpebral infiltration can be difficult to diagnose without any knowledge of context. The differential diagnosis with a type 4 cutaneous rosacea may be established.

IgG4 inflammation



The syndrome associated with IgG4 is an autoimmune condition of unknown etiology characterized by the presence of tissue and serum type 4 immunoglobulin.

It can result in infiltration, notably of the lacrimal glands but also subcutaneous involvement leading to secondary fibrosis.

SECTION 2

Conjunctival tumors

Christine Levy-Gabriel

Introduction

Most conjunctival tumors are benign, especially in children, and the most common are nevi, choristomas, and papillomas. However, in adults over 40, the possibility of a malignant tumor should be considered for any recent conjunctival lesion with progressive growth, especially since it is raised, firm on palpation, invading the cornea, and is associated with dilated feeder vessels, pigmentation, or keratinization on the surface. These malignant tumors include essentially epidermoid (dysplasia, carcinoma in situ, and invasive carcinoma) and melanocytic (precancerous Reese melanosis, melanoma in situ, and invasive conjunctival melanoma) neoplasia on the ocular surface, and conjunctival lymphoma.

The aim of this Atlas is to familiarize ophthalmologists with all these tumors of which some are uncommon, and to help them clinically identify the most aggressive (epidermoid or melanocytic neoplasia, or lymphoma) which will require the right initial surgical treatment and systematic discussion in specialist multidisciplinary consultation meetings. In the case of epidermoid carcinoma or melanoma, total surgical excision of the tumor will be conducted under general anesthesia after iconography and measurement of the dimensions of the tumor. Complementary treatment will then be discussed according to the anatomopathological results. In the case of a lymphoma, a biopsy will be performed for histological analysis before referring the patient to hematology for assessment and therapeutic treatment.

1. Choristoma

Choristomas represent between 10% and 33% of conjunctival tumors in children.

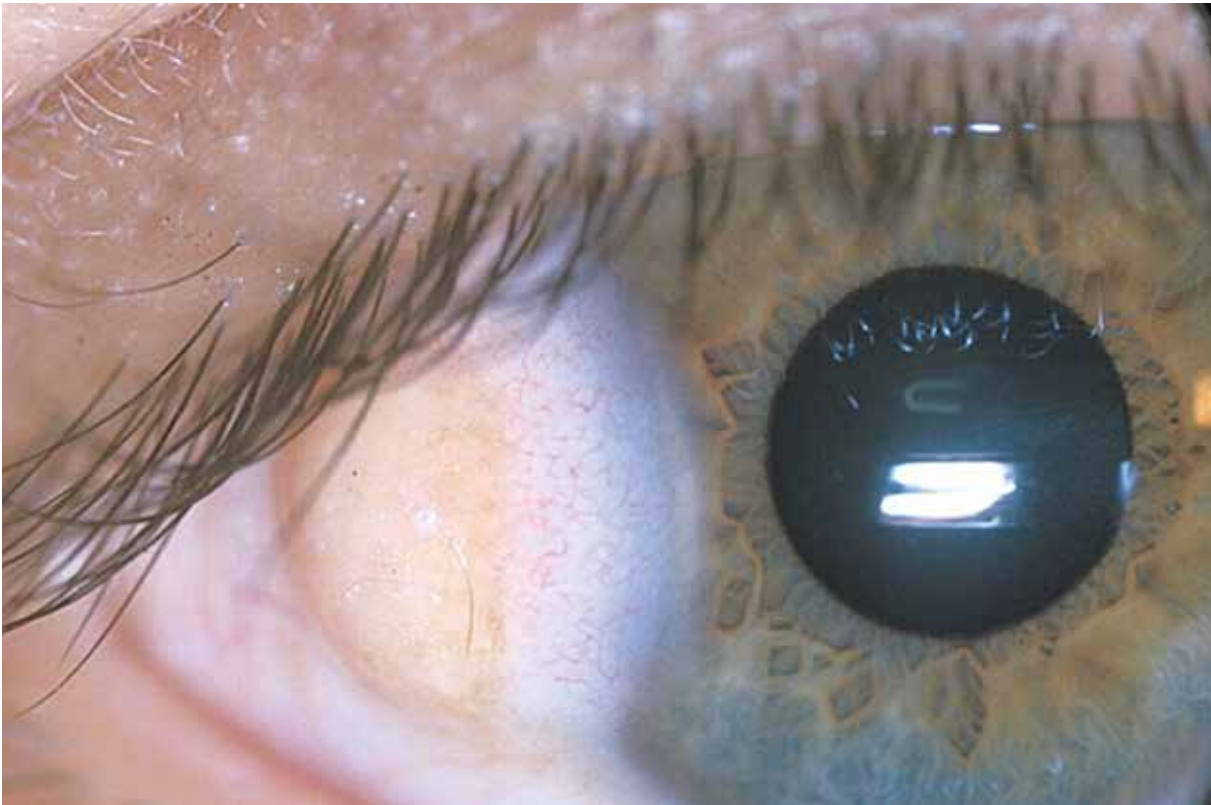
These are benign congenital malformations comprising histologically mature tissue components not normally present in the organ concerned. According to the tissue components, the following can be distinguished:

- limbus dermoids
- dermolipoma
- osteocartilaginous choristoma
- complex choristoma

On the ocular surface, the most common choristomas are limbus dermoids and dermolipoma.

These two types of choristoma can occur in isolation or coincide with a congenital malformation syndrome (Goldenhar syndrome or linear sebaceous nevus syndrome), particularly when involvement is bilateral.

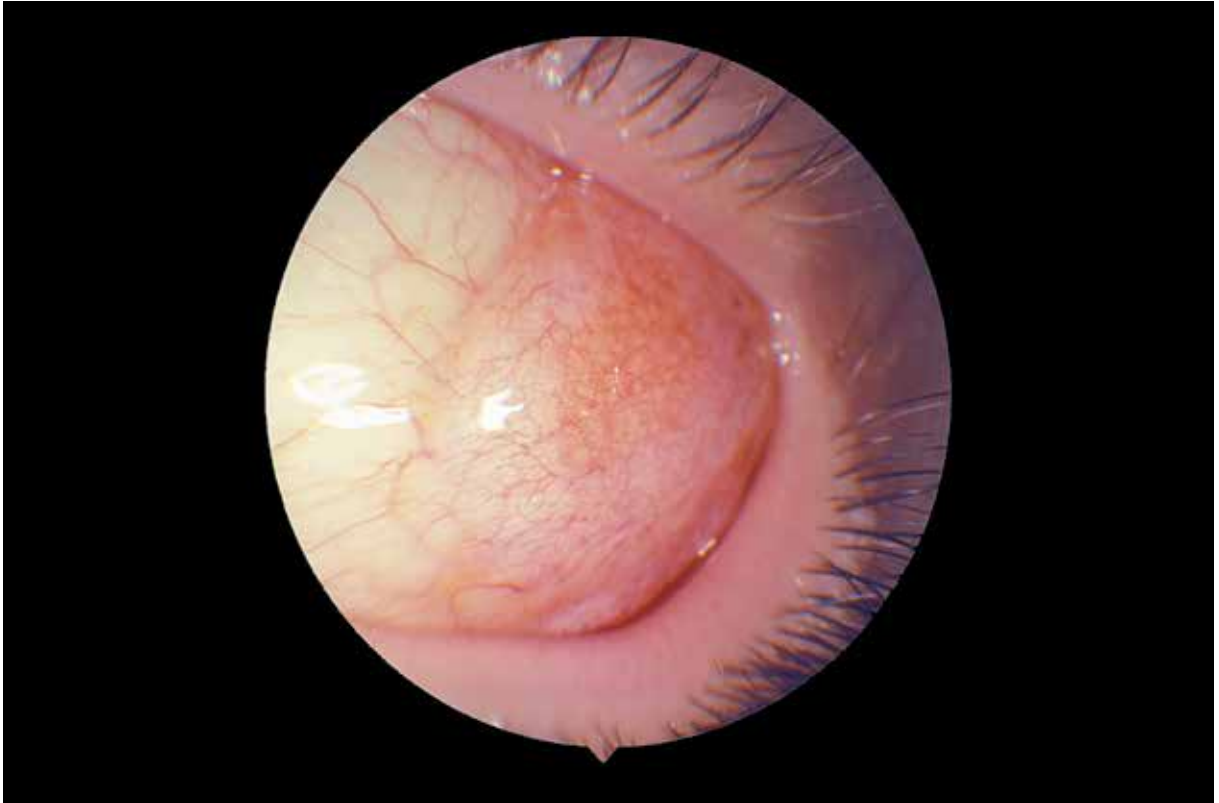Limbus dermoid tumors



Dermoids are single choristomas comprising cutaneous components (epidermis, hairs, sebaceous glands).

Present from birth and more common in girls, they are raised, rounded, firm, yellowish-white lesions, typically located on or straddling the limbus, often in the inferior temporal quadrant. They often contain dermal adnexal structures. The surface epithelium can be keratinized or not and they vary in size. In most cases, the lesion is small and asymptomatic, but large dermoids can cause astigmatism with loss of visual acuity.

Dermolipoma



Dermolipoma comprises the same components as dermoids but with more fat.

It is also a congenital lesion, but is often only easily detected in adulthood in the form of a soft, pale yellow, fusiform mass located around the palpebral portion of the lacrimal gland, in the upper temporal conjunctival bursa.

Adnexal dermal structures may or may not be present.

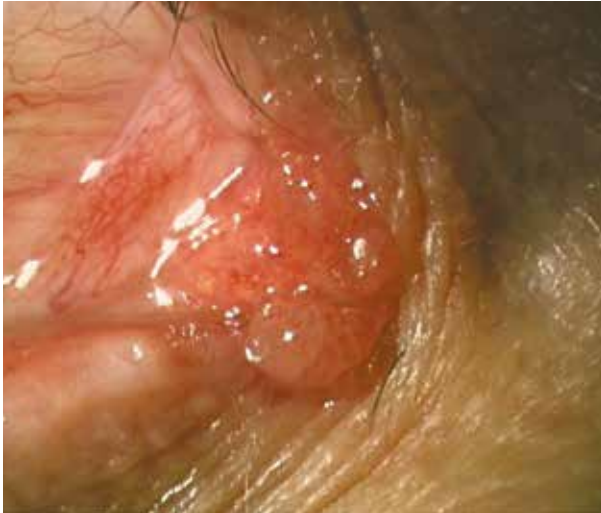These asymptomatic lesions do not require any treatment.



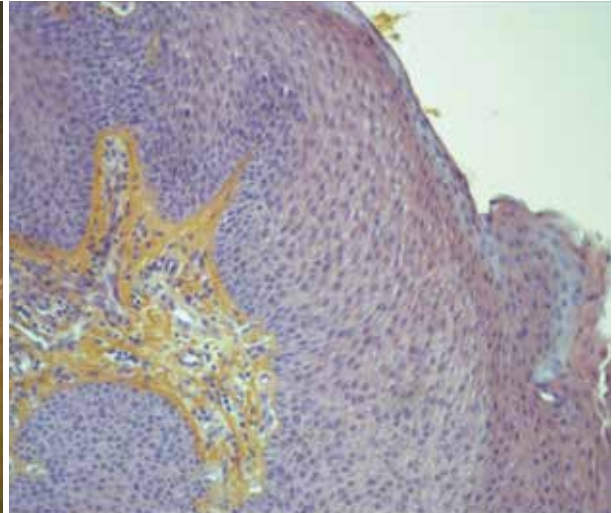


2. Epithelial tumors

Papilloma



Asymptomatic caruncular papilloma in a 60-year-old man.



Slit lamp view and histological section.

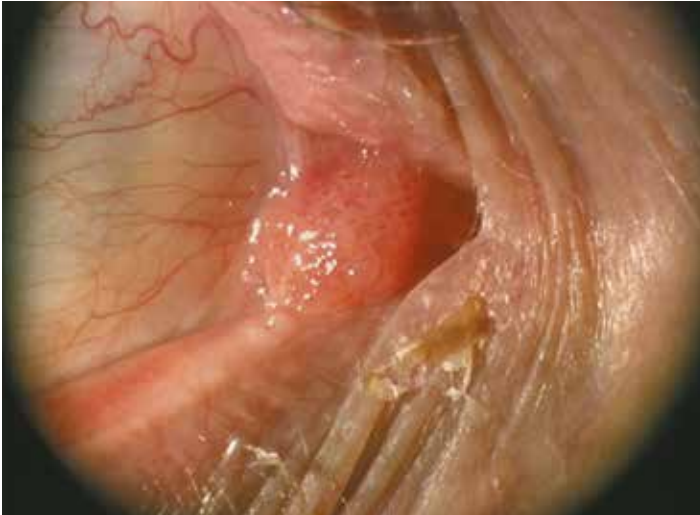
A conjunctival papilloma is a benign epithelial tumor that can develop in children and adults.

Its occurrence has been associated with a human papillomavirus conjunctival infection and in most cases is type 6 or 11 HPV with low carcinogenic risk. More rarely and especially in adults, it is type 16, 18 or 33 HPV, which are high-risk.

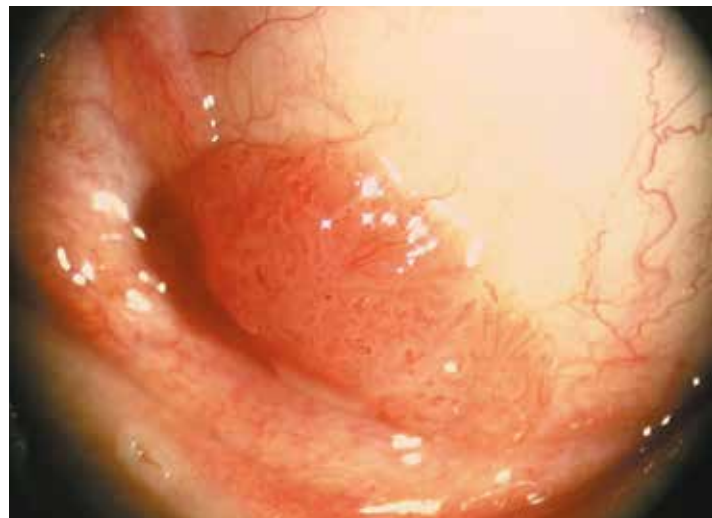If uncertain of the diagnosis with a carcinoma (particularly in adults) or when the lesion is large and symptomatic (bleeding, foreign body sensation, chronic mucous secretions, unsightly) surgical excision will be conducted. Surgical excision must be total to avoid any recurrence.

The histological analysis reveals fibrovascular papilla covered in a hyperplastic Malpighian epithelium but no cytonuclear anomalies. Moderate hyperkeratosis may be observed.

Papilloma



Caruncular papilloma that developed 2 months before in a 64-year-old man, stable since.



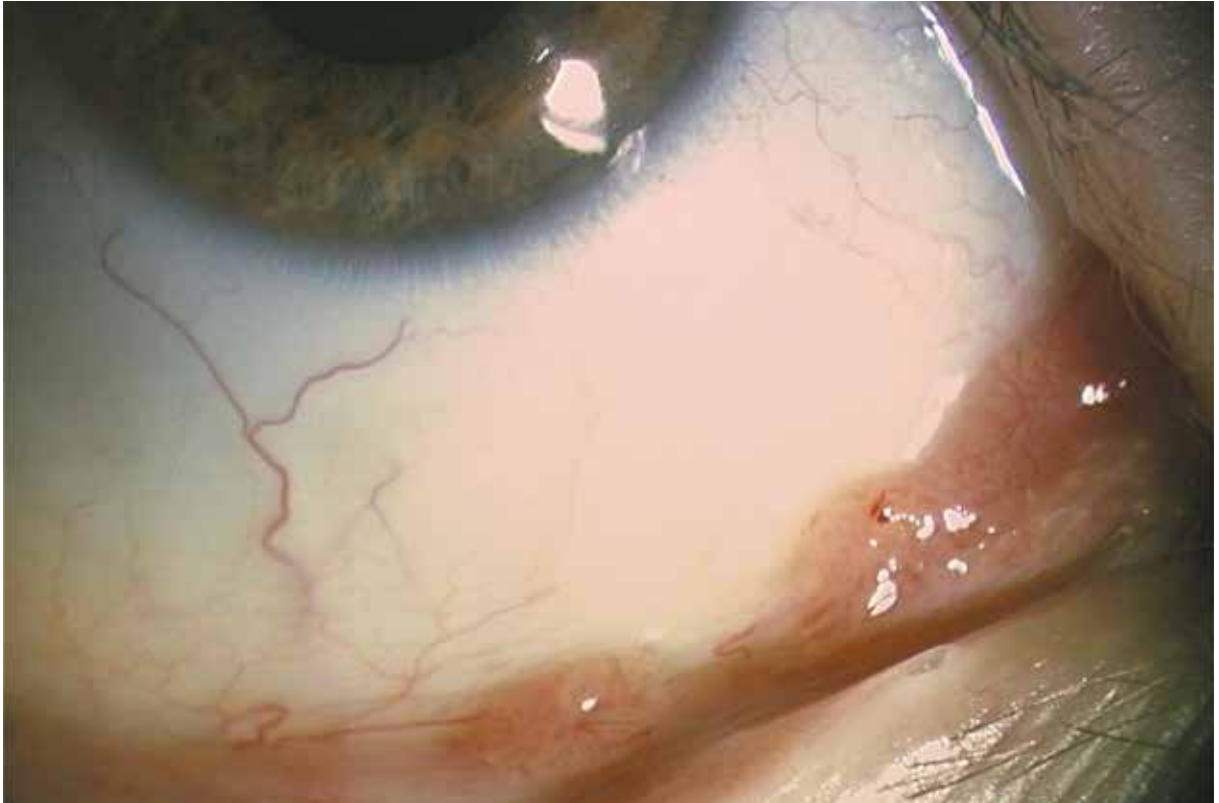
Pedunculated papilloma around the lower bursa present in a 39-year-old woman for 8 years, stable.

In adults, papillomas are often sessile and located around the caruncle.

They are generally unique, pink, slightly paler in children, papillomatous, and soft.

The differential diagnosis with a carcinoma can be very difficult: the presence of inflammation and/or leukoplakia must indicate the possibility of a neoplastic lesion. In most cases, an excisional biopsy is necessary for an accurate anatomopathological diagnosis.

Papilloma

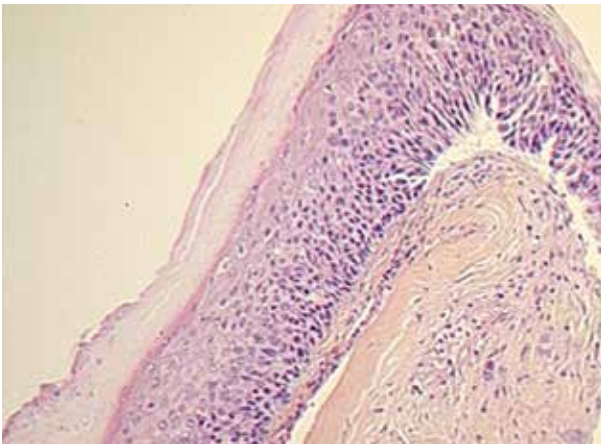


Multiple papillomas of the lower bursa in an 11-year-old child.

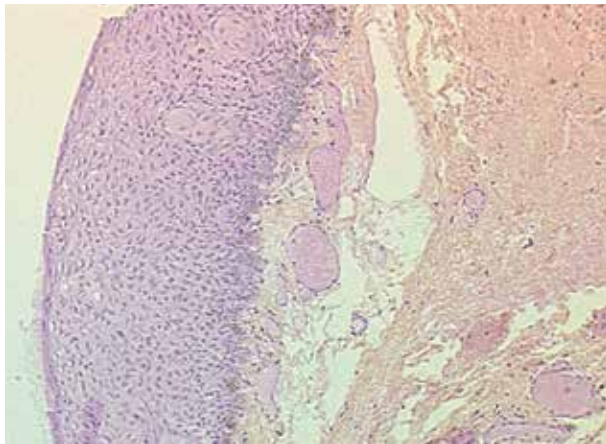
In children, papillomas are generally small, multiple, and located in the lower bursa. They are raspberry-pink, papillomatous, sessile or pedunculated growths.

The course of these papillomas is benign. They can regress spontaneously over several months or years. When they are well tolerated, monitoring can be proposed. Excision is only performed if the papilloma is irritant or unattractive.

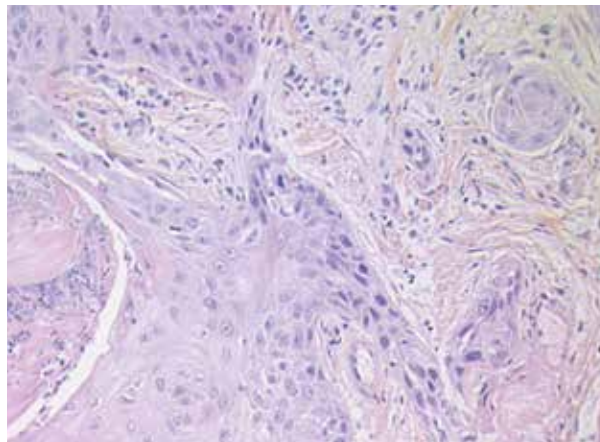
Dysplasia, carcinoma *in situ*, and invasive epidermoid carcinoma



Dysplastic lesion: presence of varying degrees of cellular atypia involving a variable thickness of the epithelium (most superficial layers of the normal epithelium).



Carcinoma *in situ*: presence of severe atypia involving the entire thickness of the epithelium and respecting the basal membrane.

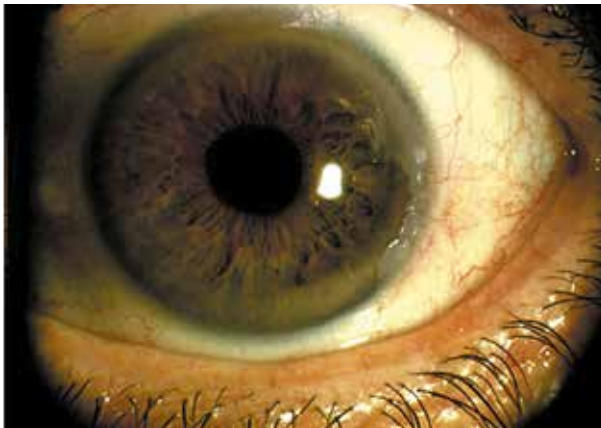

Invasive carcinoma: anomalies similar to carcinoma *in situ* but crossing the basal membrane and invasion of the underlying chorion.

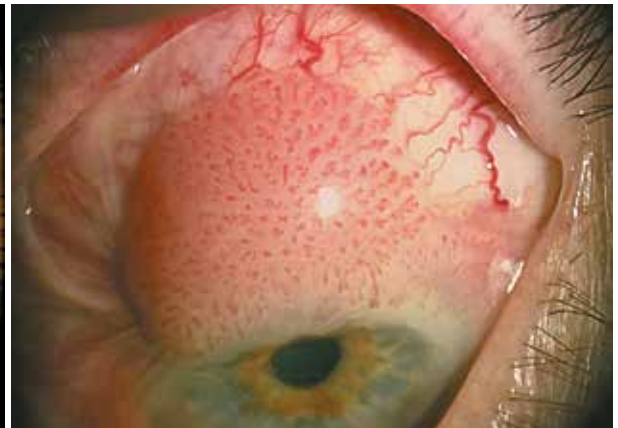Dysplastic conjunctival lesions, carcinoma *in situ*, and invasive epidermoid carcinoma are all epithelial neoplasia.

Dysplasia and carcinoma *in situ* are however only precancerous lesions (histologically tumoral proliferation remains strictly limited to the conjunctival epithelium and does not cross the basal membrane), whereas an invasive epidermoid carcinoma is an authentic malignant tumor with metastatic potential (tumoral proliferation crosses the basal membrane of the epidermis and invades the chorion).

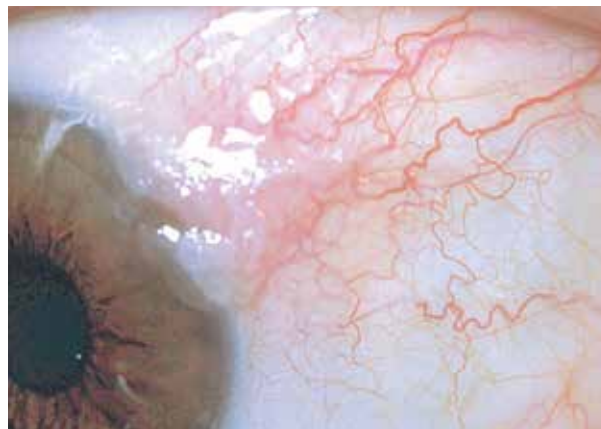
Dysplasia, carcinoma *in situ*, and invasive epidermoid carcinoma



Carcinoma *in situ*: translucent, gelatinous, planar thickening involving the limbus and spread across the adjacent corneal epithelium.



Carcinoma *in situ*: raised papillomatous swelling on the surface with dilated feeder vessels.



Dysplasia: leucoplakic lesion with keratinization on the surface of the conjunctival epithelium, invasion of a few millimeters of the adjacent corneal epithelium.

These lesions develop at around the age of sixty, more often in men than women.

They predominantly straddle the limbus, next to the palpebral fissure.

Slightly raised, more or less fleshy, sessile, greyish-white to pink, the lesion initially progresses on the surface, towards the cornea, over a few weeks to a few years.

The clinical presentation varies with an achromatic lesion that can be gelatinous, flat, and translucent around the limbus, or papillomatous and more or less raised, making it hard to differentiate from a benign papilloma, or leucoplakic with a keratin plaque on the surface. The clinical distinction between dysplasia, carcinoma *in situ*, and invasive carcinoma is often difficult.

Dysplasia, carcinoma *in situ*, and invasive epidermoid carcinoma



Plaques of different sizes containing Iodine 125 used for ocular radiotherapy.



Patient in treatment position for ocular proton beam therapy.

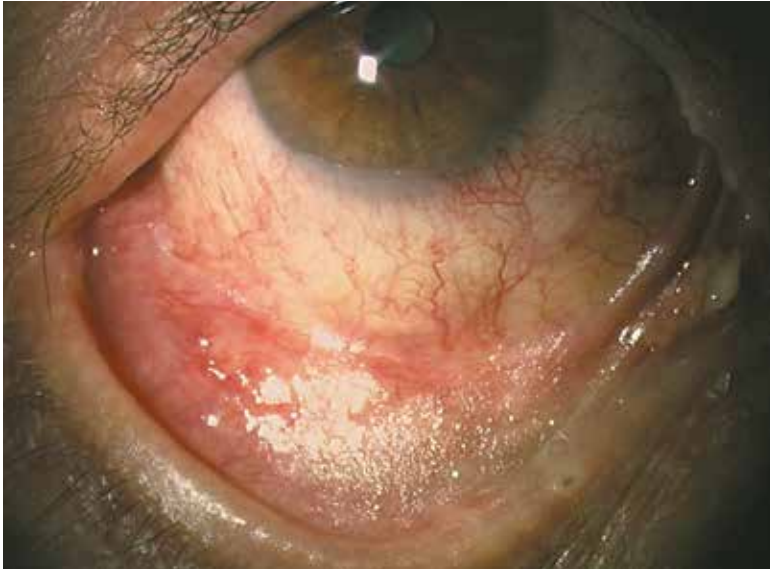Traditionally, treatment is surgical excision of the lesion.

Currently, topical chemotherapy is being increasingly used, alone or in combination with surgery to treat epidermoid neoplasia on the ocular surface. This must, however, be restricted to purely intra-epithelial neoplasia (dysplasia, carcinoma *in situ*) hence the need for a biopsy beforehand.

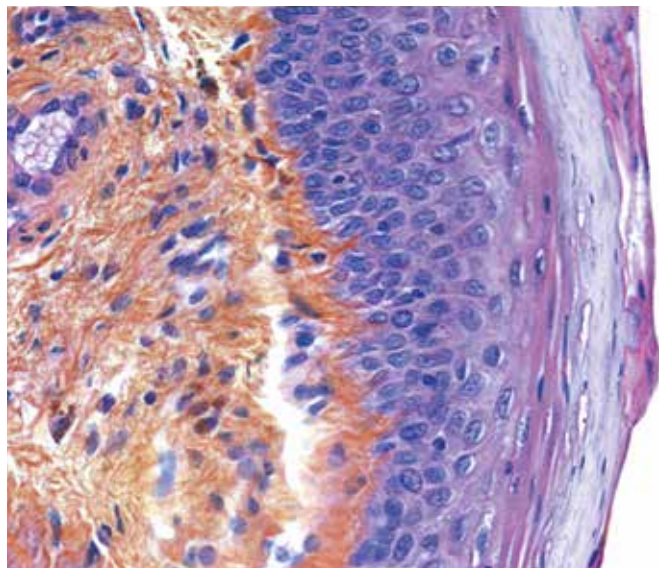
In the case of invasive carcinoma, complementary radiation therapy will often be carried out in addition to surgical excision, as the local risk of recurrence is approximately 40% in the absence of complementary treatment.

Adjuvant radiotherapy can be performed with conventional external radiation, brachytherapy or proton therapy.

Low-grade dysplasia

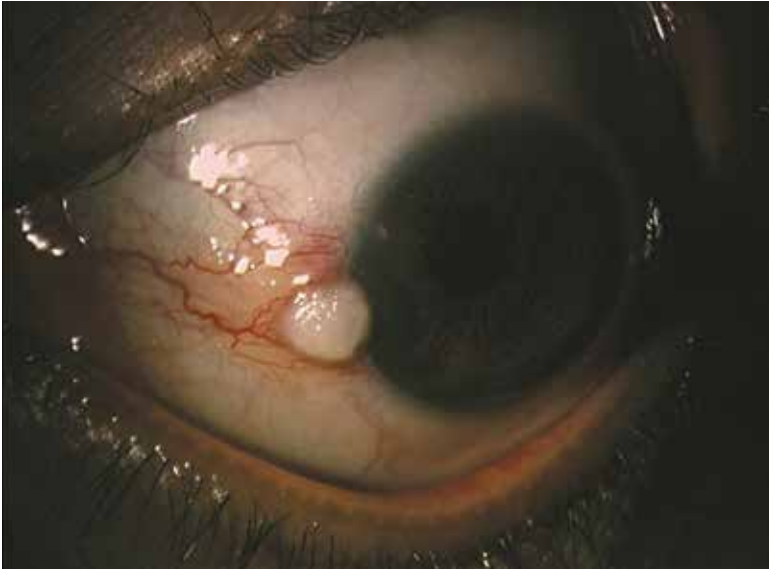

Lesion with very few symptoms progressing very slowly over 2 years in a 75-year-old man. On examination, planar, achromatic, gelatinous conjunctival lesion around the lower limbus and leucoplastic around the palpebral conjunctiva.

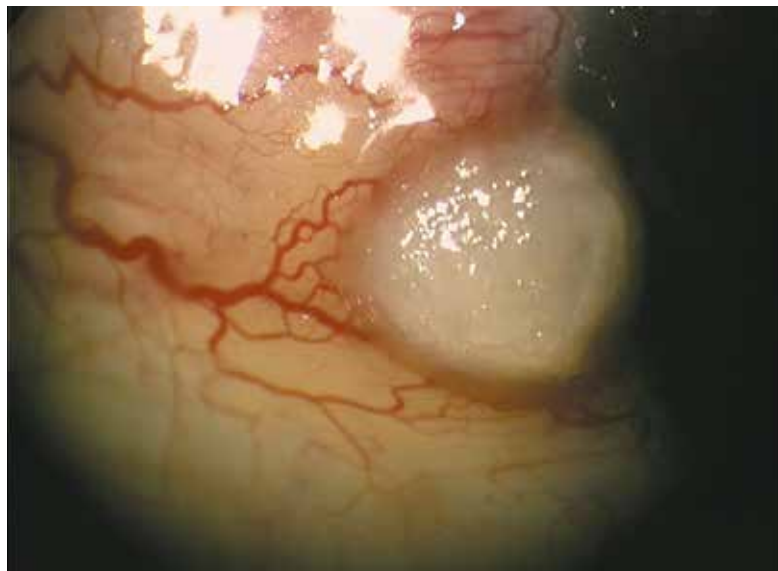


Histologically, it is a low-grade intra-epithelial epidermoid neoplasia: the Malpighian epithelium is overall clearly differentiated with progressive maturation, but a discrete focal cyto-architectural disorganization can be observed in the basal cells (a few nuclear irregularities, verticalization of the nuclei and mitosis present only in the basal layers). The chorion is moderately inflamed.

Carcinoma *in situ*



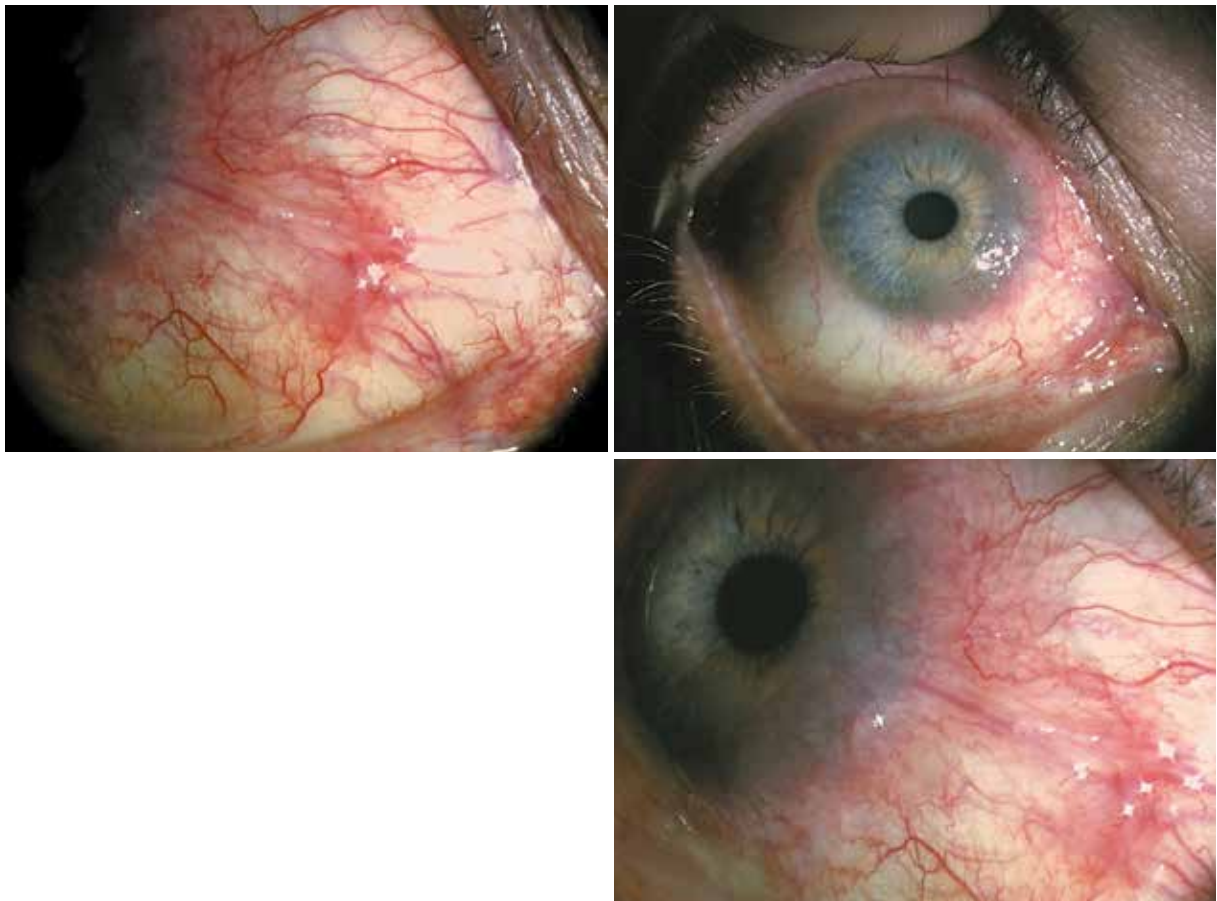Comorian patient aged 29 years. Lesion appeared 3 months before with progressive growth.



Upon examination, 3-mm limbic swelling, slightly raised, not pigmented, keratinized on the surface, slightly inflammatory.

Histologically, it is a high-grade intra-epithelial epidermoid neoplasia or carcinoma *in situ*. The epithelium is centered by a hyperplastic lesion with orthokeratotic hyperkeratosis on the surface, architectural disorganization with atypical cells and mitosis. In the upper third of this coating there is cellular wrapping centered by dyskeratotic cells. The chorion is not invaded. Treatment consists in surgical excision complemented with topical chemotherapy.

Carcinoma *in situ*



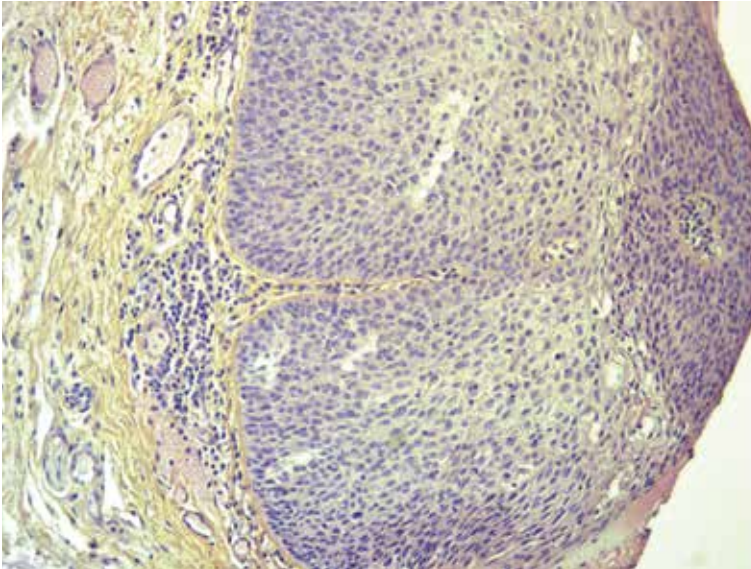
Patient aged 59 years consulting for a «red» right eye and feeling of ocular irritation that has been progressing for 7 months. VA RE 9/10.

Under slit lamp, the nasal bulbar conjunctiva has thickened with a translucent gelatinous membrane on the surface, very slightly papillomatous in places.

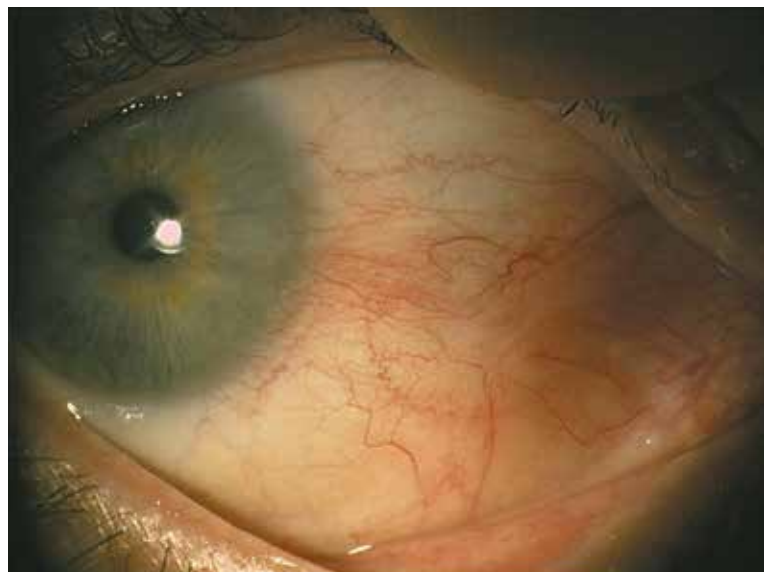The lesion extends across the limbus and the nasal cornea.

Carcinoma *in situ*

(same patient as previous page)

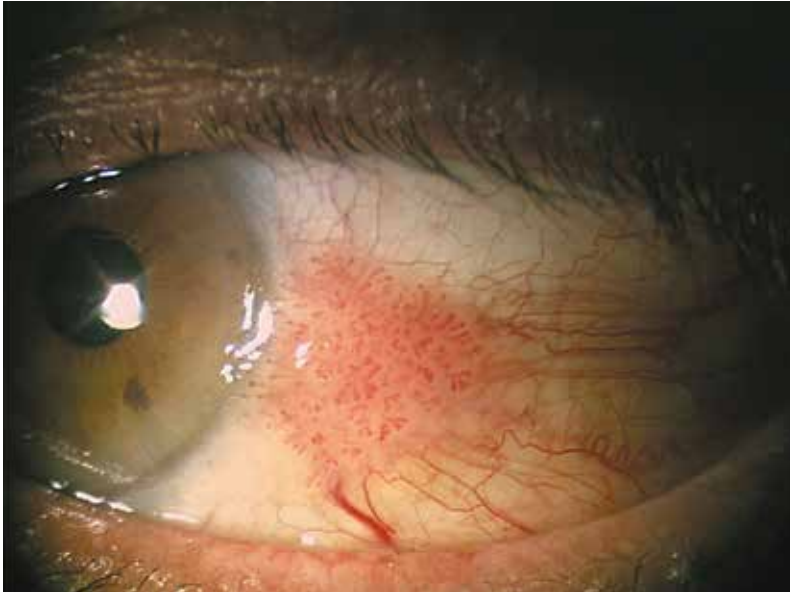

Given the extent of the lesions, there was no total surgical excision but multiple biopsies. The conclusion was a high-grade intra-epithelial neoplastic lesion (carcinoma *in situ*) with Malphigian metaplasia of the conjunctival mucosa presenting neoplastic cells with cytonuclear atypia extending through the entire thickness of the epithelium associated with a few dyskeratotic cells and cellular wrapping. There is also ascending mitosis. The chorion is fibro-vascular and slightly inflammatory, but not invaded.

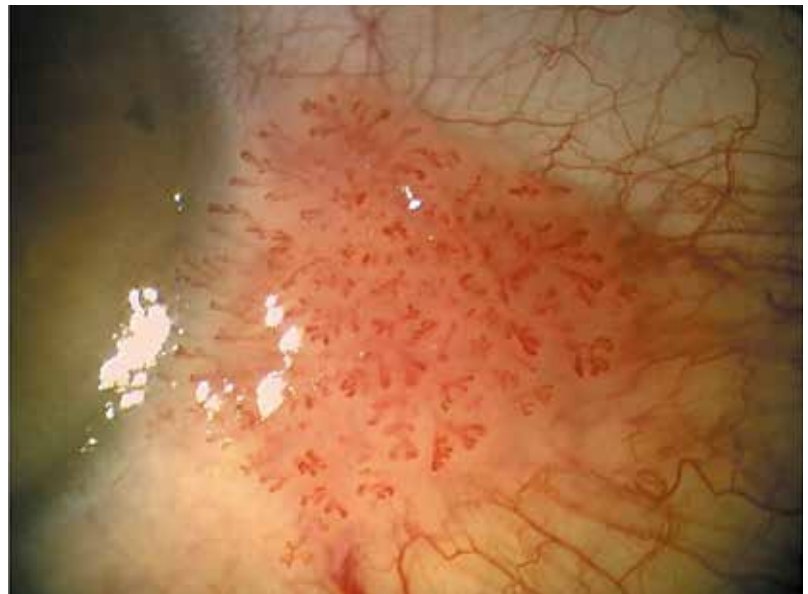

The patient received topical chemotherapy with complete disappearance of the lesions. Slit lamp view 3 years after the end of treatment with antineoplastic eye drops. VA RE 10/10.

Carcinome *in situ*



Patient aged 64 consulting with a right eye that had been «red» for 9 months. VA of 10/10 maintained.

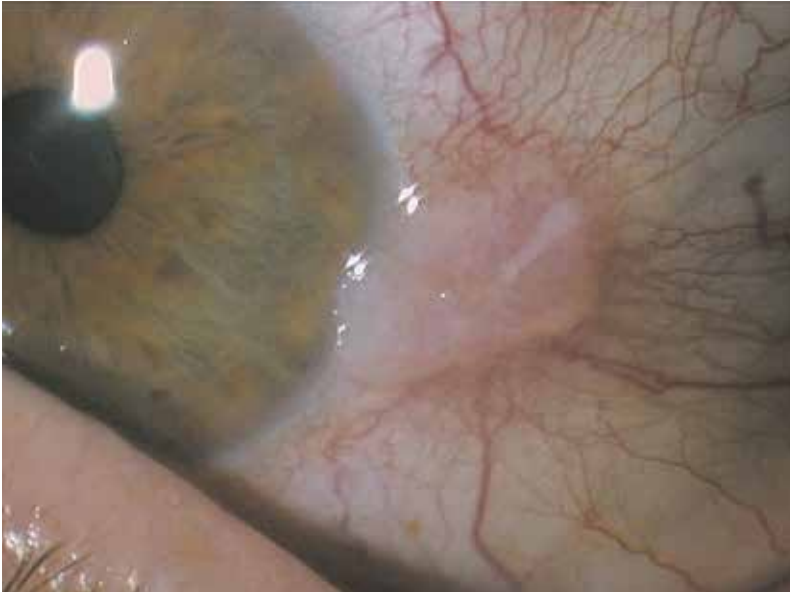

Upon examination, a raised, papillomatous, sessile nasal swelling with a dilated feeder vessel is observed.

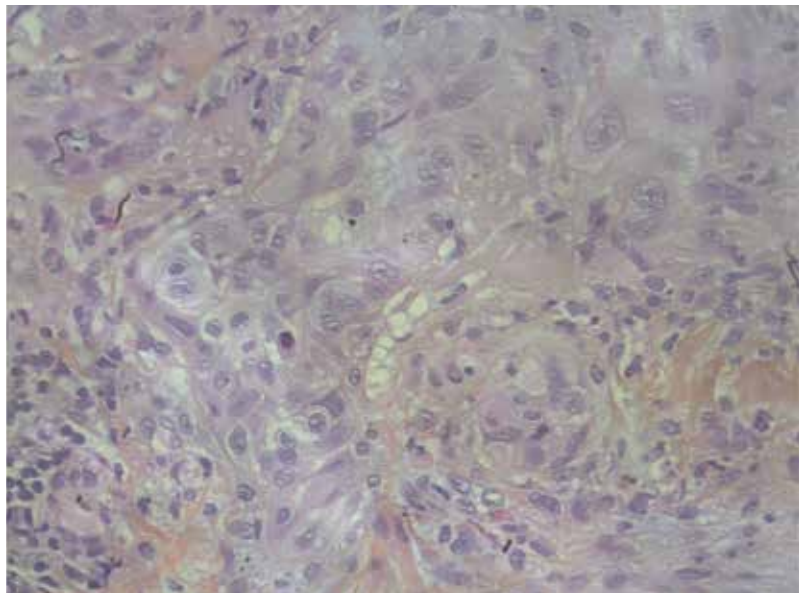
The conclusion of the anatomopathological analysis was an intra-epithelial epidermoid neoplasia with severe atypia or carcinoma in situ (the conjunctival epithelium is disorganized throughout its depth with sometimes very atypical cells, ascended mitosis, and dyskeratotic cells. The chorion is elastotic but with no tumoral infiltration).

The treatment consists in surgical excision complemented with topical chemotherapy.

Invasive epidermoid carcinoma



Patient aged 59 presenting with left ocular «redness» located on the temporal side for 4 months.

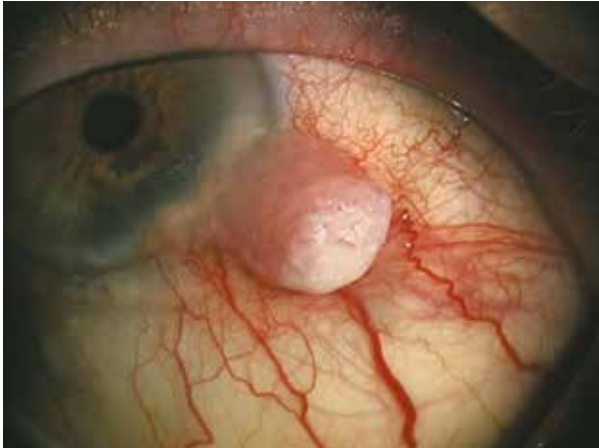


The examination revealed a small translucent lesion at 3 o'clock, slightly raised and very slightly papillomatous with a few dilated vessels around it.

The anatomopathological analysis revealed a **clearly differentiated keratinizing epidermoid carcinoma** (epithelium Malpighian with loss of cell polarity, architectural modifications involving the entire depth of the epithelium and infiltration of the underlying chorion, cytonuclear atypia sometimes marked, ascended mitosis in the epithelium).

Treatment consisted in surgical excision complemented with proton beam therapy.

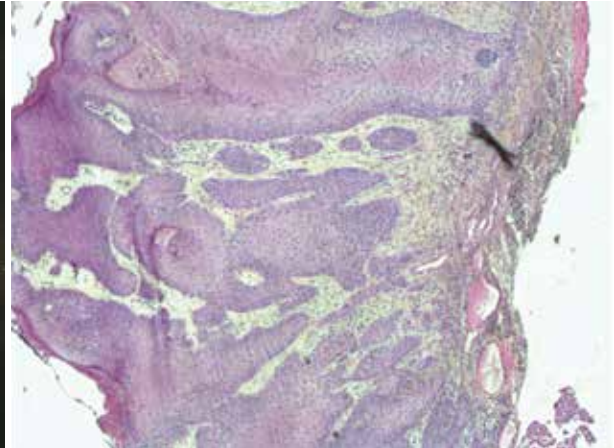
Invasive epidermoid carcinoma



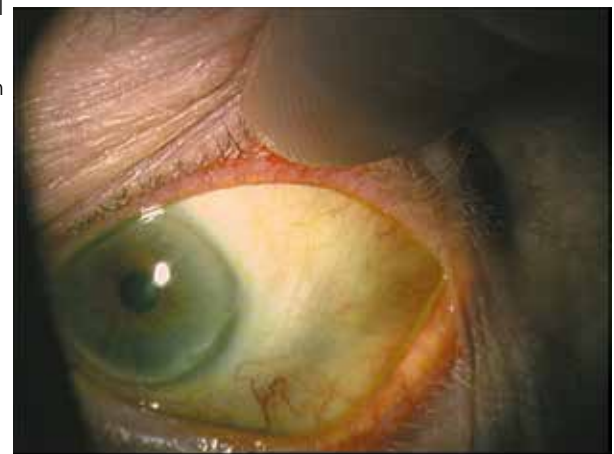Patient aged 54 presenting with a left ocular lesion growing progressively over 3 months.

The examination revealed pink swelling around the temporal limbus, clearly raised and keratinized on the surface, encroaching slightly on the cornea with several dilated feeder vessels around it.

The conclusion of the anatomopathological analysis was an invasive epidermoid carcinoma.



Invasive carcinoma: presence of severe atypia involving the entire thickness of the epithelium with crossing of the basal membrane and invasion of the underlying chorion.



Treatment consisted in surgical excision complemented with radiation therapy with plaques containing iodine 125 seeds. Slit lamp post-therapeutic appearance.

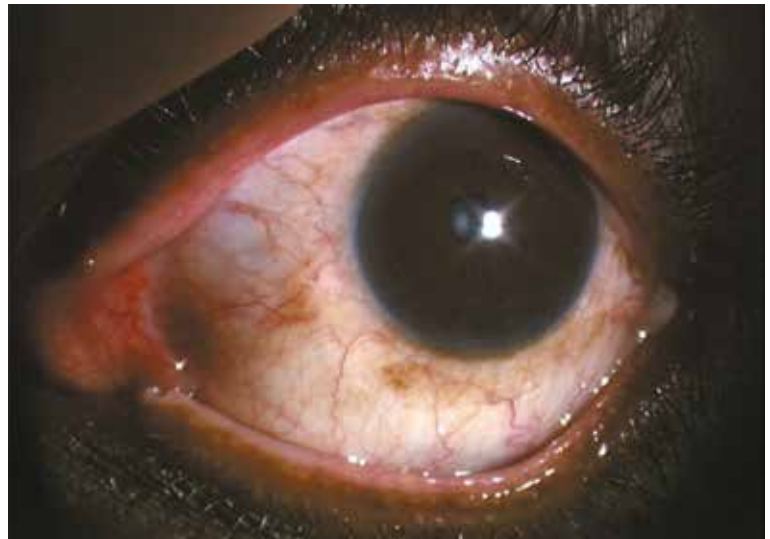
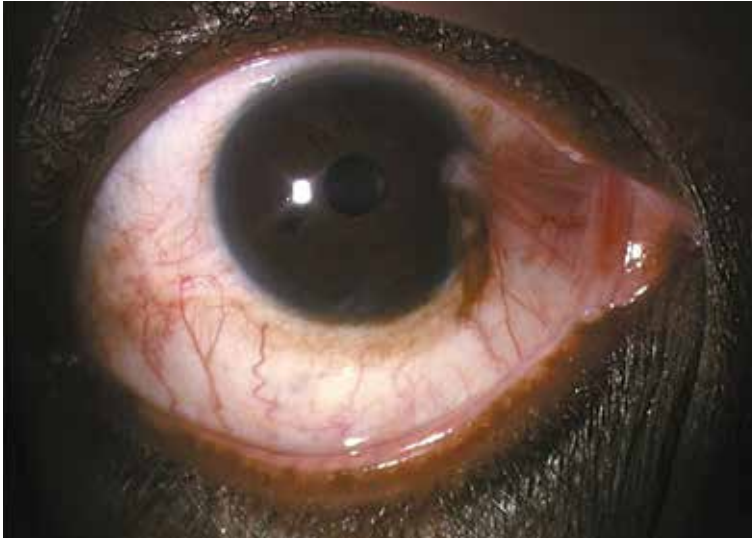


3. Melanocytic tumors

Melanocytic tumors

Ethnic melanosis



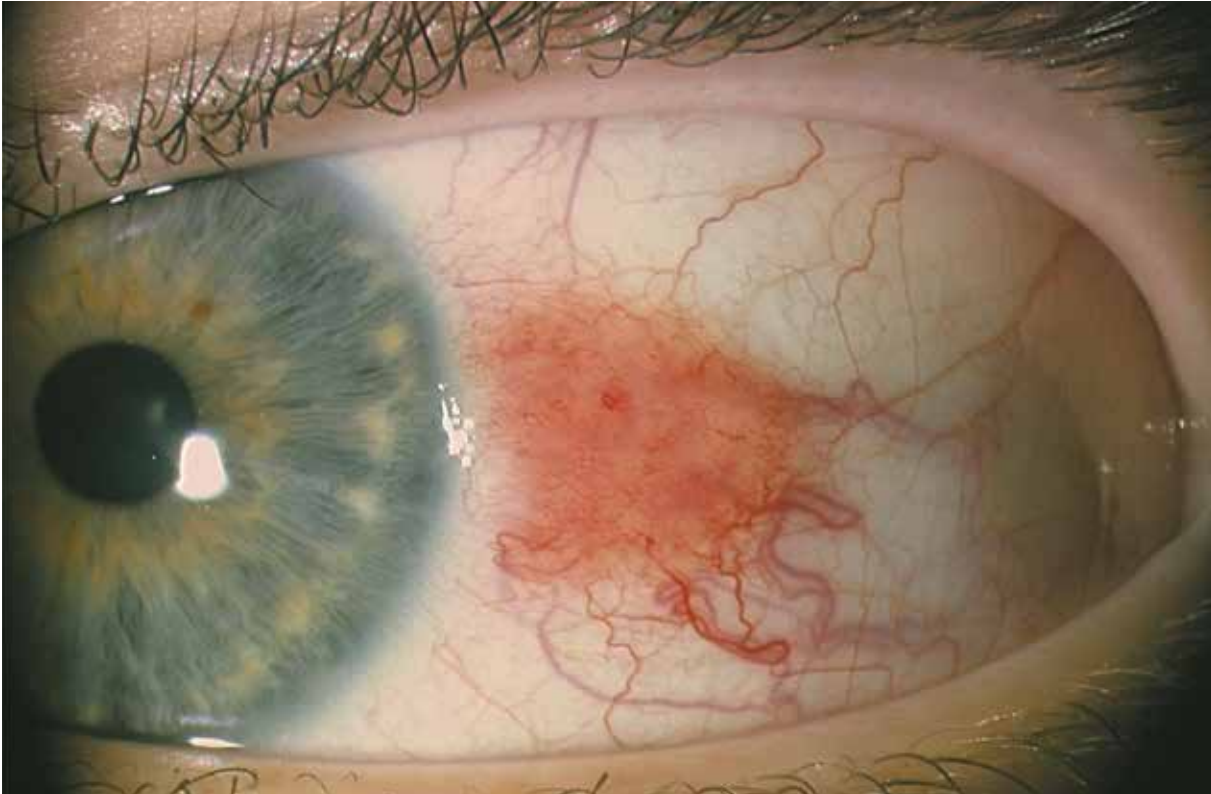
Patient aged 36 of Central African origin presenting with a bilateral ethnic melanosis associated with a pterygium on the right eye.

Racial congenital conjunctival melanosis is not a genuine tumor. There is no real cell proliferation, but a greater number of melanocytes containing more melanin.

The histological examination revealed no atypical cells. This melanosis has no potential for malignant degeneration and is only observed in melanoderm patients.

The conjunctival pigmentation of varying intensity, planar, bilateral, and relatively symmetrical has been present since the patient was young. It predominates in the limbus.

Conjunctival nevus



Sometimes, a fine vascular network (particularly when the lesion is weakly pigmented like here in a 7-year-old child) or the presence of one or two dilated episcleral vessels around the edge can be observed.

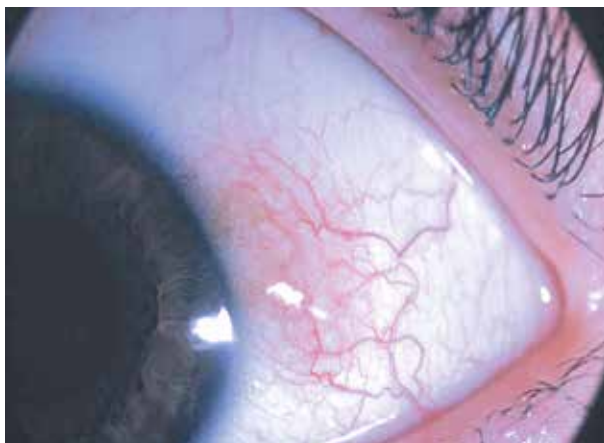Conjunctival nevi are the most common conjunctival tumors. They are benign melanocytic tumors.

Nevi can be clinically present at birth or appear during the first/second decade. They are flat or sessile lesions, very slightly raised, and generally located on the bulbar conjunctiva around the palpebral fissure. Pigmentation is variable: nevi are often achromatic in small children and progressively become pigmented during childhood and especially adolescence. The presence of intra-lesional cysts is possible and asserts the benign nature of the lesion.

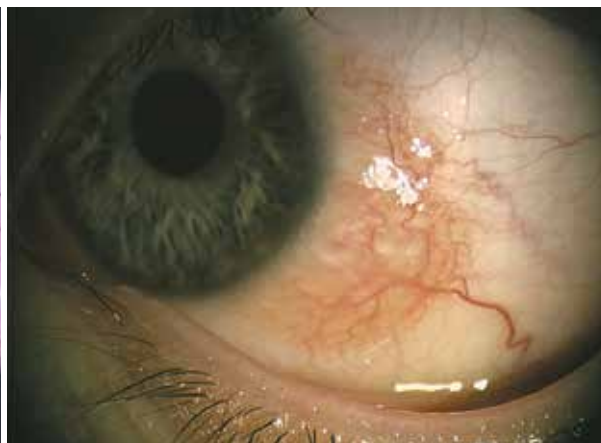Histologically, the nevus comprises nevus cells arranged in nests initially located at the junction between the epithelium and the chorion, which then descend in the chorion and lose their connections with the epithelium.

The risk of malignant transformation into melanoma is very low. The best approach is regular surveillance.

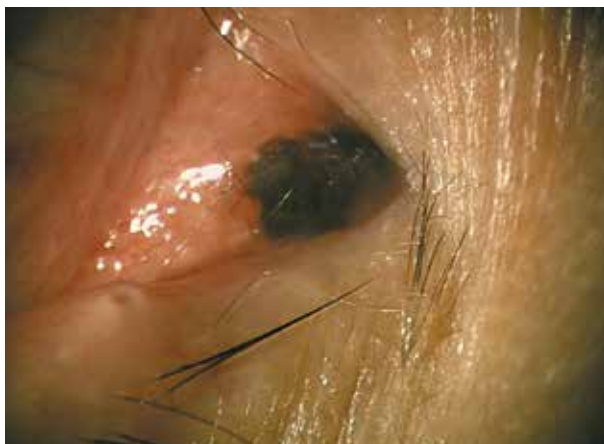Conjunctival nevus



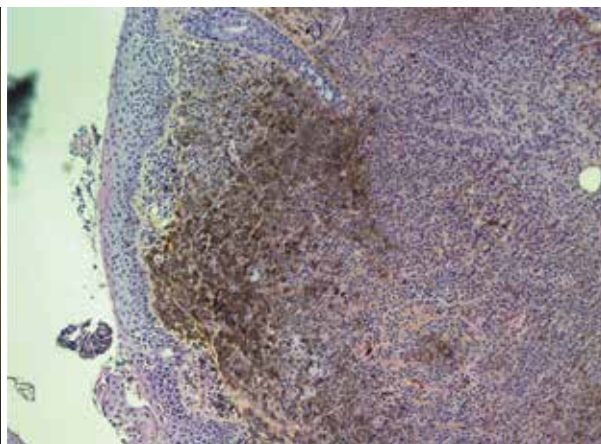
Totally achromatic nevus with a pink appearance in an 8-year-old child.



Large nevus very slightly pigmented with numerous cysts in 13-year-old child. The presence of a feeder vessel can be observed.

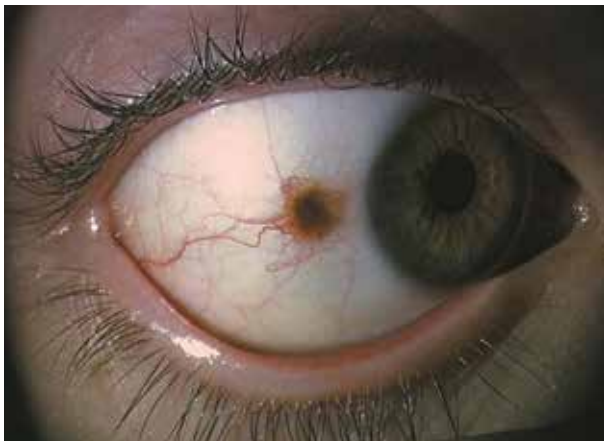

Highly pigmented caruncular nevus in a woman aged 67 years. The patient has had this lesion since adolescence with no recent modification. Hairs can be observed in the nevus.

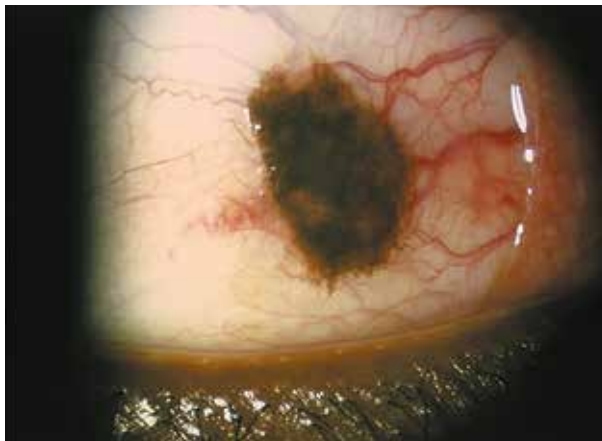


The histological section shows a subepithelial nevus with subepithelial melanocytic proliferation bulging under the epithelium in the form of poorly defined eminences comprising small cells with rounded nuclei lacking cytonuclear atypia and mitotic activity. Their cytoplasm is pigmented particularly on the surface of the lesion. There is a maturation gradient. A few cyst formations can be observed.

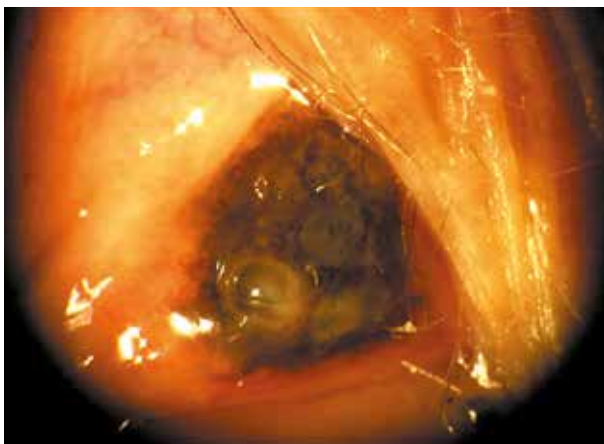Conjunctival nevus



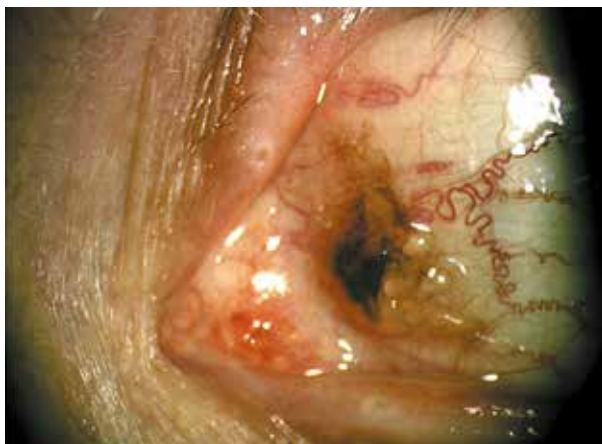Nevus with heterogeneous pigmentation observed recently in a 13-year-old child.



Highly pigmented, mildly cystic nevus in an 8-year-old melanoderm child. On questioning the parents, the lesion has been present for 5 to 6 years with no recent modifications.

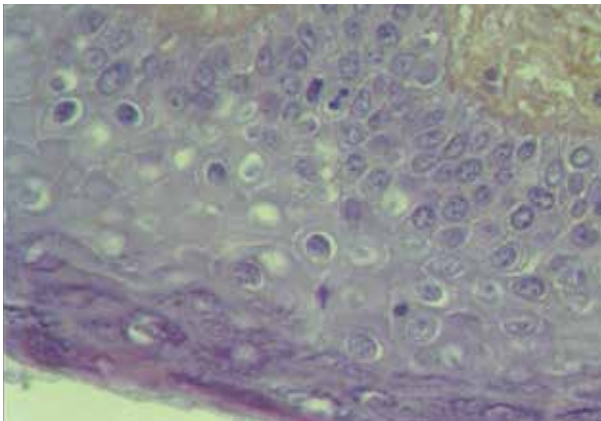


Caruncular nevus with large cysts in a 58-year-old patient. The patient has been aware of the lesion since their youth and it is perfectly stable.

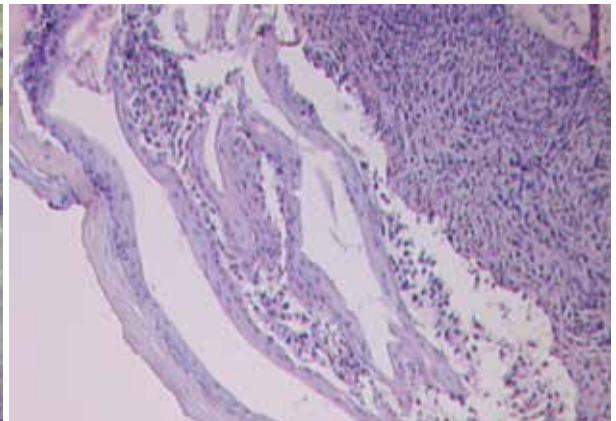


Pigmented, cystic nevus in a 72-year-old patient of North African origin. The patient has been aware of the lesion and it has been stable since childhood.

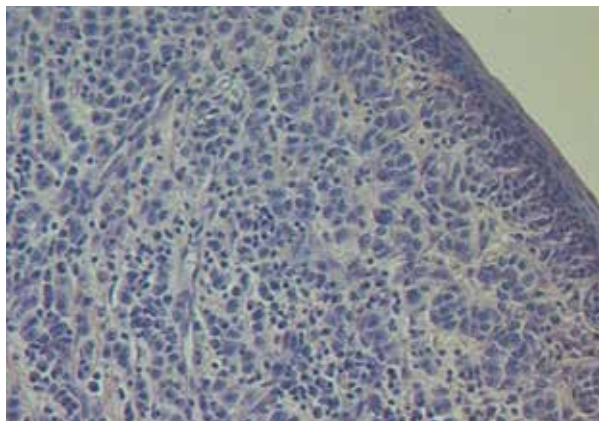
Precancerous Reese melanosis, melanoma in situ, and invasive melanoma: histological differences



Precancerous Reese melanosis: intraepithelial proliferation with cell atypia more or less pronounced involving a variable thickness of the epithelium (superficial layers of the epithelium = normal).



Melanoma *in situ*: intraepithelial proliferation with severe atypia involving the full thickness of the epithelium and respecting the basal membrane.

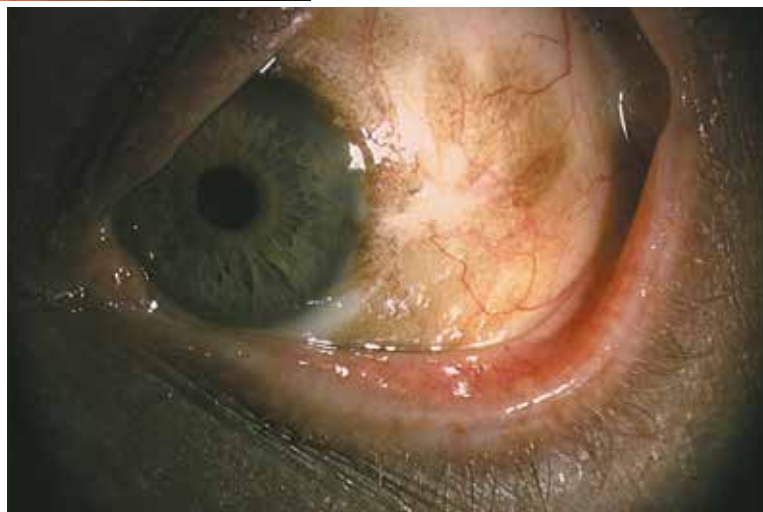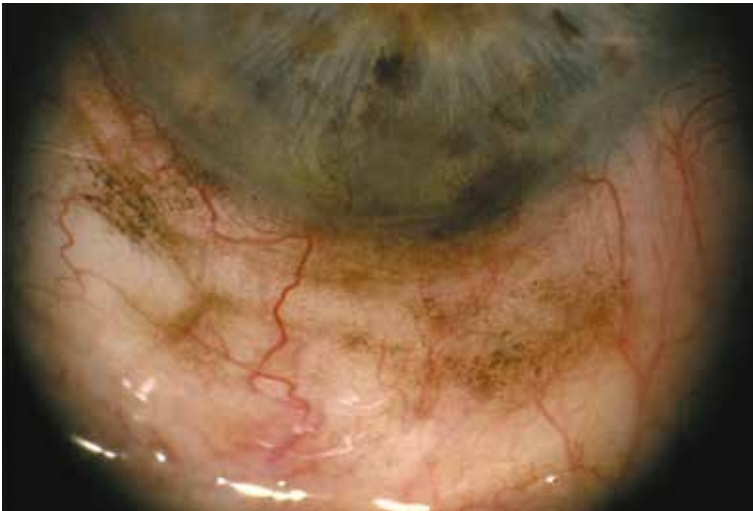


Invasive melanoma: epithelial proliferation crossing the basal membrane and invading the chorion with severe atypia, presence of abnormal mitosis.

Precancerous Reese melanosis, melanoma in situ, and invasive melanoma are all tumoral proliferations of atypical melanocytes.

Precancerous Reese melanosis and melanoma *in situ* are however only precancerous lesions (histologically, tumoral proliferation remains strictly limited to the conjunctival epithelium and does not cross the basal membrane), whereas an invasive melanoma is an authentic malignant tumor with metastatic potential (tumoral proliferation crosses the basal membrane of the epidermis and invades the chorion).

Precancerous Reese melanosis



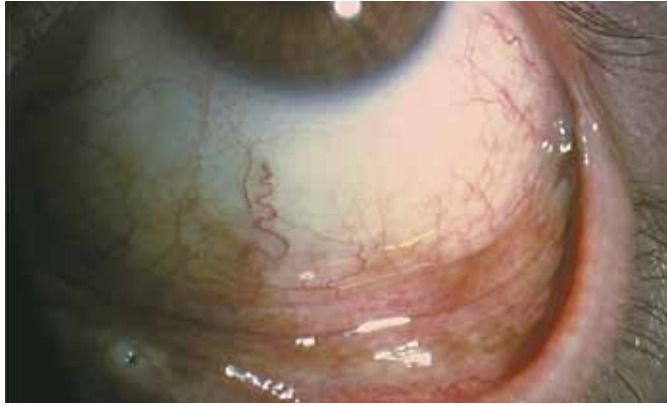Woman aged 52 years presenting with a precancerous conjunctival Reese melanosis of the left eye. The pigmentation developed 4 years ago and has spread over the surface. There is contiguous pigmentation of the corneal epithelium between 5 and 6 o'clock.

Precancerous Reese melanosis or primary acquired melanosis with atypia corresponds to strictly intraepidermal melanocytic proliferation with presence of more or less marked cytonuclear atypia.

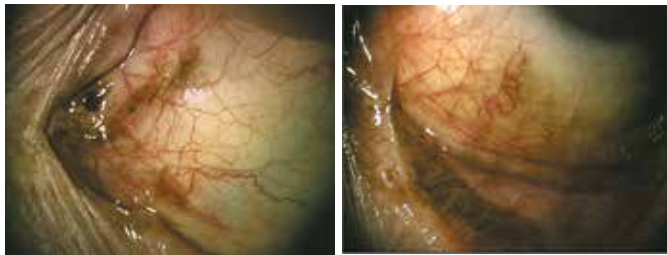
Clinically, it is a more or less dense planar unilateral conjunctival pigmentation of the bulbar and/or palpebral conjunctiva that sometimes spreads to the corneal epithelium.

It develops in adults, more often after the age of 40 or 50. The pigmentation often tends to spread across the surface over the years. These precancerous lesions regularly progress towards the formation of invasive conjunctival melanomas.

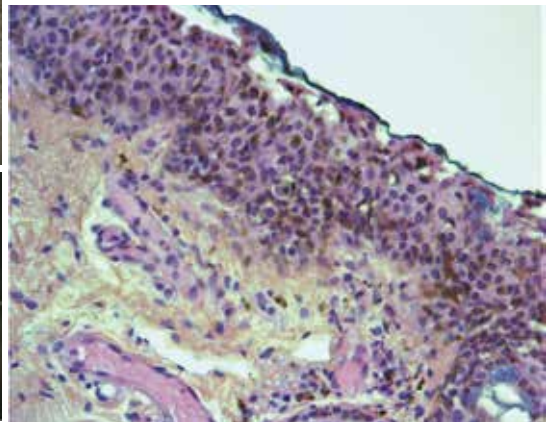
Precancerous Reese melanosis



2009: man aged 56 presenting with a left conjunctival melanosis that developed 10 years ago. The pigmentation, discreet and progressing little, predominates on the lower palpebral conjunctiva. A first biopsy was conducted in town a few years earlier but did not find any cytonuclear atypia.



2015: six years later, the pigmentation has clearly changed and intensified on the lower palpebral conjunctiva with a suspicious zone in the caruncular region. Further biopsy samples were taken.



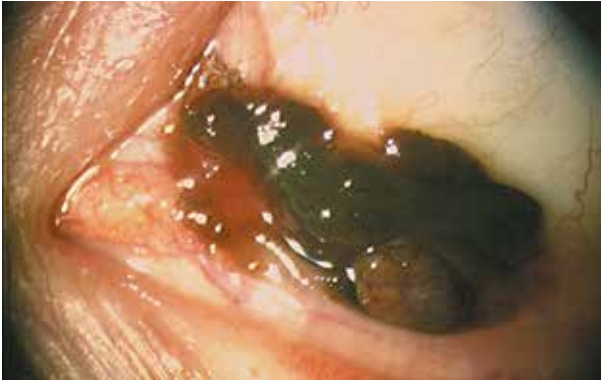2015: the conclusion of the histological analysis was an acquired melanosis with moderate to severe atypia.

Lentiginous melanocytic proliferation is observed with pagetoid ascent (vertical invasion by melanocytic cells over 50% to 90% of the depth of the epithelium). The melanocytic cells present focally minimal cytonuclear atypia. No mitosis or invasion of the chorion was observed.

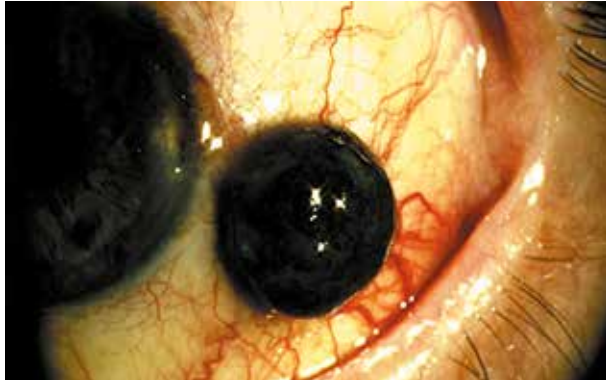In the case of lesions that are less than an hour quadrant, it is possible to settle with surveillance.

If the lesions are more widespread or progressive, «map biopsies» will be conducted to confirm the diagnosis and specify the extent of cytonuclear atypia. According to the anatomopathological results, treatment with cryotherapy or antineoplastic eye drops could be discussed.

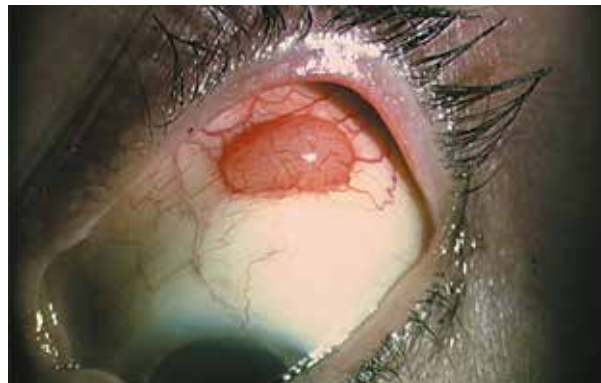Conjunctival melanoma



Melanoma of the lower bursa + semi-lunar fold.



Invasive melanoma on a Reese melanosis.



Recurrence of achromatic melanoma.

An invasive melanoma is a life-threatening malignant tumor with a 5-year risk of around 16% and a 15-year risk of around 32% of metastatic lymph or visceral spreading.

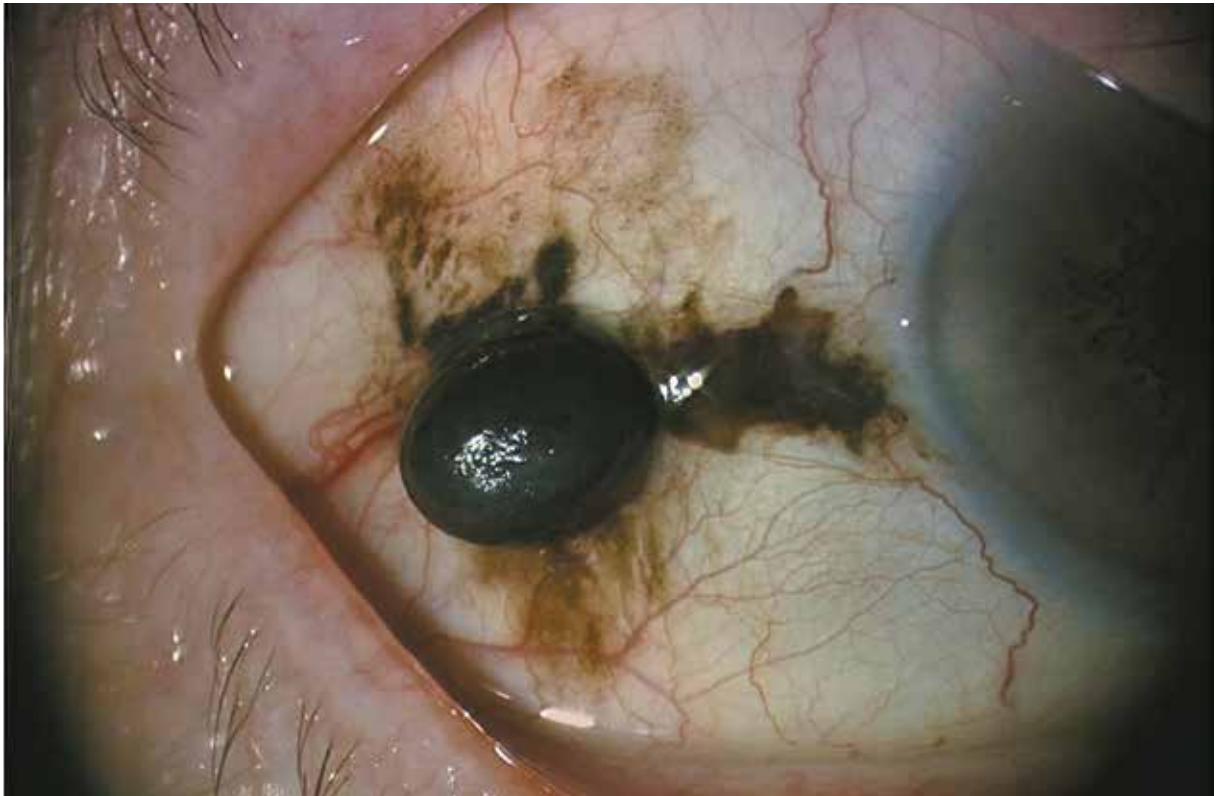
In more than half of cases, it develops on a precancerous Reese melanosis but can also occur on a healthy conjunctiva (melanoma «de novo») or on a pre-existing nevus.

The clinical appearance of a conjunctival melanoma is extremely variable. In 70% of cases, it presents as a raised pigmented lesion with feeder vessels.

However, some melanomas can be completely achromatic, which can lead to problems of differential diagnosis with an inflammatory granuloma or an epidermoid carcinoma.

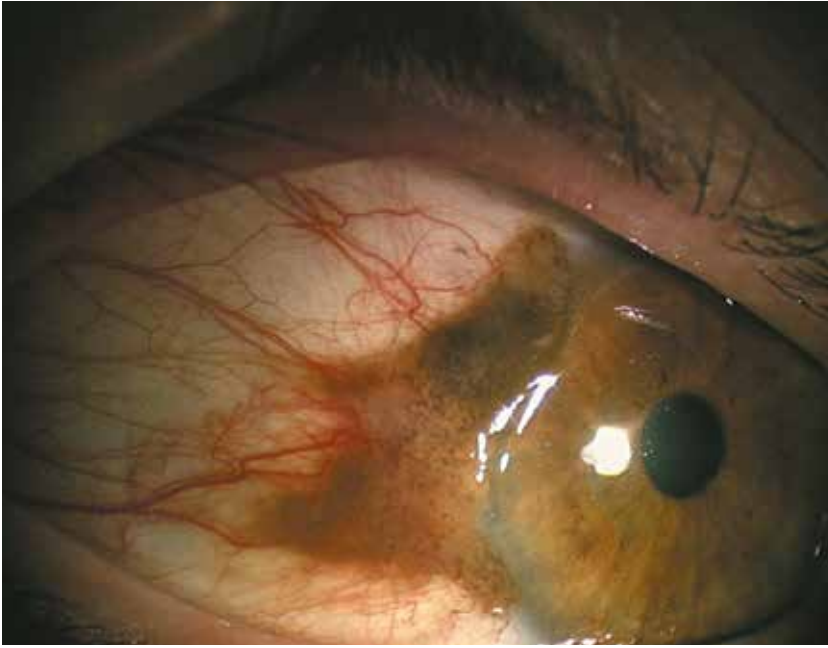
The recent emergence in a patient aged between 50 and 60 years, the raised appearance with progression often relatively rapid, and the firm nature on palpation must indicate a malignant tumor. The absence of keratinization on the surface or papillomatous appearance, the association with precancerous Reese melanosis must guide the diagnosis towards a melanoma.

Conjunctival melanoma

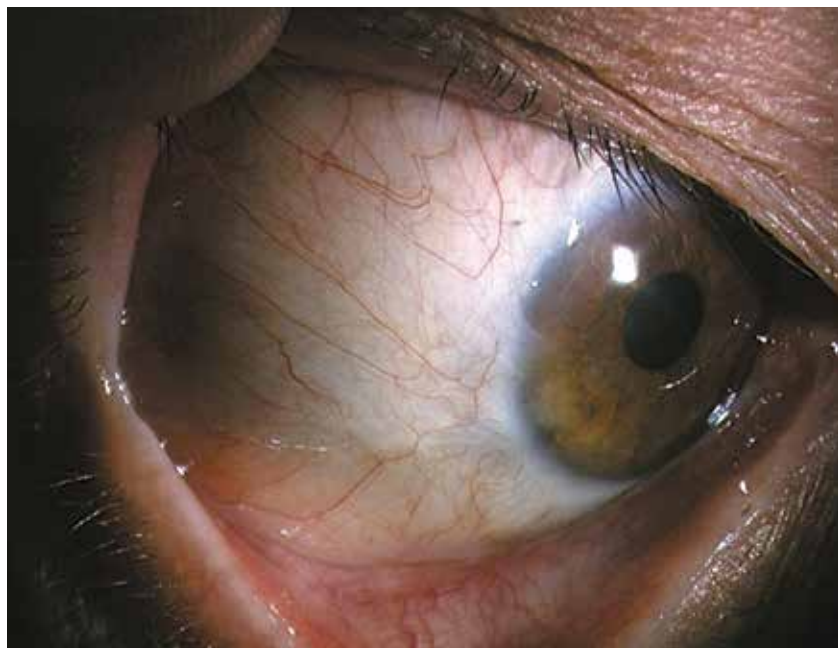

Woman aged 74 years presenting with an invasive conjunctival melanoma. The presence of planar pigmentation around the edge of the lesion indicates a pre-existing precancerous Reese melanosis.

Conjunctival melanoma

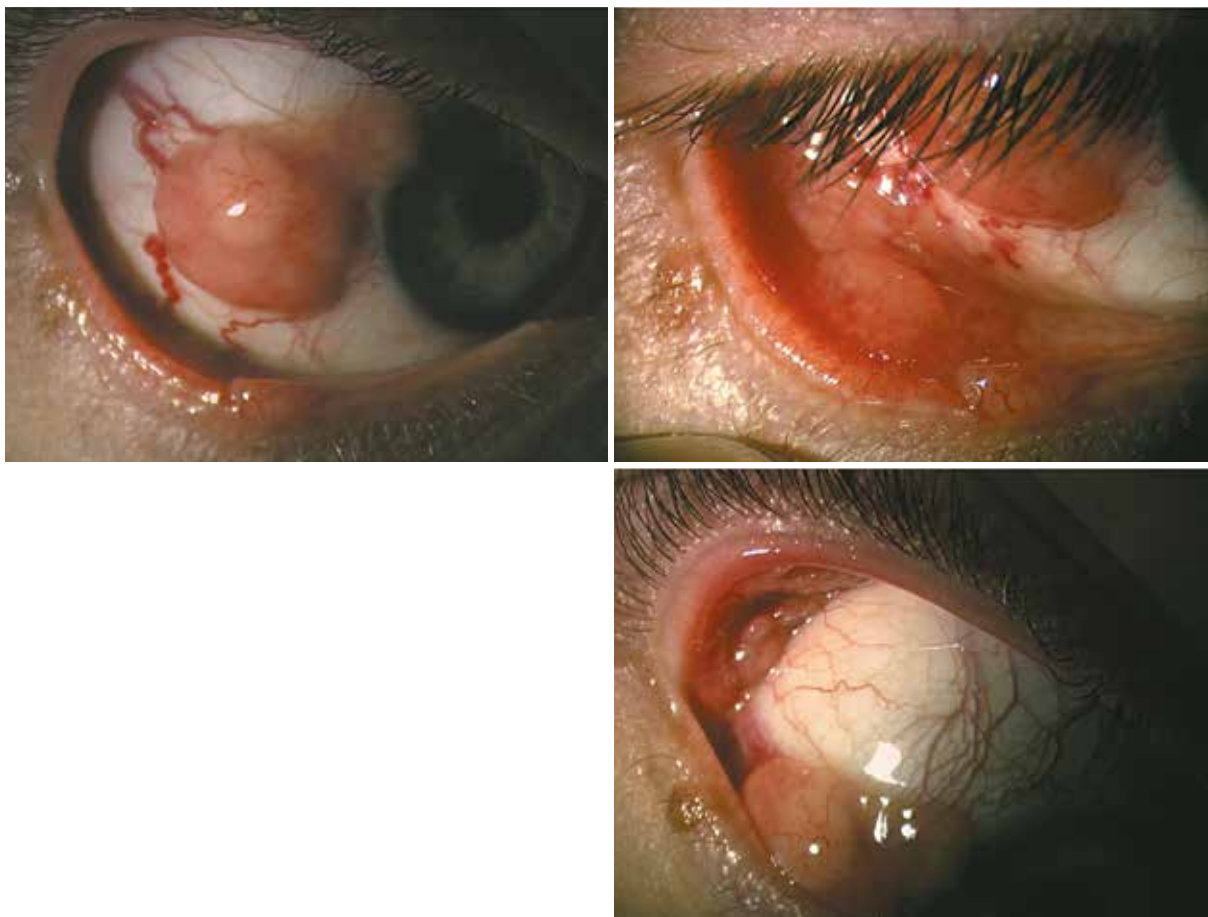


«*De novo*» invasive conjunctival melanoma in a 53-year-old man. Lesion appeared 18 months ago with growth observed recently. The slightly raised appearance with numerous feeder vessels and the recent development in a patient in their fifties must indicate the diagnosis.



Appearance of the scar 3 years after treatment by surgical excision and complementary proton beam therapy.

Conjunctival melanoma

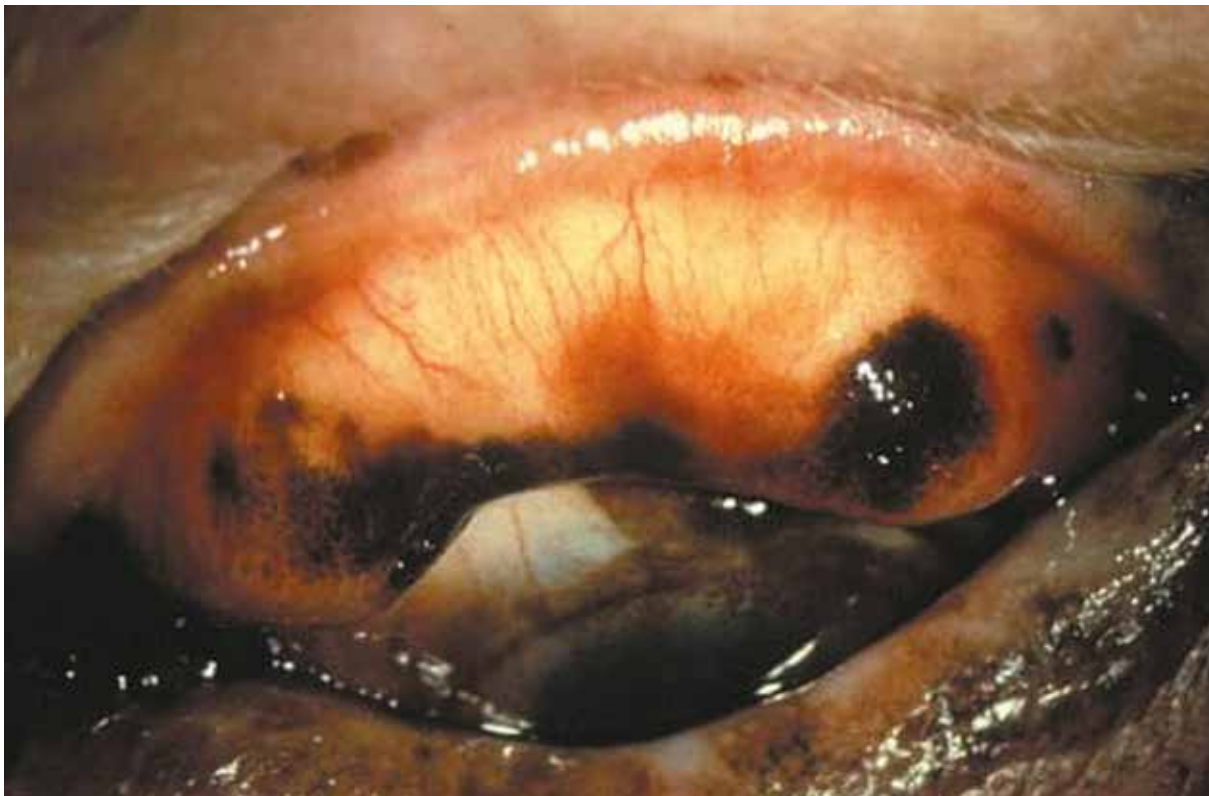

Rapidly progressive achromatic and plurifocal conjunctival melanoma in a young woman aged 23 years and 8 months pregnant.

Note the upper and lower palpebral tumoral locations associated with a melanoma of the bulbar conjunctiva.

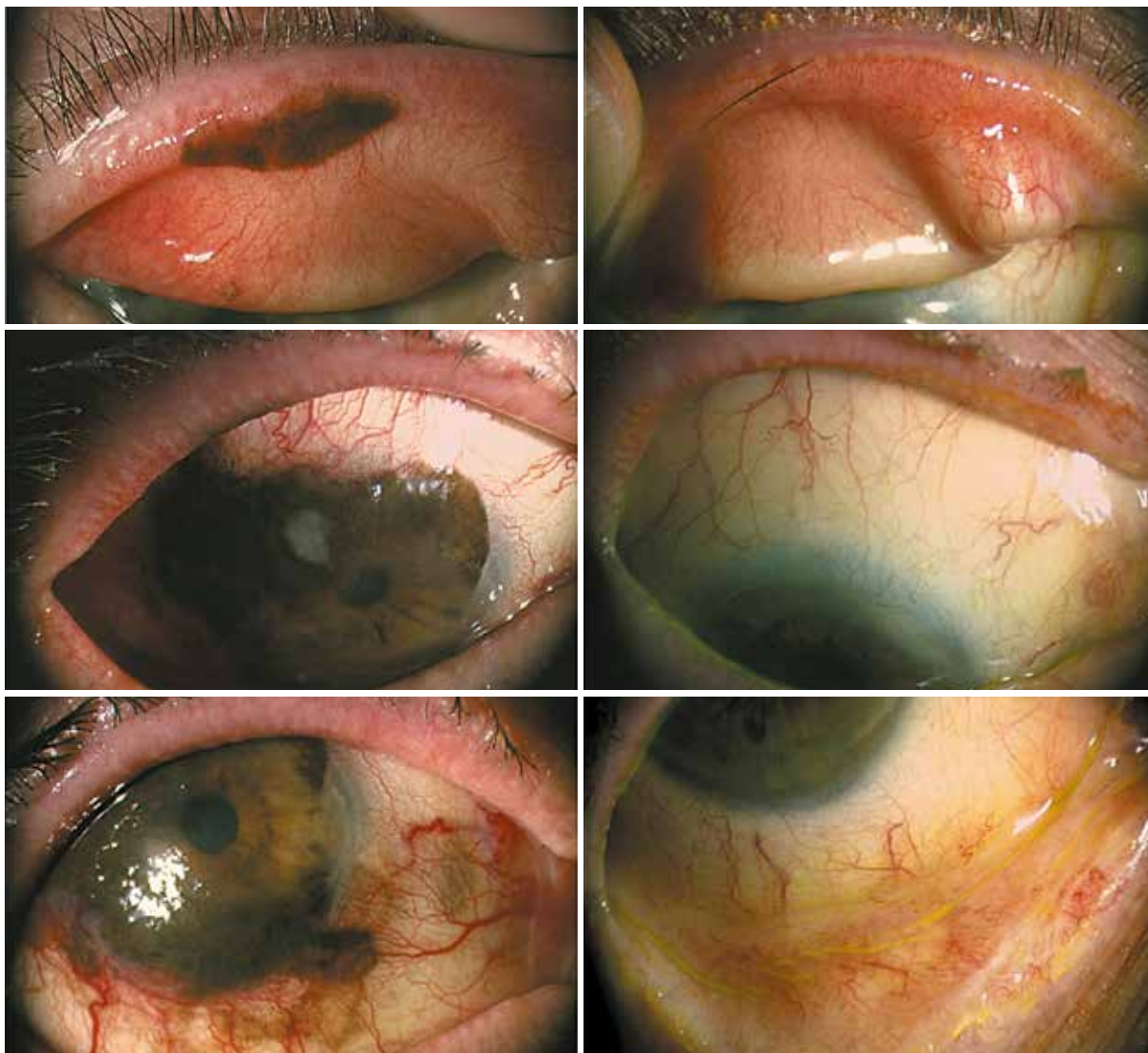The absence of keratinization on the surface or papillomatous appearance helps establish the differential diagnosis with an epidermoid carcinoma.

Conjunctival melanoma



Invasive melanoma of the upper palpebral conjunctiva that developed on an extensive precancerous Reese melanosis.

Conjunctival melanoma



Appearance of an invasive corneal melanoma before treatment on a Reese melanosis extending to the bulbar and upper palpebral conjunctiva.

Appearance of an invasive melanoma after treatment by surgical excision and complementary proton beam therapy, and treatment of the residual Reese melanosis with antineoplastic eye drops.

Conjunctival melanoma firstly requires total surgical excision under general anesthesia after precise iconography of the lesion (photos, diagrams, measurements).

In the case of an invasive melanoma confirmed by histological examination, given the high risk of local recurrence after surgery alone, complementary radiotherapy is strongly recommended and must be systematically discussed in multi-disciplinary oncology-ophthalmology consultation meetings.



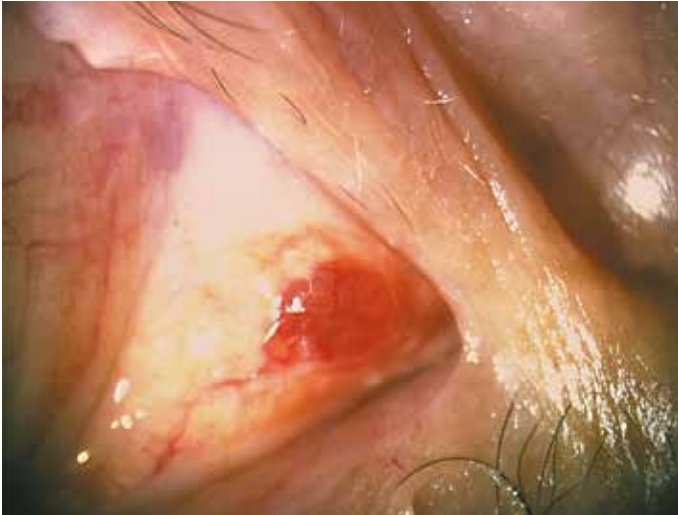

4. Glandular tumors

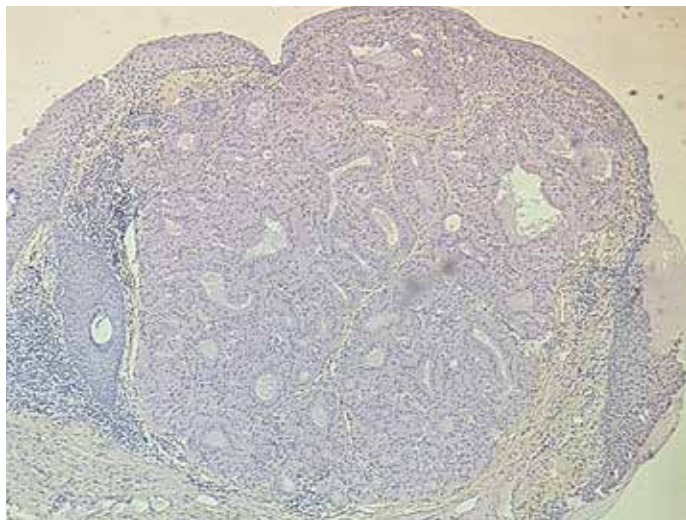
Glandular tumors

Glandular tumors, generally located in the caruncle, can develop from accessory lacrimal glands (oncocytoma) or sebaceous glands (sebaceous adenoma and sebaceous carcinoma)

Oncocytoma



Caruncular oncocytoma in an 83-year-old woman.



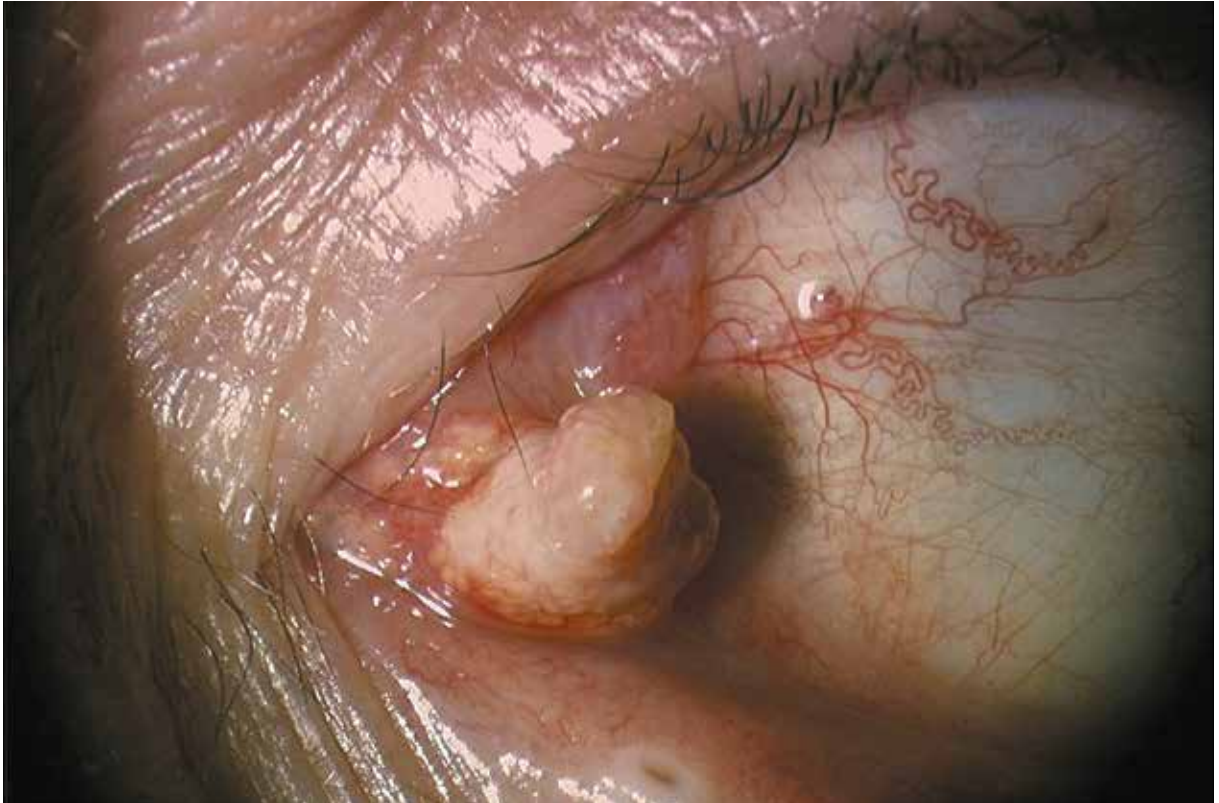
Histological section. Benign tumoral proliferation comprising glandular structures surrounded by a tall cylindrical epithelium comprising large eosinophilic cells with abundant cytoplasm.

Oncocytoma (or cystadenoma) is a benign proliferation of the epithelium of the accessory lacrimal and apocrine glands and is therefore an adenoma.

It typically occurs in the caruncle, often in elderly women, and presents as a brown to red vascularized, sometimes cystic nodule. The asymptomatic lesion grows slowly.

Histologically, it comprises a proliferation of epithelial cells, similar in appearance to those of an apocrine epithelium (Moll glands), surrounding a space as in a gland.

Sebaceous adenoma

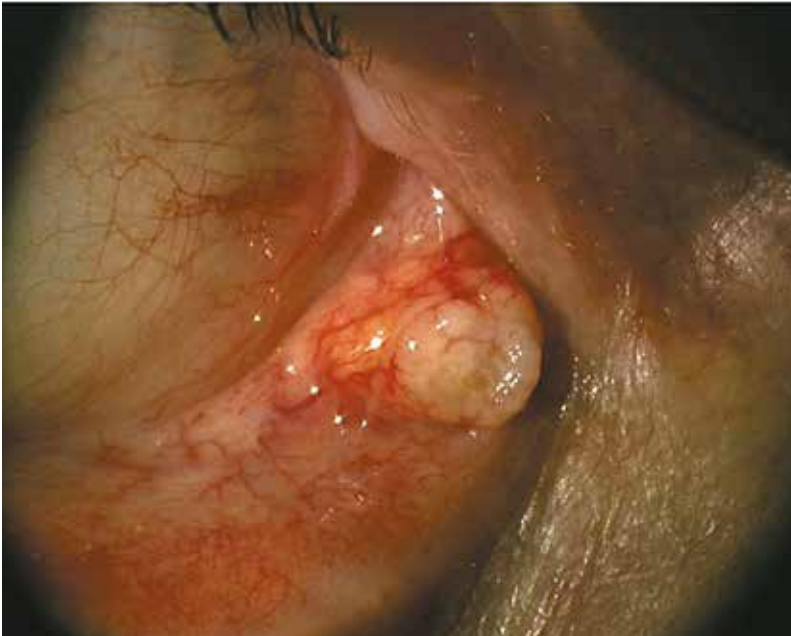


Sebaceous caruncular adenoma in a 61-year-old woman. Developing lobed lesion containing fat, soft on palpation.

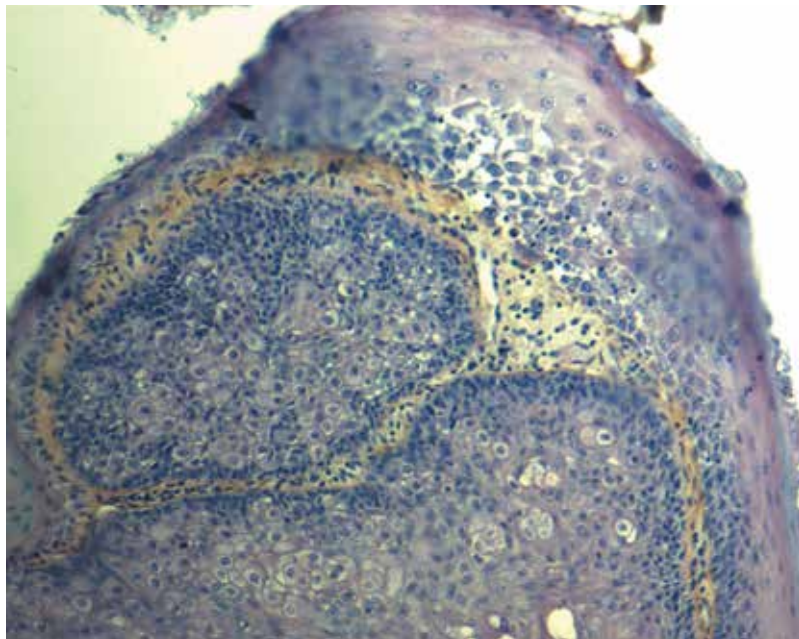
Sebaceous adenoma is a benign and rare glandular tumor. It occurs clinically as a flexible, sometimes multinodular, yellow swelling of the caruncle.

Histologically, the sebaceous adenoma comprises multiple irregular and incompletely differentiated sebaceous lobes. When a sebaceous adenoma is diagnosed, screening for the Muir-Torre syndrome is necessary.

Sebaceous adenoma

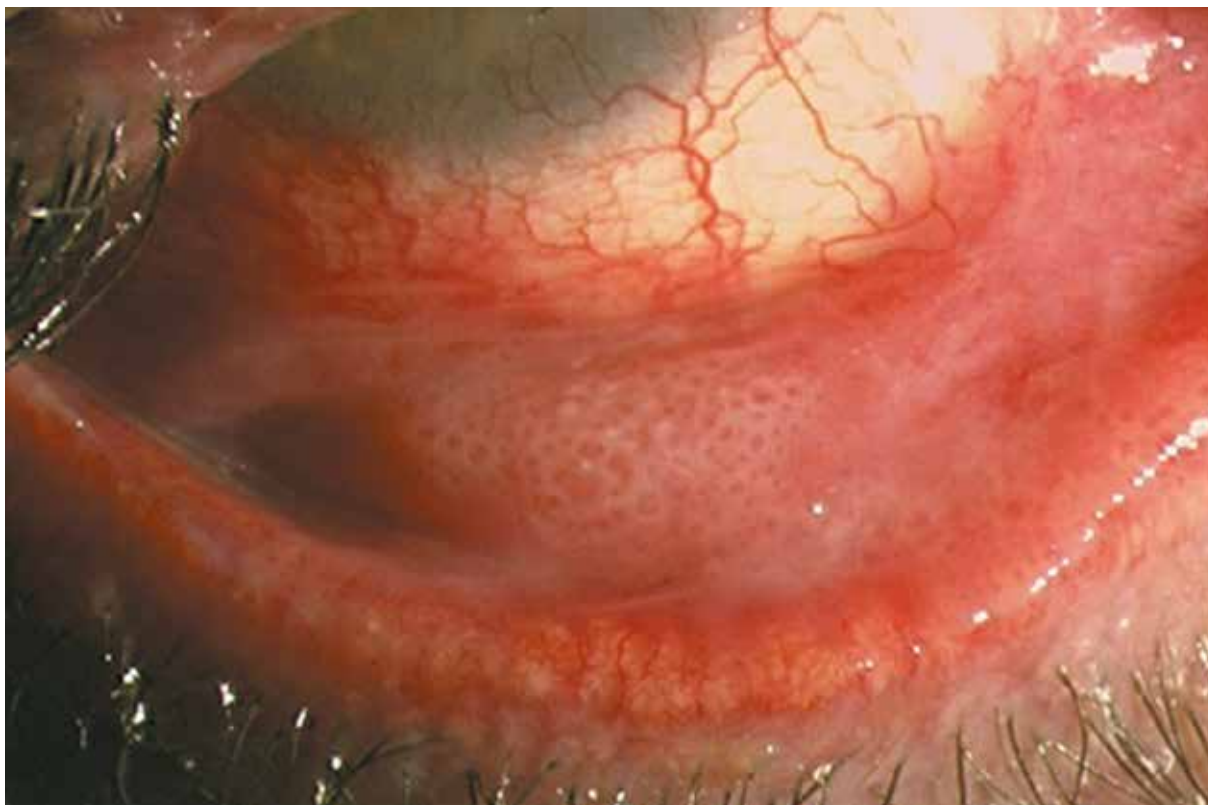

Sebaceous caruncular adenoma in a 67-year-old man. Developing lesion observed 2 months ago.



Histological section of a sebaceous adenoma: clearly defined due to large sebaceous lobes with peripheral basophilic cells. The sebocytes are regular, mature. Absence of cytonuclear atypia. Absence of mitosis.

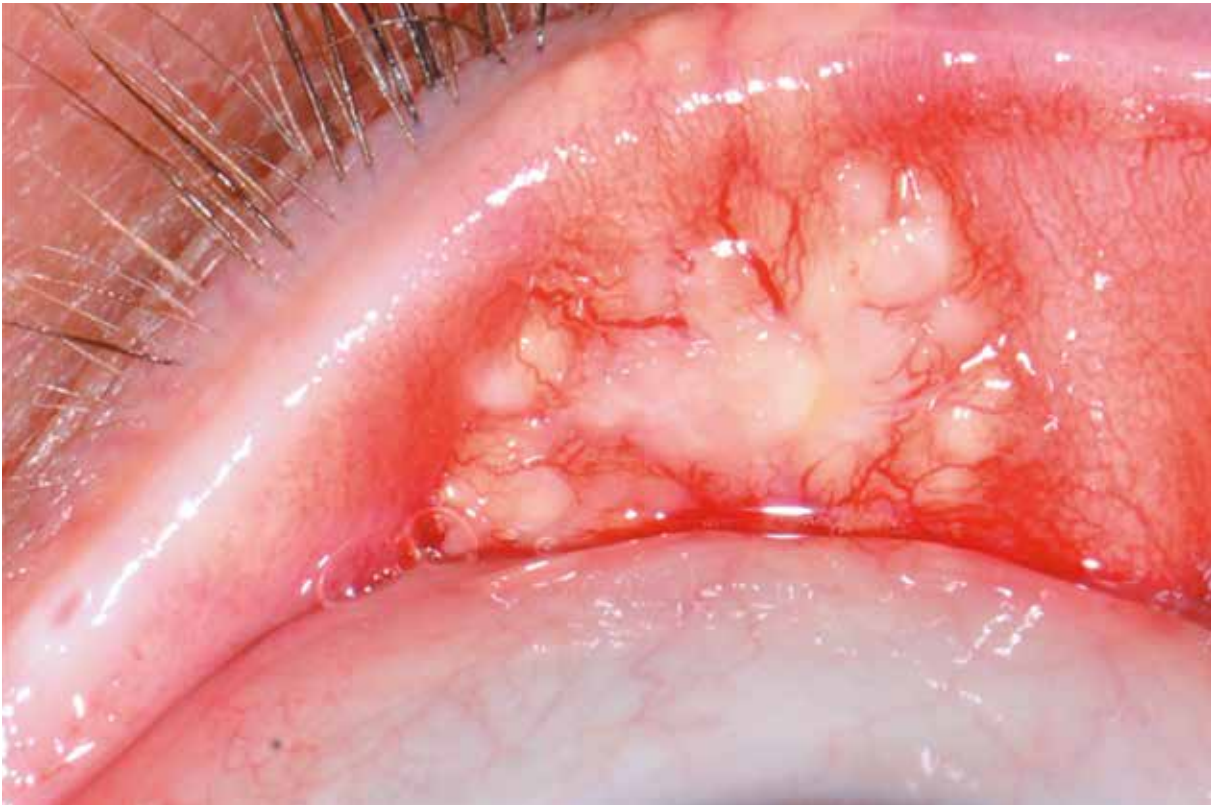Sebaceous carcinoma



Sebaceous carcinoma is a malignant tumor that develops in the sebaceous glands with high lymph and visceral metastatic potential.

It generally occurs in elderly subjects in the form of a palpebral or caruncular nodule, but can also develop in the conjunctival epithelium in the form of a layered pagetoid infiltrate, sometimes multicentric. This specific form of sebaceous carcinoma involving the conjunctival pagetoid presents as a diffuse, inflammatory, slightly papillomatous lesion and is particularly insidious. The initial clinical appearance often causes problems of differential diagnosis with chronic blepharoconjunctivitis.

Sebaceous carcinoma



Upper palpebral conjunctiva sebaceous carcinoma.

Histologically, clearly differentiated sebaceous carcinomas can be identified by the foamy, micro-vesicular appearance of the cytoplasm of the tumoral cells.

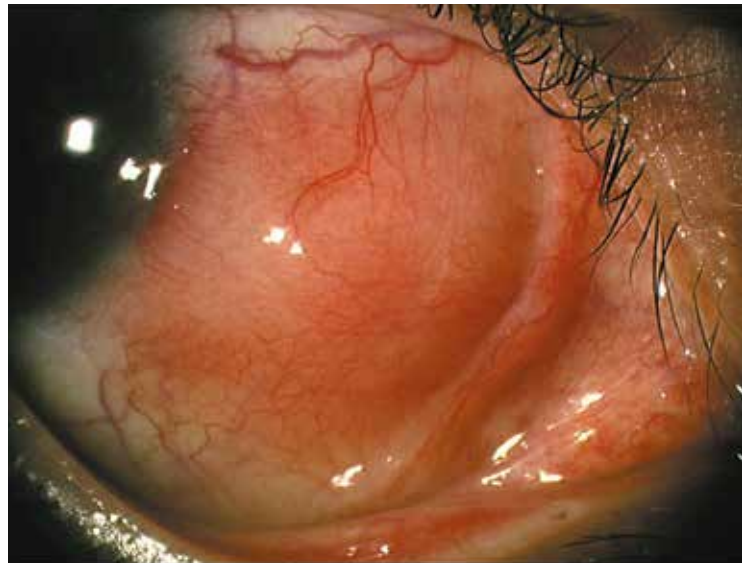
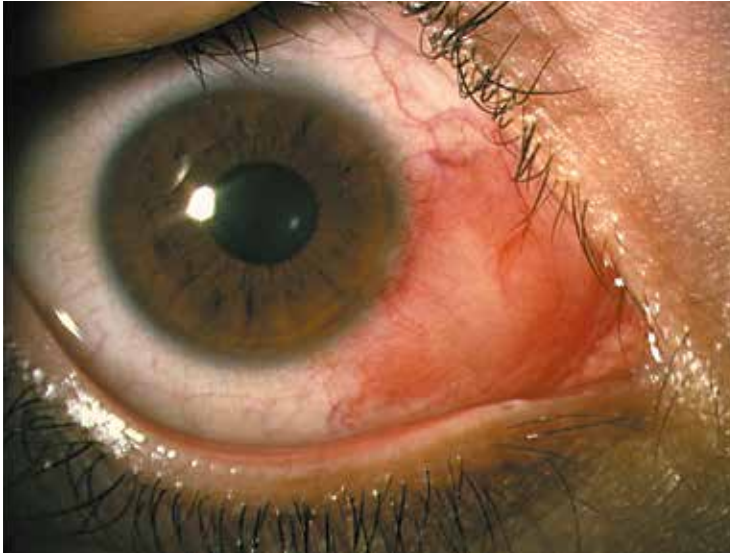
The diagnosis of poorly differentiated tumors is more difficult and can be confused with other more common malignant epithelial tumors (epidermoid carcinoma).

The vital prognosis of sebaceous carcinomas is not as good as that of epidermoid carcinomas, with a 5-year death rate of nearly 25%.



5. Lymphoproliferative tumors

Benign reactive lymphoid hyperplasia

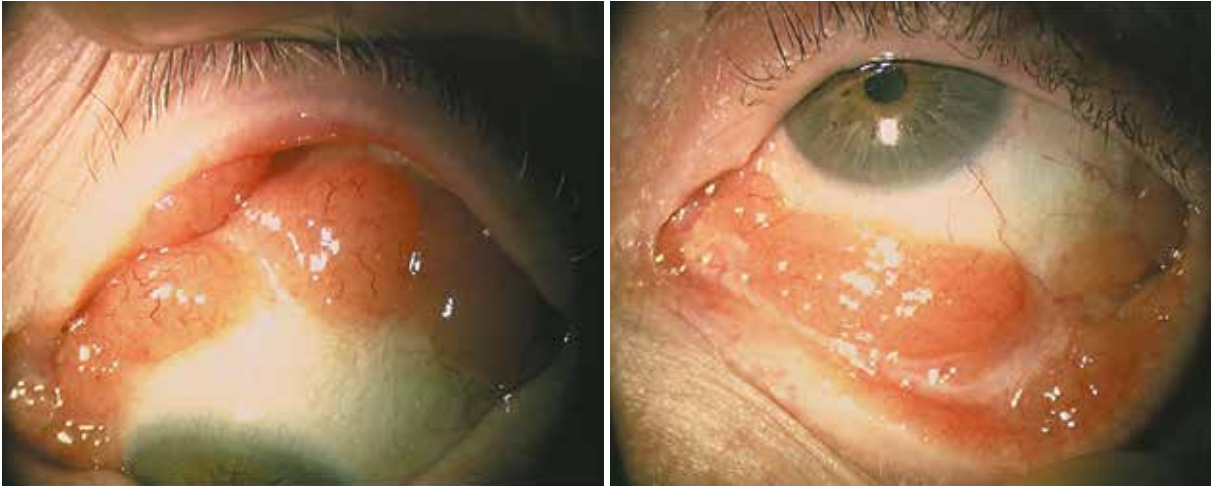


Young woman aged 30 presenting with benign reactive lymphoid hyperplasia. The painless bulbar conjunctival lesion appeared 5 months ago and has doubled in size.

Benign reactive lymphoid hyperplasia corresponds to benign polyclonal lymphocytic proliferation, with no cell atypia and comprising a balanced proportion of T and B lymphocytes.

It is impossible to distinguish clinically the conjunctival lesions from a lymphoma. Subjects affected are generally younger, but only a biopsy with immunohistochemical analysis will enable a diagnosis to be established.

Conjunctival lymphoma



Woman aged 72 presenting a left conjunctival MALT lymphoma.

The large salmon-colored conjunctival follicles merge in raised tumoral masses, firm on palpation, in the upper and lower bursa.

The conjunctival epithelium on the surface is intact, smooth and regular, not keratinized.

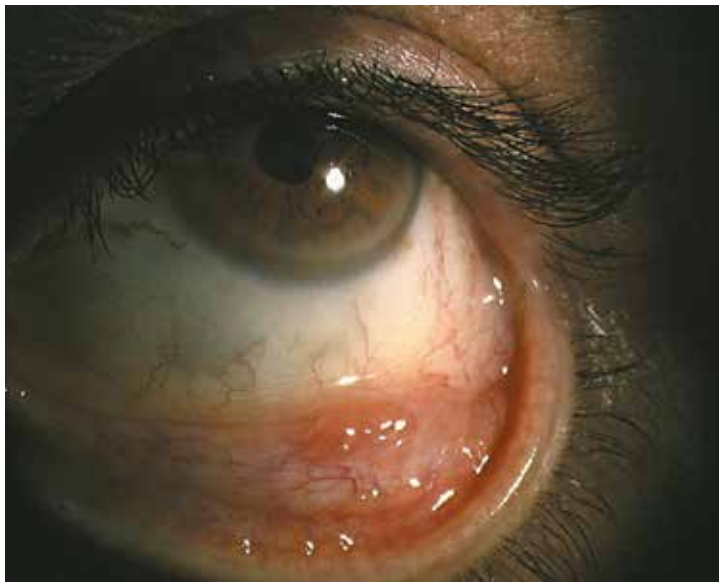A lymphoma is a malignant tumor corresponding to the clonal proliferation of lymphocytes (B lymphocytes, and rarely T or NK cells) or their precursors.

The conjunctival localization generally corresponds to primary involvement. In most cases, it is a B-cell non-Hodgkin lymphoma of which 2/3 are low-grade MALT lymphomas. A conjunctival lymphoma thus often develops slowly and insidiously in an asymptomatic patient aged around sixty.

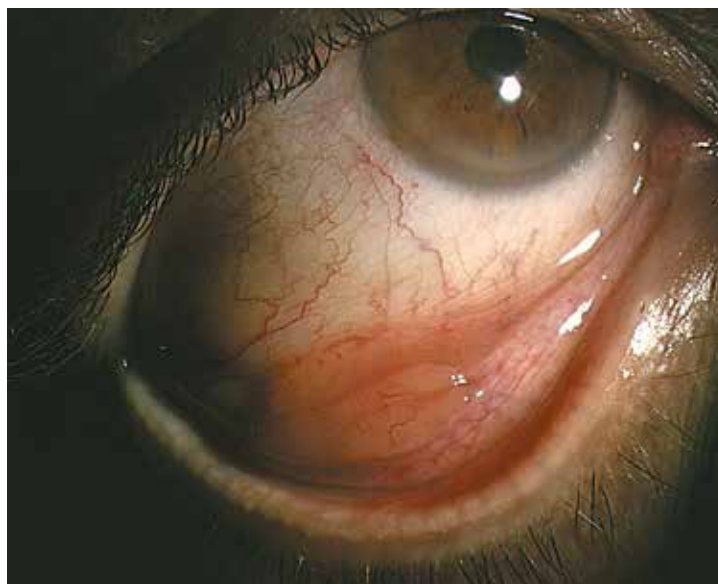
A conjunctival tumor starts in the conjunctival bursa or the bulbar conjunctiva as large pink more or less confluent conjunctival follicles. At a more advanced stage, lymphomatous infiltration can look like hard, salmon-colored bulges surrounding the eyeball. Unilateral or bilateral involvement (10% to 40% of cases).

For a third of patients, an extra-ophthalmological site is involved (lymph, medullary involvement) and the hematologist must prescribe a general assessment. A biopsy with histological analysis is essential for the diagnosis and enables the type of lymphoma to be characterized. Radiotherapy has for a long time been the standard treatment, but due to adverse effects, new therapies are now often proposed: monoclonal antibodies, antibiotic therapy, and even therapeutic abstinence with surveillance.

Conjunctival lymphoma




Left eye.



Right eye.

Patient aged 53 years consulting due to chronic tearing for the past 3 years. The examination shows large salmon-colored conjunctival follicles on the palpebral conjunctiva, near the lower bursa. The orbital MRI did not reveal any associated orbital involvement. The PET scan highlighted a minor, non-specific, relatively symmetrical hypermetabolism in front of the eyeball of very moderate intensity (SUV max 2.9). General assessment (osteo-medullary biopsy, gastric fibroscopy, thoracic-abdominal-pelvic scan) did not highlight any other lymphomatous localization.

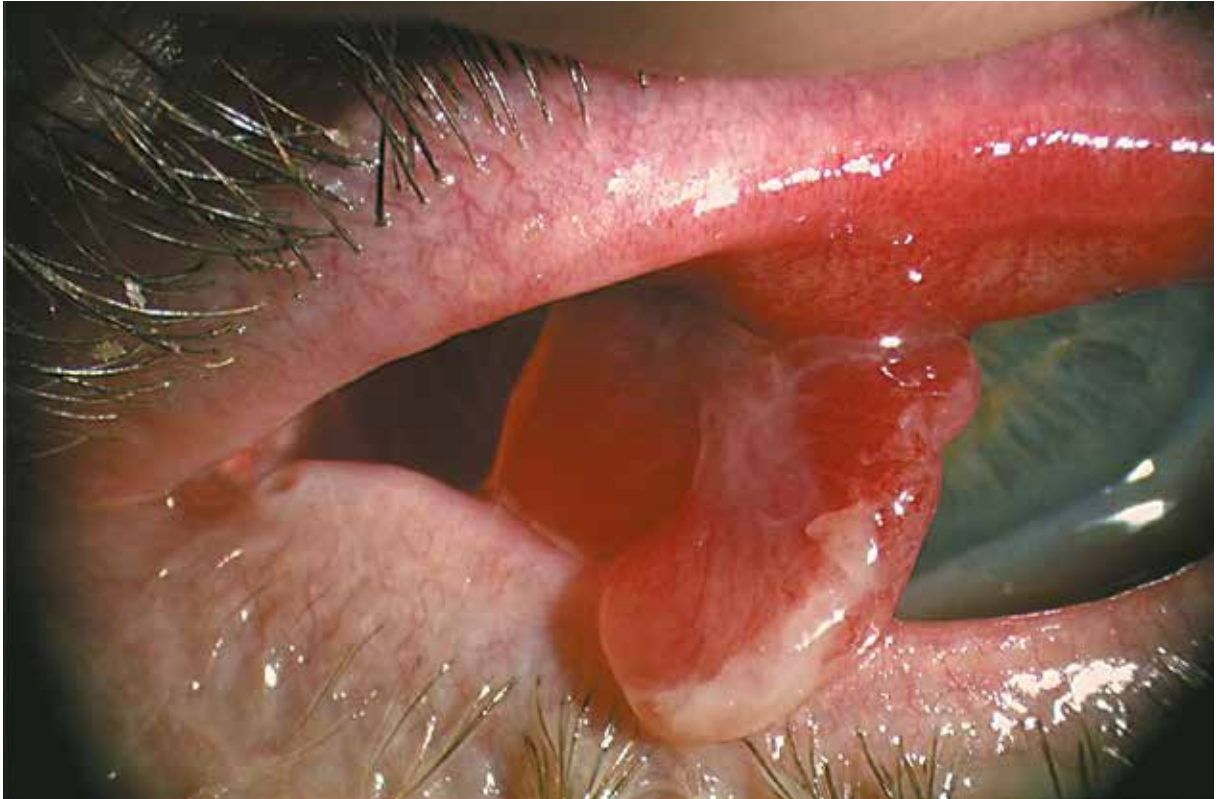
The analysis of the biopsy samples determined a grade I follicular B lymphoma with bilateral involvement. Given the negativity of the assessment and the small tumor size, at a multi-disciplinary consultation meeting the decision was made to monitor the tumor. The involvement has remained stable for the previous 9 years.





6. Vascular tumors

Pyogenic granuloma

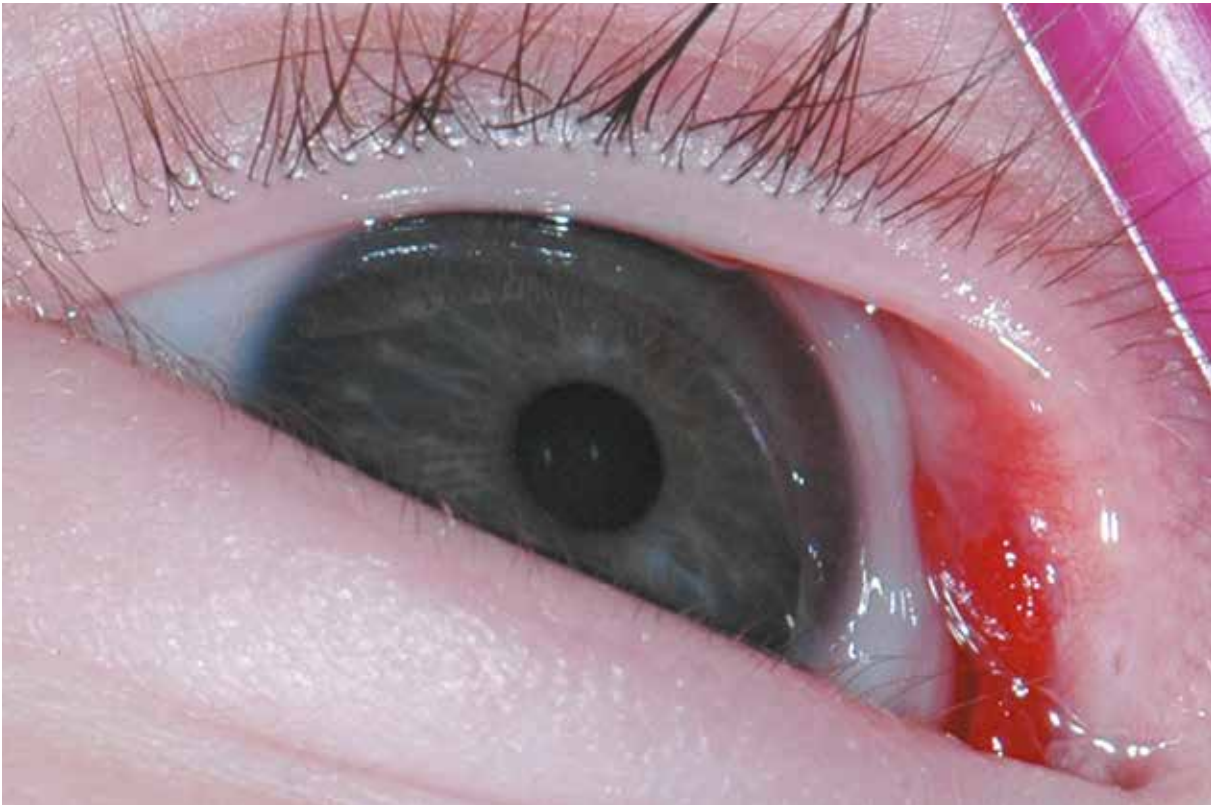


Pyogenic granuloma (or lobular capillary hemangioma) is a benign inflammatory fibrovascular proliferation that often occurs in young subjects in response to an aggression (chalazion, history of surgery or trauma).

It is a painless, bright red, smooth conjunctival swelling that bleeds easily and is often pedunculated.

This benign vascular tumor can regress. Topical anti-inflammatory treatment can be tried initially. If regression is incomplete, it will be surgically excised.

Conjunctival capillary hemangioma

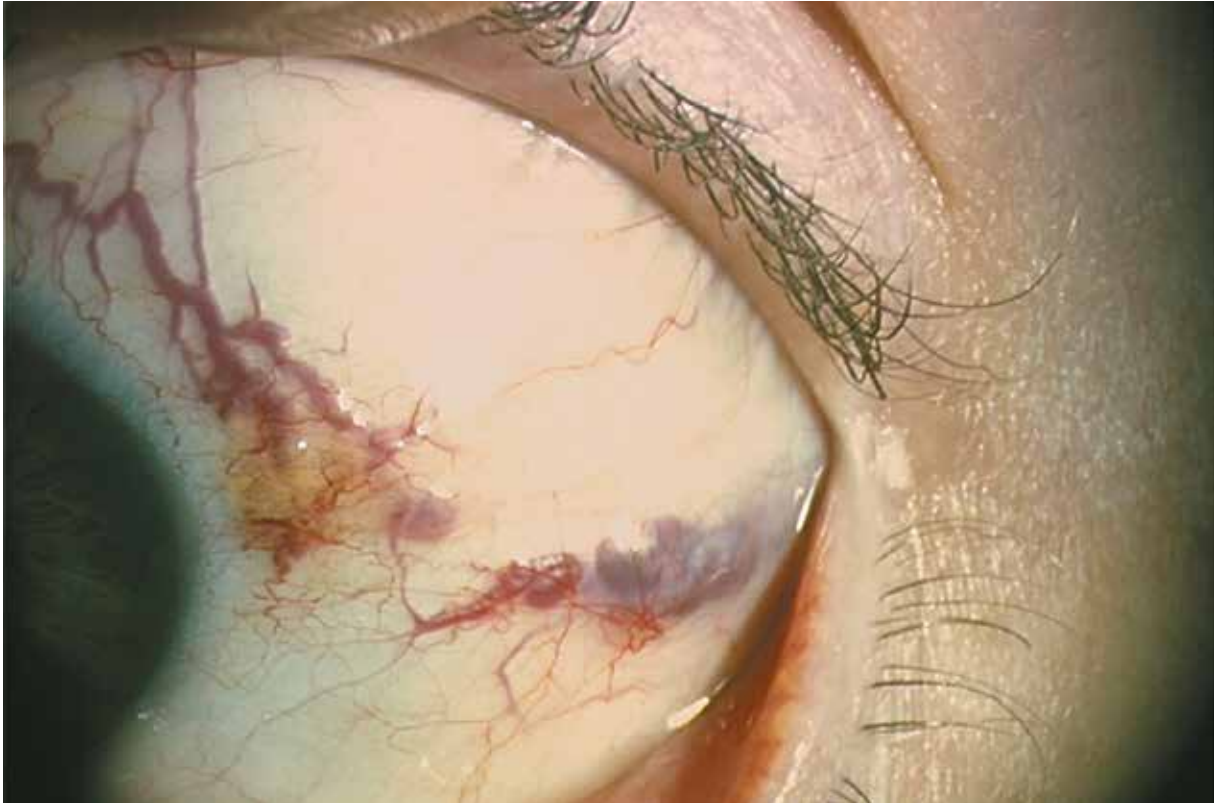


A capillary hemangioma is a hamartoma, or benign congenital tumor, corresponding to the abnormal proliferation of mature tissue normally present in the organ affected.

It develops rapidly after birth, grows progressively for 2 years then slowly regresses, just like palpebral or orbital capillary hemangiomas with which it is sometimes associated. Histologically, it is characterized by the proliferation of lobular endothelial cells separated by a thin fibrous septum. The involuted lesions are less vascular and more fibrous.

The examination shows a more or less extensive small red mass.
Most are small and asymptomatic and only require monitoring.

Conjunctival lymphangiectasia



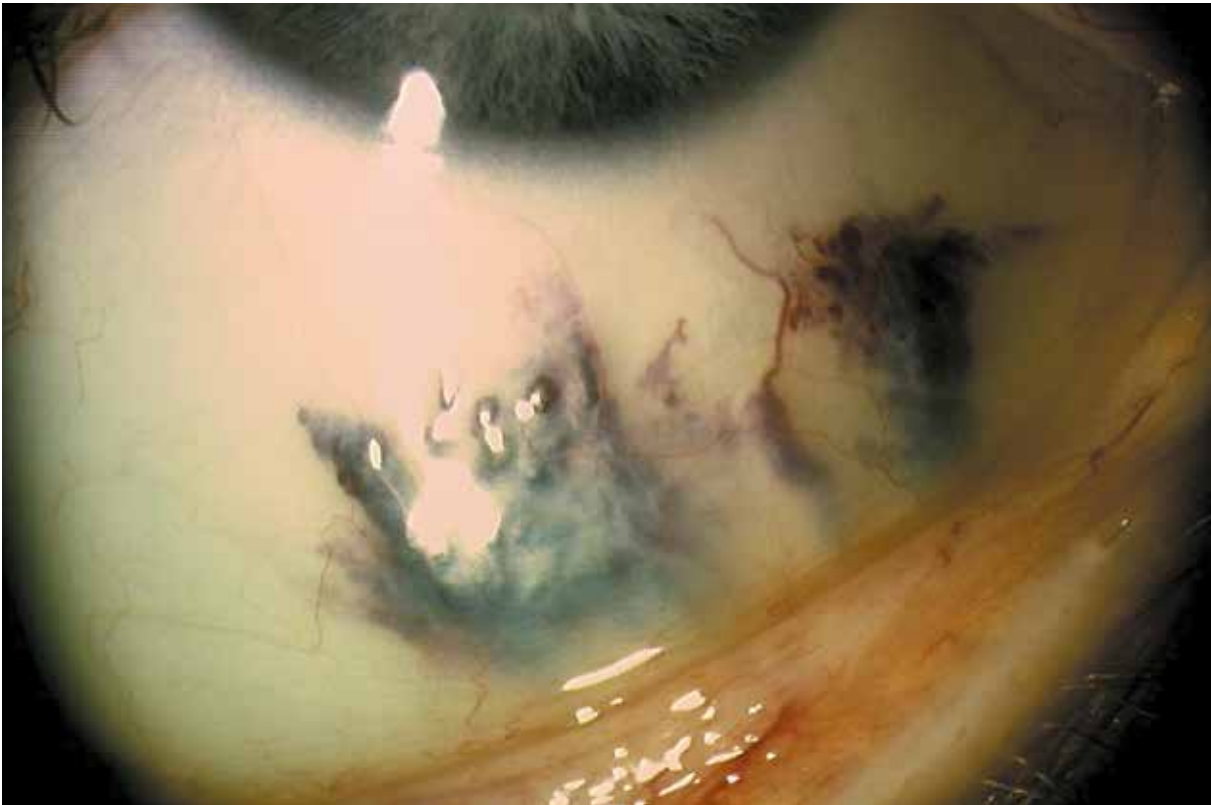
A 32-year-old man presenting with vascular angiomatous dilations under the bulbar conjunctiva of the left eye. The patient has been aware of it since his first consultations with the ophthalmologist around the age of 7.

Conjunctival lymphangiectasias can be isolated or correspond to the visible superficial part of an orbital lymphangioma.

These rare conjunctival tumors develop clinically during the first decade as a unilateral polylobed mass comprising dilated cystic vessels of varying size. In most cases, the cysts contain purplish-brown blood.

Small, localized lesions can sometimes be surgically resected. The excision of more extensive lesions is often more difficult and complicated with significant bleeding.

Conjunctival lymphangiectasia

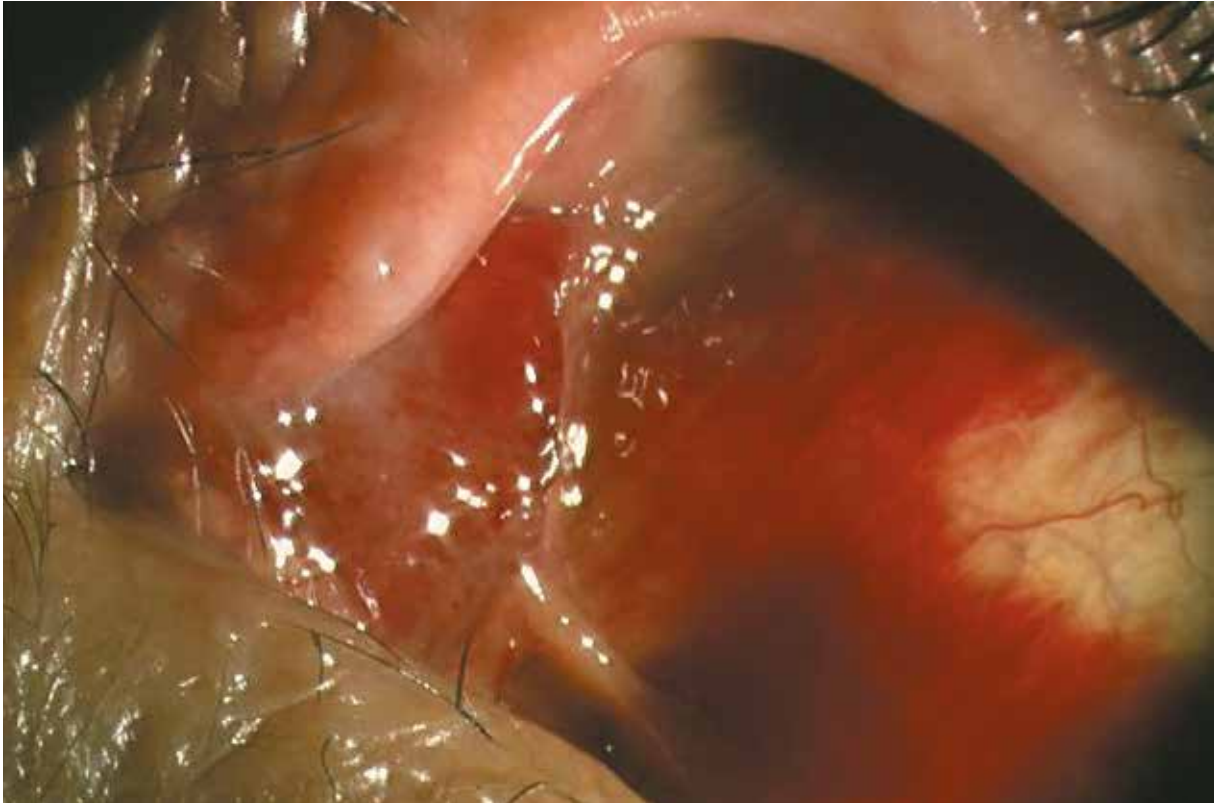


Conjunctival lymphangiectasia in a young 14-year-old girl.

The conjunctival lesions developed at the age of 7 or 8 with episodes of subconjunctival bleeding with increases in the size of the lymphangiectasias.

An orbital MRI confirmed the absence of associated orbital lymphangioma.

Kaposi's sarcoma



Left conjunctival Kaposi's sarcoma in a 75-year-old woman with no specific history (HIV negative). The lesion close to the caruncle developed approximately 2 months ago and manifests with recurrent bleeding of the nasal bulbar conjunctiva.

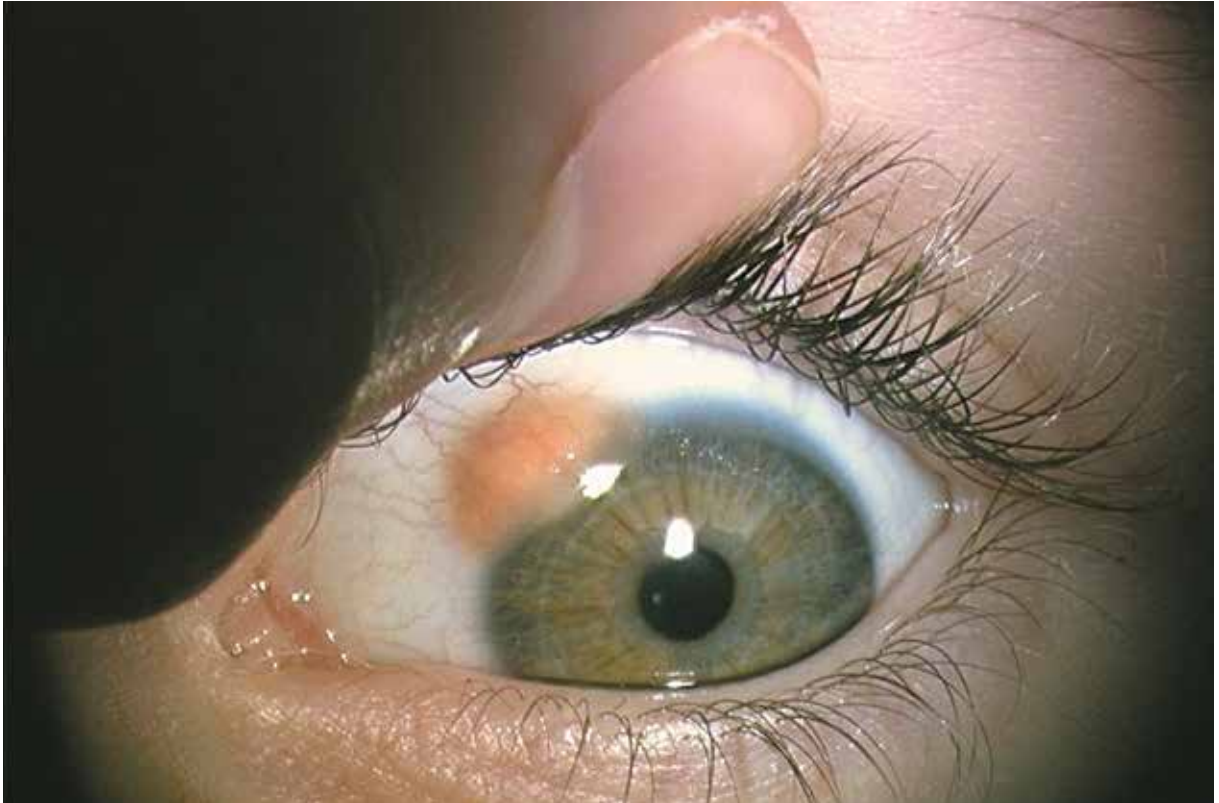
Kaposi's sarcoma can be a sign of an HIV viral infection, but with the effective HIV treatments now available, its incidence has drastically decreased.

Initially, it presents as painless, unilateral hemorrhagic conjunctivitis, and then a flat, bright red conjunctival lesion develops which grows in size to become a solid purplish nodule.





Juvenile Xanthogranuloma

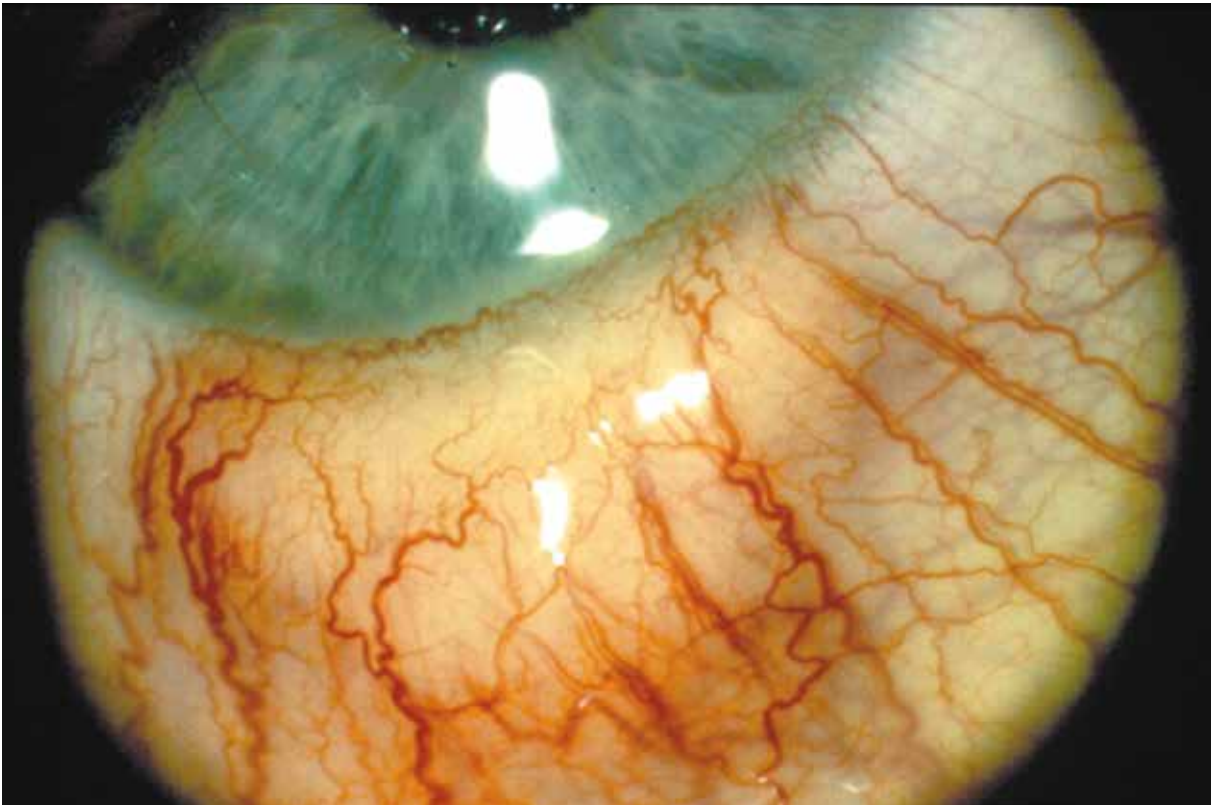


Xanthogranuloma in a little 2-year-old girl.
Slightly raised, limbic lesion appeared suddenly 3 months ago, non-progressive.

A juvenile xanthogranuloma is a rare idiopathic disease linked to the benign proliferation of non-Langerhans histiocytes.

Lesions of the iris are the most common and often complicated with hyphema or glaucoma. Conjunctival involvement is rare and presents as a raised yellow mass, often close to the limbus. It is generally isolated with no associated cutaneous rash.

Fibrous histiocyoma



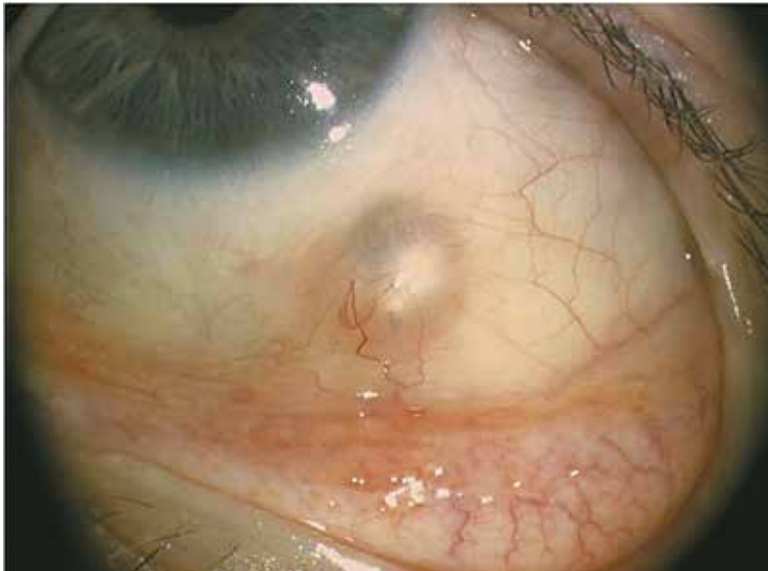Benign fibrous histiocyoma in an 8-year-old girl.
The pink-brown lesion is covered by an intact conjunctival epithelium and adheres to the sclera.

The fibrous histiocyoma comprises fibroblasts and histiocytes. It can be benign, locally aggressive or malignant. If malignant, metastatic spreading remains rare.

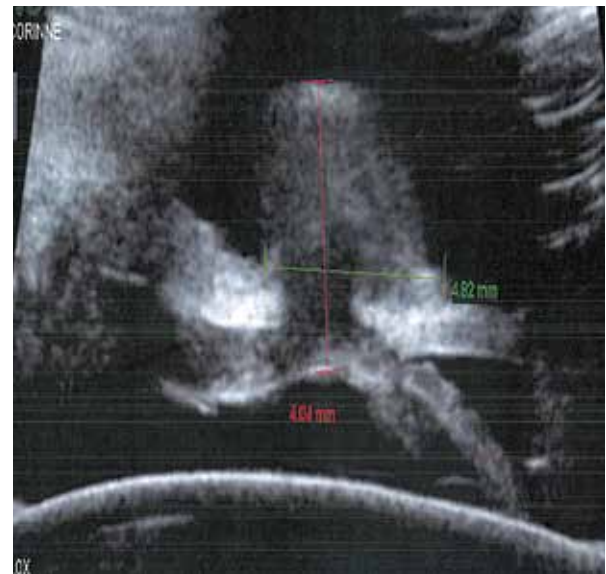Clinically it looks like a red to brown firm stromal tumor and is often located in the limbus with extension to the cornea. Due to its unusual appearance, it is difficult to differentiate from other non-pigmented stromal tumors.

Total surgical excision of the lesion is recommended.

Schwannoma




Schwannoma in a 47-year-old woman. Lesion observed 3 years ago, progressing little. Patient describing ciliary-type pain.



Examination revealed a hard, achromatic, subconjunctival nodule adhering to the sclera. High frequency ultrasound identified a tumor with scleral extension.

Schwannoma (or neurinoma) is a benign tumor comprising only Schwann cells that develop in the peripheral nerve sheaths.

A conjunctival schwannoma is rare. In this case, it presents as a slightly yellow or pink mass located in the conjunctival stroma or the episclera, sometimes with a few conjunctival or episcleral feeder vessels. Very slow growth can be observed.





Edition

Edité par :
Laboratoires Théa
12 Rue Louis Blériot - ZI du Brézet
63017 Clermont-Ferrand cedex 2 - France
Tél. 04 73 98 14 36

