

CHRONIC CORNEAL ULCERS

Pr Marc Muraine

Dr Julie Gueudry

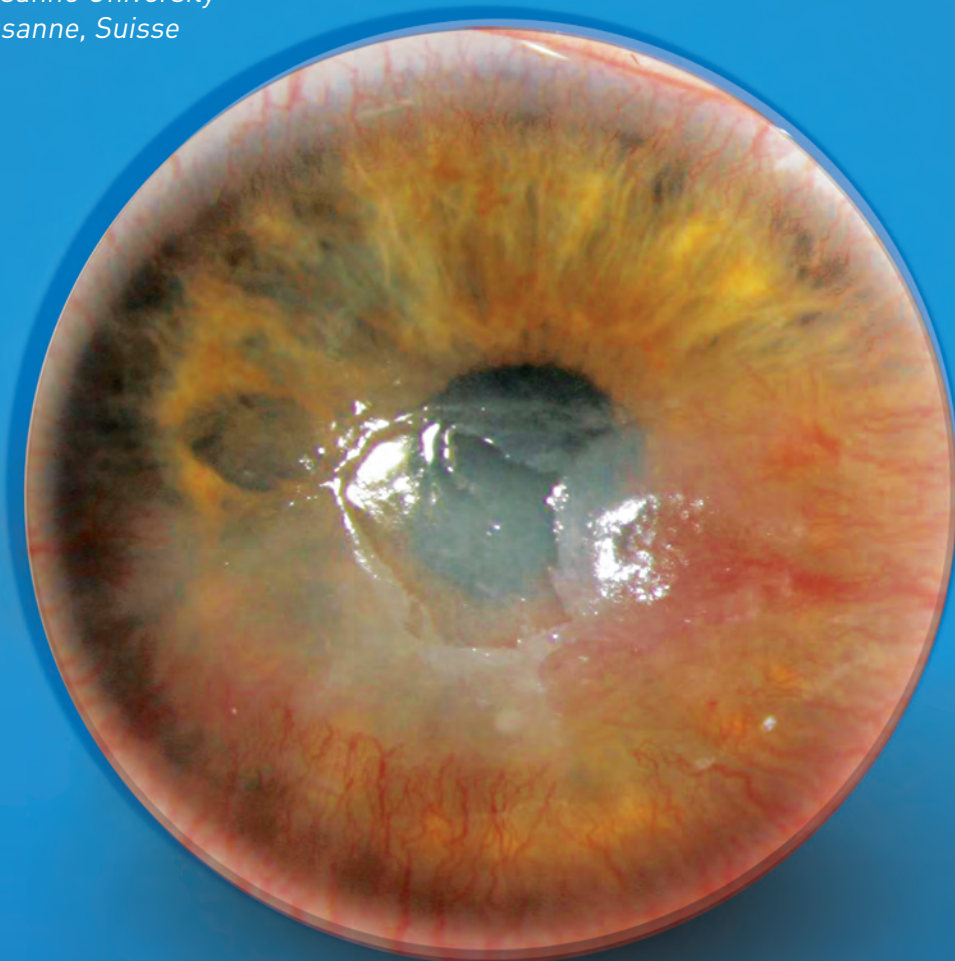
*Ophthalmology department
University Hospital Charles Nicolle
Rouen, France*

Pr Bernard Duchesne

*Ophthalmology department
University Hospital
Liège, Belgique*

Dr François Majo

*MD, PhD, Privat Docent
Ophthalmic Hospital Jules-Gonin
Lausanne University
Lausanne, Suisse*





Edition

Edited by:
Laboratoires Théa
12, rue Louis Blériot
63000 Clermont-Ferrand
Tel: +33 4 73 981 436

Work spread with the cooperation of the Laboratory Moria
Laboratoires Moria SA
15 rue Georges Besse
92160 Anthony

The content of this book presents the viewpoint of the authors and does not necessarily reflect the opinions of Laboratoires Théa.

Design - Production: Elwood

All rights of translation, adaptation and reproduction by any means are reserved for all countries.

Any reproduction, in whole or part, by any means whatsoever, of the pages published in this book, is prohibited and unlawful and constitutes forgery without the prior written consent of the publisher. The only reproductions allowed are, on the one hand, those strictly reserved for private use and not intended for collective use and, on the other hand, short analyses and quotations justified by the scientific or informational nature of the work into which they are incorporated (Law of 11 March 1957, art. 40 and 41, and Penal Code art. 425).



Preface

This book on chronic corneal ulcers is a generously and beautifully illustrated account of common and serious corneal ulcers written by experts in the field. The authors have adopted a practical approach to a complex clinical problem providing the reader with diagnostic and therapeutic algorithms to work their way towards arriving at a sound clinical diagnosis when confronted with mild or sight threatening ulcers of the cornea. The multitude of illustrations covering a range of clinical presentations of the conditions discussed serve to re-inforce the succinct points made in the associated text. The emphasis is on the details of the clinical signs and presentations of different types of corneal ulcers but appropriate reference to suitable tests and investigations has been made where necessary. It will be a useful read for trainees learning the art and science of their specialty and equally for the generalist and specialist ophthalmologists dealing with corneal ulcers.

The authors for compiling this useful material under one cover and Thea Pharmaceuticals for supporting this educational endeavour are both worthy of congratulations and commendation.

Harminder S Dua



Foreword

Dear reader,

First of all I would like to thank Laboratoires Thea for suggesting this book dedicated to chronic ulcers of the cornea. As we know, corneal ulcers usually heal within a few days and chronic ulceration, where the ulcer has not closed after 3 weeks, is therefore relatively rare. Etiological diagnosis is however not easy in this unusual situation, and I therefore propose a diagnostic approach based on a rich pictorial atlas of the conditions that we see in our clinics.

Following a pathophysiological reminder of the corneal healing process, I provide a diagnostic algorithm that we then return to regularly as we work through the book. It guides you step by step through the various possible causes of chronic ulcers. First of all you need to rule out an infectious cause, especially viral or acanthamoeba keratitis, and don't forget to assess corneal sensitivity as neurotrophic ulcers of any origin are the most frequent chronic ulcers. If corneal sensitivity is unaltered, it is the location of ulcer that will provide the next key guide. When it is peripheral, the diagnostic algorithm will prompt you to find for example autoimmune marginal ulcer or catarrhal ulcer disease. When the ulcer is central or paracentral you should think of atopic keratoconjunctivitis, rosacea or rheumatoid arthritis, but the causes are numerous as we remind you later in the book. The recommended therapeutic approach is also not forgotten, but we have simplified it by providing the treatment of neurotrophic ulcers following their clinical description, with the treatment of other ulcers being addressed at the end of the book.

I would like to thank my collaborator, Dr. Julie Gueudry, for her valuable assistance and her attention to detail on the general direction of the book, as well as her help in choosing and sorting many of the images. I would also like to thank equally my friends Bernard Duchesne from Liège and François Majo from Lausanne for accepting my invitation to join me in this project. This book benefited from both their scientific and iconographic views, and also their benevolent critical eye.

I hope that this atlas will help you if the ulcer you are following refuses to heal and I would ask you to photograph your clinical situations because the slit lamp is, and will remain in my opinion, the most wonderful instrument for analysis of the anterior segment.

Marc Muraine



Thanks

Many thanks to Pr Harminder DUA for his involment and his careful reading and valuable inputs.

Many thanks to Dr. Agnès Delcampe for her valuable support in the complex pathologies of the ocular surface.

Many thanks also to Dr. Alain Retout for his indispensable expertise in the palpebral static disorders.

Many thanks to Véronique Replinger.

Special thanks too to the residents, fellows and orthoptists of the Rouen University Hospital, who have contributed to this book.

Fellows:

Alice DUNCOMBE,
Alexandre PORTMANN,
Perrine ROSSI

Residents:

Abdelouahab AIFA,
Guillaume BOUTILLIER,
Élodie CALAS,
Hela Yahia CHERIF,
Hélène LEBEL-BOIDIN,
Étienne LETESSON,
Alexandra LUCE,
Édouard MALANDAIN,
Élodie MARINGE,
Chloé NGO,
Admir MIRI,
William SIDE,
Laura VERMUSO,
Thibaut VILLANI

Orthoptists :

Émilie BAUDU,
Sophie CHAZALON,
Corentin FRETE,
Sophie MAZET

We also thank the photography team of the Jules Gonin Hospital and Marc Curchod as well as Mireille Clavien and Professor Daniel Thalmann of the École Polytechnique Fédérale de Lausanne.

TABLE OF CONTENT

Preface

Foreword

Thanks

PART 1: CORNEAL EPITHELIAL RENEWAL AND HEALING 15

The cornea and its epithelium 16

Corneal epithelial renewal 20

Pathological renewal of the corneal epithelium 24

Usual healing of corneal ulceration 26

Chronic corneal ulceration: definition 28

Complications of ulcers 32

PART 2: DIAGNOSTIC AND THERAPEUTIC APPROACH 37

Diagnostic approach introduction 38

Rule out an infection! 40

Diagnostic approach 44

Testing corneal sensitivity and suspecting
neurotrophic keratitis 46

Neurotrophic keratitis 48

Neurotrophic keratitis classification 48

Neurotrophic keratitis aetiologies 52

Neurotrophic keratitis treatment 62

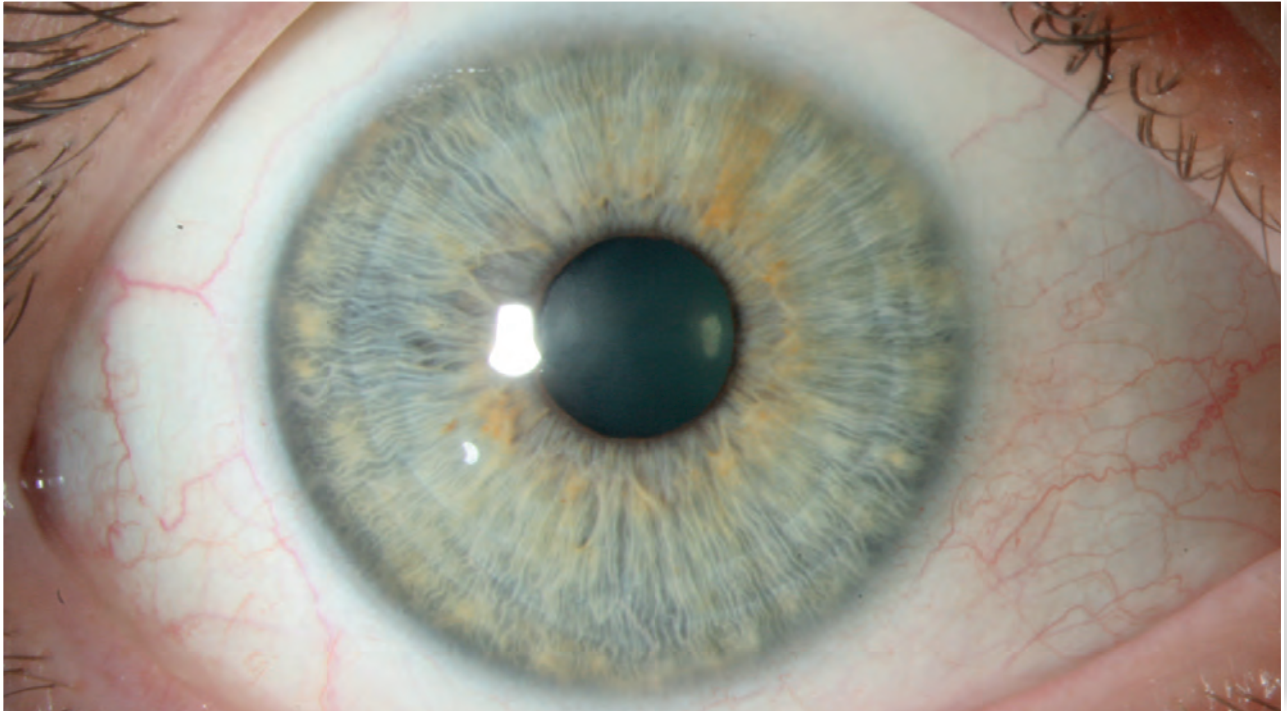
Peripheral ulcer with unaltered corneal sensitivity	84
Catarrhal infiltrates and phlyctenular keratitis	86
Autoimmune marginal ulcers	96
Superior limbic keratoconjunctivitis	106
Central and/or peripheral ulcers with unaltered sensitivity	108
Eyelids malpositions	110
Toxic keratitis	114
<i>Other limbal stem cells deficiencies (page 134)</i>	
Central or paracentral ulcers with unaltered sensitivity	116
Vernal keratoconjunctivitis	118
Atopic keratoconjunctivitis	120
Rosacea (central involvement)	122
Keratolysis and rheumatoid arthritis	126
Cicatrising conjunctivitis	128
Other limbal stem cell deficiencies	134
Dry eye disease	138
Thygeson's superficial punctate keratitis	142
Management of peripheral or central ulcers with unaltered corneal sensitivity	144
CONCLUSION.....	146

1

CORNEAL EPITHELIAL RENEWAL AND HEALING

THE CORNEA AND ITS EPITHELIUM

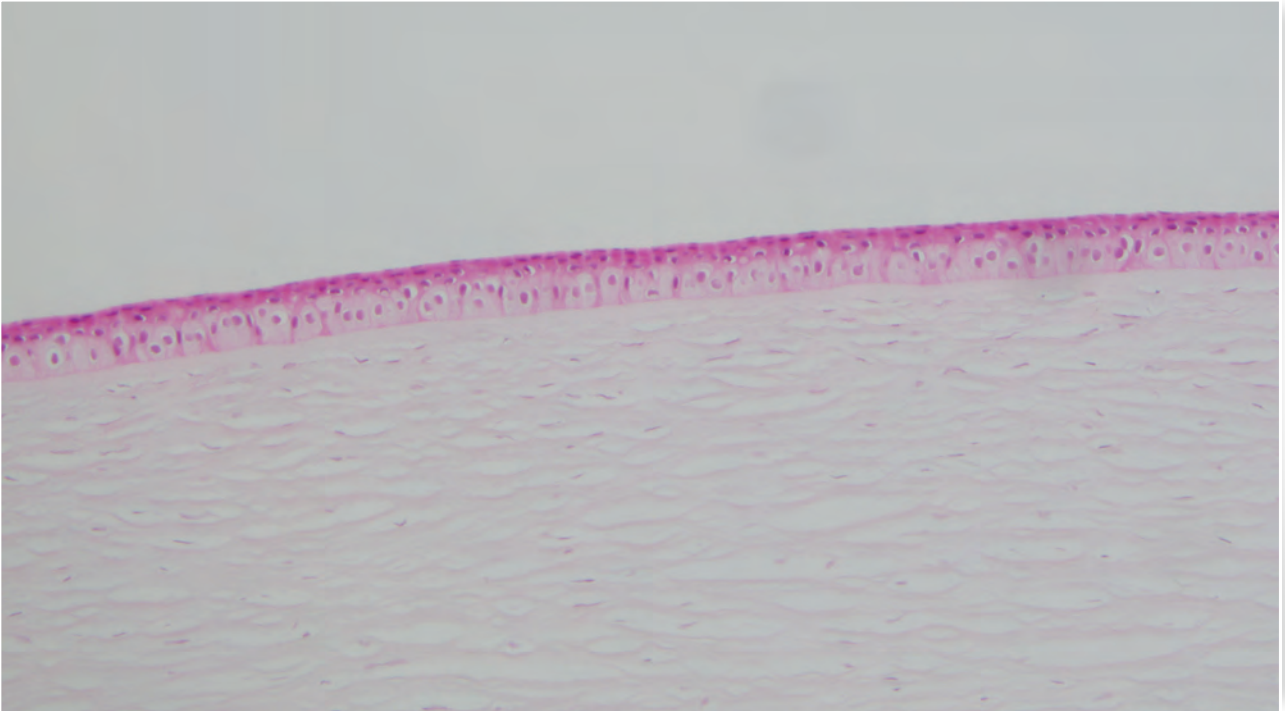
- The cornea is the avascular and transparent structure, embedded like a window in the front of the eyeball. The cornea consists from front to back of a stratified, non-keratinised epithelium, which rests on the Bowman's layer of the anterior stroma by means of a basal membrane. Then follows a collagen-rich stroma representing 90% of the total thickness, then, the Descemet's membrane, which is the basal membrane of the endothelium, a mono-cellular layer.
- The adjacent conjunctival epithelium is vascularised. The conjunctival epithelium is stratified and nonkeratinized. It contains goblet cells which secrete mucins. The epithelium of the cornea and the conjunctiva are separated by the limbal epithelium.
- Anatomically, the ocular surface includes the corneal and conjunctival epithelia together with the tear film. A disorder of any single anatomical component of the ocular surface is capable of altering other components.



The cornea and the ocular surface.

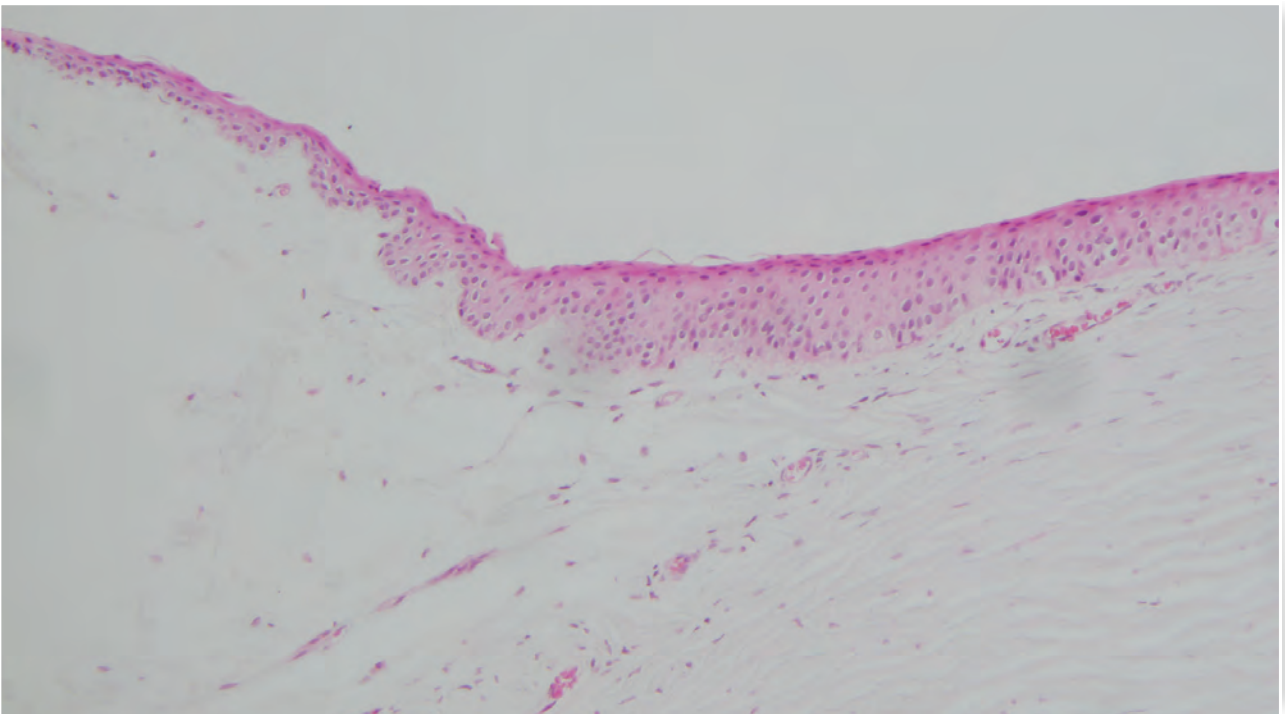
The "ocular surface" entity includes the corneal epithelium and the conjunctival epithelium, separated by the corneo-conjunctival limbus, and the tear film.

THE CORNEA AND ITS EPITHELIUM



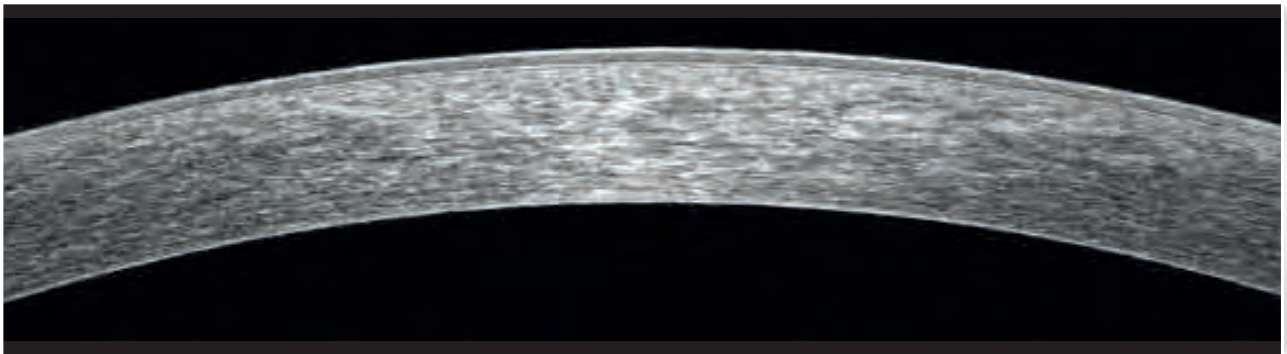
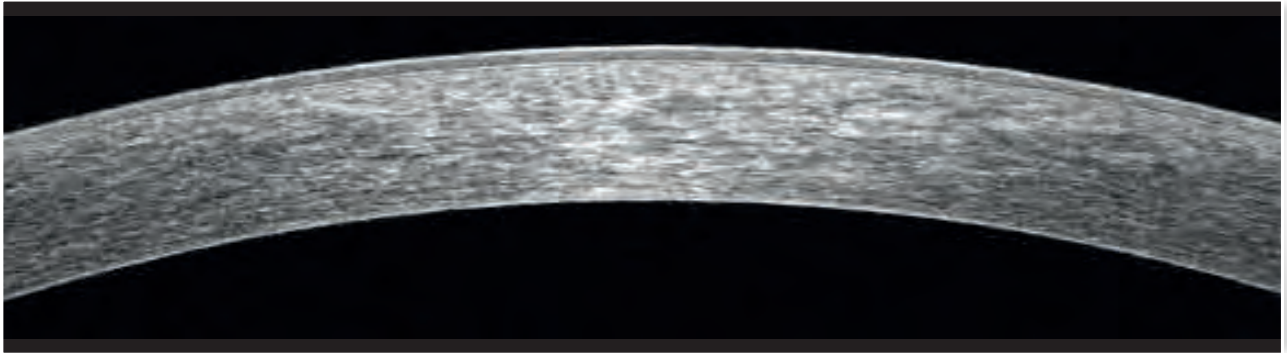
The corneal epithelium.

This is a stratified squamous epithelium 50 μm thick. It comprises 5 to 7 cell layers and rests by means of a basal membrane on Bowman's layer. The underlying stroma is also visible in this histological section. (haematoxylin-eosin, X100).



The corneoscleral limbus.

Here the epithelium thickens and has 10-12 layers. It is possible to observe the vascularisation present in the region of the limbus while it is absent at the peripheral corneal stroma (haematoxylin-eosin, X100).



Images of normal cornea using Spectral Domain OCT and Swept Source OCT.

The main layers of the cornea are visible, from the tear film to the endothelium.

From top to bottom:

- Cirrus OCT®, Carl Zeiss Meditec, Dublin, USA
- Triton OCT®, Topcon, Tokyo, Japan

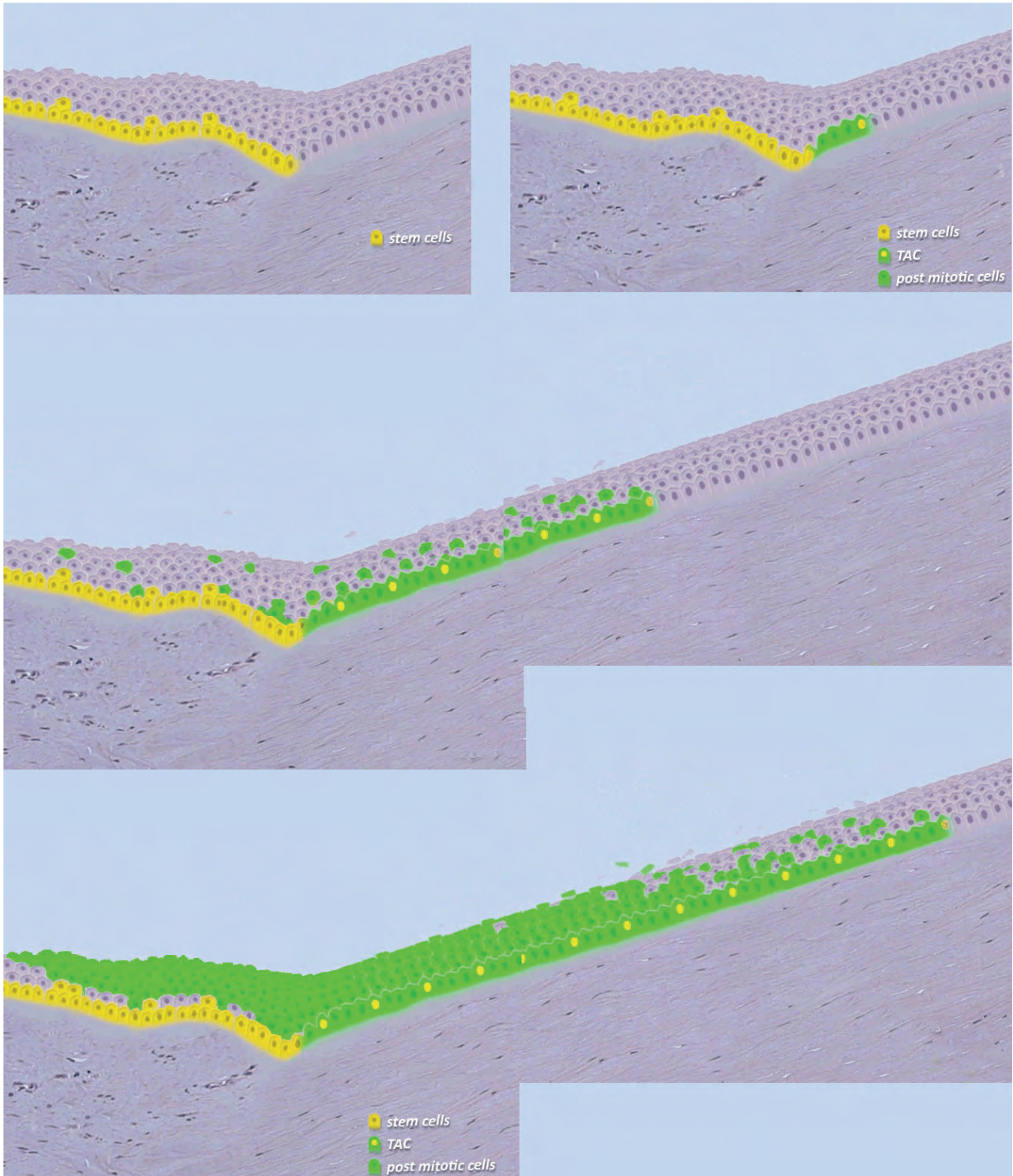
CORNEAL EPITHELIAL RENEWAL

- It is important to make the distinction between the healing mechanisms triggered during an injury with those present in the physiological renewal of this epithelium.
- There are two schools of thought about the physiological renewal of the epithelium of the human cornea.

Epithelial renewal from limbal stem cells (dominant theory)¹:

- The corneal epithelium is renewed within 15 days from stem cells localised exclusively in the limbus. The basal epithelial cells, whose average diameter is 10 μm , have to travel about 6 mm (or 600 times their diameter) to reach the central cornea. They migrate continuously from the limbus to the central cornea like a conveyor belt, at its basal layer. The more superficial supra-basal cells migrate vertically, supporting themselves on the conveyor belt of the basal layer. This entire tissue and its dynamic renewal process have to withstand 10-20 blinks every minute.
- The epithelium is supplied by sensory nerves, which emerge vertically from the anterior stroma and head to the surface epithelium. On the surface, the tear film, which is classically composed of three layers (mucous layer, aqueous layer and lipid layer) plays a fundamental role in nourishing the corneal epithelium and avoiding desiccation. This model underpins our current understanding of the pathologies of the cornea called limbal stem cell deficiency. According to this pathological model, if there are no epithelial stem cells at the limbus, or if the limbus is destroyed, epithelial renewal is adversely affected and the corneal epithelium is replaced by the closest epithelium, the conjunctival epithelium.

1. Dua HS, Azuara-Blanco A. Limbal stem cells of the corneal epithelium. *Surv Ophthalmol.* 2000 ;44:415-25.



Renewal of the epithelium from the limbal stem cells.


The entire renewal is performed from the stem cells located only at the limbus (yellow cells in the diagram). The migration of the transient amplifying cells takes place first at the basal level up to the centre of the cornea, with the post-mitotic cells then migrating to the anterior layers.

CORNEAL EPITHELIAL RENEWAL

Renewal from epithelial stem cells scattered throughout the cornea (second theory)²:

- Another school of thought considers that there are epithelial stem cells distributed ubiquitously throughout the ocular surface, including the cornea. Physiologically the corneal epithelium would then renew itself as does the epidermis of the skin, from the basal stem cells.
- According to this model, there would be no centripetal migration from the limbus during physiological turnover, but this would occur following denudation of central corneal epithelium after injury or insult.

2. Majo F, Rochat A, Nicolas M, Jaoudé GA, Barrandon Y. Oligopotent stem cells are distributed throughout the mammalian ocular surface. *Nature*. 2008;456:250-4.

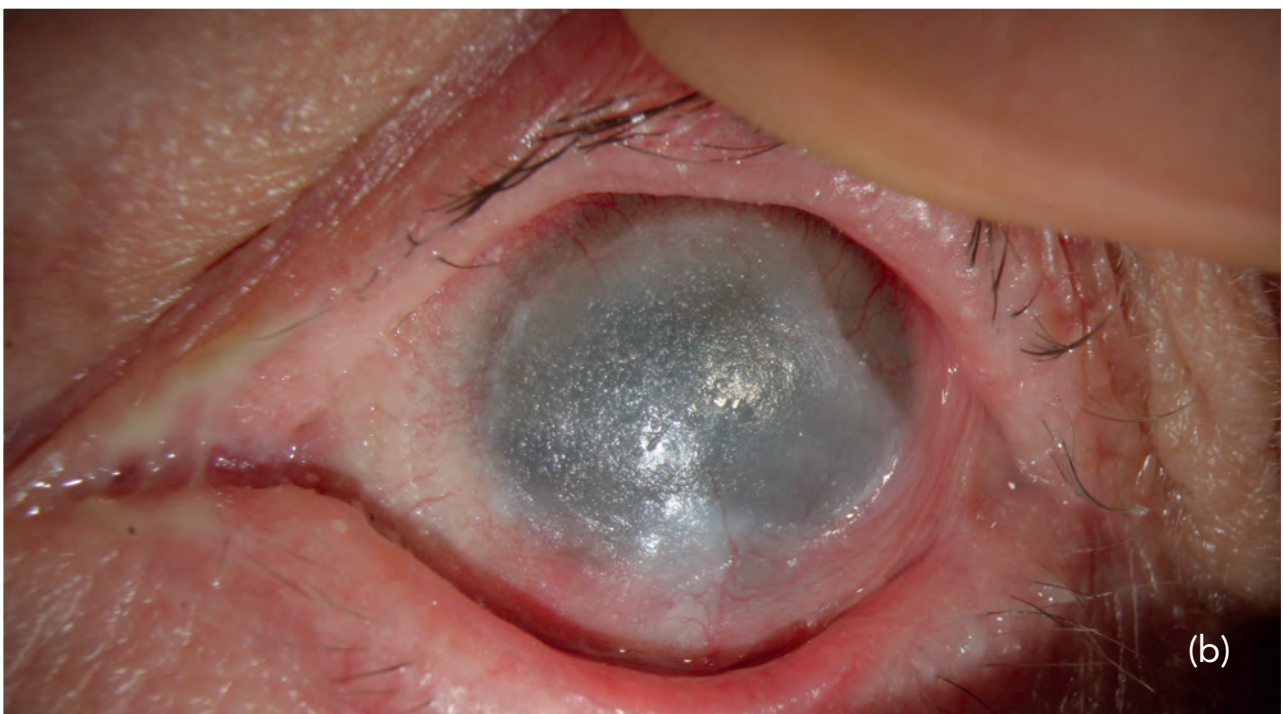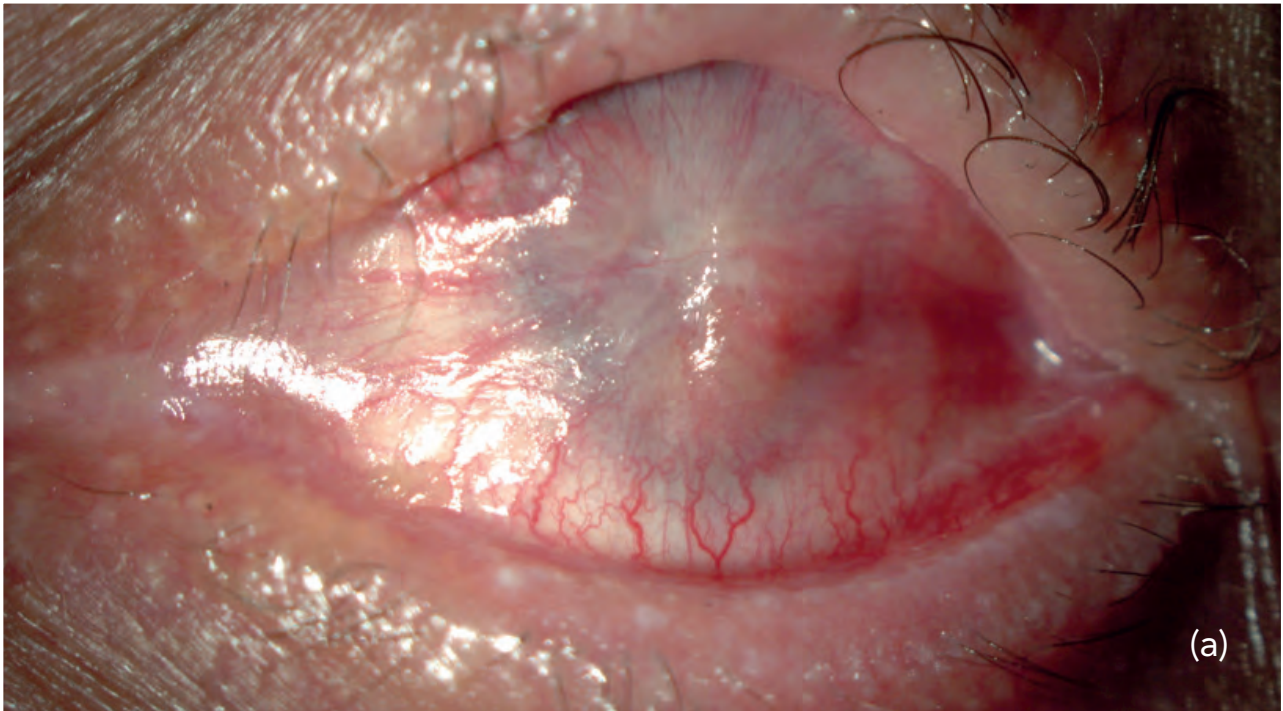


The stem cells are distributed over the entire surface of the cornea.

According to this theory, the epithelium renews itself under physiological conditions from these scattered stem cells (yellow cells in the diagram), as it does in the skin.

PATHOLOGICAL RENEWAL OF THE CORNEAL EPITHELIUM

- With both theories however, epithelial renewal will generate a corneal phenotype of epithelium (transparent, non-keratinised) only if the environment is healthy: tear quality, healthy eyelids, absence of conjunctival inflammation, and preserved innervation.
- In the event of chronic changes in the microenvironment, such as a chronic inflammation of the ocular surface or severe dry eye disease, the corneal epithelium can take on a conjunctival phenotype, or even show keratinisation. This constitutes a metaplasia.



Corneal epithelial metaplasia.

Note the appearance of corneal conjunctivalisation secondary to severe atopy (a) and the keratinisation of the cornea secondary to toxic epidermal necrolysis (TEN) (b).

USUAL HEALING OF CORNEAL ULCERATION

**Without treatment, corneal abrasion
of 6 to 8 mm diameter closes in 48 hours**

- The healing of the corneal epithelium is extremely rapid, as can frequently be seen after superficial corneal abrasion or after refractive photokeratectomy. In such cases, the extended area of stromal matrix not covered by the epithelium normally heals within 24 to 48 hours. The basal epithelial cells at the edge of the wound migrate to fill the denuded area by creating a monocellular layer of flattened cells, which travel with an amoeboid movement. This movement can be observed whilst the abrasion is still present. Then, once the opposing epithelial cells from the wound edges come into contact, the migration is stopped by contact inhibition. The next step comprises the lamination of the reconstituted epithelium.
- For an injury of 6 mm in diameter to be closed in 48 hours, it is necessary for the epithelial cells to migrate at a rate of 60 to 80 $\mu\text{m}/\text{hour}$ or 6 to 8 times their diameter in the resting state.

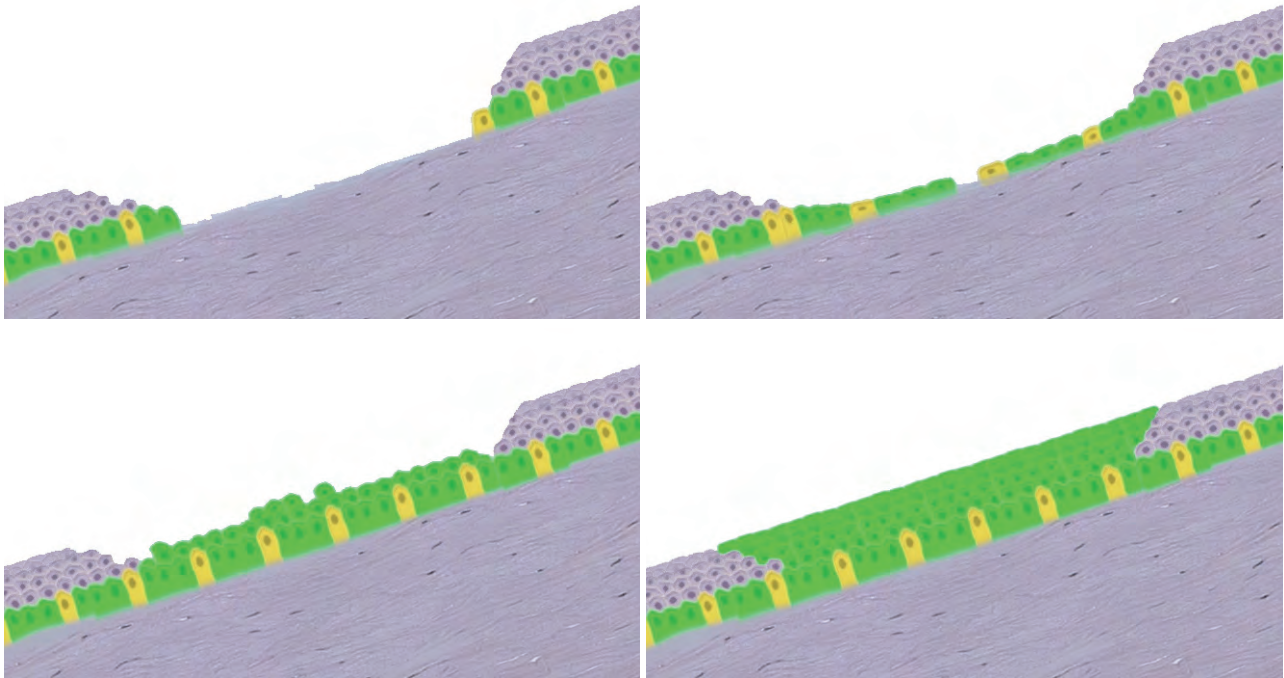
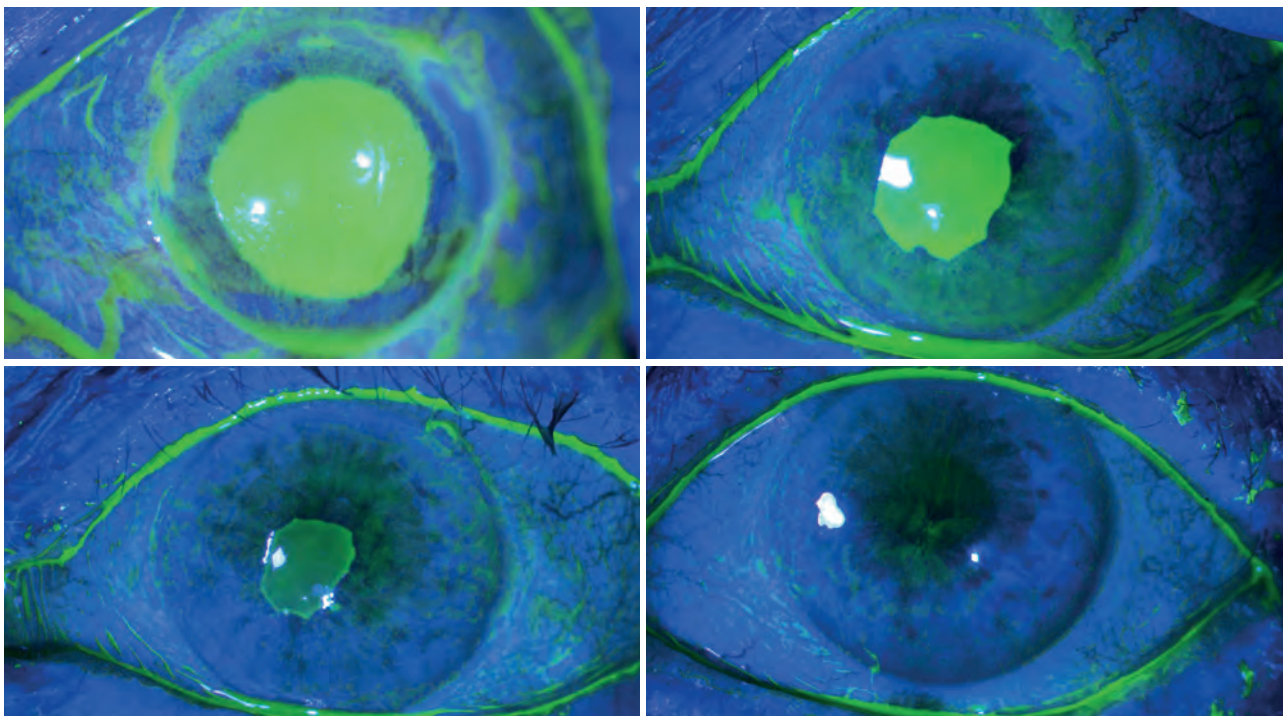


Diagram of the corneal epithelium healing.

The usual healing of the corneal epithelium is rapid, comprising an epithelial migration phase and a stratification phase of the reconstituted epithelium.



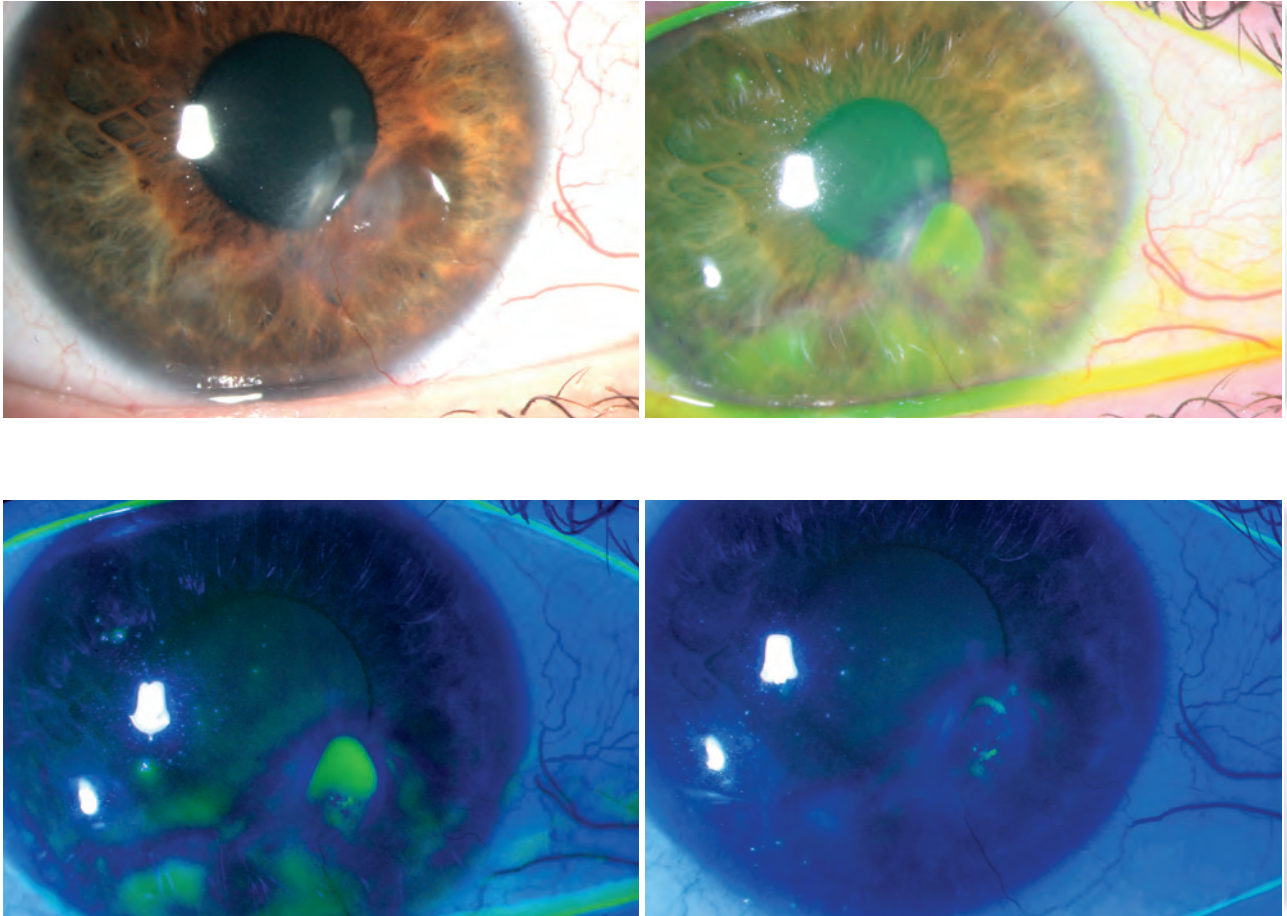
Epithelial healing.

Spontaneous epithelial healing in 48 hours of an abrasion of 7 mm diameter.

CHRONIC CORNEAL ULCERATION: DEFINITION

- **Superficial corneal ulceration** is defined as a loss of the epithelial layer. A **deep corneal ulcer** is defined as a loss of the epithelial layer with involvement of the corneal stroma. During clinical examination with fluorescein dye, it is important not to confuse a corneal ulcer (which stains with fluorescein) and a healed corneal ulcer which may cause a facet or irregular area of the cornea resulting in a *pooling* effect.
- A **corneal facet** or an **irregular area of the corneal surface** can result in pooling of fluorescein dye. When examined with white light through a cobalt blue filter the pooled dye gives the appearance of a stained ulcer. However, when a swab or sponge is applied to the 'stained area' the dye is absorbed revealing the intact underlying epithelium and the false appearance of a stained area.

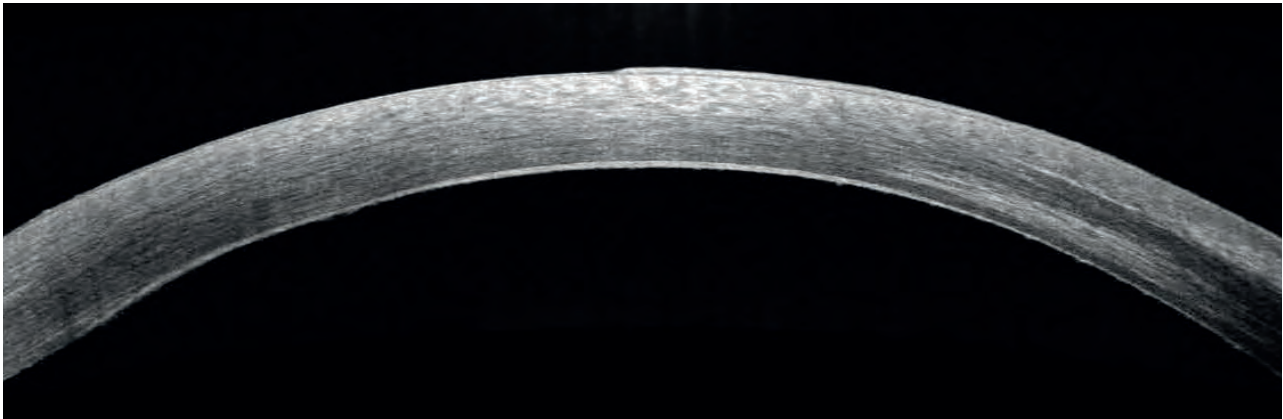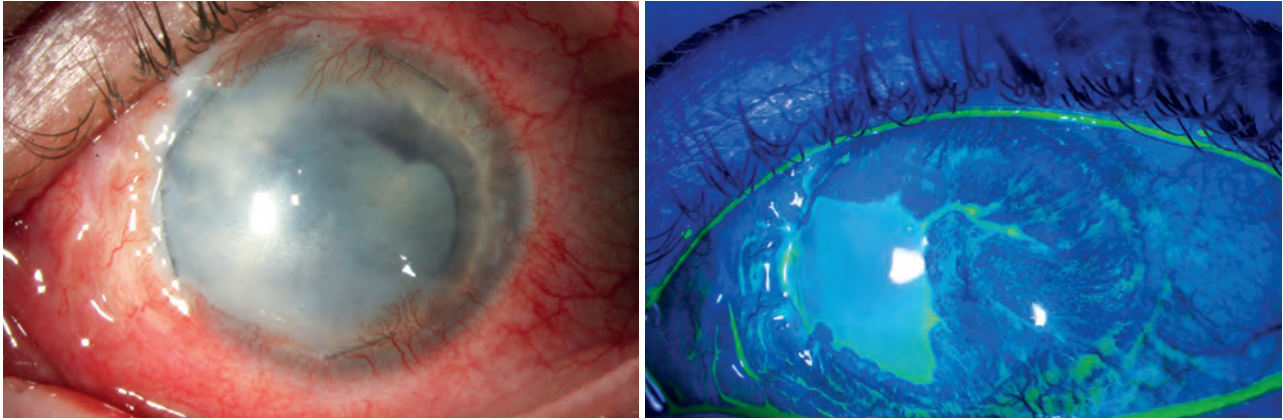
A chronic corneal ulcer is an ulcer which does not heal 3 weeks after development.



Appearance of "false corneal ulcer".

The white light examination is suggestive of a corneal ulcer with a stromal loss. After instillation of fluorescein, the white and cobalt blue light examination seems to confirm the dye retention. However, it is possible to «absorb» the fluorescein in the area of concern with a swab until it disappears. This confirms that the corneal epithelium is intact and a pooling effect is being observed.

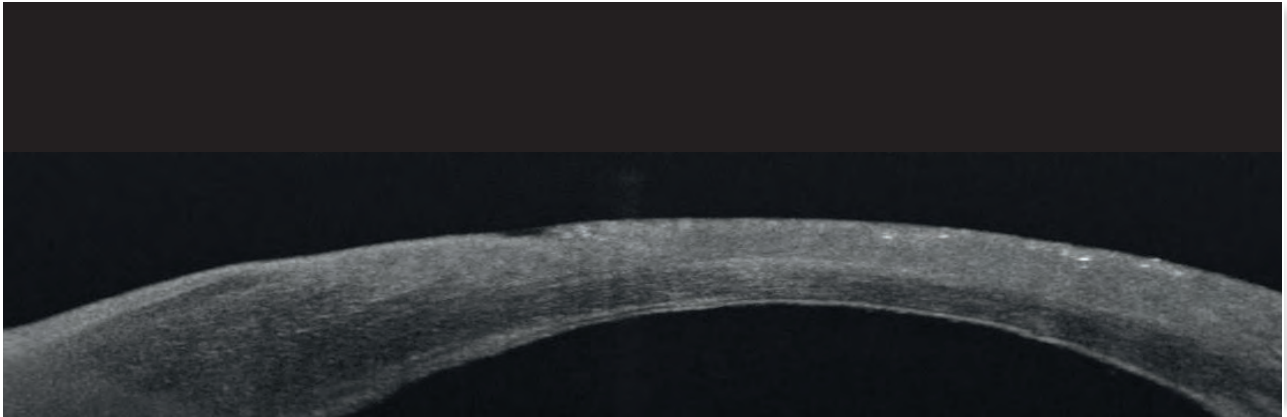
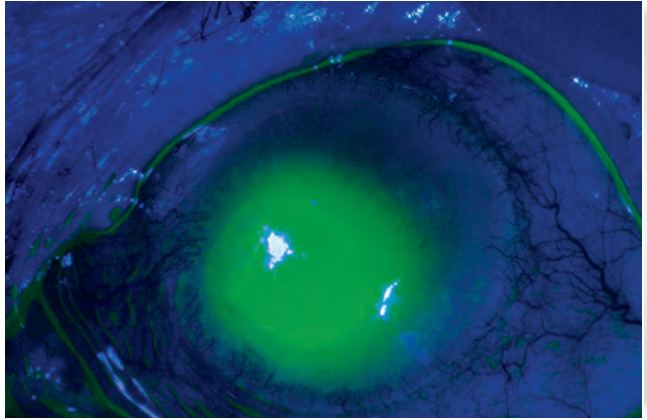
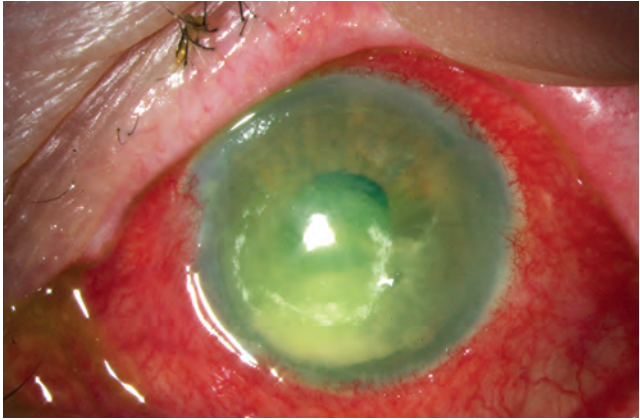CHRONIC CORNEAL ULCERATION: DEFINITION



Superficial corneal ulceration.

Persistent superficial corneal ulceration after alkali chemical burn, despite an amniotic membrane transplantation (the corneal stitches are still visible).

Note the absence of an overlying epithelial layer at the level of the ulceration without stromal involvement using SD-OCT.



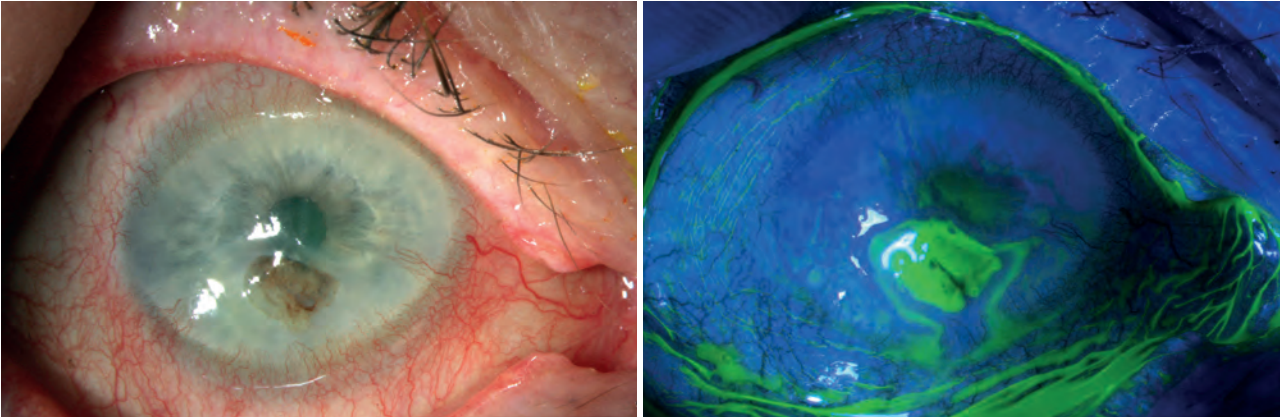
Deep corneal ulcer.

Chronic corneal ulcer following bacterial keratitis being resolved. Note the fluoroquinolone deposits and the persistent fibrin in the anterior chamber.

Using Swept Source OCT (Triton®, Topcon, Tokyo, Japan), the anterior stromal involvement is visible beyond the epithelium, as well as the corneal thinning.

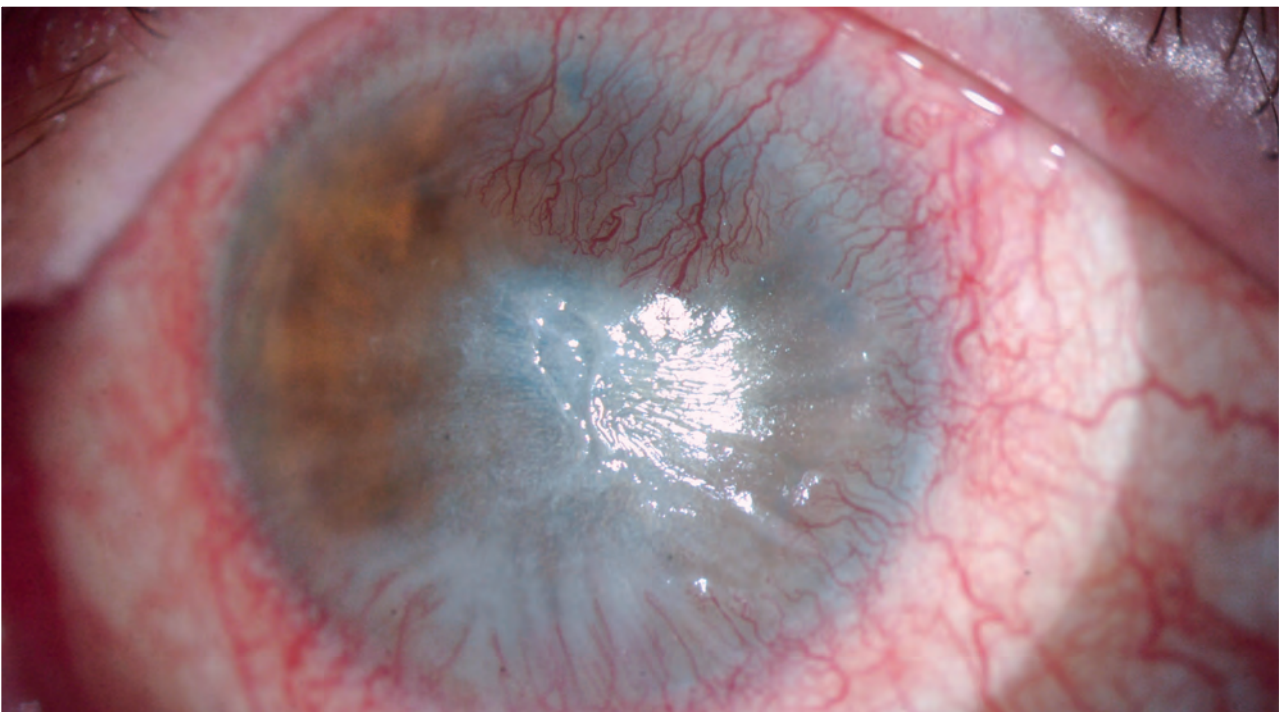COMPLICATIONS OF ULCERS

- The occurrence of a corneal ulcer requires prompt treatment as there is a real risk of progression to corneal perforation.
- In addition to the risk of perforation, the corneal ulcer could result in sight-threatening complications due to neovascularisation and infection risks.
- When the ulcer is healed, visual recovery depends not only on the severity of the residual opacities but also on the size of any secondary corneal thinning and any induced irregular astigmatism.



Corneal perforation.

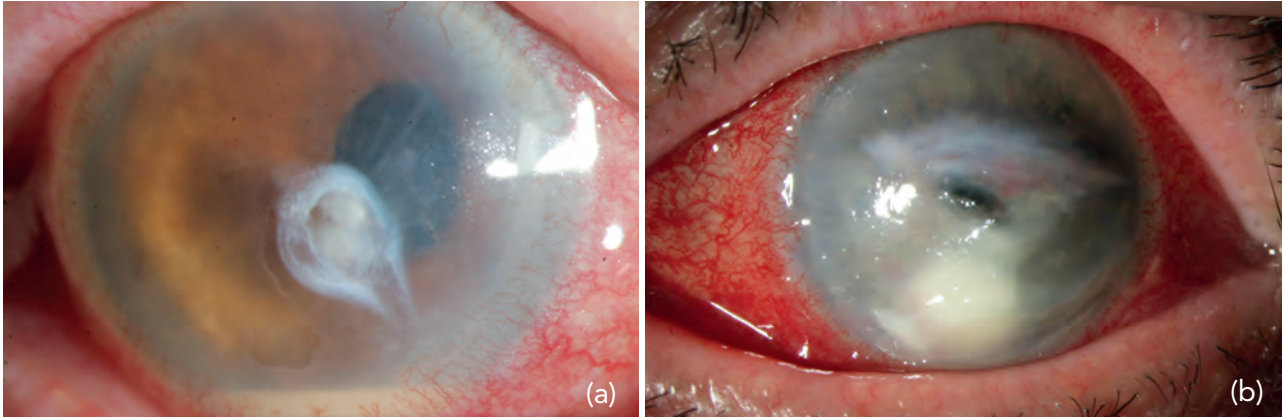
Neurotrophic ulcer following herpes zoster ophthalmicus which occurred 10 months previously, complicated by a corneal perforation with iris prolapse. Note the positive Seidel sign at examination with cobalt blue light; the fluorescein is washed by the flow of aqueous humour.



Corneal neovascularisation.

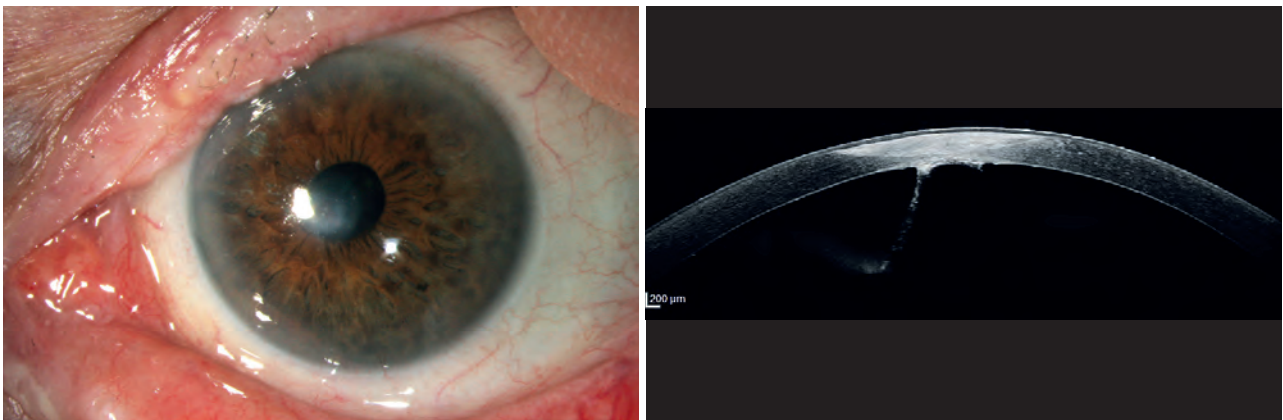
Neurotrophic corneal ulcer; note the peripheral neovascularisation.

COMPLICATIONS OF ULCERS



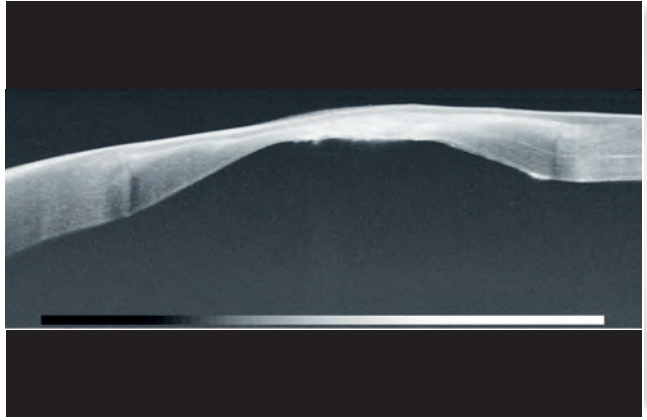
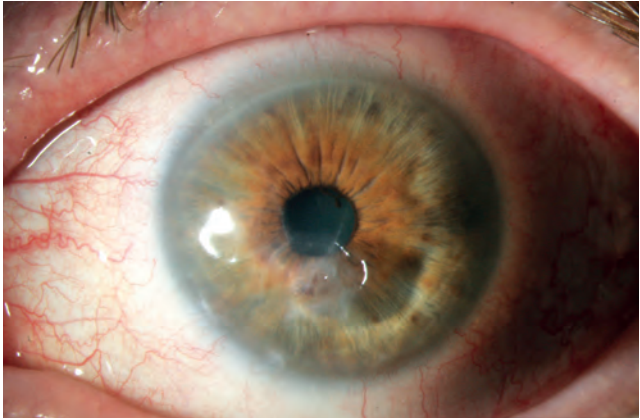
Corneal infection.

Staphylococcus aureus keratitis in two patients with a neurotrophic ulcer after herpes zoster ophthalmicus. Note the stromal infiltrate and the hypopyon (a), and the stromal infiltrate and the fibrin in the anterior chamber (b).



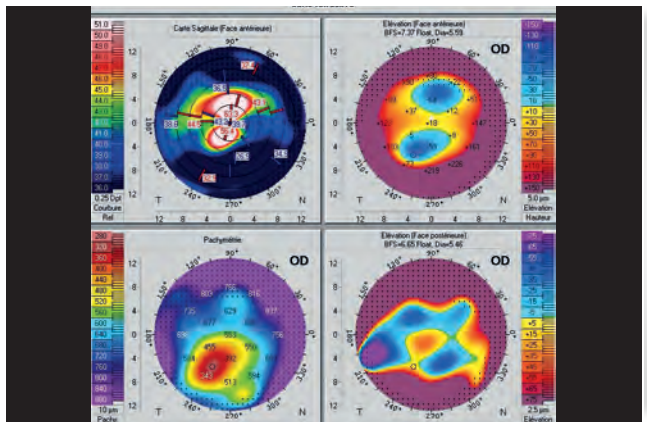
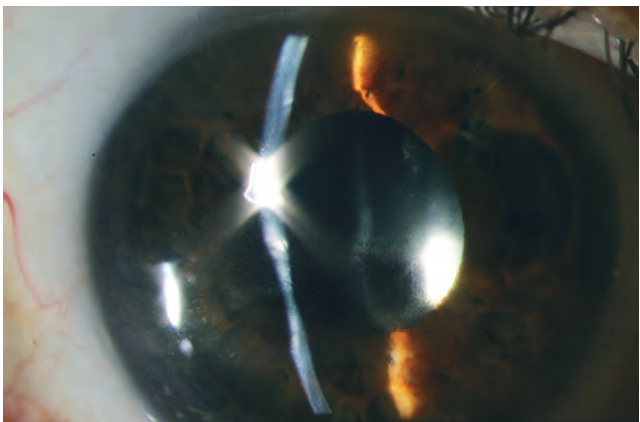
Stromal opacity.

Paracentral corneal opacity of a perforated ulcer treated with multi layered amniotic membrane transplantation. Using SD-OCT (Spectralis OCT®, Heidelberg, Germany), the stromal opacity and the iridocorneal anterior synechia induced by the corneal perforation are visible.



Corneal thinning.

Post-infectious neurotrophic ulcer complicated by a corneal perforation. Appearance at 1-month after multi layered amniotic membrane transplantation and removal of sutures. Note the major thinning visible in the corneal scar area using Swept Source OCT (Triton®, Topcon, Tokyo, Japan).



Irregular astigmatism.

Consequence of a healed neurotrophic ulcer. Note the thinning and induced irregular astigmatism of 6.9 dioptres (Pentacam®, Oculus, Arlington, United States).

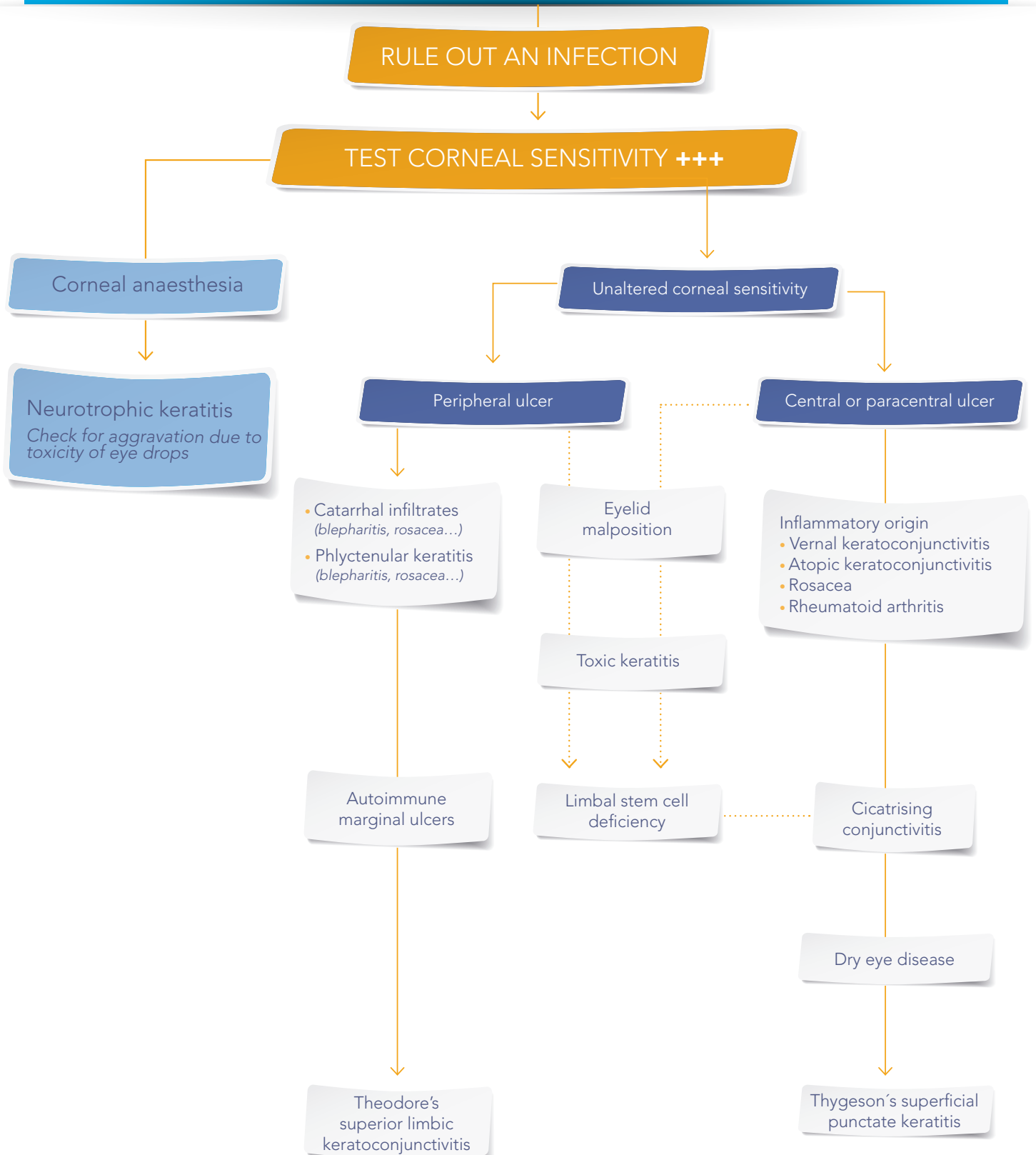
2

DIAGNOSTIC AND THERAPEUTIC APPROACH

DIAGNOSTIC APPROACH INTRODUCTION

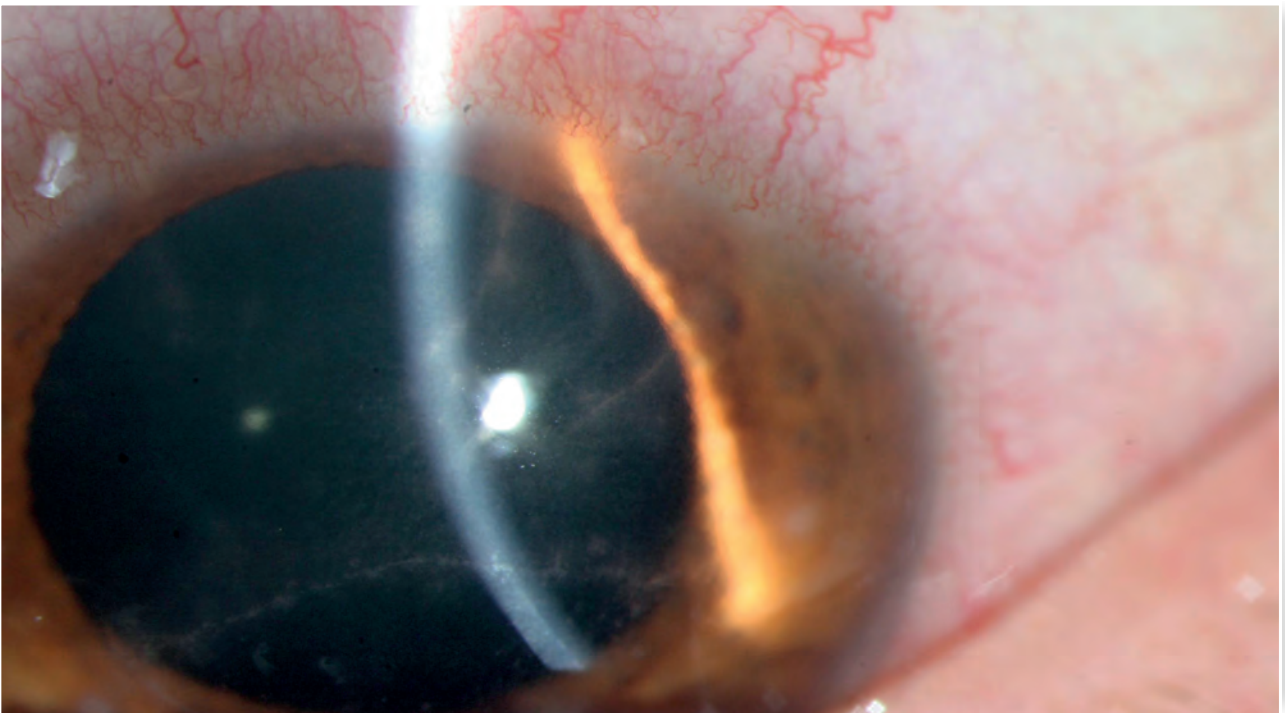
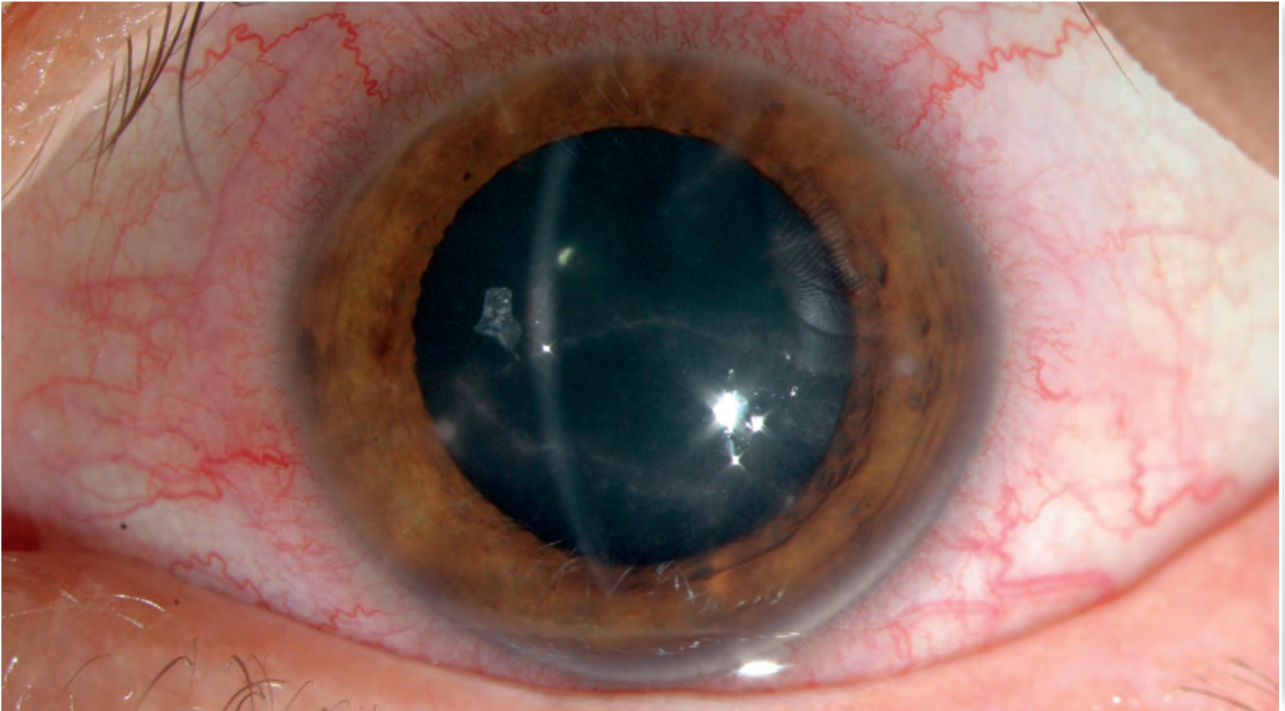
- Corneal ulcers are the consequence of varied and sometimes complex pathophysiological phenomena. The diagnostic approach to a chronic corneal ulcer requires examination of key clinical features.
- The diagnostic approach is summarised in the figure on the next page. Caution is required however concerning rigid interpretation of these rules, as some initial corneal disorders, especially herpes, can be extremely misleading.
- Throughout the remainder of this book, these different clinical situations will be illustrated to explain this diagnostic algorithm.

DIFFERENTIAL DIAGNOSIS WHEN FACED WITH KERATITIS OR A CHRONIC ULCER



RULE OUT AN INFECTION!

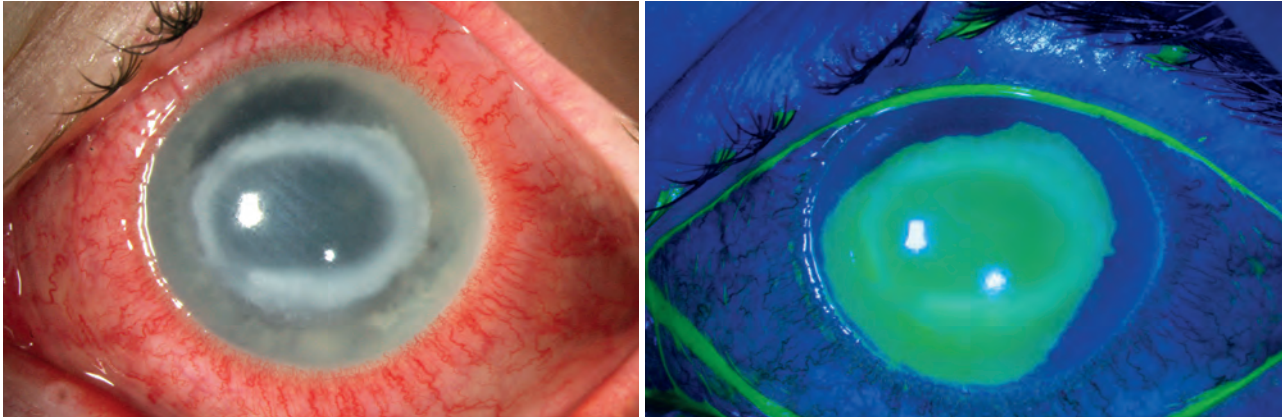
- Although infectious keratitis occurs most often with an acute onset, diagnosis can be difficult, particularly in cases of *Acanthamoeba* keratitis or herpes keratitis. Indeed, these infectious keratitides can progress in a chronic manner with little or no stromal infiltrate, at least in the early stages. This is a sign seen significantly less during bacterial or fungal infections.
- Infection should be suspected in cases of focal stromal infiltrate and hypopyon.
- Microbiological samples should be taken if there is the slightest doubt. Indeed, it is sometimes difficult to formally eliminate an infection in a patient who has already been treated with several topical medications.



Epithelial *Acanthamoeba* keratitis.

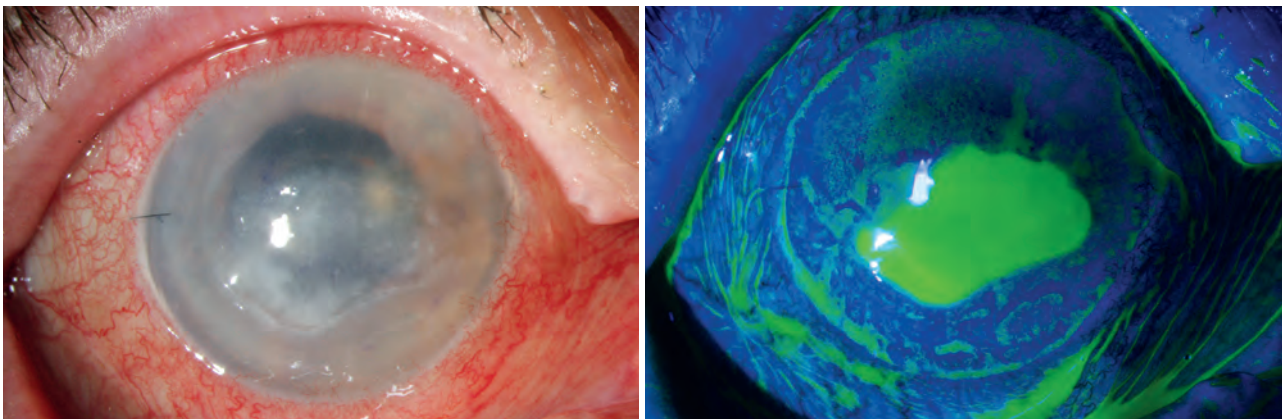
Keratitis in a soft-contact-lens wearer progressed over a 3 weeks period. Note the pseudodentrites and the visualisation of corneal nerves with indistinct edges or perineuritis, pathognomonic of ***Acanthamoeba*** keratitis, when present.

RULE OUT AN INFECTION!



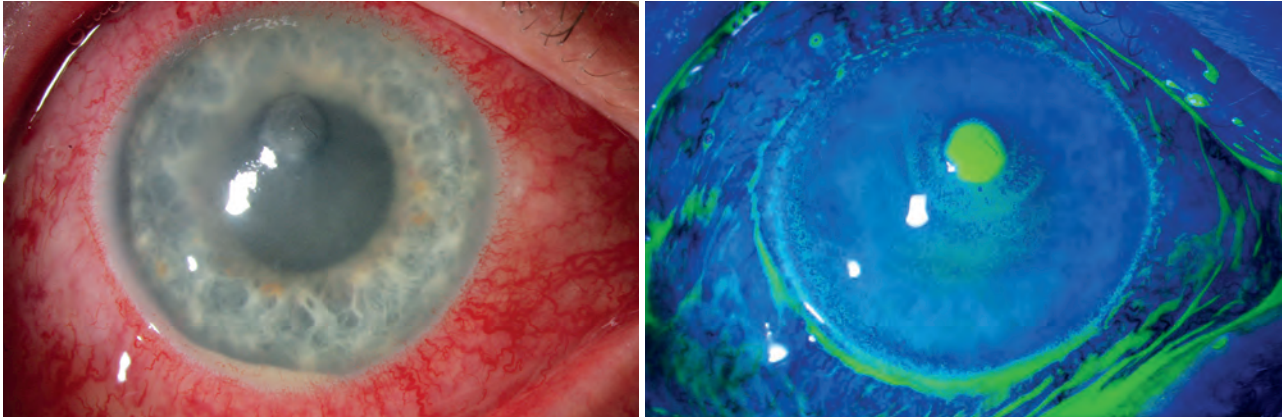
Stromal *Acanthamoeba* keratitis.

Keratitis in a soft-contact-lens wearer progressed over 2 months, treated with topical steroids. Note the ring infiltrate corresponding to an immune ring (Wessely ring), very suggestive of *Acanthamoeba* keratitis in the context of intense pain, and also the extensive epithelial ulcer after instillation of fluorescein.



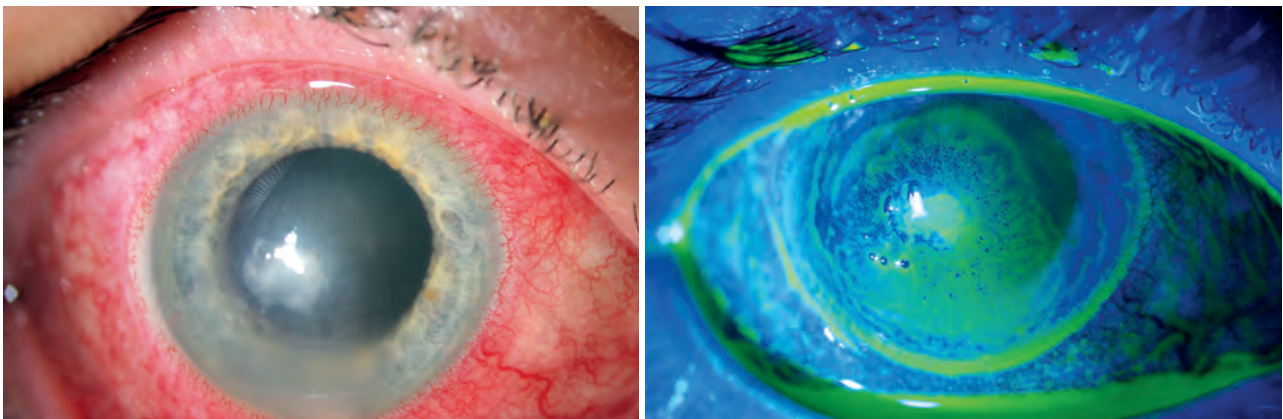
Herpes necrotizing stromal keratitis.

Ulcer progressed over 21 days following an endothelial keratoplasty without known history of corneal herpes. The corneal sampling identified HSV-1 by PCR. Note the extensive corneal ulcer associated with white infiltrate of the underlying stroma.



Bacterial corneal abscess (acute onset).

Keratitis in a soft-contact-lens wearer progressed within 48 hours. *Pseudomonas aeruginosa* was identified in the corneal microbiological samples. Note the upper stromal infiltrate around the epithelial ulceration, surrounding corneal oedema and the hypopyon.



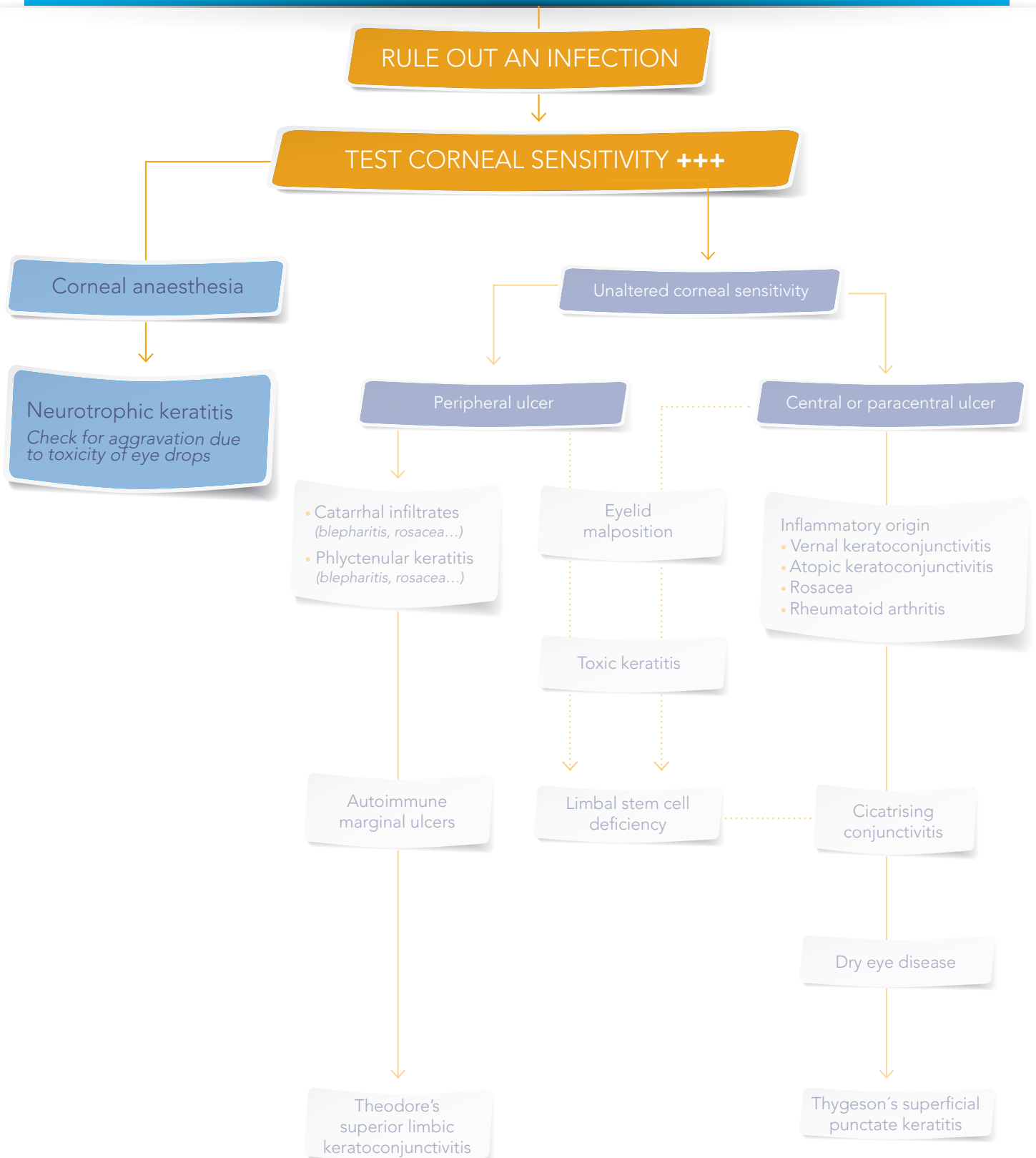
Fungal keratitis (sub-acute evolution).

Keratitis in a soft-contact-lens wearer progressed over 7 days. *Fusarium solani* was identified in the microbiological samples. Note the pronounced corneal oedema at the periphery of the stromal infiltrate and the epithelial ulceration.

DIAGNOSTIC APPROACH

- Once infection is ruled out, the first thing to do is to test the corneal sensitivity.

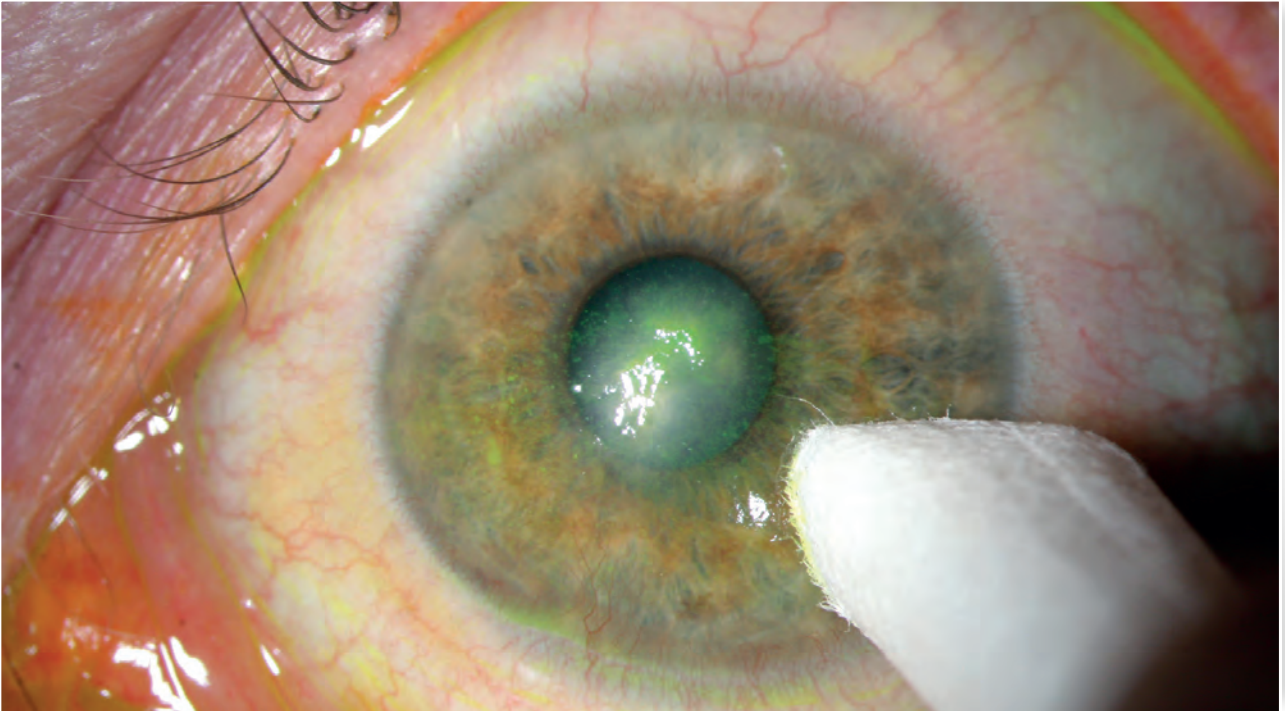
DIFFERENTIAL DIAGNOSIS WHEN FACED WITH KERATITIS OR A CHRONIC ULCER



TESTING CORNEAL SENSITIVITY AND SUSPECTING NEUROTROPHIC KERATITIS

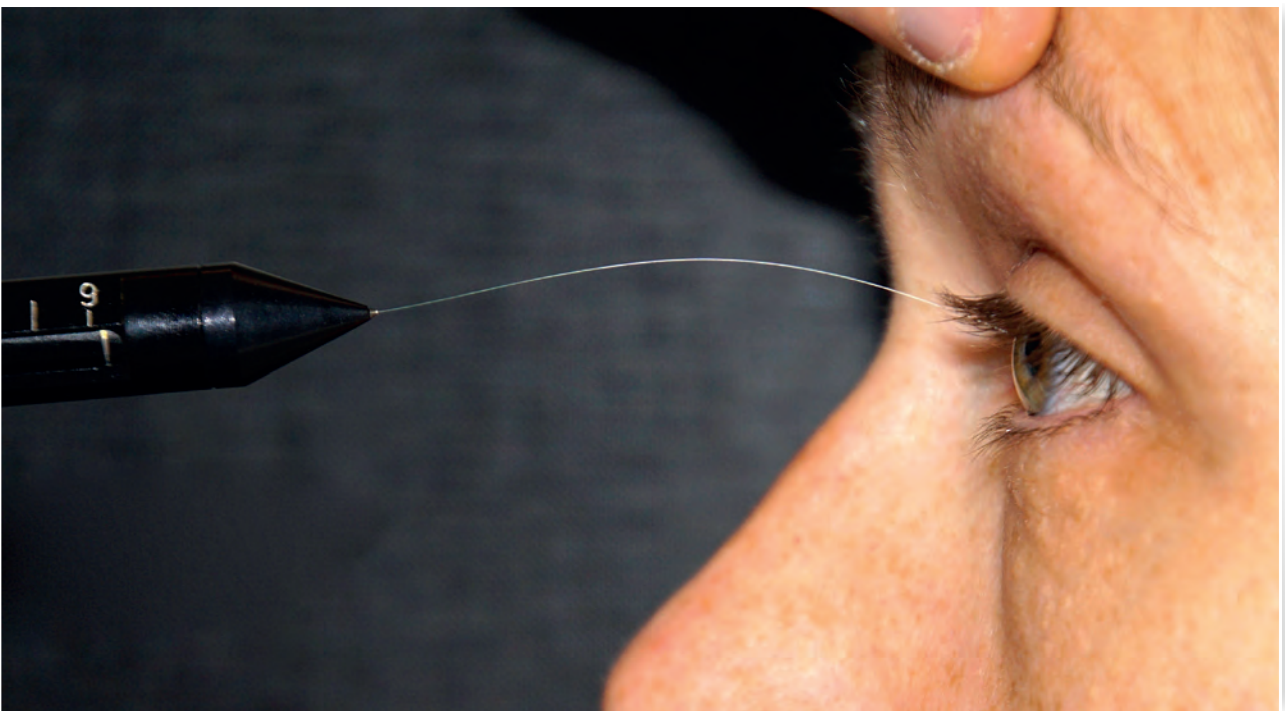
- In chronic ulcers, the diagnostic approach firstly includes the testing of corneal sensitivity. Indeed, corneal anaesthesia and hypoaesthesia are one of the main causes of a chronic ulcer.
- Corneal sensitivity can be tested by contact or non-contact methods. The Cochet-Bonnet aesthesiometer is the reference instrument. It allows a quantitative measure of sensitivity by the application of a nylon thread from 0 to 6 cm long, on the corneal surface. The more sensitivity found with a long nylon thread, the better it is, because the applied force is lower. Conversely, the shorter the nylon thread, the greater the force applied on the corneal surface, and therefore the lower the level of sensitivity required to distinguish it.
- Corneal sensitivity is usually evaluated however, albeit less accurately and more qualitatively, using a bilateral assessment of a patient's feeling of touch on their cornea using a cotton wisp. This is a qualitative test where difference in sensitivity between the two eyes can indicate relative hypoaesthesia.

**Corneal anaesthesia or hypoaesthesia
are signs which highly suggest
a neurotrophic keratitis**



Assessment of corneal sensitivity.

Recurrent herpetic keratitis complicated by a chronic neurotrophic ulcer. The application of a cotton swab on the cornea without inducing a blink reflex confirms corneal anaesthesia.



The Cochet-Bonnet aesthesiometer.

This instrument allows a quantitative measurement of corneal sensitivity using different lengths of nylon thread.

NEUROTROPHIC KERATITIS CLASSIFICATION

- Neurotrophic keratitis should be considered in all cases of chronic corneal ulcers and especially when an ulcer is associated with corneal anaesthesia or hypoaesthesia. Neurotrophic keratitis is a chronic degenerative impairment of the corneal epithelium characterised by a delay in epithelial healing. Corneal neurotrophic ulcer is a relatively rare condition, which requires prompt and aggressive treatment. The initial clinical presentation is characterised by a loss of normal corneal reflection and altered tear film. Even in the absence of trauma, this initial state can progress into superficial punctate keratitis, then to epithelial ulceration, followed by stromal ulcer and finally to corneal perforation.
- Functional signs of neurotrophic keratitis include decreased visual acuity, moderate conjunctival hyperaemia, eye watering, and absent or moderate pain. Neurotrophic keratitis progresses in three stages of increasing severity as described by Mackie *et al* (1978)³.

Stage 1:

- Conjunctival hyperaemia.
- Decreased tear film break-up time (BUT).
- Superficial punctate keratitis.

Stage 2:

- Persistent epithelial ulceration with rounded or oval edge.
- A surrounding zone of epithelial weakness.
- Thickening of the edges of the ulcer, and rolled with time.
- Stromal oedema.
- Aqueous cell and flare.

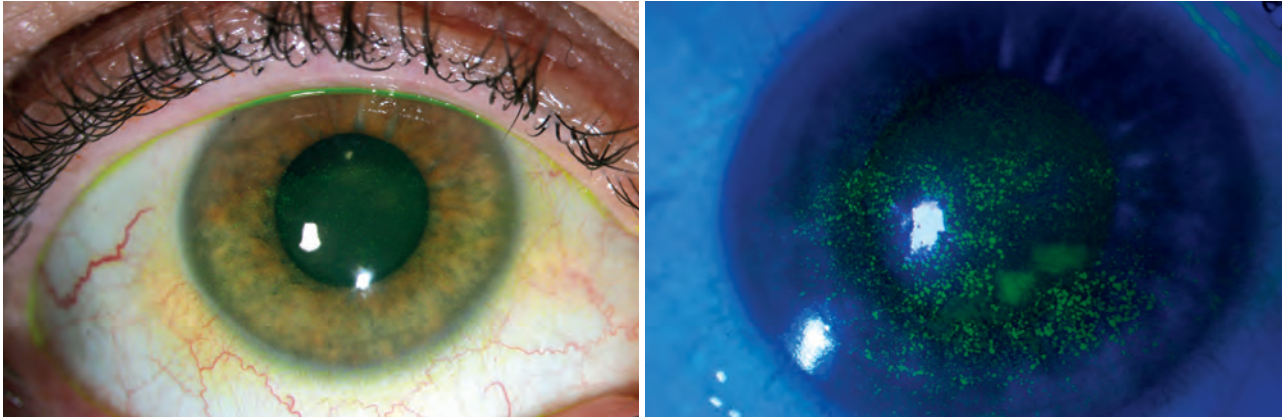
Stage 3:

- Stromal lysis.
- Possible perforation.

Clinical stages of neurotrophic keratopathy according to Mackie (1978)³.

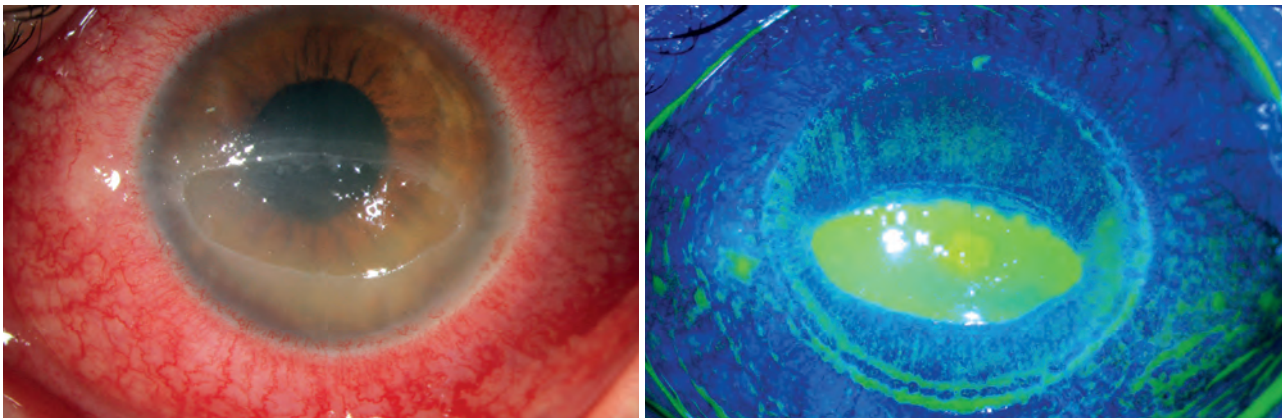
3. Mackie IA. Role of the corneal nerves in destructive disease of the cornea. Trans Ophthalmol Soc UK. 1978;98: 343-7.

NEUROTROPHIC KERATITIS CLASSIFICATION



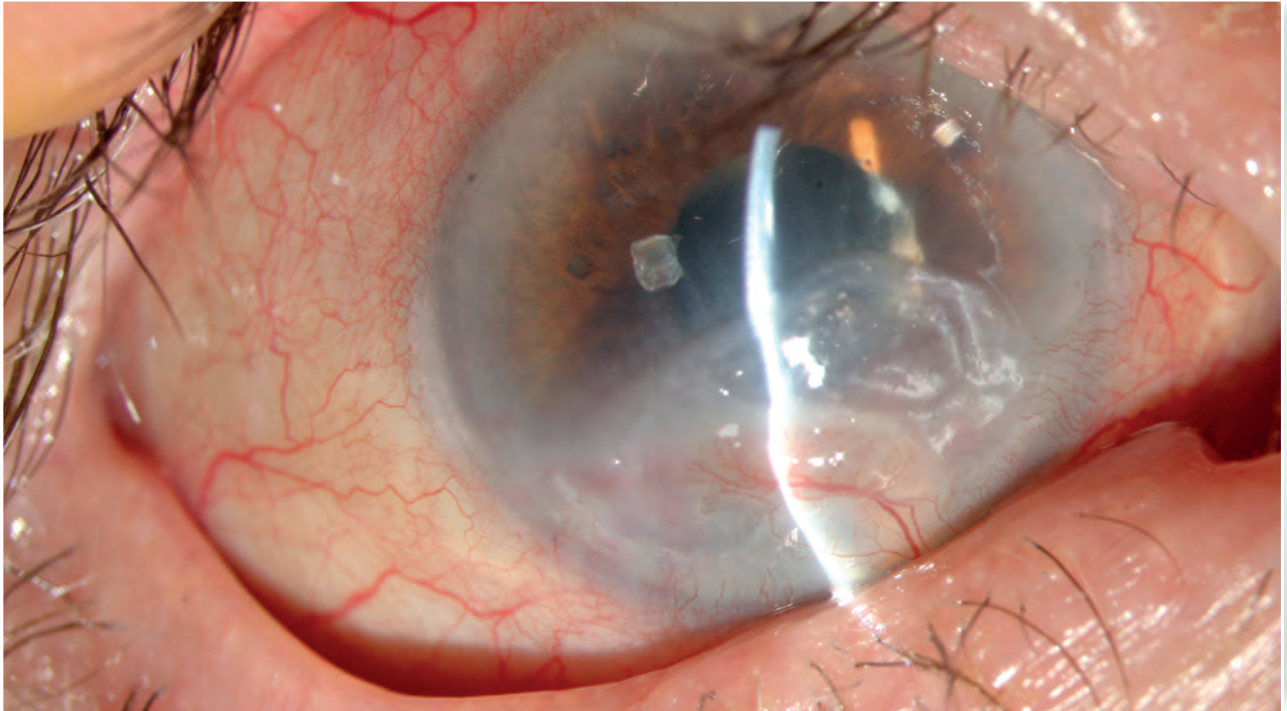
Neurotrophic keratitis, stage 1.

Secondary corneal anaesthesia due to post-surgical damage of the right trigeminal nerve following intracranial meningioma excision. Patient reported a decrease in visual acuity measured at 20/25 without redness or pain. Note the superficial punctate keratitis after instillation of fluorescein.



Neurotrophic keratitis, stage 2.

Epithelial ulceration following a surgical excision of a vestibular schwannoma of the cerebellopontine angle, responsible for corneal anaesthesia. Note the characteristic appearance of a horizontal oval ulcer with thick and rolled epithelial edges.



Neurotrophic keratitis, stage 3.

Corneal ulcer progressing over 1 month after combined trabeculectomy surgery and phacoemulsification for which the patient received non-steroidal anti-inflammatory eye drops. Corneal anaesthesia is also present. Note the deep stromal involvement.

NEUROTROPHIC KERATITIS AETIOLOGIES

- The most common cause of corneal hypoaesthesia or anaesthesia is corneal herpes simplex or varicella zoster virus infections.
- Next, neoplastic lesions or post-surgical damage of the fifth cranial nerve are also important causes. The use of some topical medications, particularly NSAIDs, can also be responsible for decrease of corneal sensitivity.
- NSAID eye drops should not be used, or should be used with extreme caution in patients with local or general risk factors for ocular surface diseases. In addition, it may be necessary to suspend treatment with NSAID eye drops if corneal complications are observed in the postoperative period.

Main aetiologies of neurotrophic corneal ulcers.

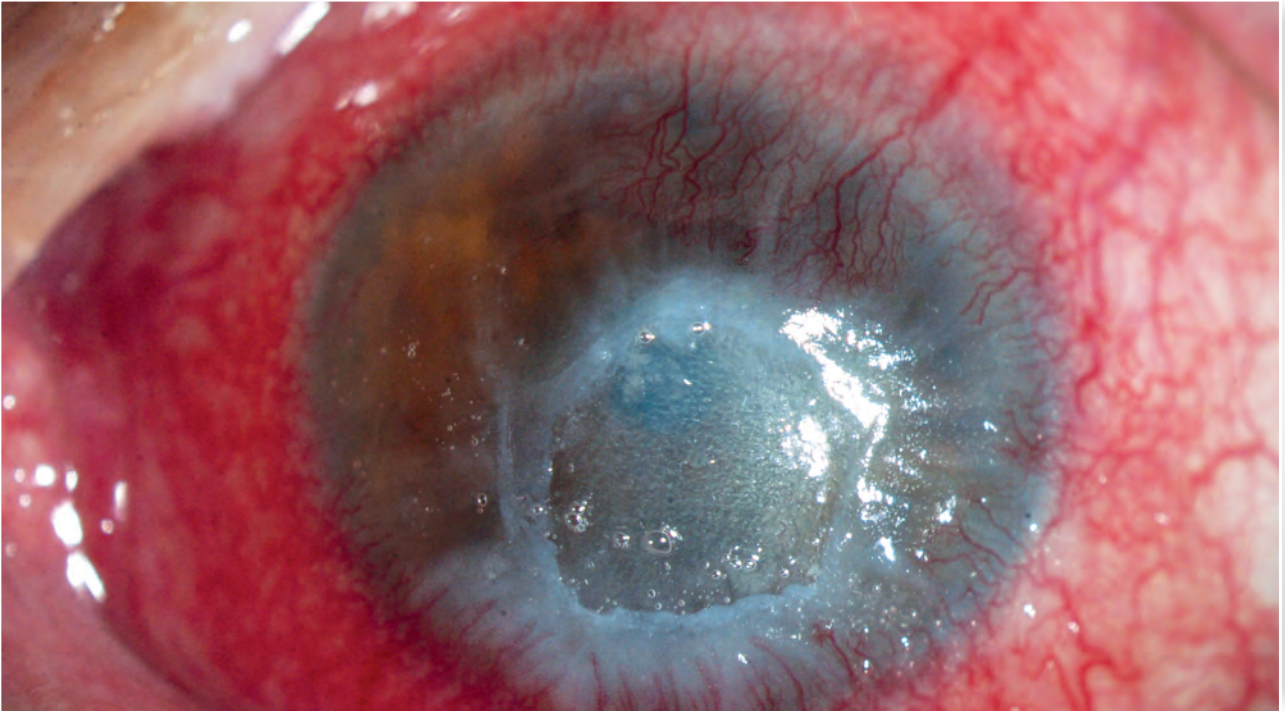
Local aetiologies

- Post-infectious neurotrophic ulcer after *herpes simplex* or *varicella zoster virus* infections.
- Neurotrophic ulcer after topical medications use: abuse of local anaesthetics, NSAID eye drops, preserved eye drops.
- Neurotrophic ulcer after ocular surgery: LASIK, penetrating keratoplasty, vitreoretinal surgery, retinal photocoagulation.
- Neurotrophic ulcer following an ocular burn or any other inflammation or chronic trauma to the corneal epithelium.
- Neurotrophic ulcer after irradiation of the face (proton therapy, brachytherapy, external radiotherapy).

Intracranial or systemic aetiologies

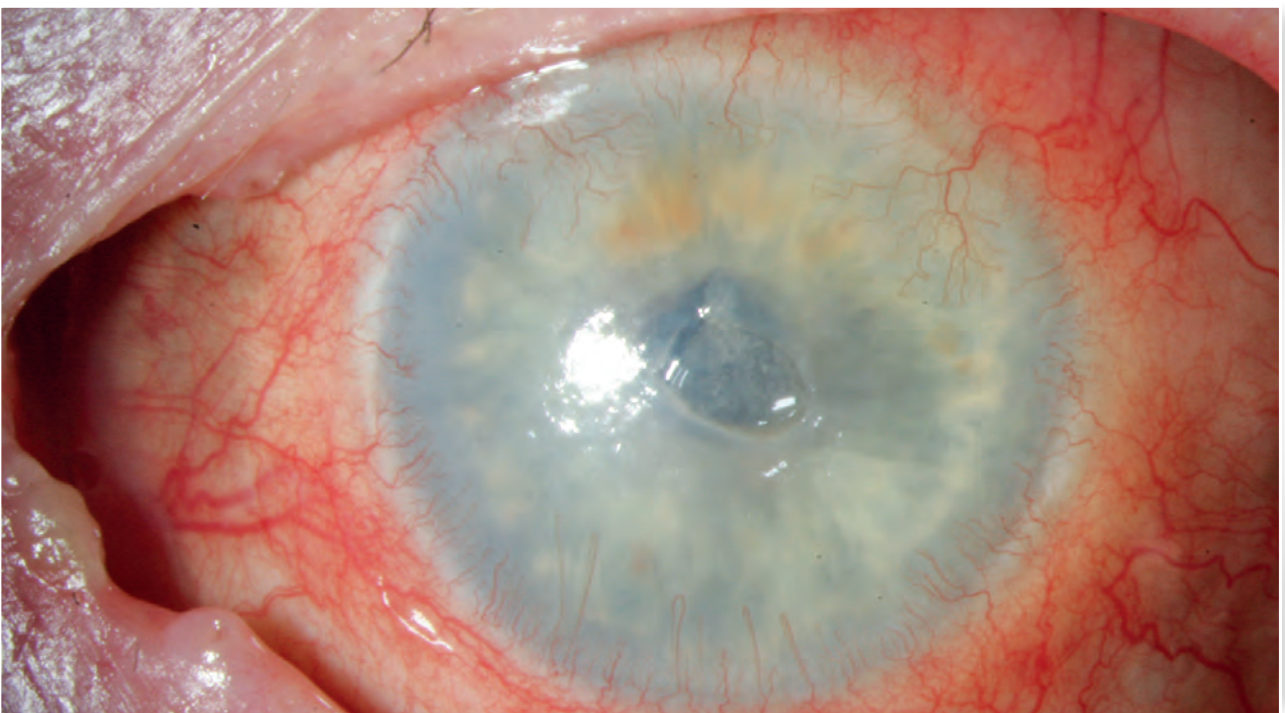- Neurotrophic ulcer due to a congenital disorder of the fifth cranial nerve or secondary to an aneurysm, surgical or non-surgical trauma, or a tumour-related aetiology.
- Neurotrophic ulcer in the context of diabetes or vitamin A deficiency.

NEUROTROPHIC KERATITIS AETIOLOGIES



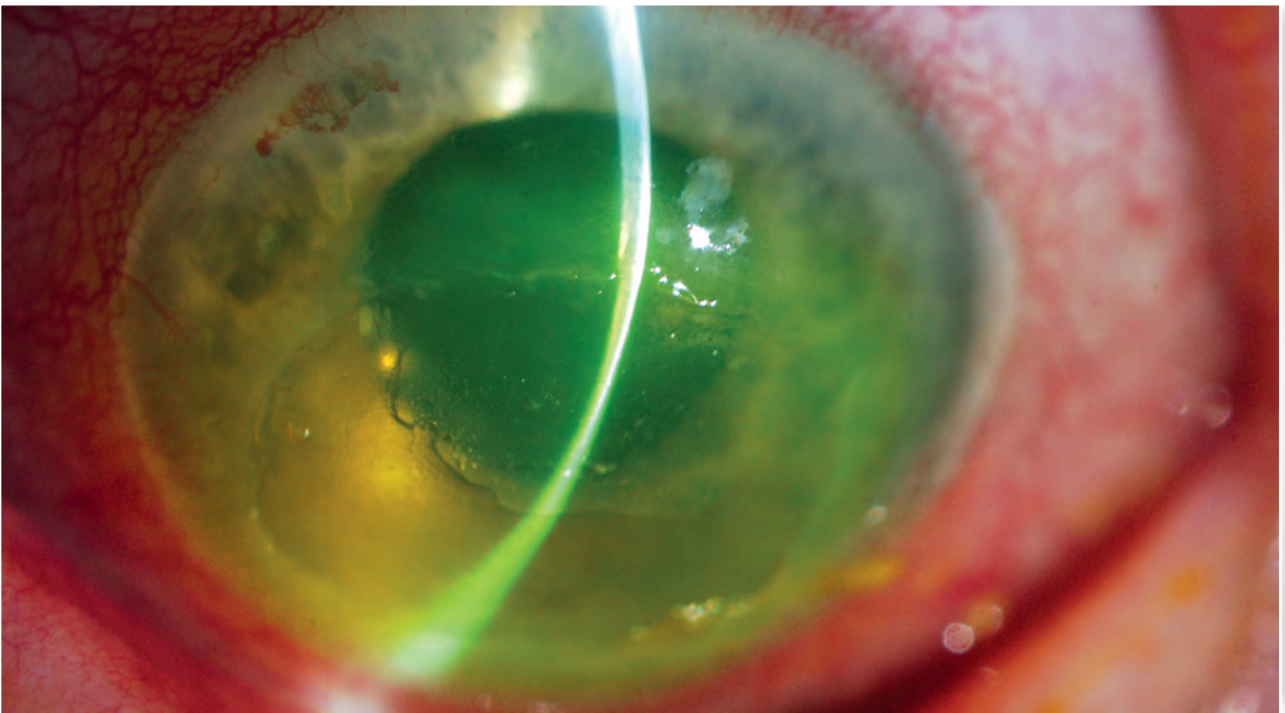
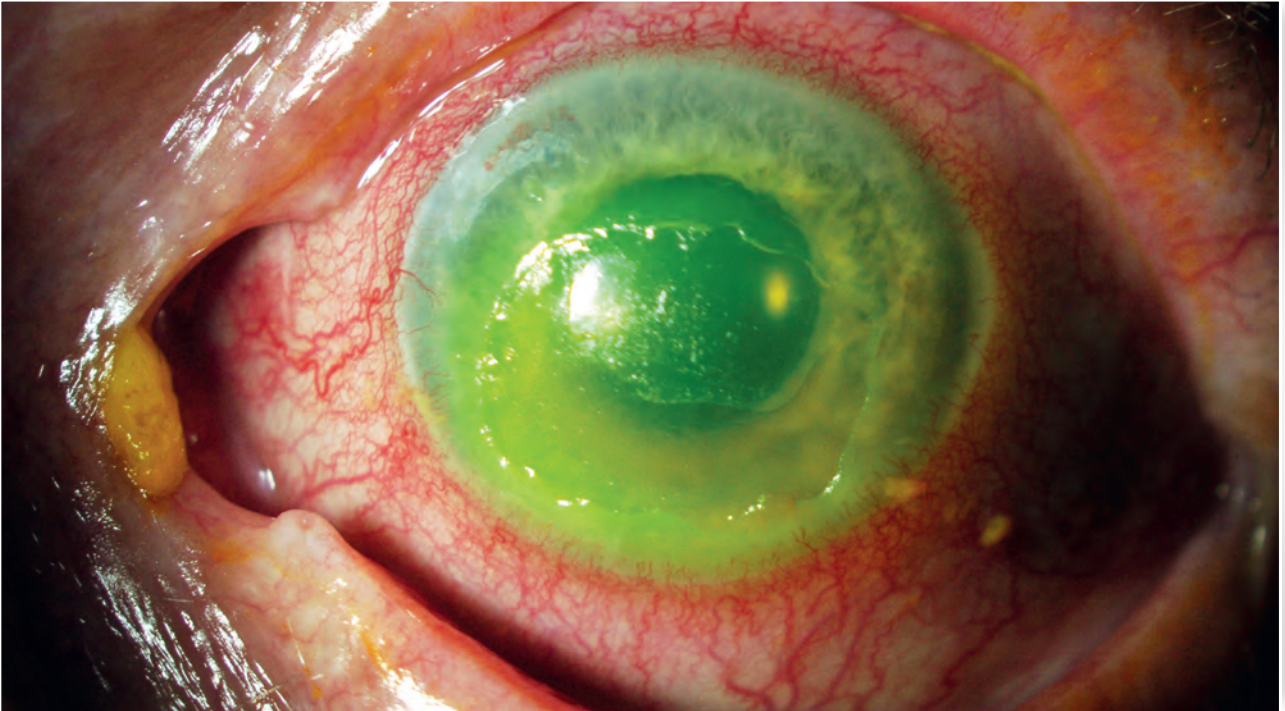Neurotrophic ulcer and herpetic keratitis.

Painless corneal ulcer in a patient with a history of previous multiple herpetic keratitis episodes.



Neurotrophic ulcer and previous herpes zoster keratitis.

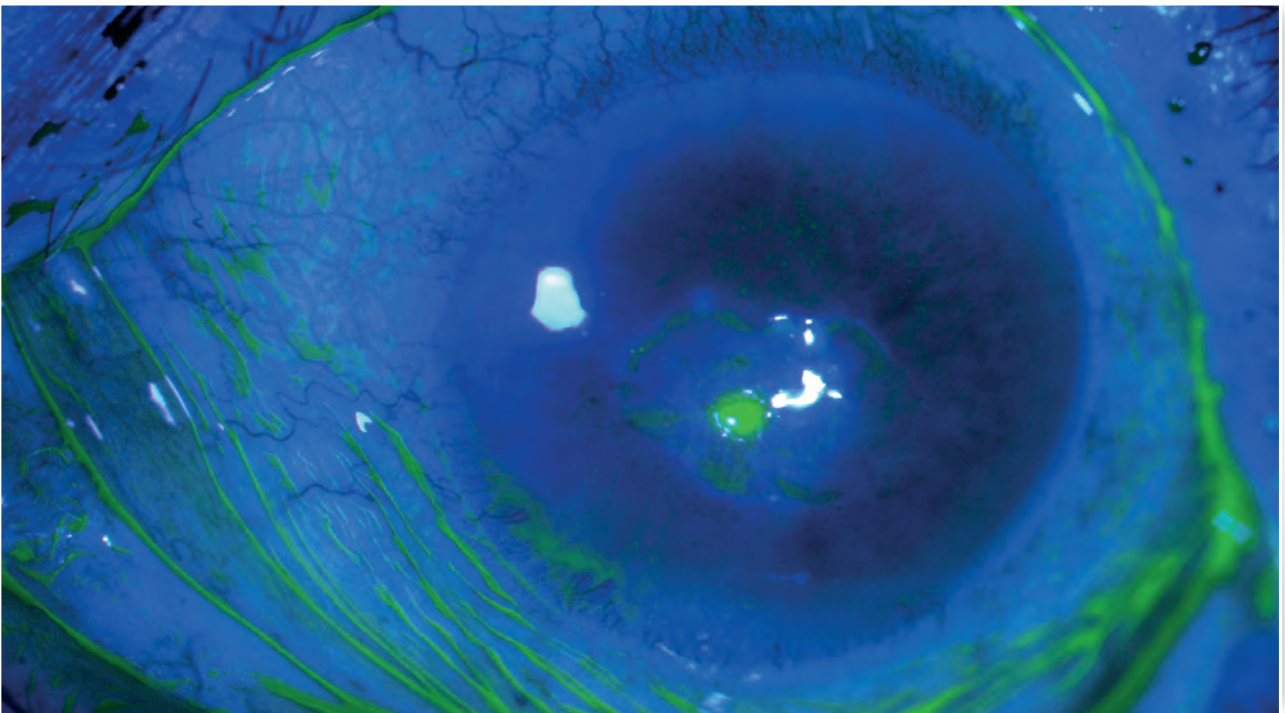
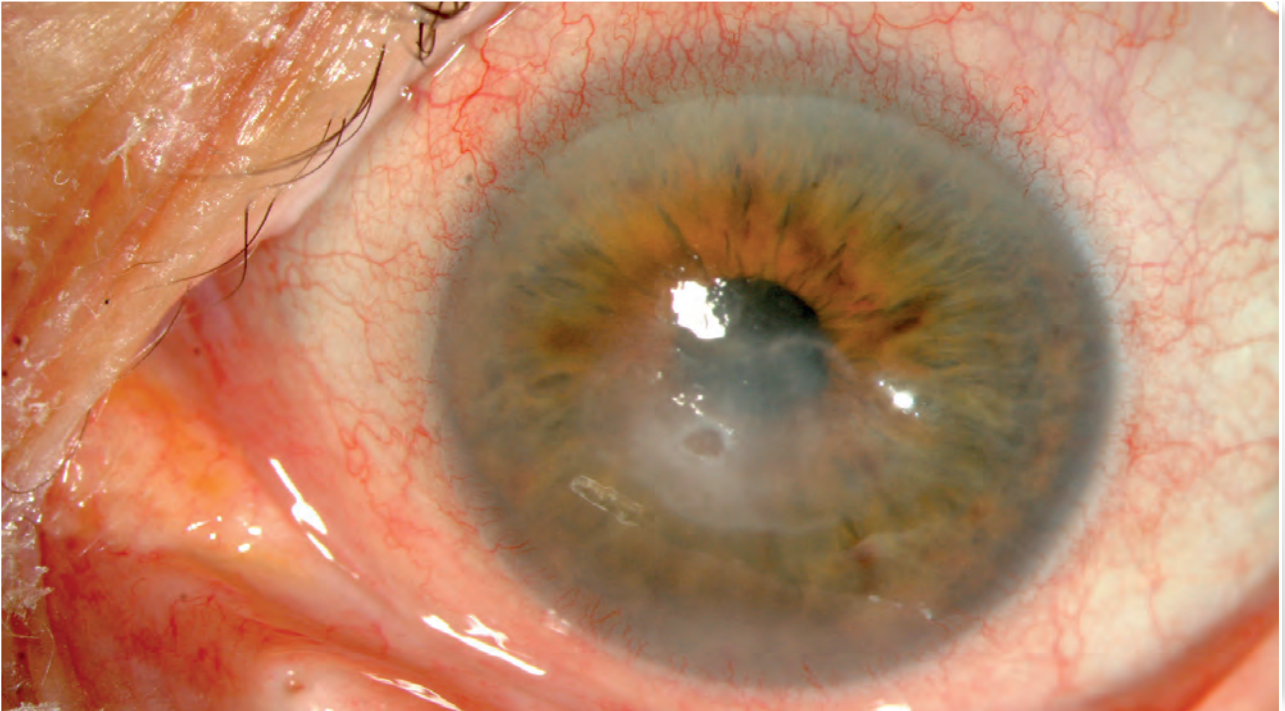
Note the persistent central epithelial defect with rounded edges punched-out appearance, and surrounded by an area of epithelial weakness associated with peripheral neovascularisation.



Post-zoster neurotrophic ulcer.

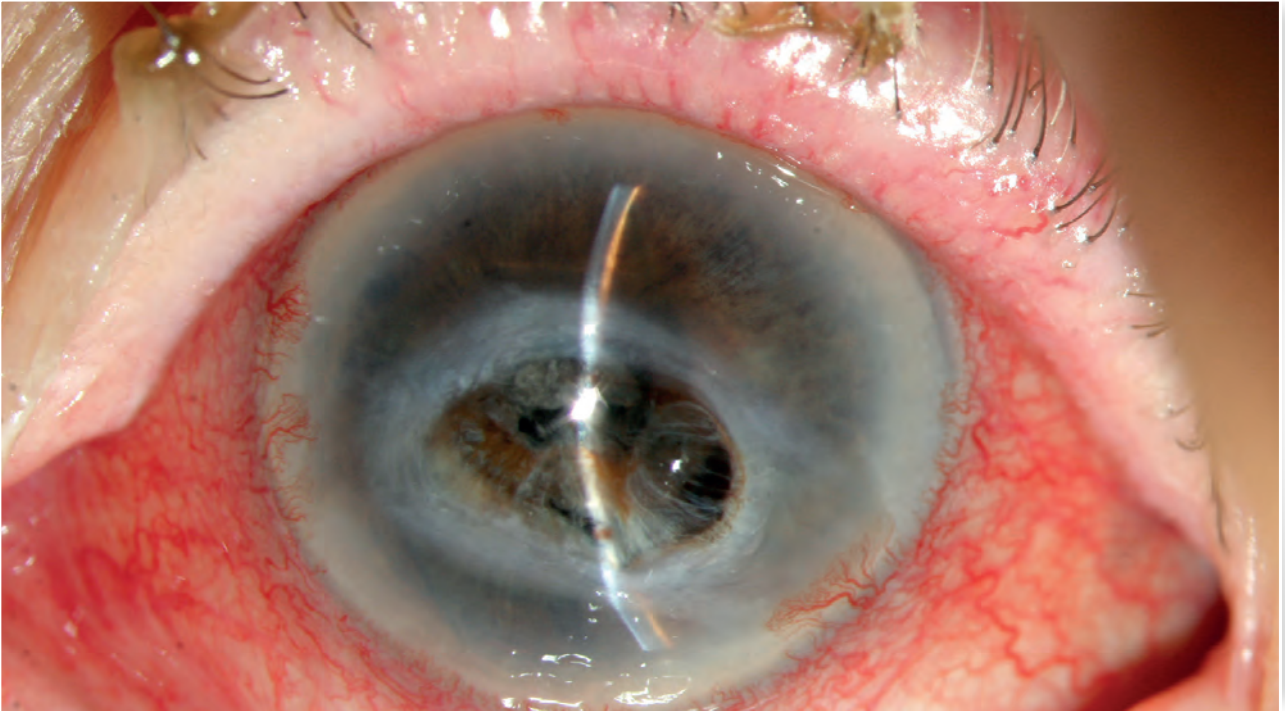
Wide epithelial ulceration and persistent anterior stromal disorder following ophthalmic zoster infection.

NEUROTROPHIC KERATITIS AETIOLOGIES



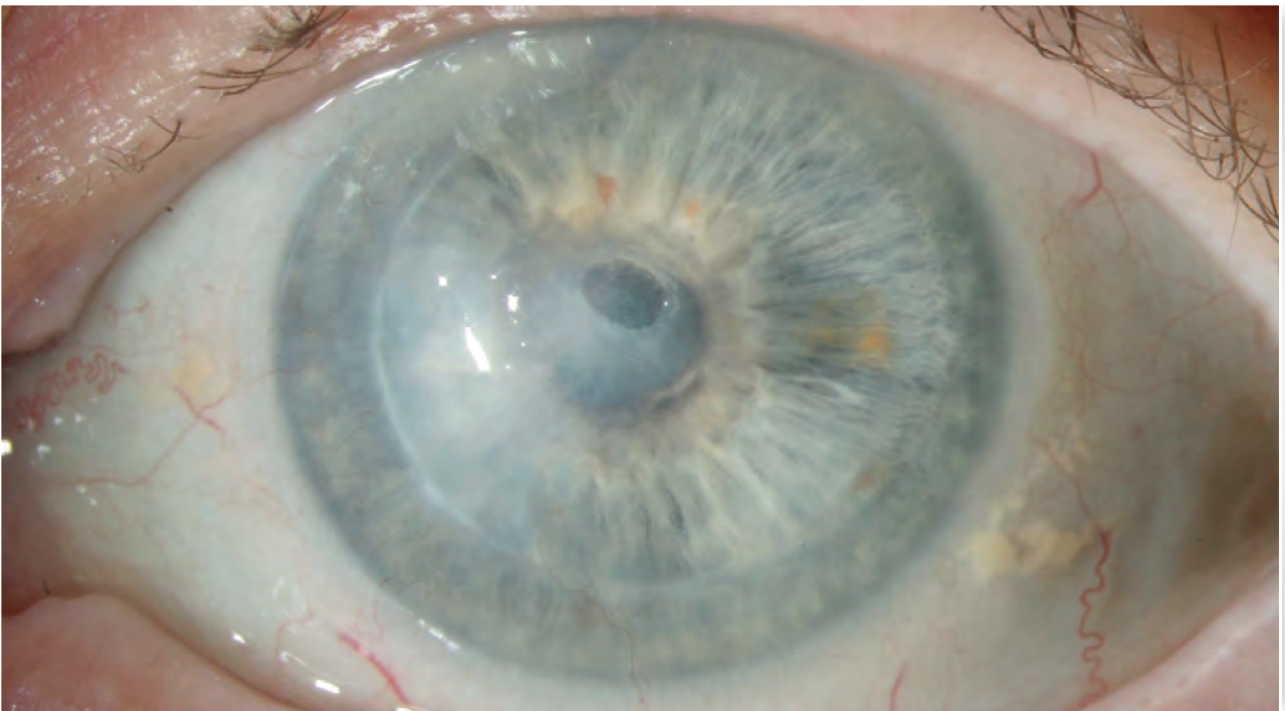Neurotrophic ulcer related to preservatives.

Delayed epithelial healing with punched-out appearance, secondary to intensive use of antibiotic eye drops to treat a bacterial keratitis.



Neurotrophic ulcers and NSAID drops.

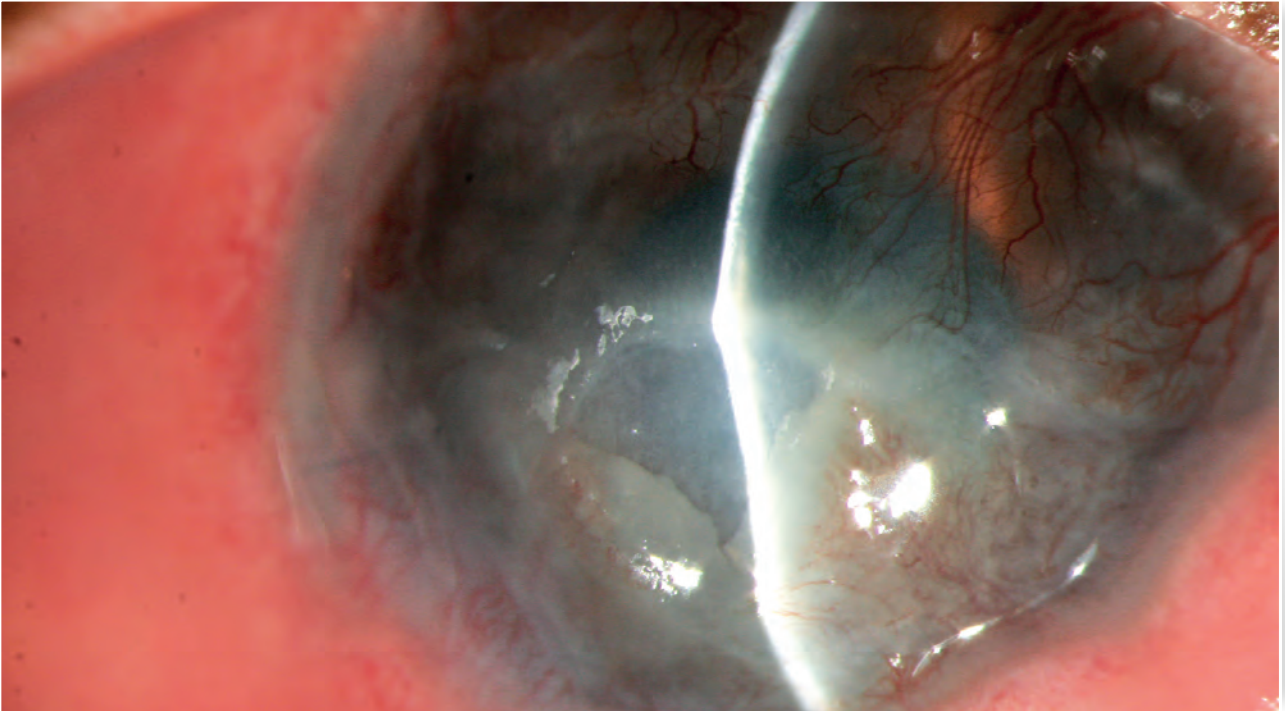
Large perforated central corneal ulcer and corneal anaesthesia. This patient had received non-steroidal anti-inflammatory eye drops one week before and three weeks after a YAG laser capsulotomy. Conjunctival hyperaemia appeared after 21 days of treatment.



Neurotrophic keratitis and keratoplasty.

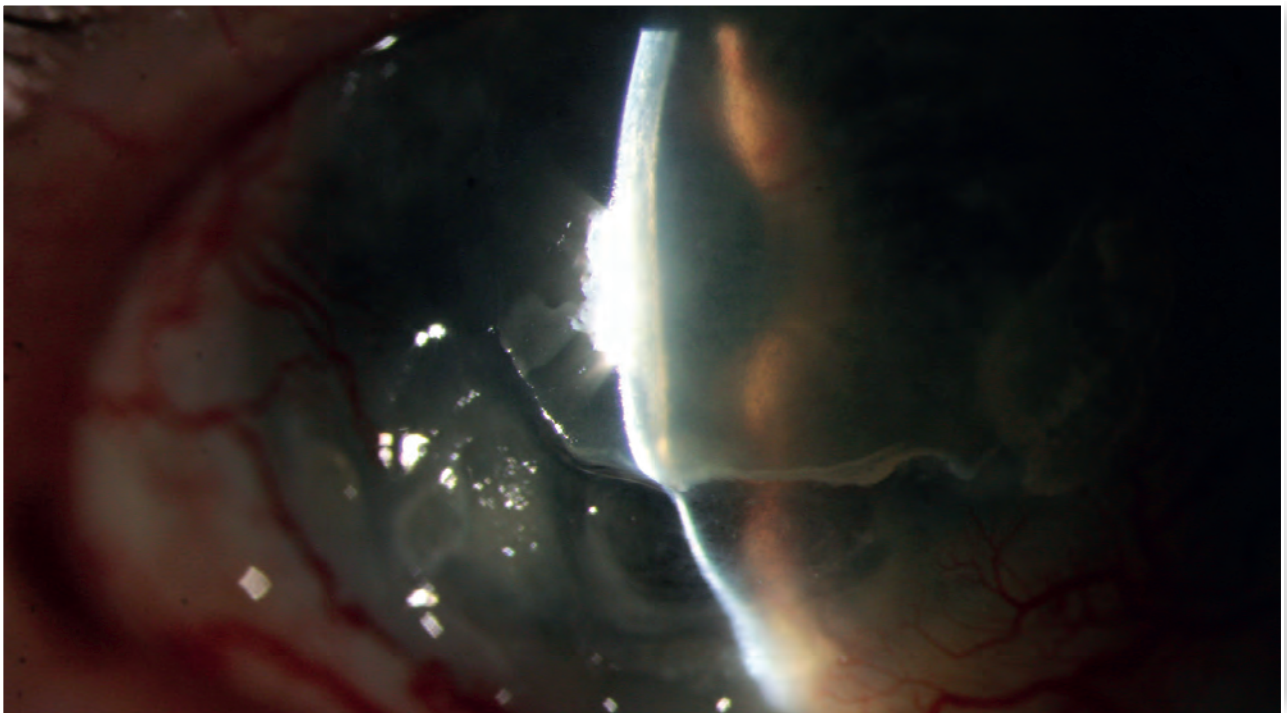
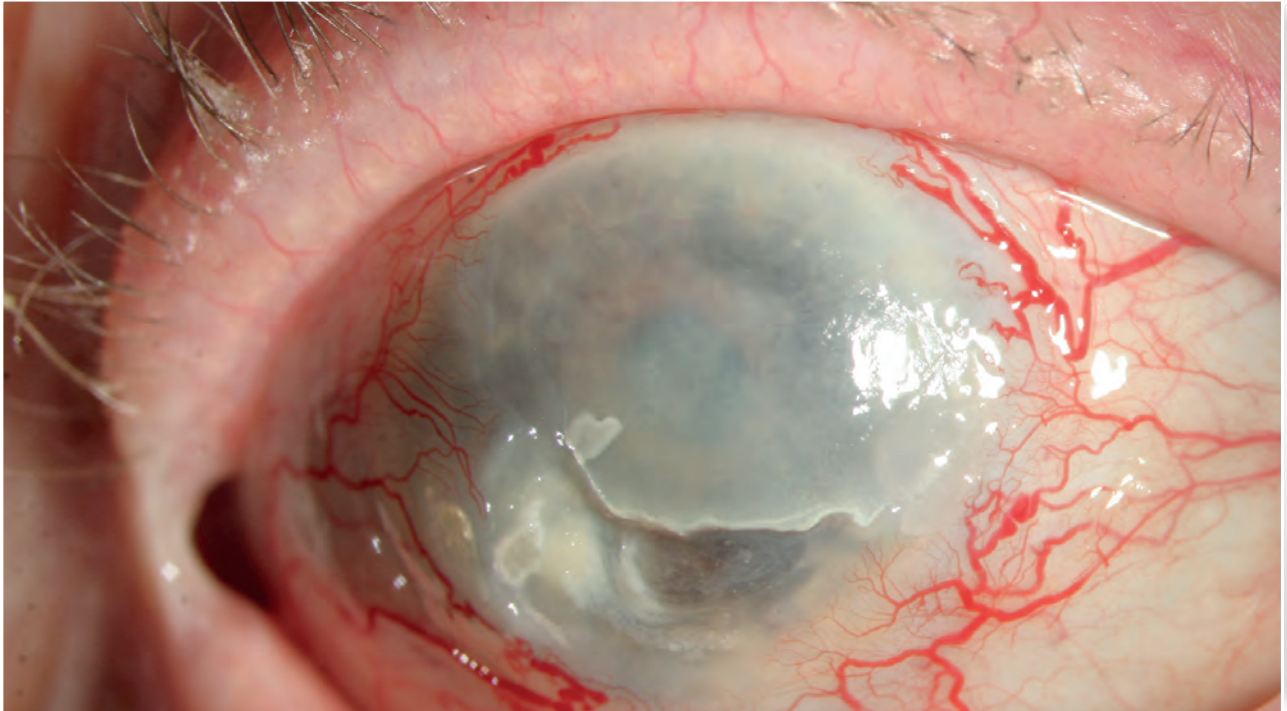
Chronic and painless, corneal ulcer after penetrating keratoplasty.

NEUROTROPHIC KERATITIS AETIOLOGIES



Neurotrophic ulcers and ocular burn.

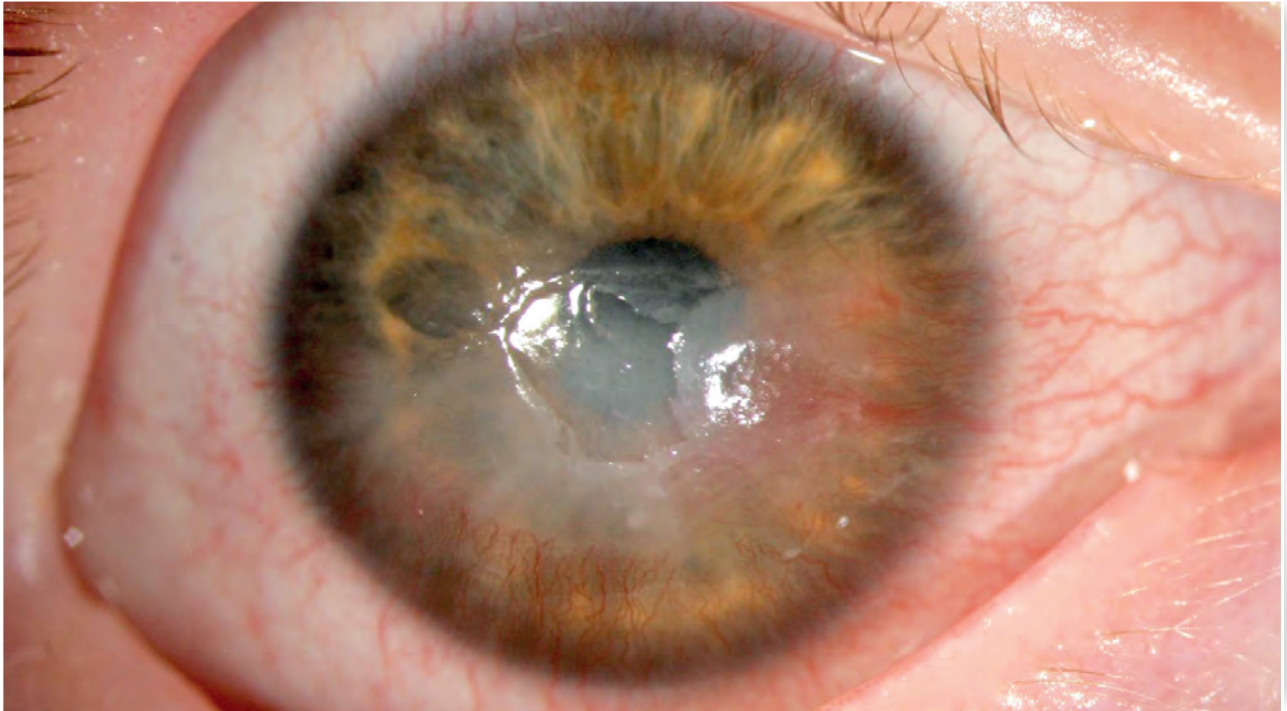Serious sequelae following chemical burn of the ocular surface with persistent central ulceration and neovascularisation over 360° covering the cornea. Note the stromal thinning and the hypertrophic epithelial edges of the ulcer.



Neurotrophic ulcer and proton therapy.

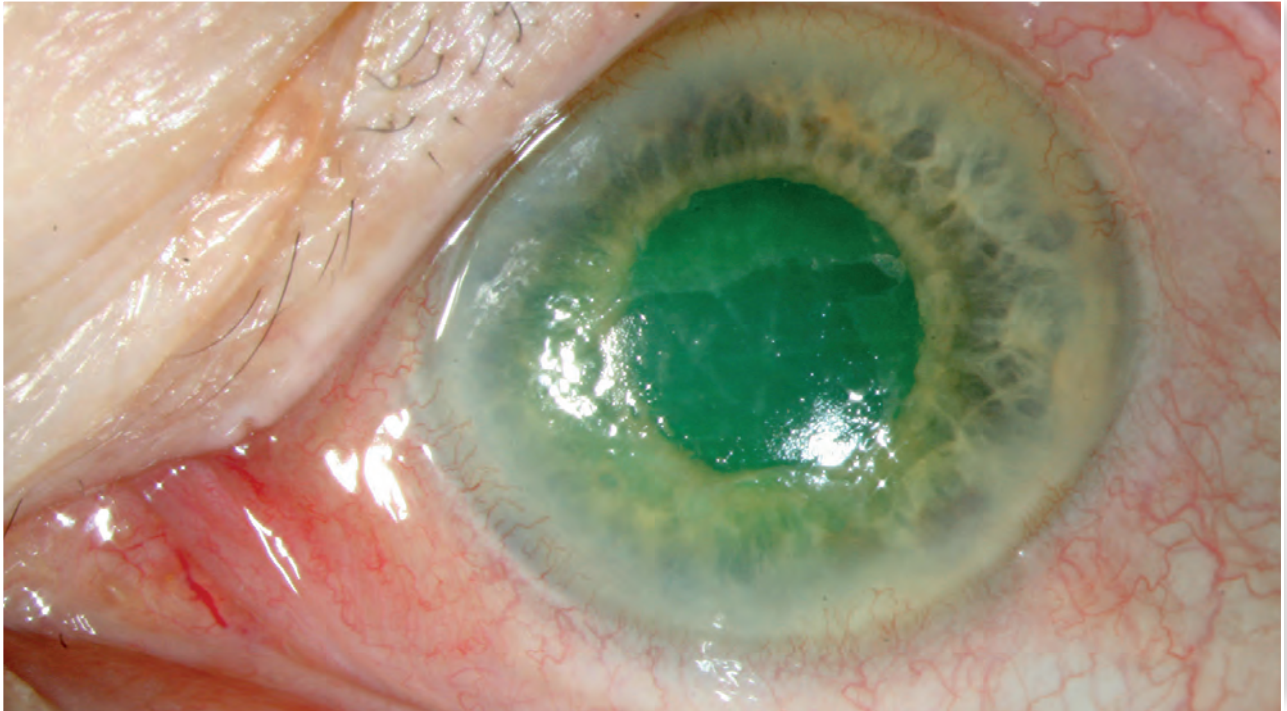
Non-functional right eye due to secondary neovascular glaucoma following a proton therapy for choroidal melanoma. There is a large, persistent, and painless stromal ulcer complicated by major corneal thinning.

NEUROTROPHIC KERATITIS AETIOLOGIES



Neurotrophic ulcer and radiotherapy.

Chronic neurotrophic corneal ulcer secondary to orbital irradiation for rhabdomyosarcoma. Note the peripheral vascularisation.



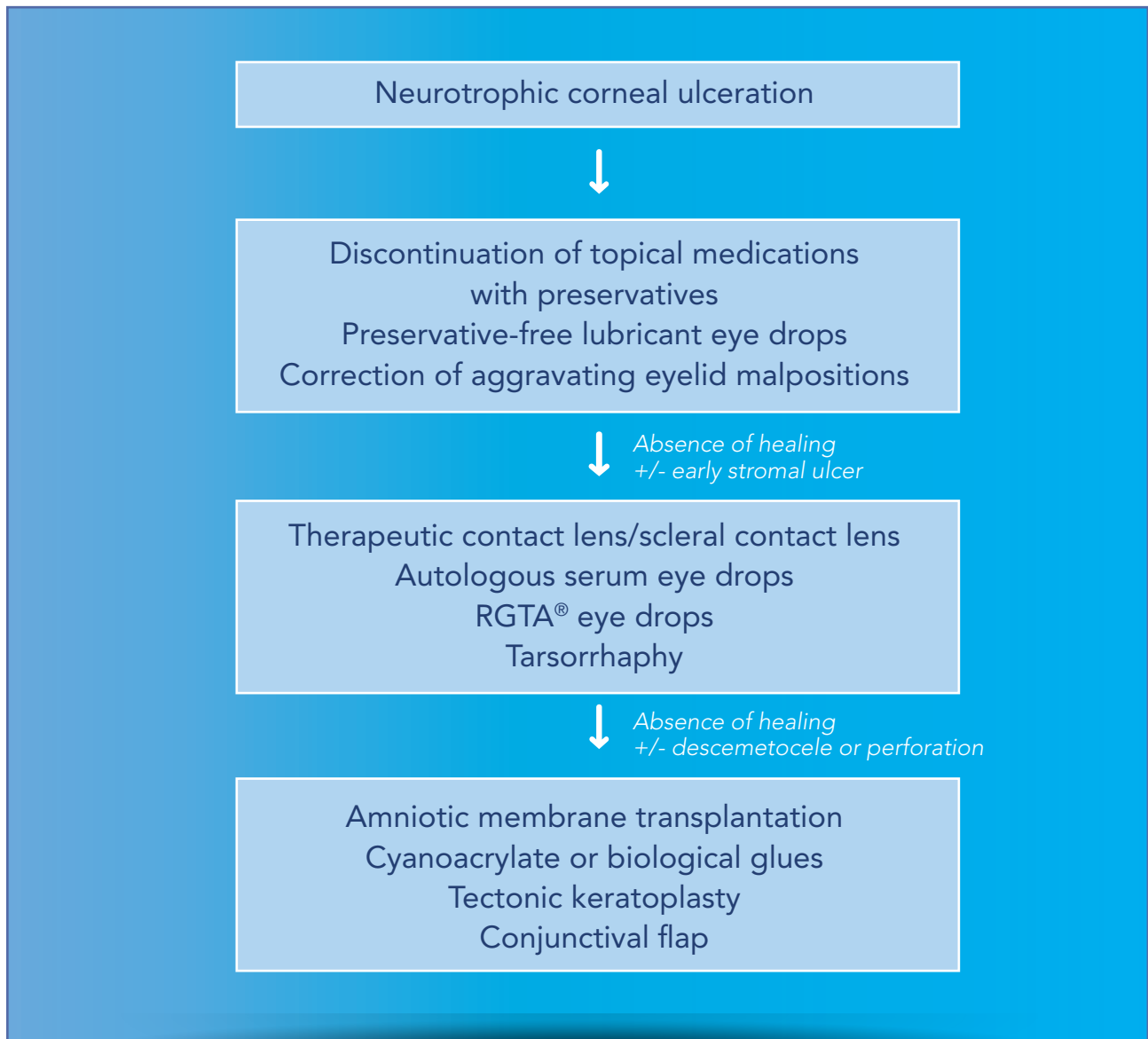
Post-surgical neurotrophic ulcer.

A complaint of blurred vision revealed neurotrophic epithelial ulceration with corneal anaesthesia, consequential to thermo-coagulation of the Gasser's ganglion for trigeminal neuralgia 30 years previously. Note the underlying stromal oedema with significant Descemet's folds.

NEUROTROPHIC KERATITIS TREATMENT

- Treatment of neurotrophic ulcers is often challenging. The first priority is to discontinue any element of toxicity from topical medications on the ocular surface.
- Medical and surgical treatments aim to improve epithelial healing, to avoid stromal lysis and to prevent potential complications. Data from experimental and pilot clinical studies suggest that some growth factors or some molecules from the microenvironment, can improve the prognosis.
- Up to now, there are no specific treatments for neurotrophic keratitis. In all cases, preservative-free lubricant eye drops are prescribed as first-line treatment, often with the addition of antiseptic eye drops preservative-free, rather than antibiotic eye drops.
- Whilst there is no definite management strategy for treating a neurotrophic corneal ulcer, a therapeutic stepladder algorithm is proposed in the figure on the next page.

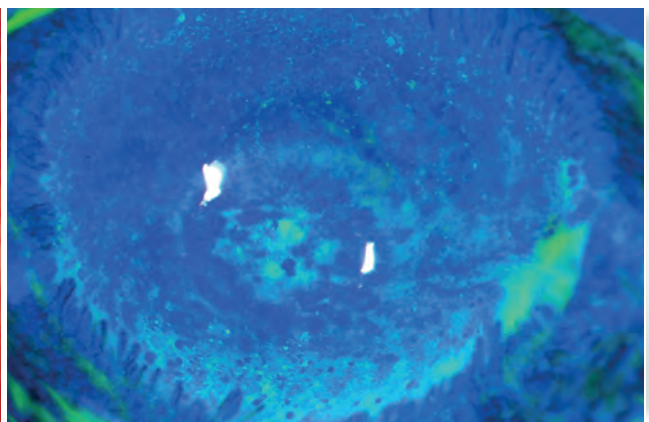
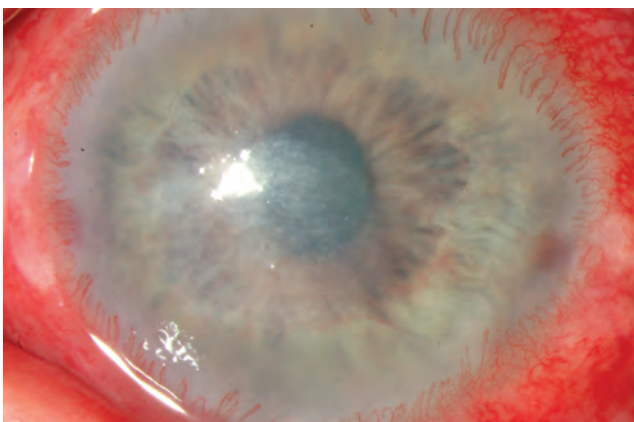
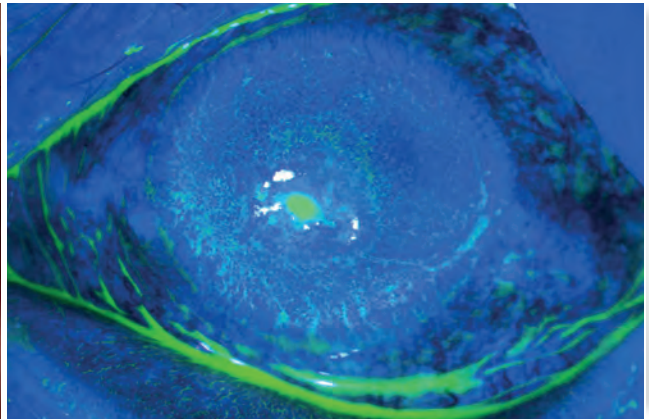
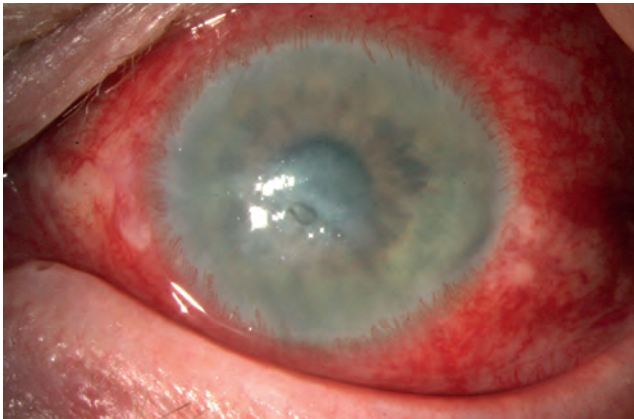
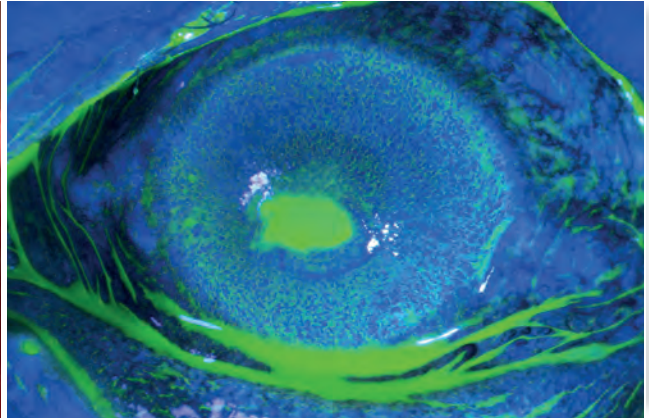
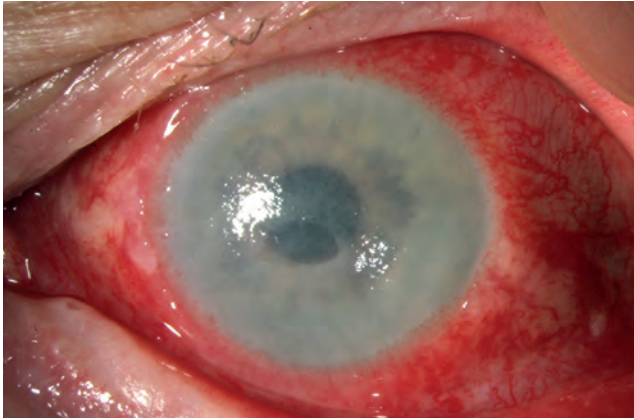
Therapeutic stepladder algorithm for neurotrophic ulcers.



NEUROTROPHIC KERATITIS TREATMENT

- The priority is the discontinuation of any toxic topical medications being applied to the ocular surface. The toxicity of treatments may be related to the active molecule itself or to associated preservatives. Some molecules are well known for their potential toxicity such as nonsteroidal anti-inflammatory, antivirals, some antibiotics or anaesthetics eye drops.

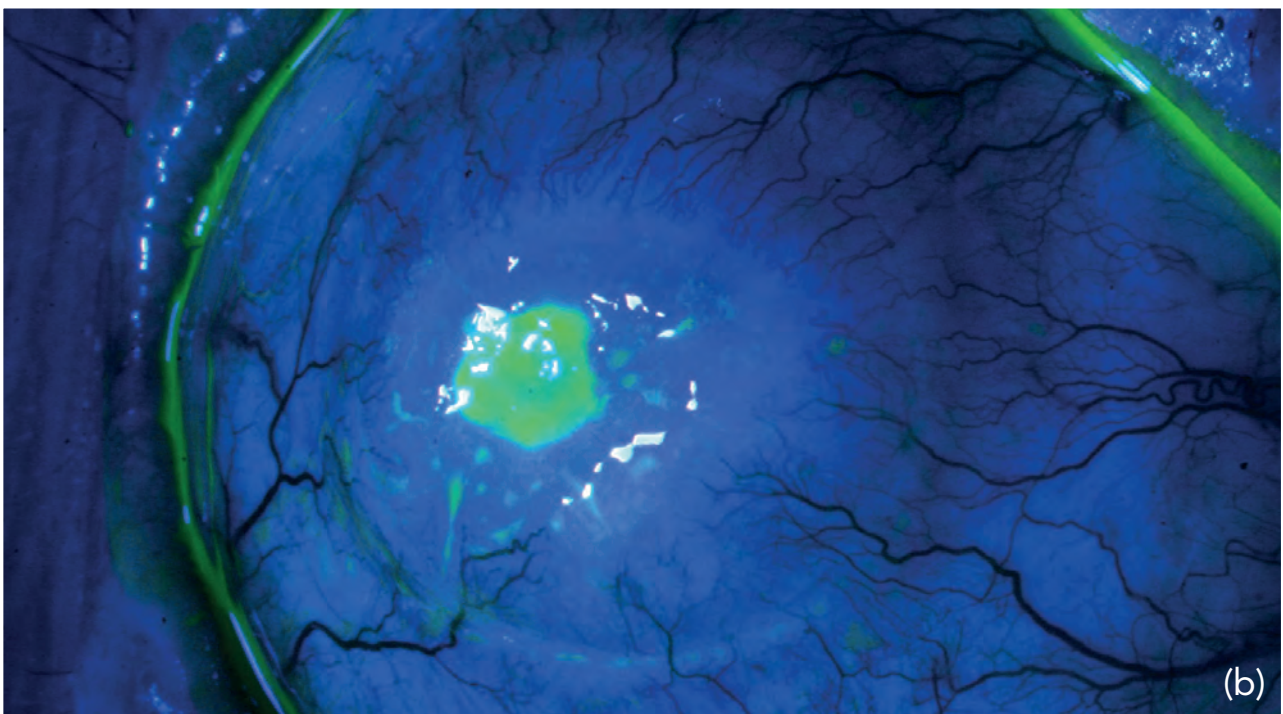
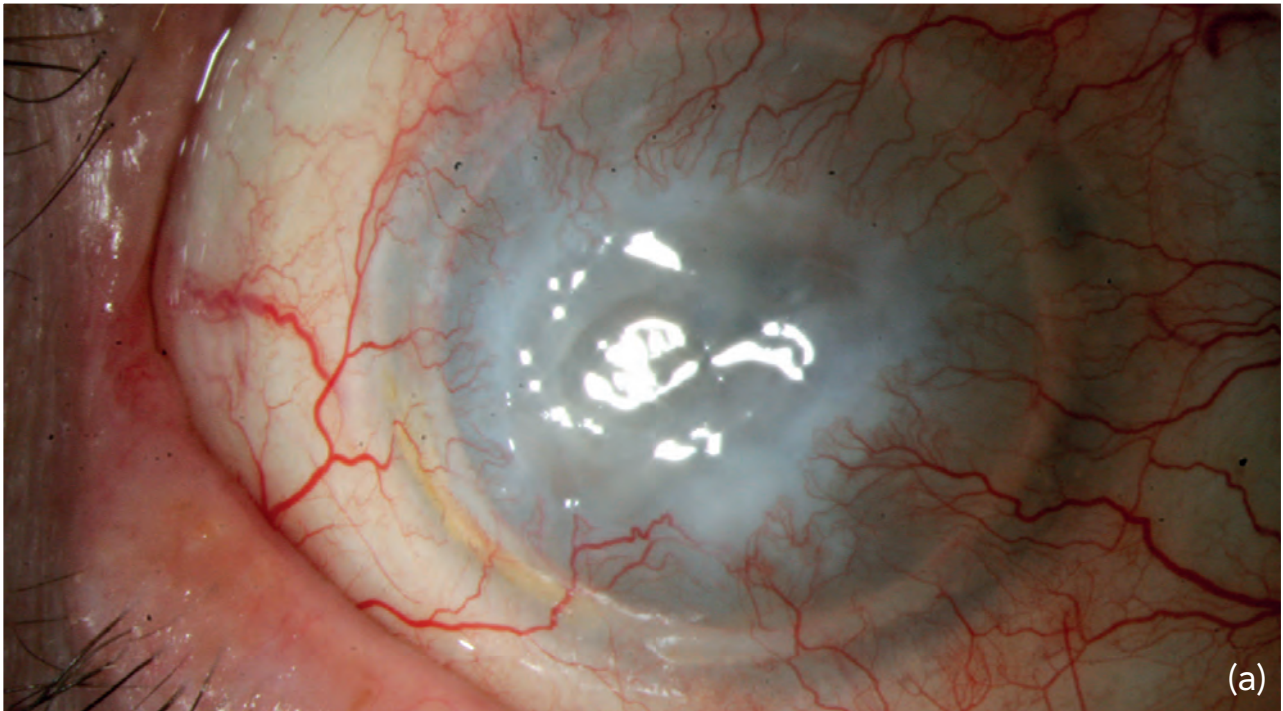
**Look for an aggravating toxicity
of topical medications**



Importance of the wash out period.

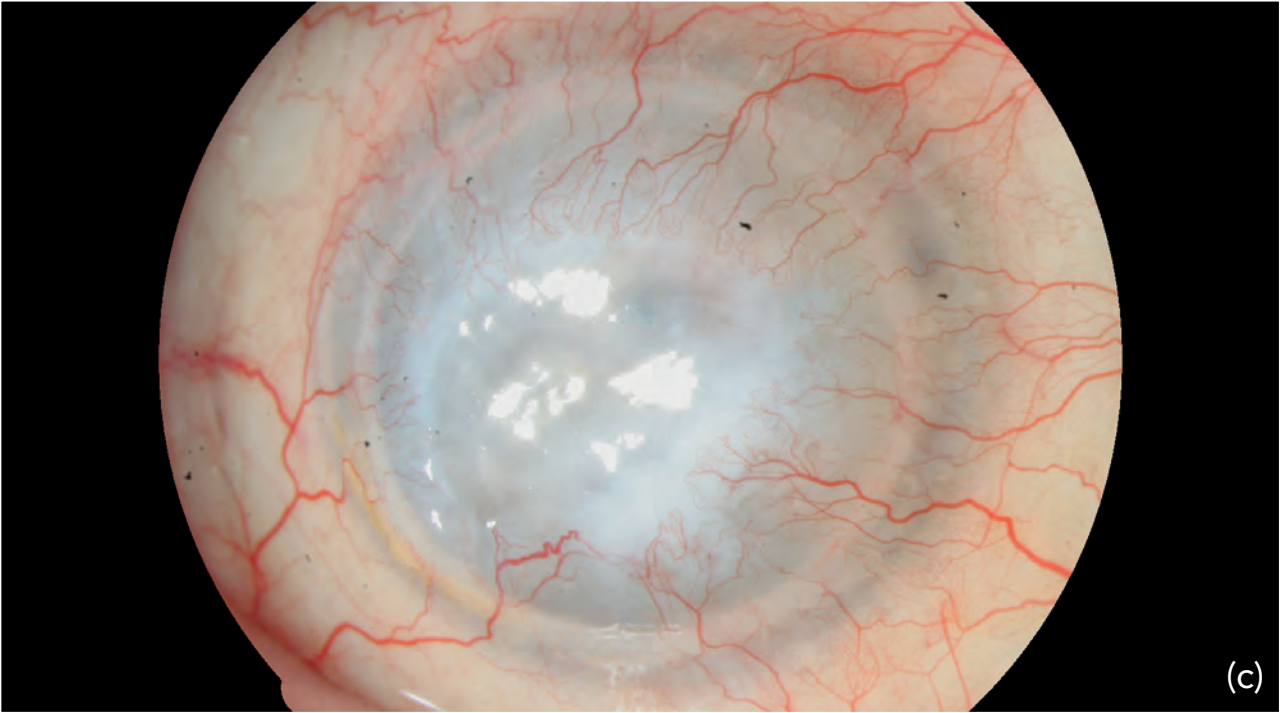
Persistent corneal ulceration for several months following herpes zoster ophthalmicus treated with antiviral eye drops. Initial appearance at the top, at day 10 in the center, complete healing obtained less than 21 days after discontinuation of toxic topical medications at the bottom.

NEUROTROPHIC KERATITIS TREATMENT

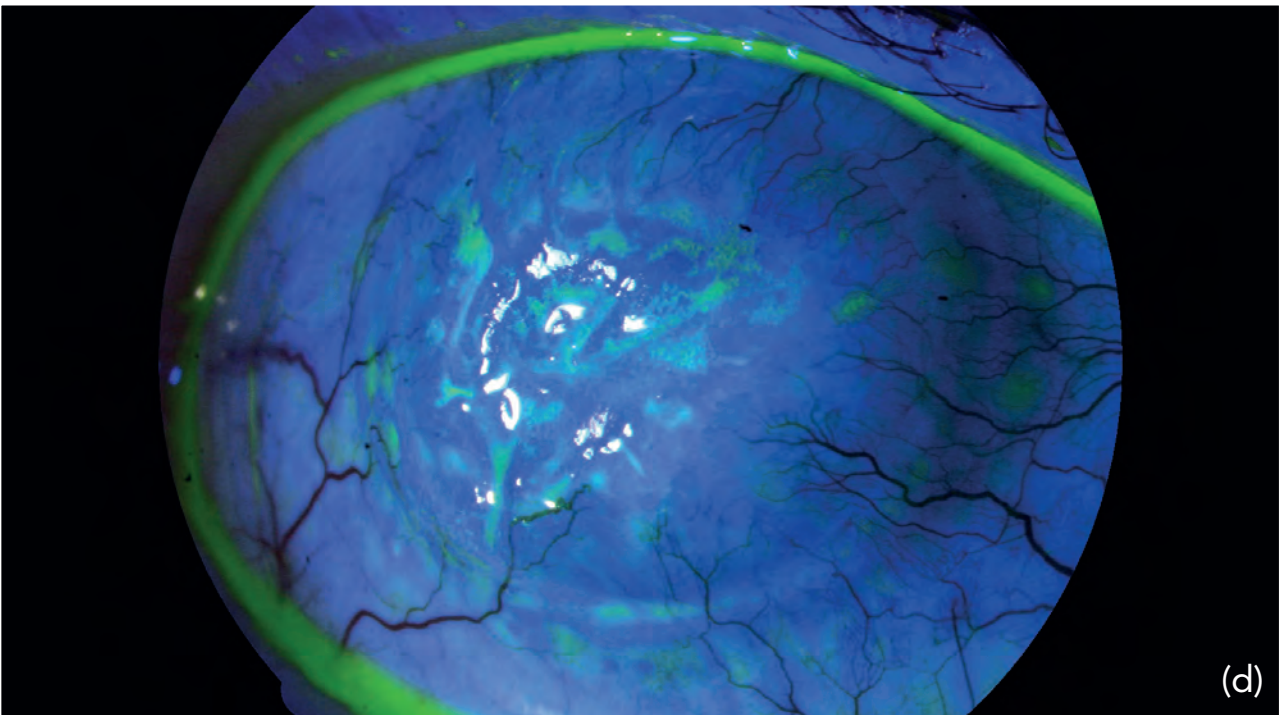


Importance of the wash out period.

Persistent corneal ulceration following an infectious keratitis occurring after multiple penetrating keratoplasties performed initially for herpes infection related corneal scar. Discontinuation of all topical medications other than preservative free lubricant eyedrops allowed epithelial healing. Initial appearance (a and b), and complete healing at day 15 (c and d).



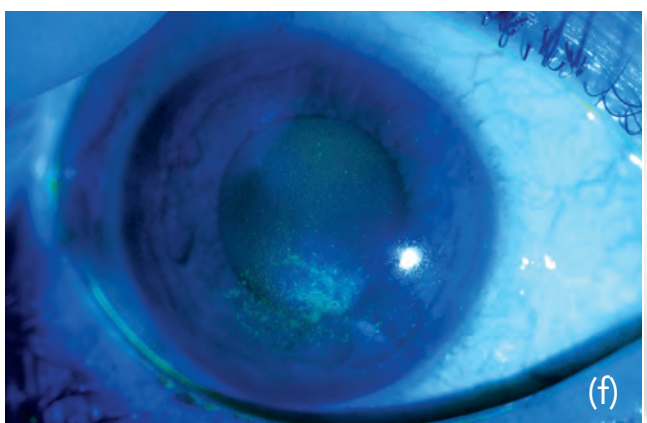
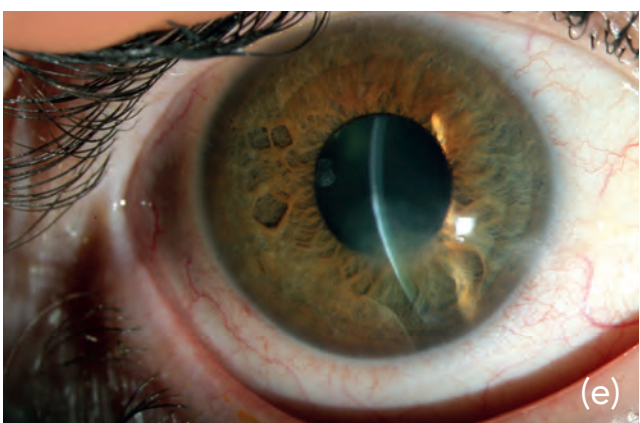
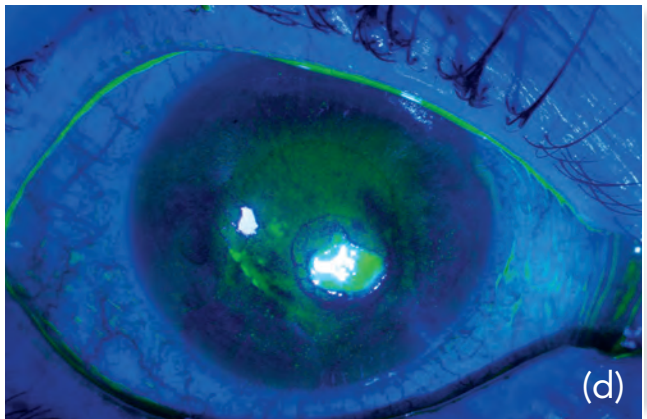
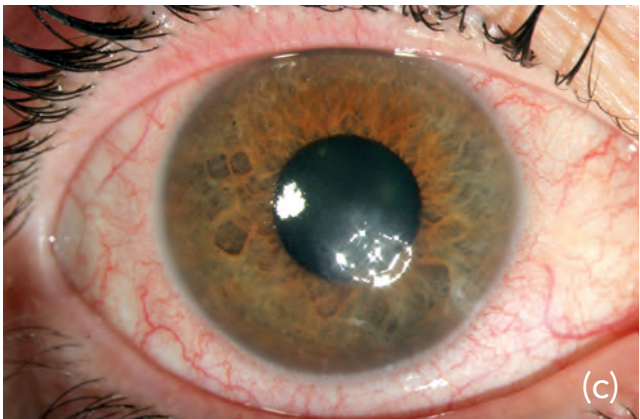
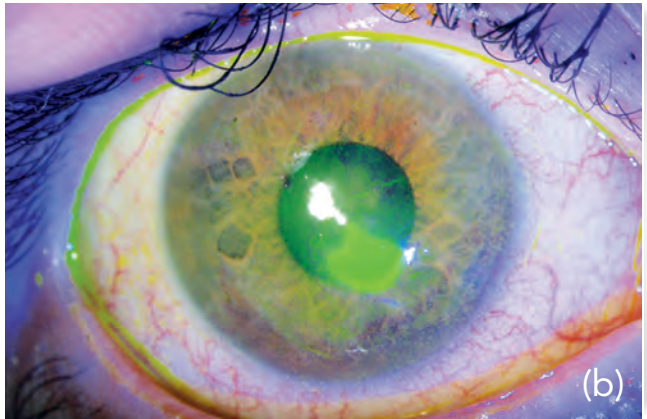
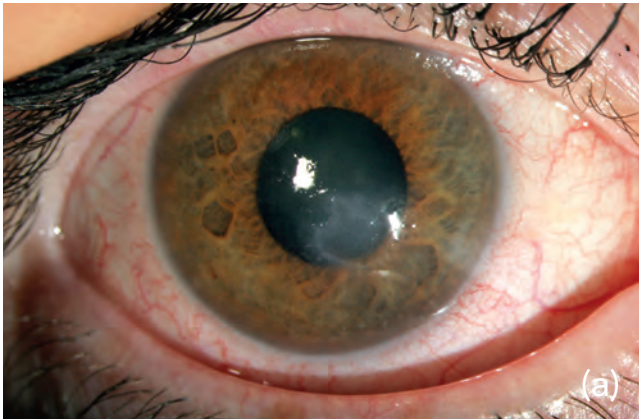
(c)



(d)

NEUROTROPHIC KERATITIS TREATMENT

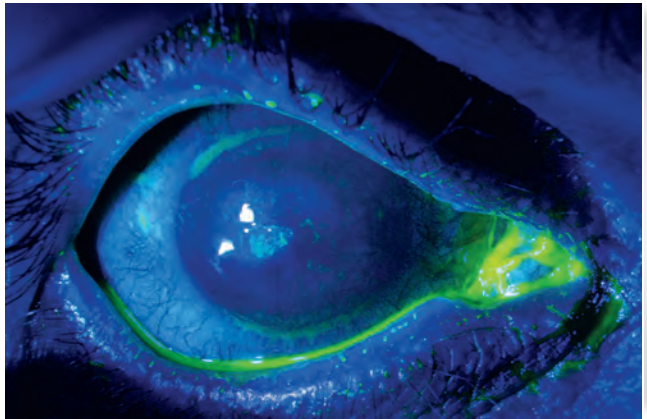
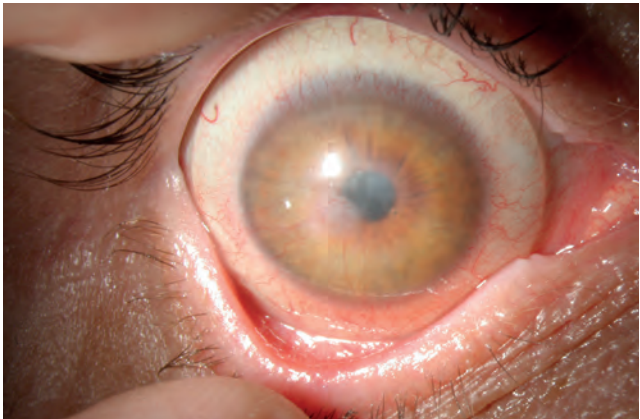
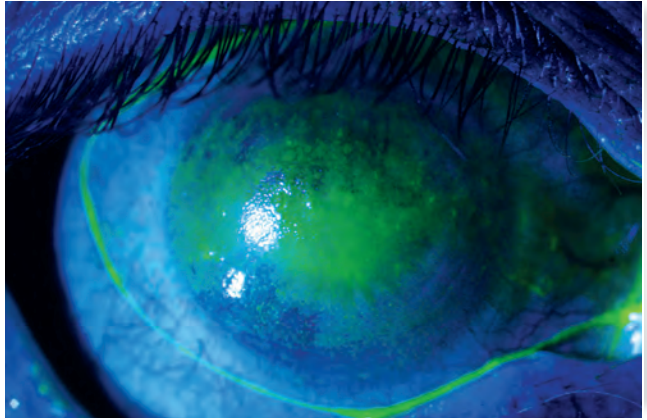
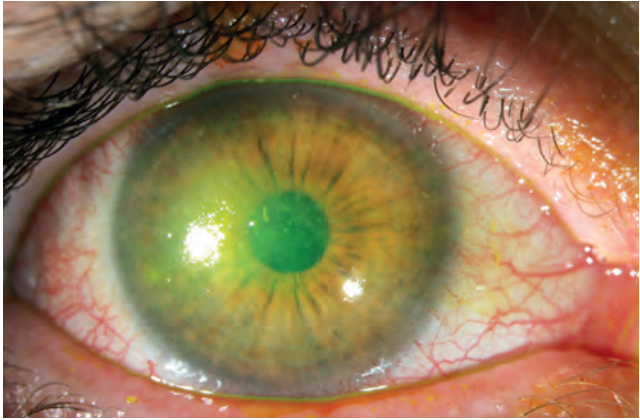
- Based on clinical response, a **therapeutic soft contact lens**, usually worn on a continuous wear basis may be proposed.
- In this indication, **scleral permeable to oxygen contact lens** fitting, may be helpful. These are large-diameter lenses that only rest on the sclera, remaining clear of the limbus and cornea, permeable to oxygen. In addition to its refractive advantage, it also offers a mechanical protection against irritation by the eyelashes and eyelids while maintaining a permanent fluid reservoir in front of the cornea. The advantage of scleral lenses in this indication therefore, compared to soft contact lenses, is the lack of transmission of frictional forces from the eyelids during blinking.
- **Tarsorrhaphy**, despite its unaesthetic appearance, can be useful in the treatment of neurotrophic ulcers. It can be used in cases of eyelid malpositions, associated with tectonic keratoplasty for large perforations, or for refractory situations. Indeed, epithelial healing can often be achieved using tarsorrhaphy, even in the absence of lagophthalmos. **Botulinum toxin injections** in the upper lid to induce ptosis can be used instead of tarsorrhaphy.



Neurotrophic ulcer and therapeutic soft contact lens.

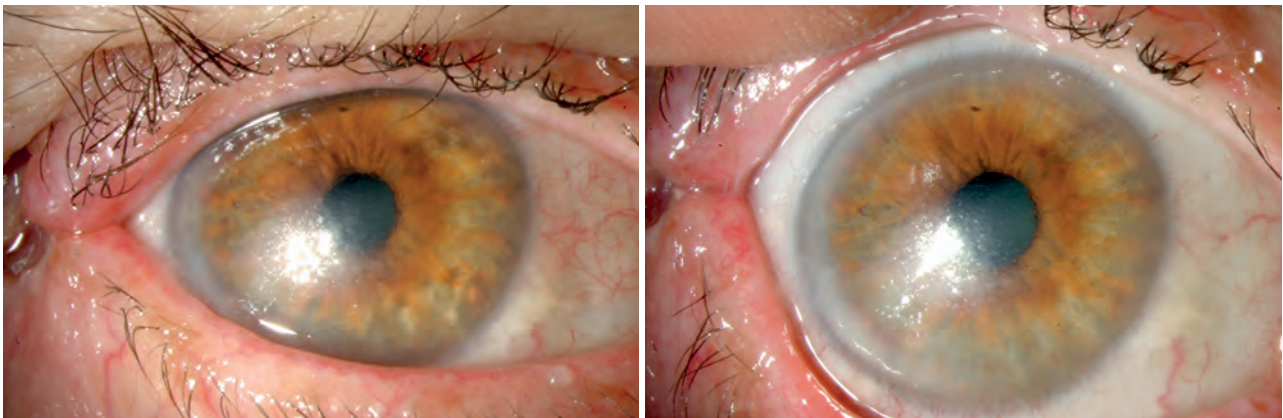
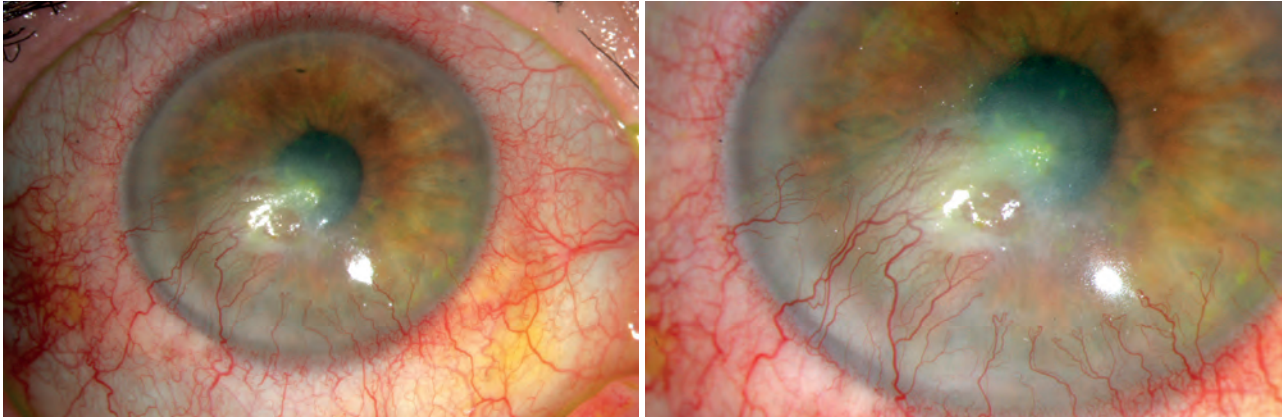
Recurrent corneal herpetic infection complicated by neurotrophic keratopathy. The therapeutic contact lens fitting allowed epithelial healing in 15 days. Initial appearance (a, b), at day 8 (c, d), and complete healing at day 15 (e, f).

NEUROTROPHIC KERATITIS TREATMENT



Neurotrophic ulcer and scleral contact lenses.

Traumatic injury to the fifth cranial nerve following a fracture of the petrous portion of the temporal bone, complicated by neurotrophic keratitis. Due to the fragility of the ocular surface and corneal hypoesthesia, this patient was fitted with a scleral contact lens, both for protection and to allow improved stability of the corneal epithelium.



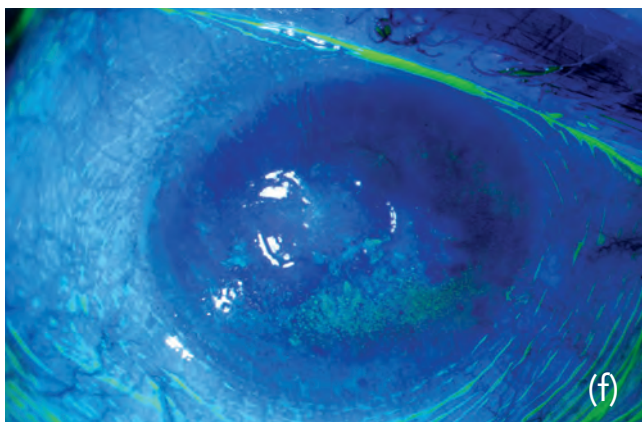
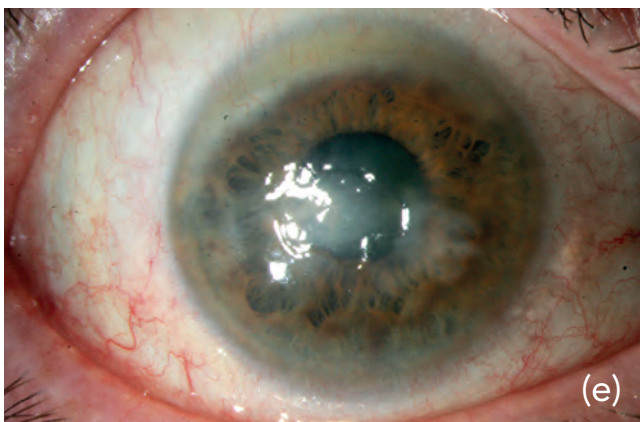
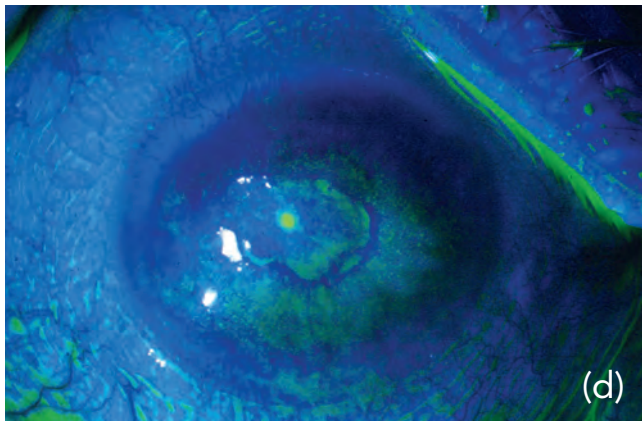
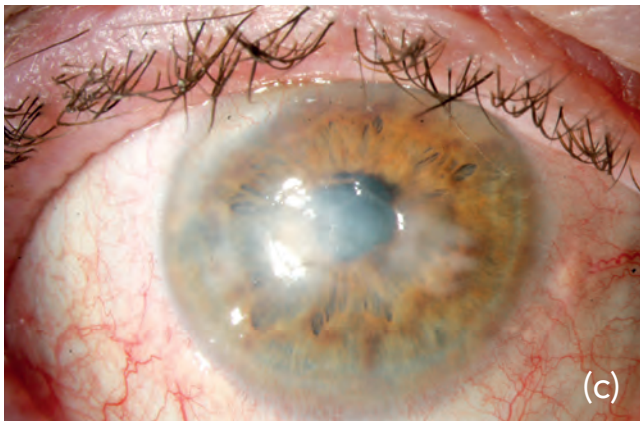
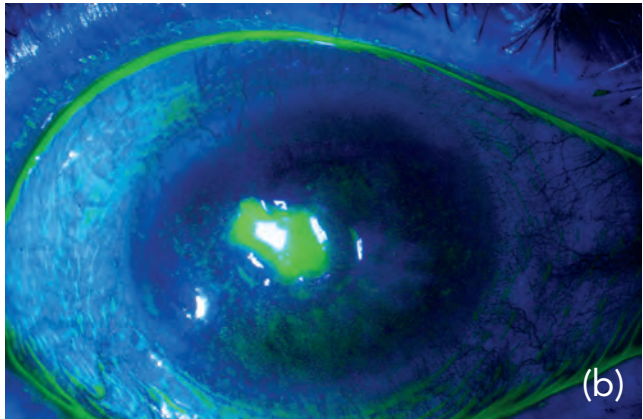
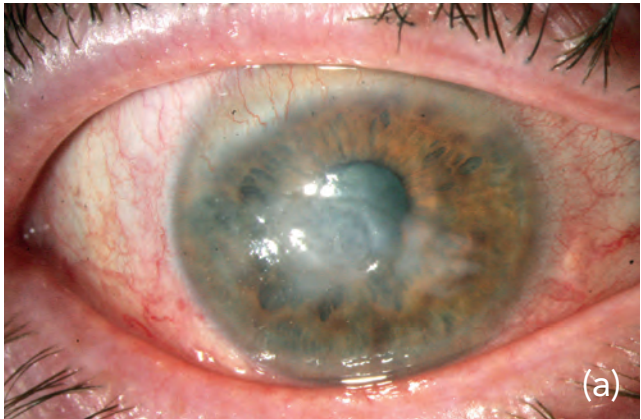
Neurotrophic keratitis and tarsorrhaphy.

Corneal anaesthesia aggravated by lagophthalmos related to concomitant facial paralysis, following an intra-parenchymal haematoma of the brainstem. Despite supportive eye care, the neovascularisation progressed. The tarsorrhaphy allowed stabilisation of the corneal epithelium and stopped growth of corneal neovascularisation.

NEUROTROPHIC KERATITIS TREATMENT

- Another approach to improve the cellular microenvironment to promote healing is «matrix therapy» which is currently under clinical evaluation. Cacicol® (RGTA eye drops, medical device, Laboratoires Théa, France), may be effective in the treatment of neurotrophic ulceration, through the replacement of the heparan sulphates of the degraded extracellular matrix. It would thereby restore the cellular microenvironment and promote growth factors in the injured epithelium⁴.
- Autologous serum eye drops, rich in growth factors and protease inhibitors, seem to be effective in the management of neurotrophic keratitis. However, restrictive regulations and facilities for preparation limit its availability.
- Other eye drops containing growth factors, such as nerve growth factor, are still under evaluation with promising early results in the management of neurotrophic ulcers and might be available in the future.

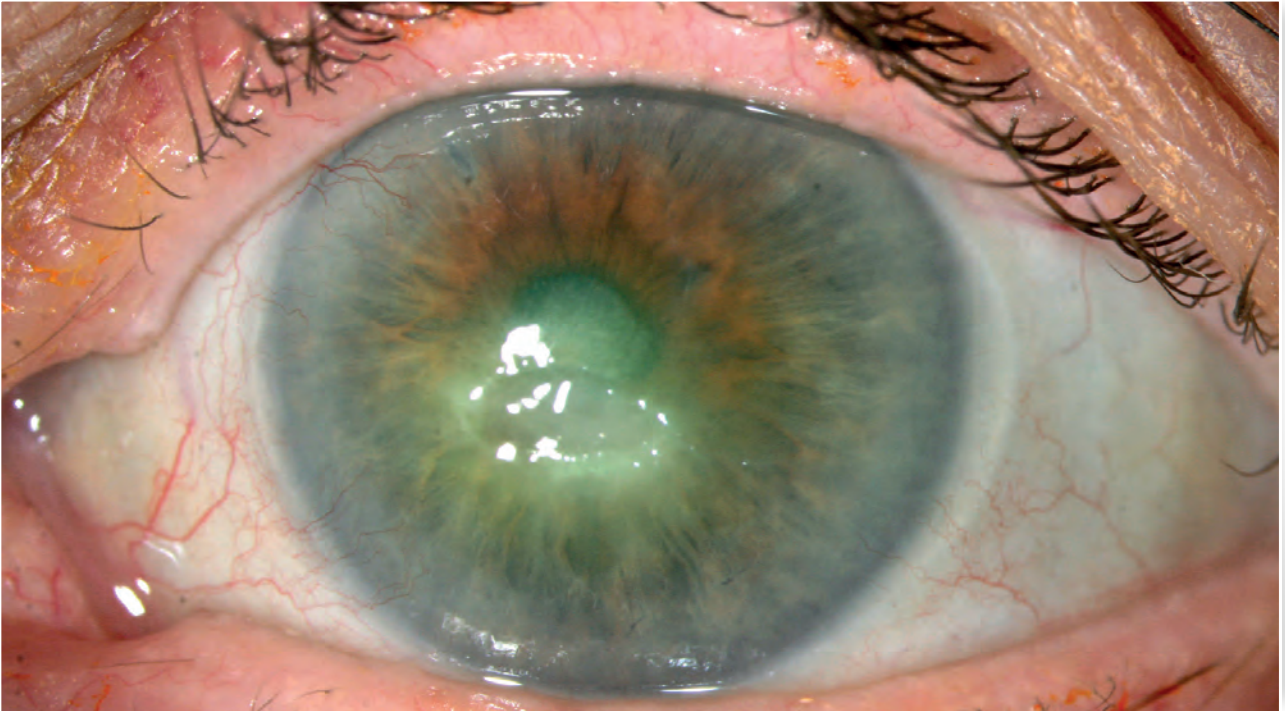
4. Aifa A, Gueudry J, Portmann A, Delcampe A, Muraine M. Topical treatment with a new matrix therapy agent (RGTA) for the treatment of corneal neurotrophic ulcers. Invest Ophthalmol Vis Sci. 2012;53:8181-5.



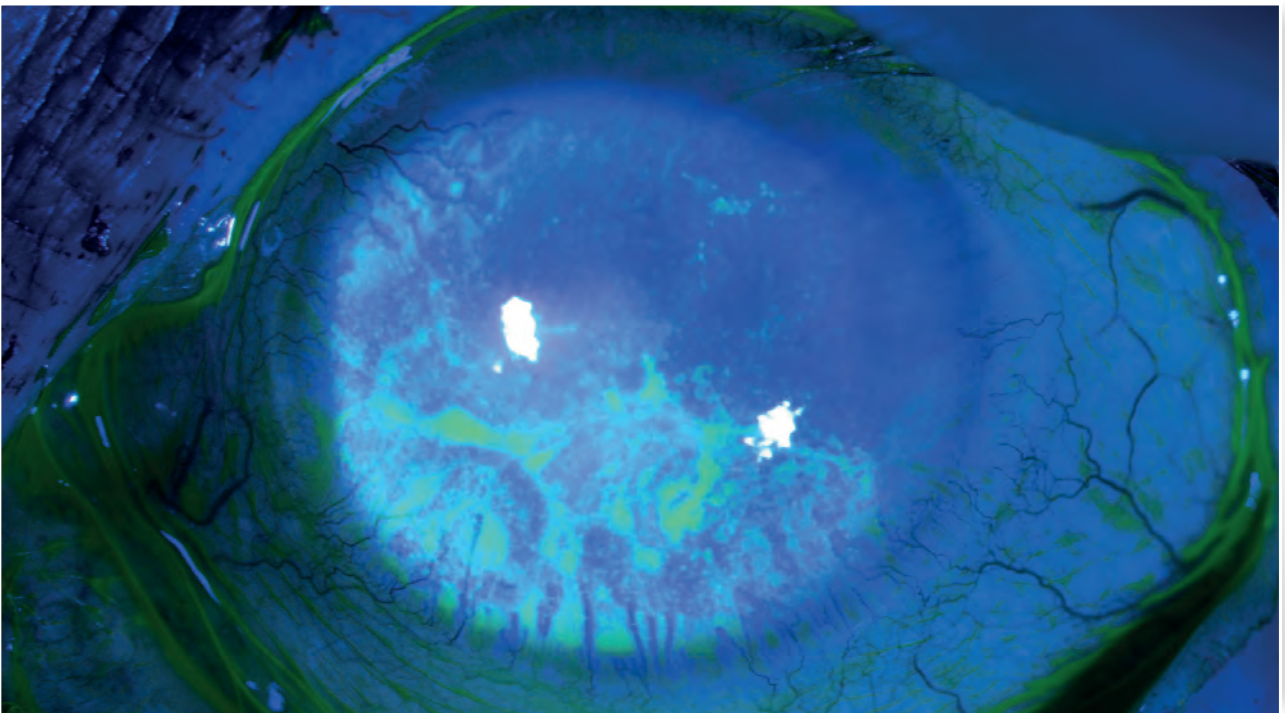
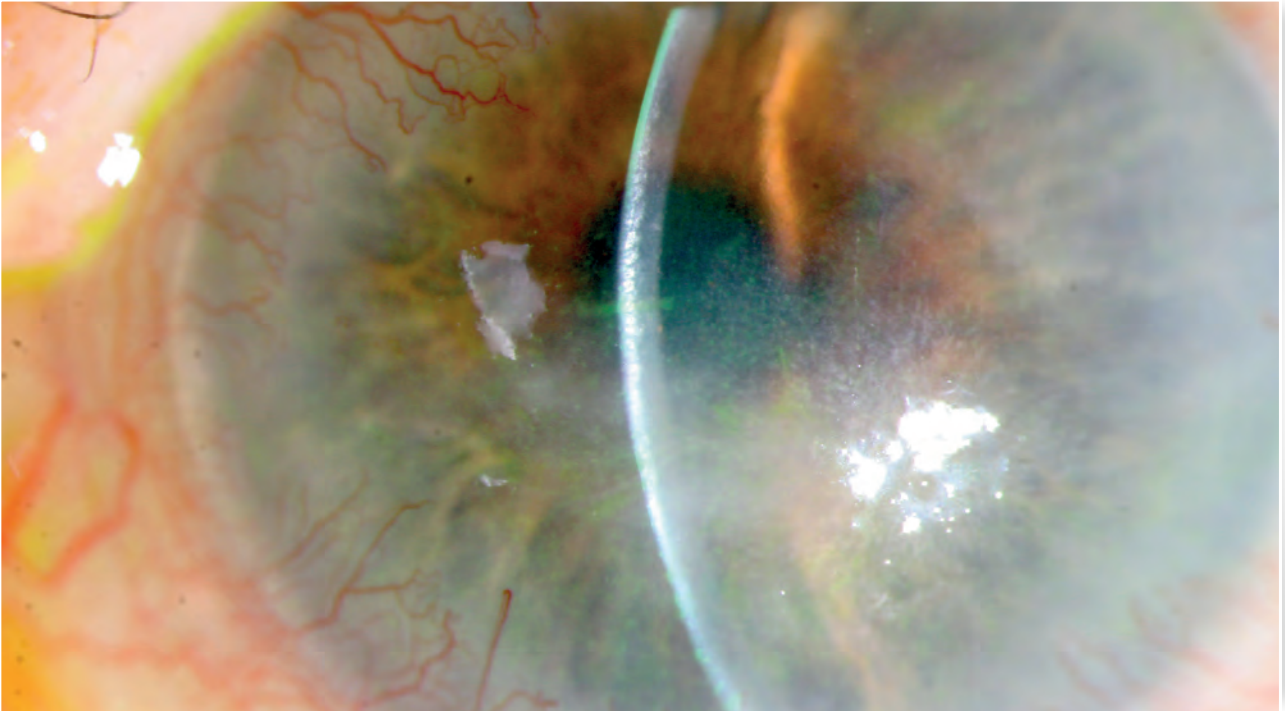
Neurotrophic ulcer and matrix therapy.

Recurrent neurotrophic corneal ulcer following a stroke. Despite discontinuation of potentially toxic topical medications, and the introduction of preservative-free lubricant eye drops, healing could not be obtained after 1 month. Epithelial healing was finally achieved one month after instillation of RGTA® eye drops (Cacicol®, medical device, Laboratoires Théa, France). Initial appearance (a,b), at day 15 (c, d), and complete healing at day 30 (e,f).

NEUROTROPHIC KERATITIS TREATMENT



Neurotrophic ulcer after herpes keratitis before matrix therapy.



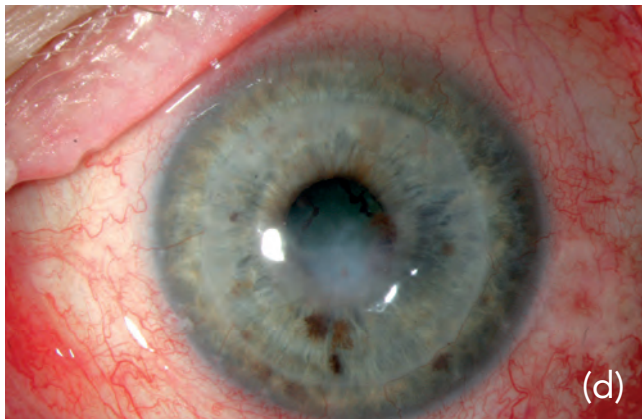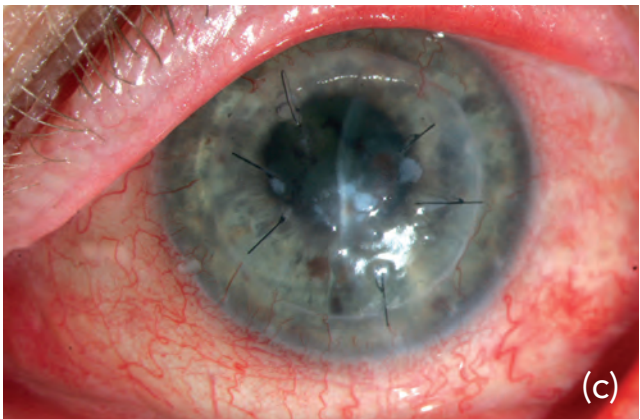

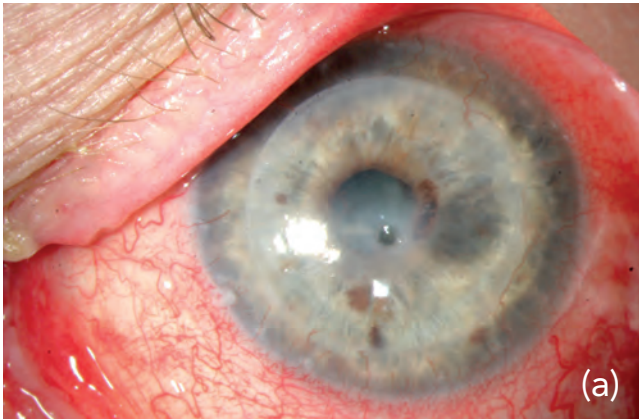
Neurotrophic ulcer following herpes keratitis and matrix therapy.

Despite the discontinuation of potentially toxic eye drops, and the introduction of preservative-free lubricant eye drops, healing did not occur (figure on the previous page). Epithelial healing was finally achieved following use of RGTA[®] matrix therapy (Cacicol[®], medical device, Laboratoires Théa, France) for 1 month (one drop every other day). Note the opaque anterior stromal scarring.

NEUROTROPHIC KERATITIS TREATMENT

- When an eye is initially seen at the stage of stromal ulceration, preserving the structural integrity is the priority. Monolayer or multi layered amniotic membrane transplantation may be required in persistent, perforated or pre-perforated corneal ulcers. Amniotic membrane is often sutured, but it can also be fixed with biological fibrin glue. Amniotic membrane has anti-inflammatory and pro-healing properties, and also provides physical support which facilitates the migration of cells from the edges of the ulcer.
- Cyanoacrylate glue, or biological fibrin glue, are sometimes used for very small perforations, or while waiting for amniotic membrane transplantation in cases of corneal perforation⁵.
- Tectonic lamellar or penetrating keratoplasty are used as a last resort in perforations of large diameter, often combined with tarsorrhaphy or conjunctival flap.
- When previous treatment strategies fail, a partial or total conjunctival flap may sometimes be necessary to preserve the structural integrity of the globe.

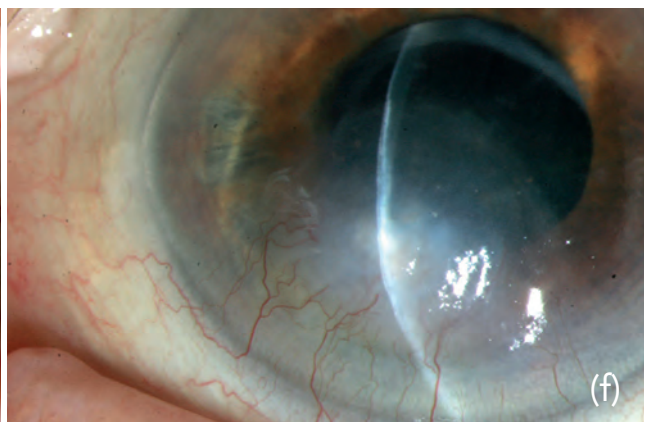
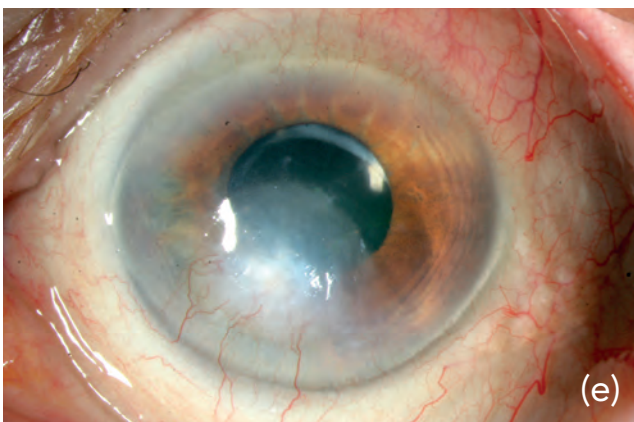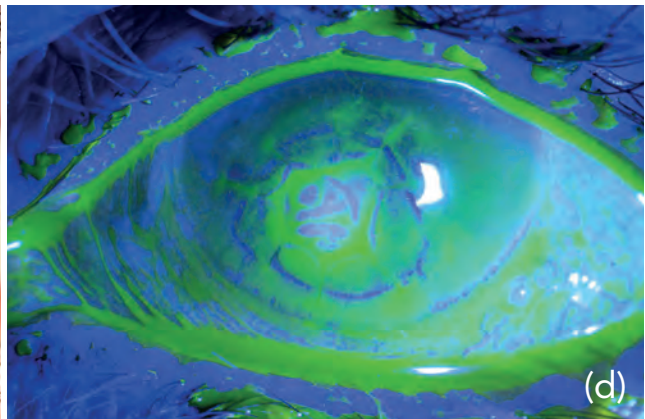
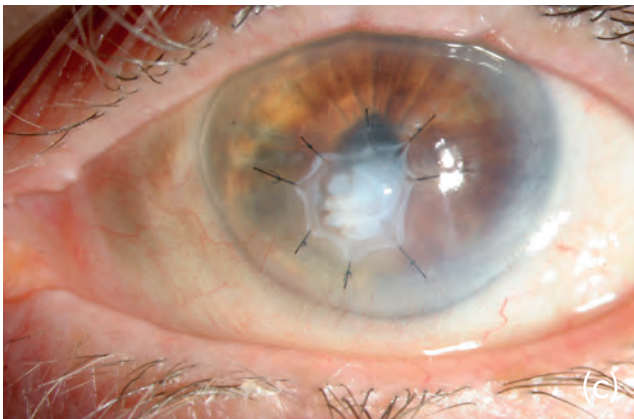
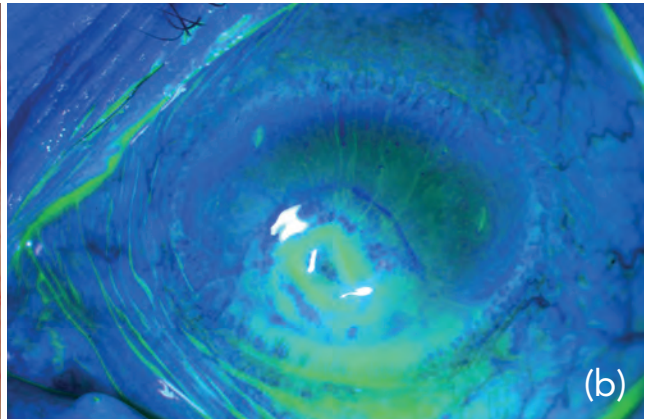
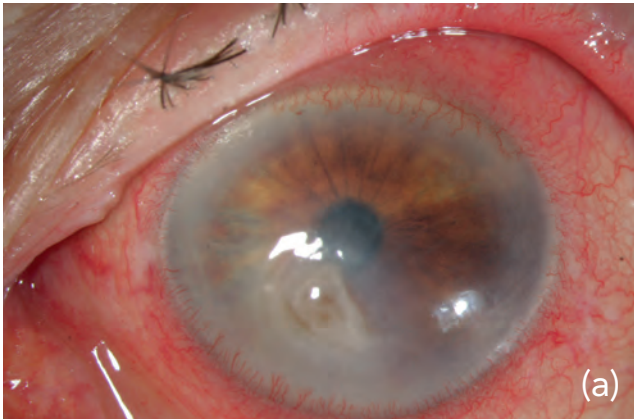5. Vasseneix C, Toubreau D, Brasseur G, Muraine M. Prise en charge chirurgicale des perforations cornéennes non traumatiques : étude rétrospective sur 8 ans. J Fr Ophtalmol. 2006;29:751-62.



Neurotrophic ulcer and amniotic membrane transplantation.

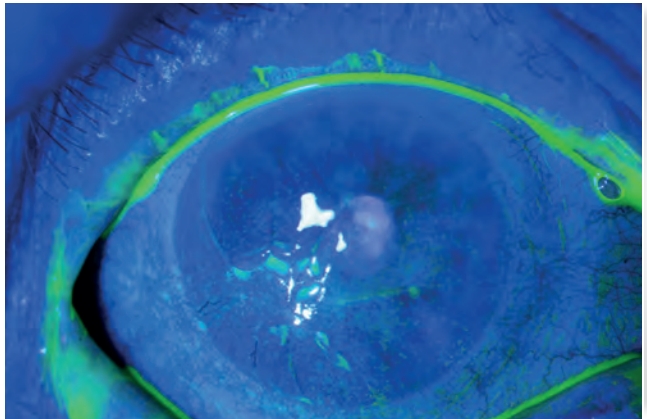
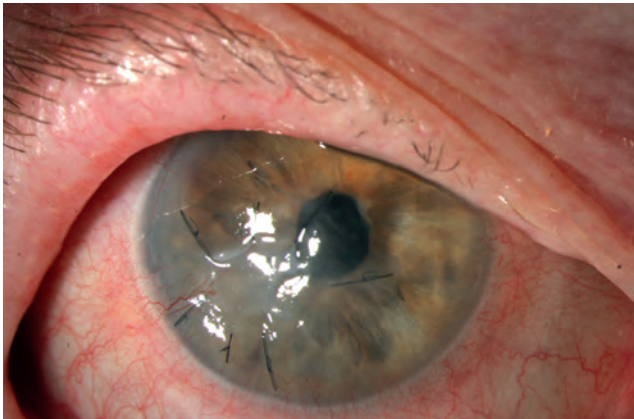
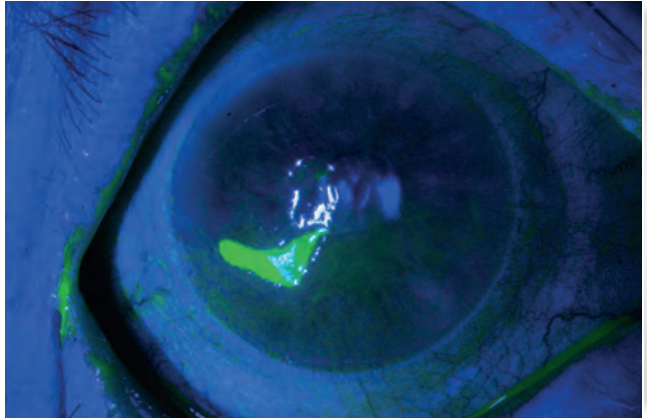
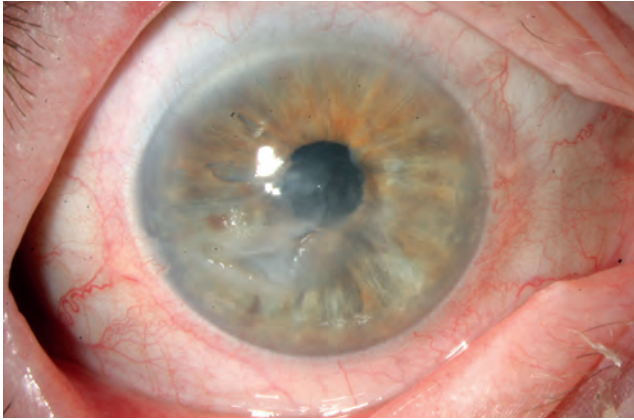
Neurotrophic ulcer following penetrating keratoplasty performed for herpes keratitis sequelae (a, b); appearance at 1 month (c) and at 1 year (d) after multi layered amniotic membrane transplantation.

NEUROTROPHIC KERATITIS TREATMENT



Perforated neurotrophic corneal ulcer and amniotic membrane transplantation.

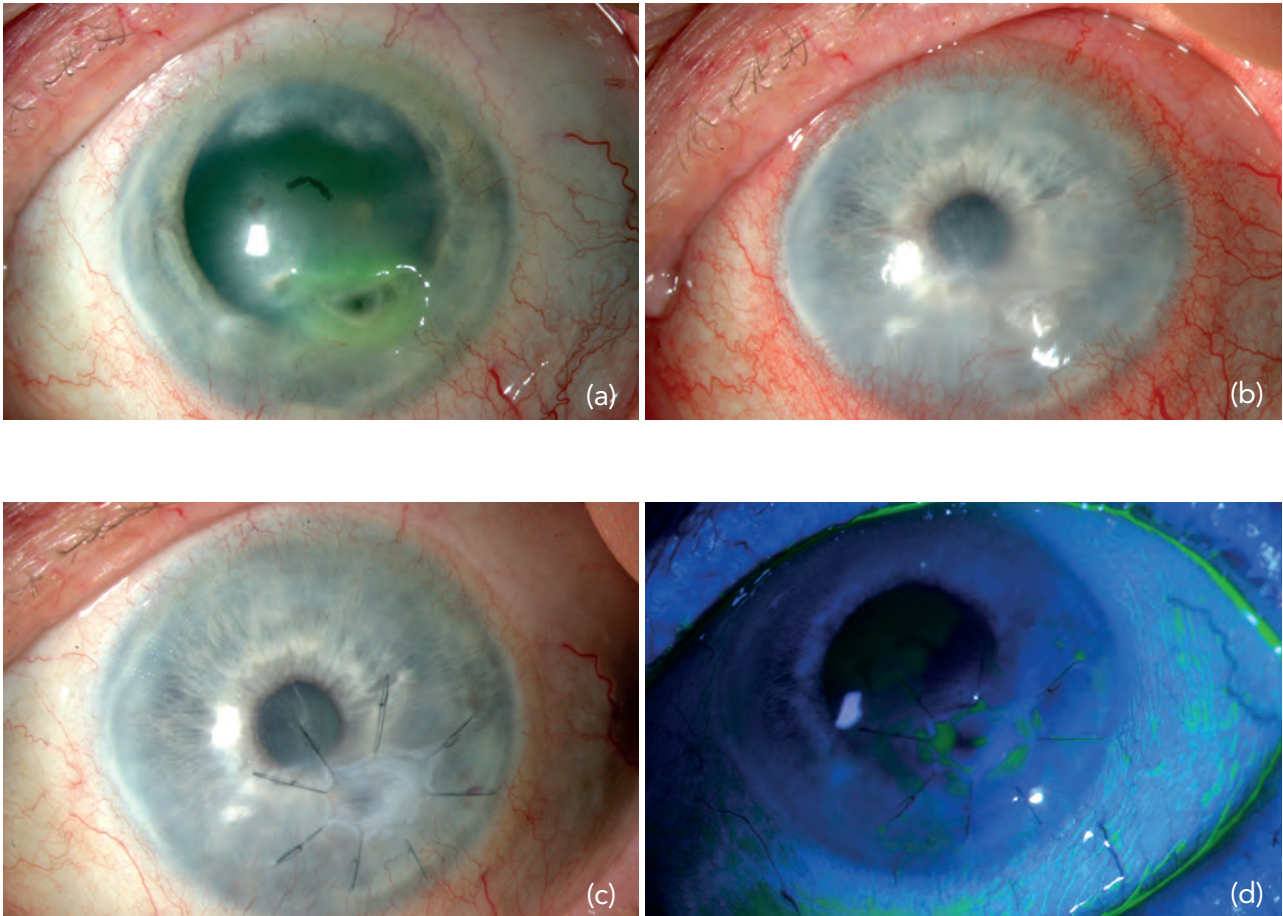
The structural integrity of the globe has been preserved by multi layered amniotic membrane transplantation. Initial appearance (a, b), at day 21 (c, d), and complete healing at 1 year (e, f).



Neurotrophic corneal ulcer and amniotic membrane transplantation.

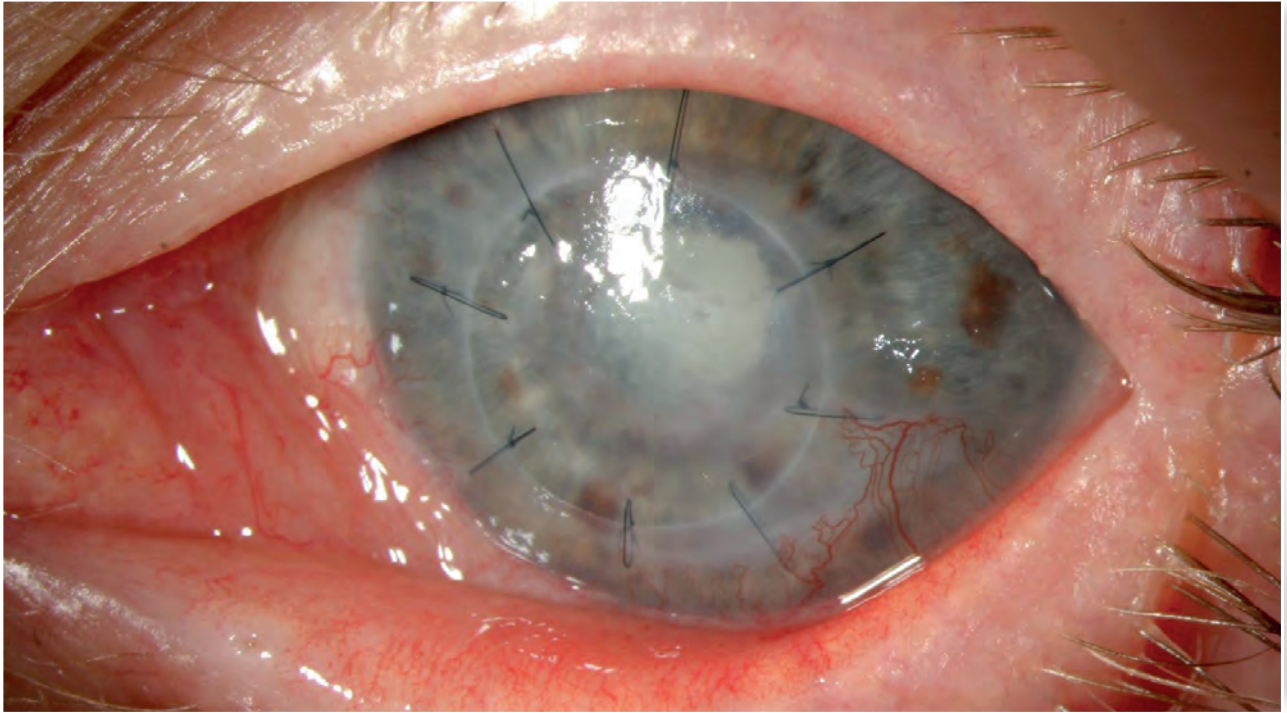
Persistent corneal ulcer following phacoemulsification combined with scraping of band keratopathy, despite the discontinuation of toxic topical medications and the initiation of RGTA® eye drops (Cacicol®, medical device, Laboratoires Théa, France). The lower images show healing obtained after amniotic membrane transplantation and therapeutic soft contact lens fitting.

NEUROTROPHIC KERATITIS TREATMENT



Amniotic membrane transplantation after cyanoacrylate glue use.

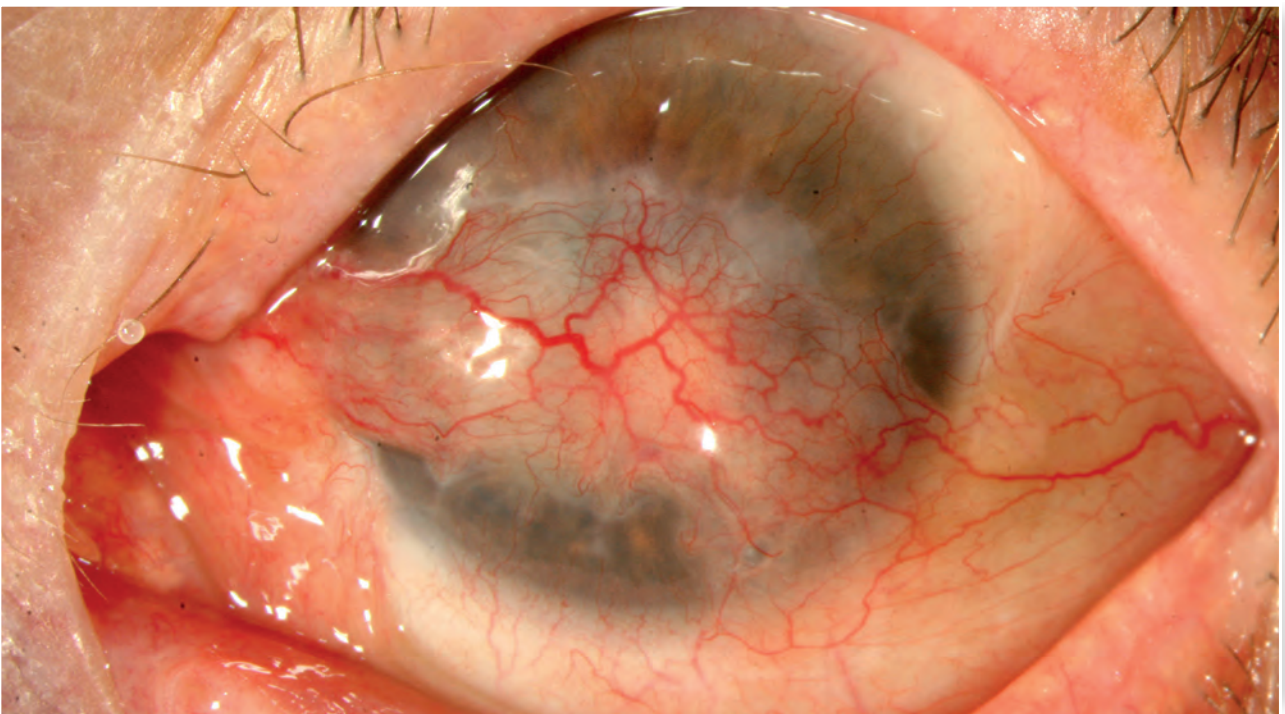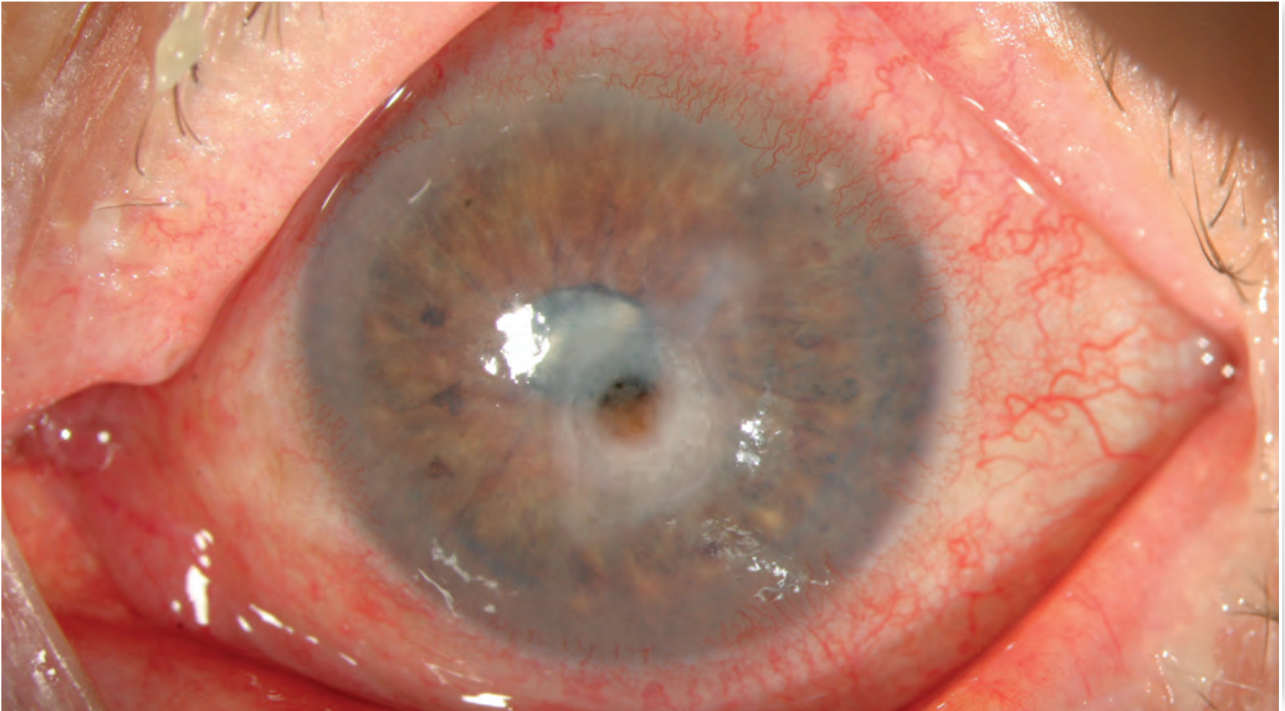Appearance of post-herpetic perforated neurotrophic ulcer. Application of cyanoacrylate glue associated with a therapeutic contact lens (b) allowed restoration of the structural integrity of the globe until multi layered amniotic membrane transplantation was performed (c and d).



Tectonic keratoplasty.

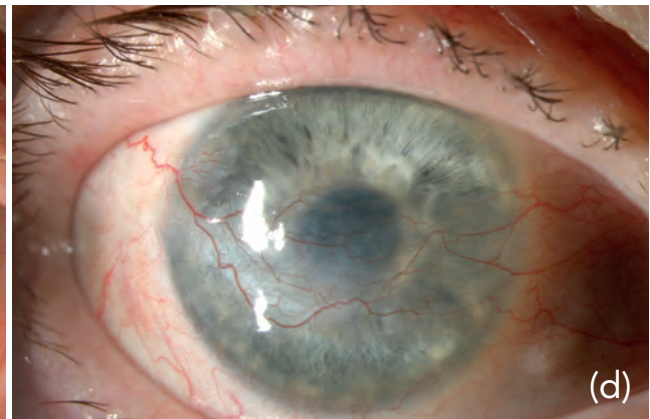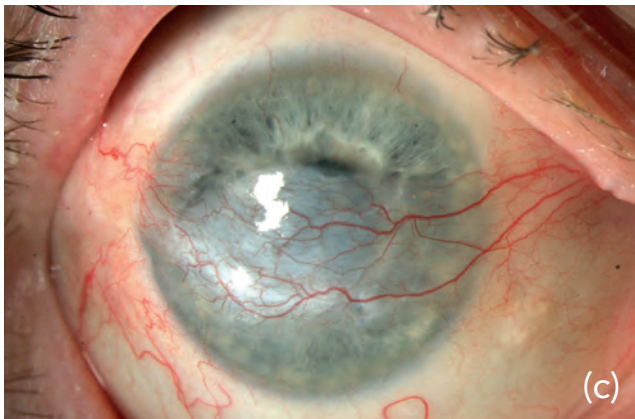
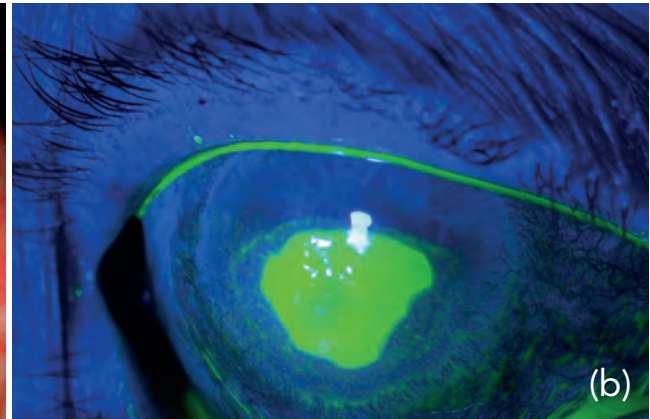
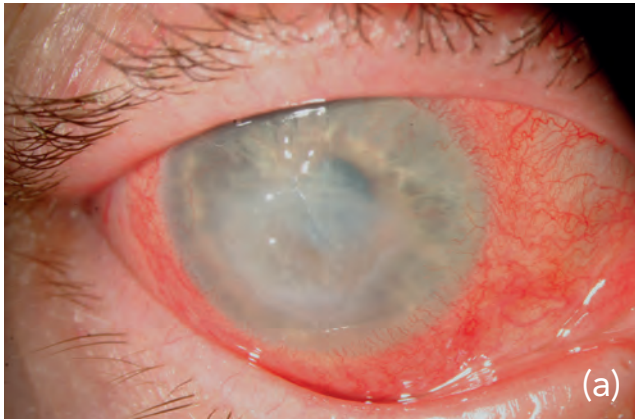
Perforated neurotrophic corneal ulcer despite two amniotic membrane transplantations. A keratoplasty was performed with a 6 mm diameter graft, combined with tarsorrhaphy.

NEUROTROPHIC KERATITIS TREATMENT



Perforated neurotrophic ulcer and conjunctival flap.

Corneal perforation treated by application of biological glue and a therapeutic contact lens, followed by a multi layered amniotic membrane transplantation. However, a partial conjunctival flap was necessary due to the recurrence of corneal perforation with iris prolapse.



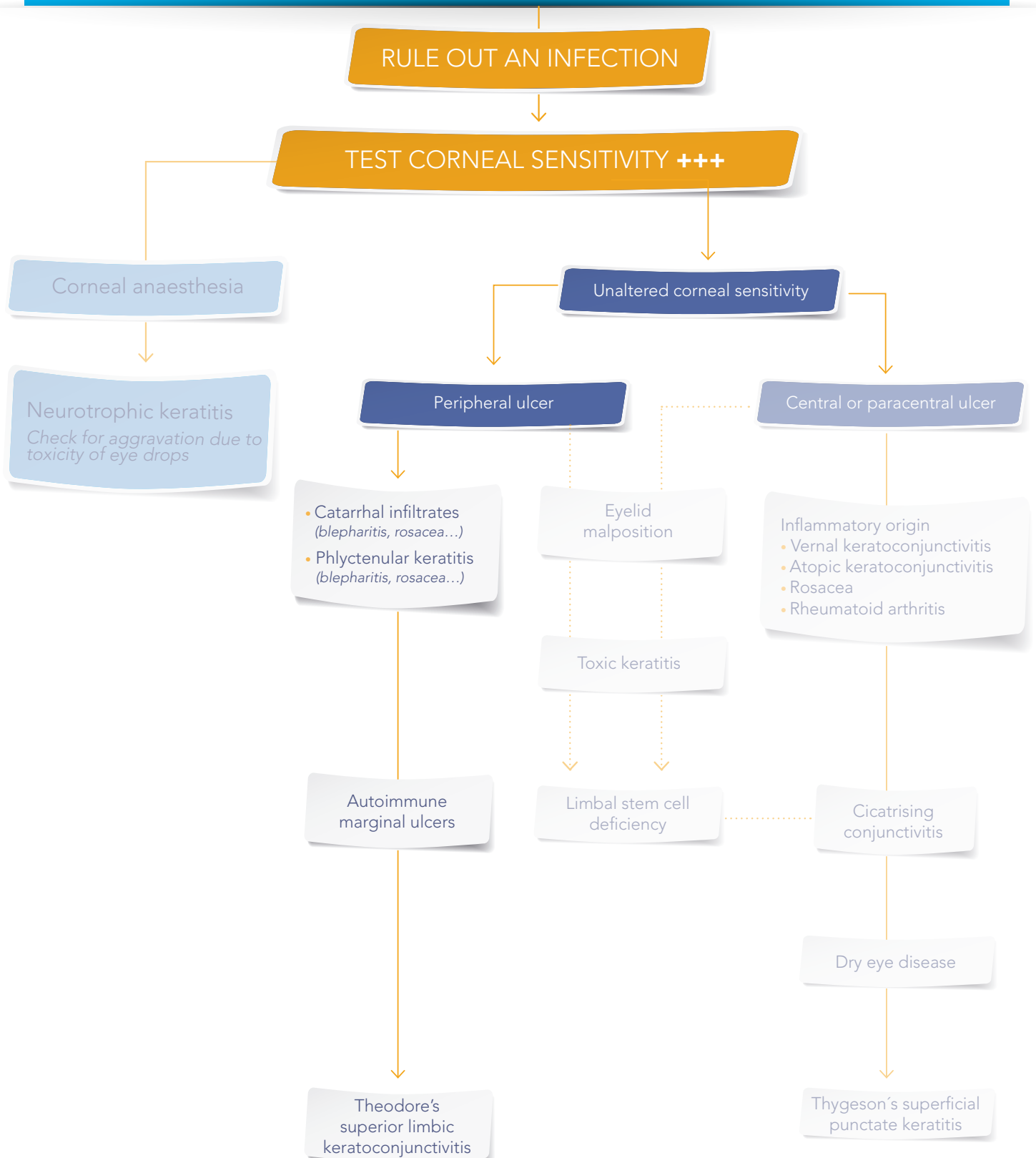
Perforated neurotrophic corneal ulcer and conjunctival flap.

Persistent corneal ulcer in a diabetic patient treated twice using amniotic membrane transplantation. Both transplantations were unsuccessful with a recurrent ulcer a few weeks following the removal of the sutures (a, b). Finally, ocular surface stability was achieved using a partial conjunctival flap (c). Note the gradual thinning and clearing after three years (d).

PERIPHERAL ULCER WITH UNALTERED CORNEAL SENSITIVITY

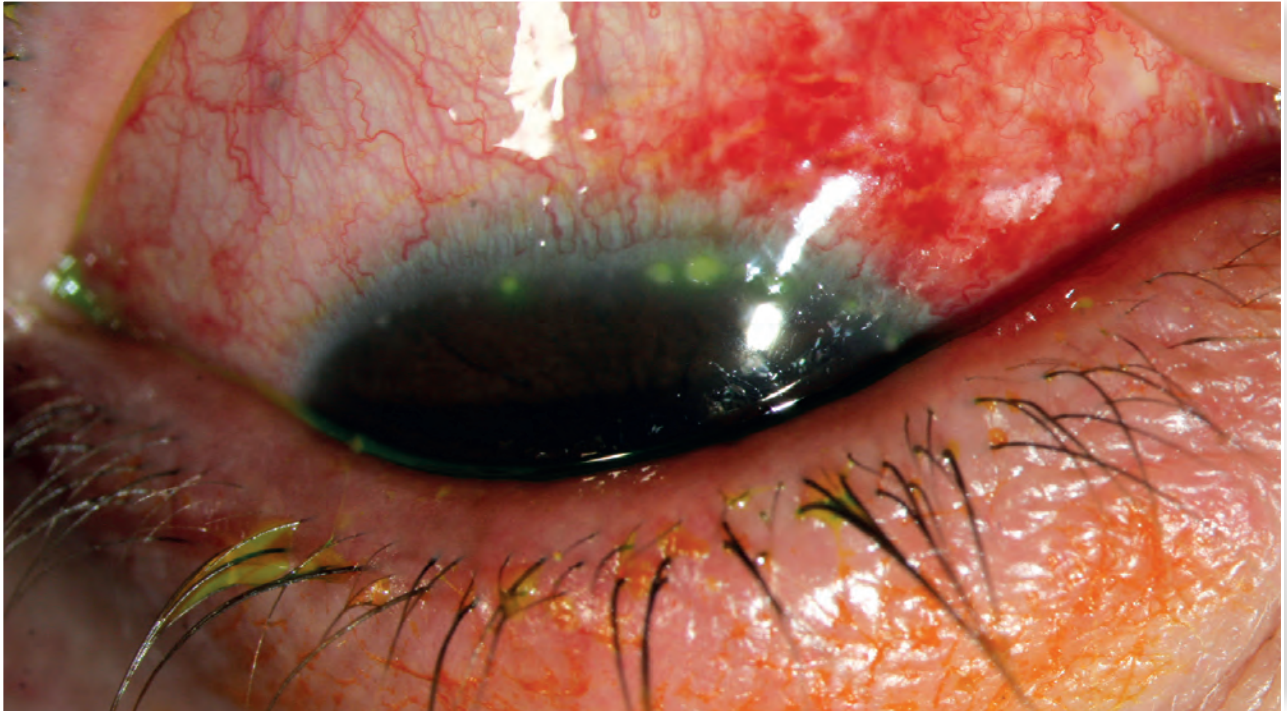
- When infectious keratitis is ruled out and corneal sensation is found to be unaltered, a neurotrophic keratitis too can be ruled out. The location of the ulcer then becomes an important guide for further analysis. The causes of peripheral ulcers will first be addressed.

DIFFERENTIAL DIAGNOSIS WHEN FACED WITH KERATITIS OR A CHRONIC ULCER



CATARRHAL INFILTRATES AND PHYCTENULAR KERATITIS

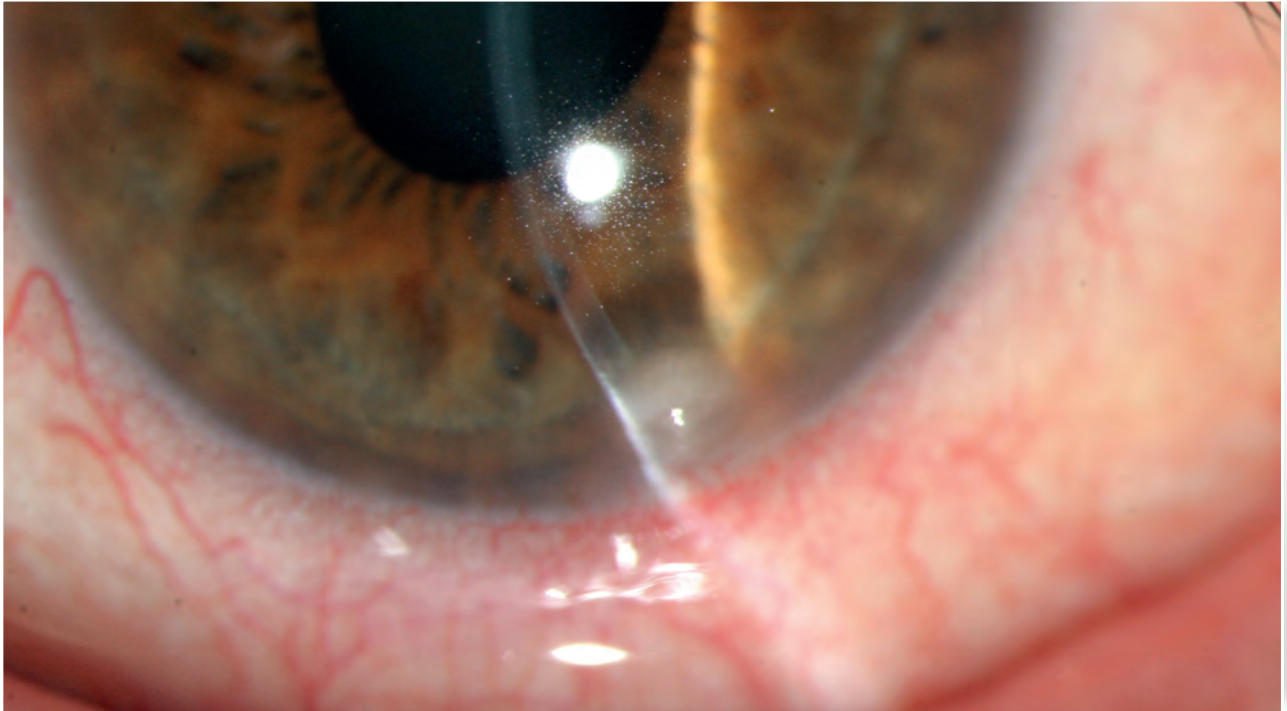
- Inflammatory peripheral ulcers with grey-white infiltrate, (**catarrhal infiltrates or ptyctenular keratoconjunctivitis**) are shallower and have a smaller circumference than autoimmune peripheral ulcerative keratitis.
- They constitute a non-infectious inflammatory disorder of the ocular surface based on hypersensitivity mechanism to bacterial antigens.
- **Catarrhal infiltrates** are associated with meibomian gland dysfunction or rosacea blepharitis and probably represent a type III hypersensitivity reaction (immune complex deposition) to staphylococci antigens emanating from the inflamed eyelids. Their distribution is circumferential; these infiltrates are separated from the limbus by a clear space, which may show superficial peripheral vascularisation. Their major axis is parallel to the limbus. With prolonged inflammation, the corneal epithelium overlying the stromal infiltrate can break down leading to peripheral ulceration. These infiltrates are usually rounded but may coalesce into broader lesions to give a misleading picture of pseudo-Mooren's ulcer or of an autoimmune marginal ulcer. Evolution mostly occurs over a few weeks with a significant risk of recurrence if blepharitis is not treated.



Catarrhal infiltrate.

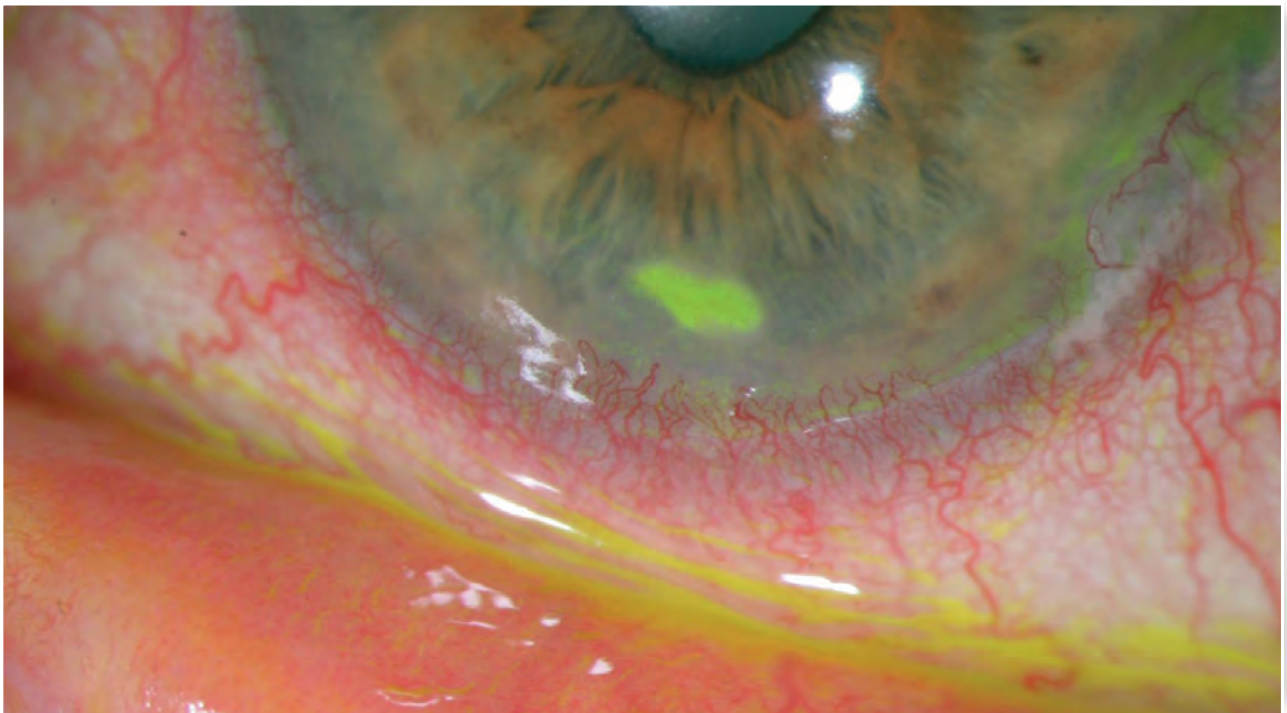
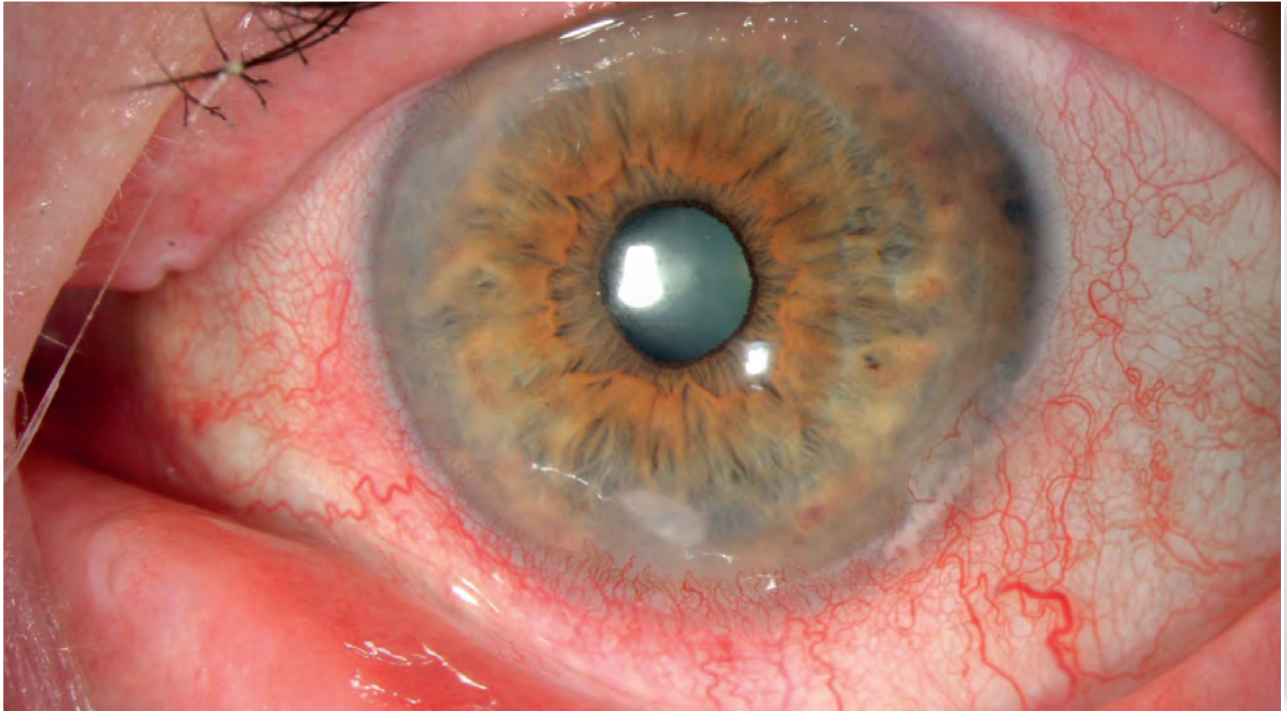
These are small infiltrates, often multiple and separated from the limbus by a clear space. In the illustration above, the corneal epithelium overlying the stromal infiltrates has broken down, leading to multiple peripheral ulcers.

CATARRHAL INFILTRATES AND PHYCTENULAR KERATITIS



Catarrhal infiltrate.

Note the infiltrate at about 2 mm from the limbus. These lesions tend to be located where the eyelid margins intersect the limbus (i.e. 2, 4, 8 and 10 o'clock).

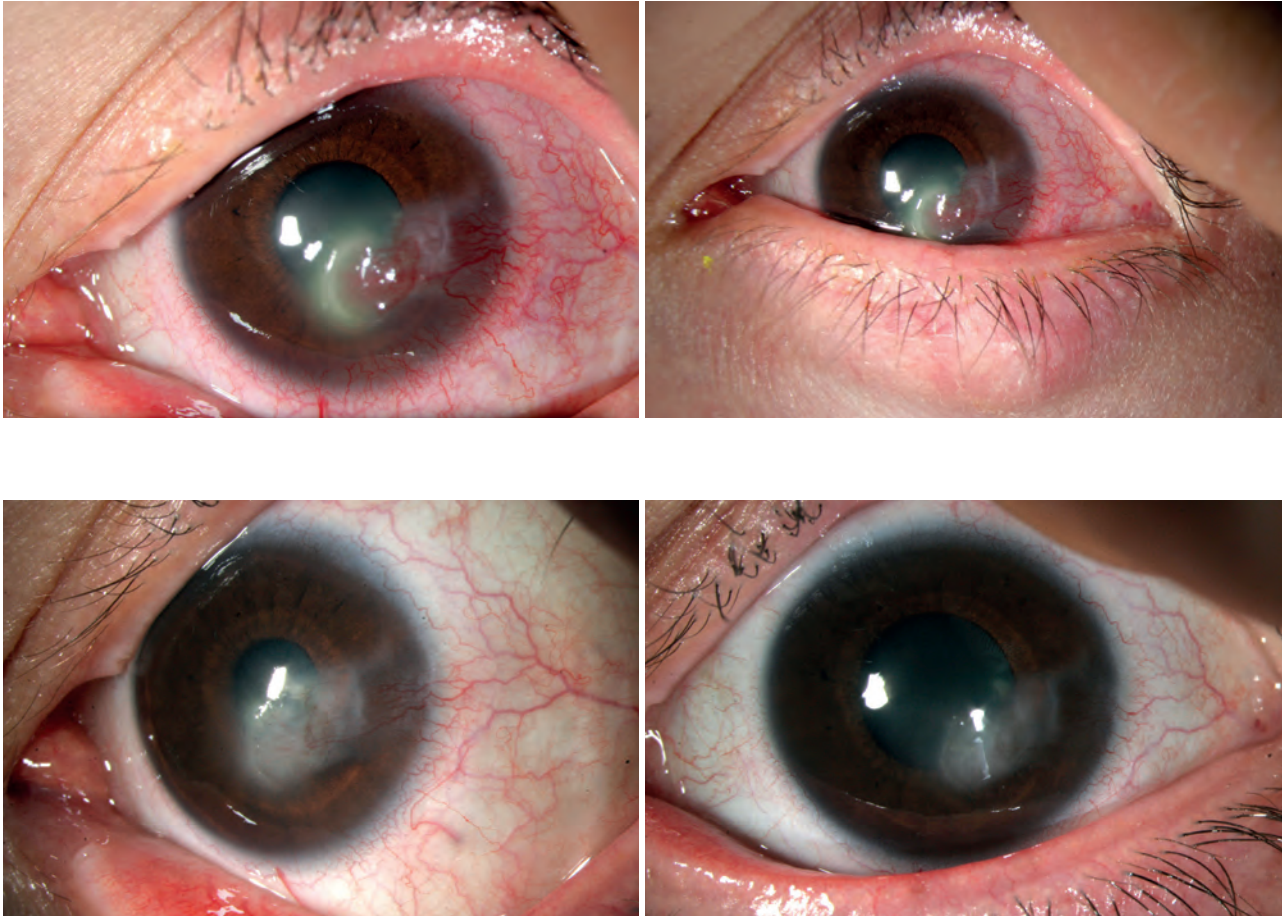


Catarrhal infiltrates.

Inferior infiltrate near the limbus with overlying epithelial defect staining with fluorescein. Note the associated superficial vascularisation.

CATARRHAL INFILTRATES AND PHYCTENULAR KERATITIS

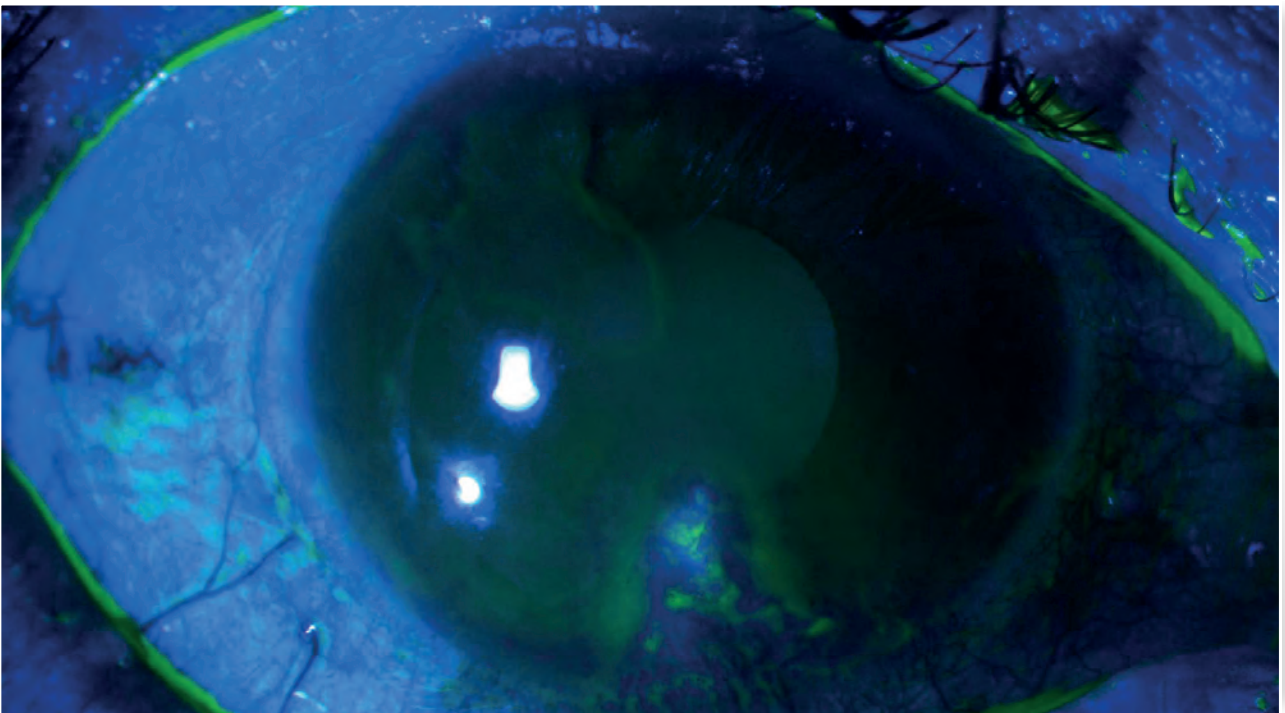
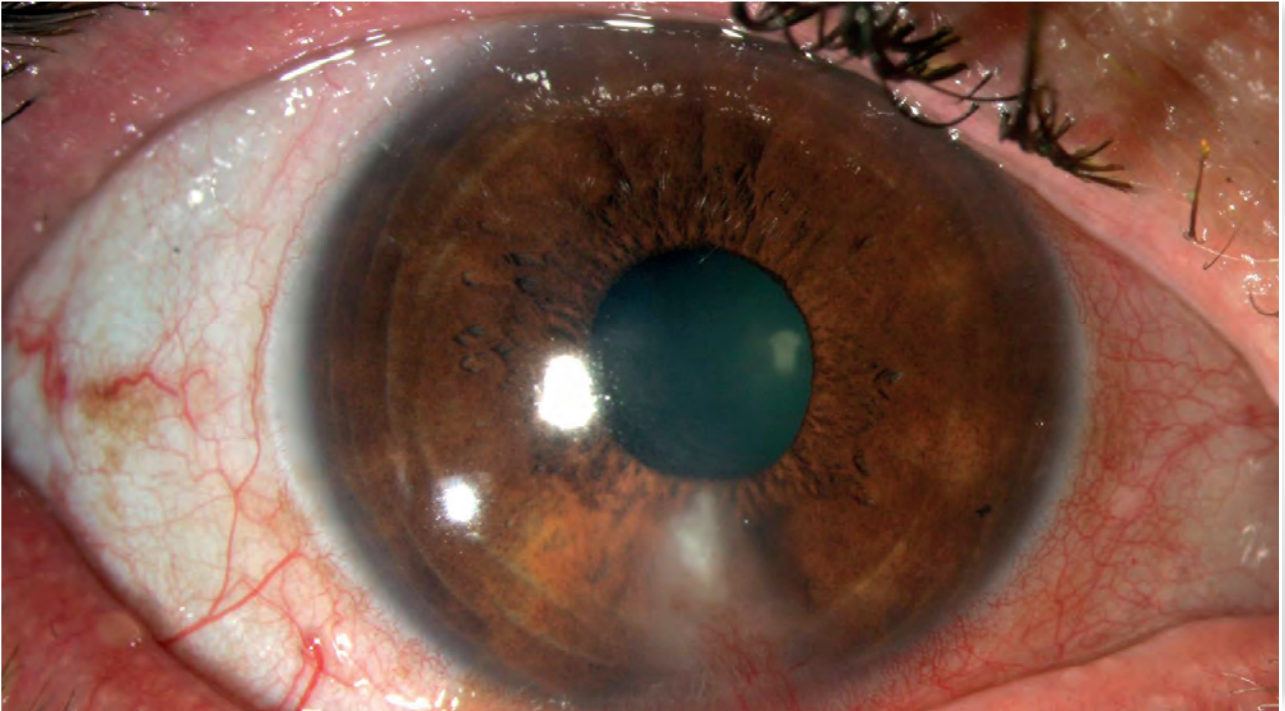
- **Phlyctenular keratoconjunctivitis** results from a type IV hypersensitivity reaction (cell-mediated immunity) to bacterial antigens, *staphylococcus* species in the great majority of cases. The phlyctenules may be conjunctival, limbal or corneal.
- **Corneal phlyctenules** are small whitish vesicles, often near the limbus, associated with intense localised conjunctival inflammation. They often necrose, creating a marginal ulcer, which then heals, leaving an anterior stromal scar. Superficial corneal neovascularisation is common; it can be fascicular or with a broader base. The complete cycle lasts 2 weeks. New phlyctenules may form at the central border of the vascularisation consequential to a previous lesion, giving the impression that the phlyctenule is being carried across the cornea by the invading vessels.



Corneal phlyctenules.

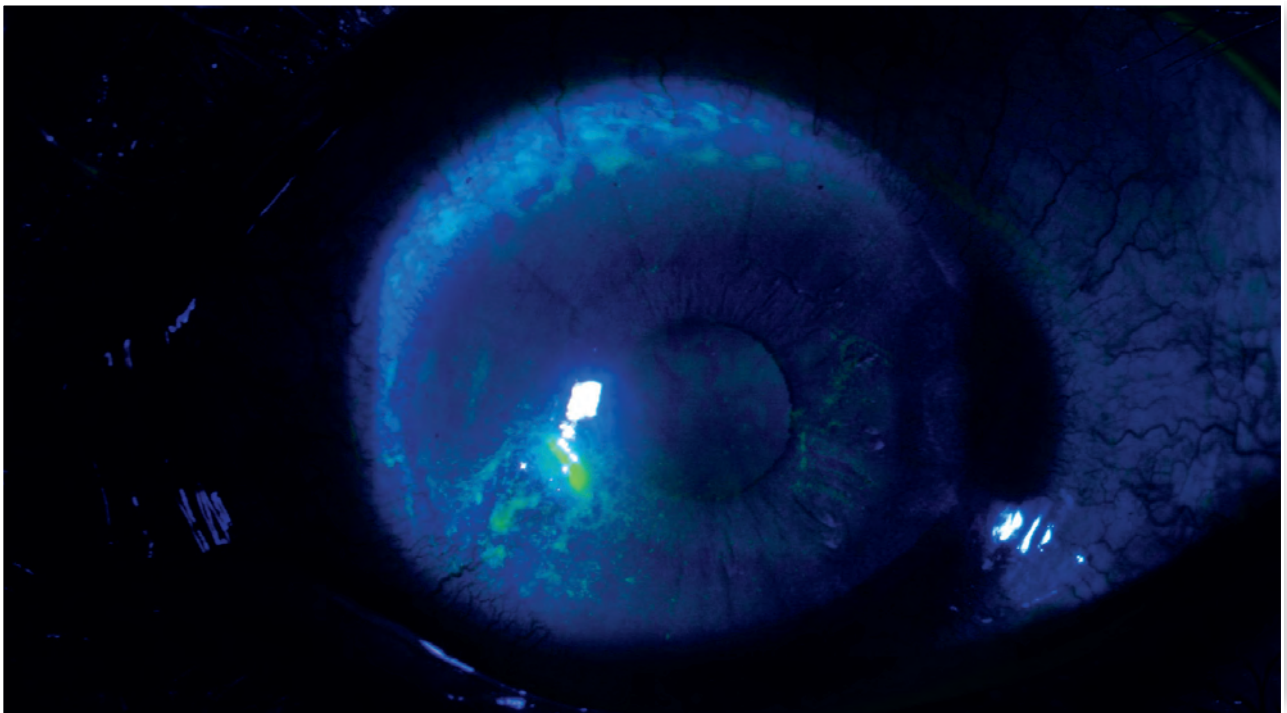
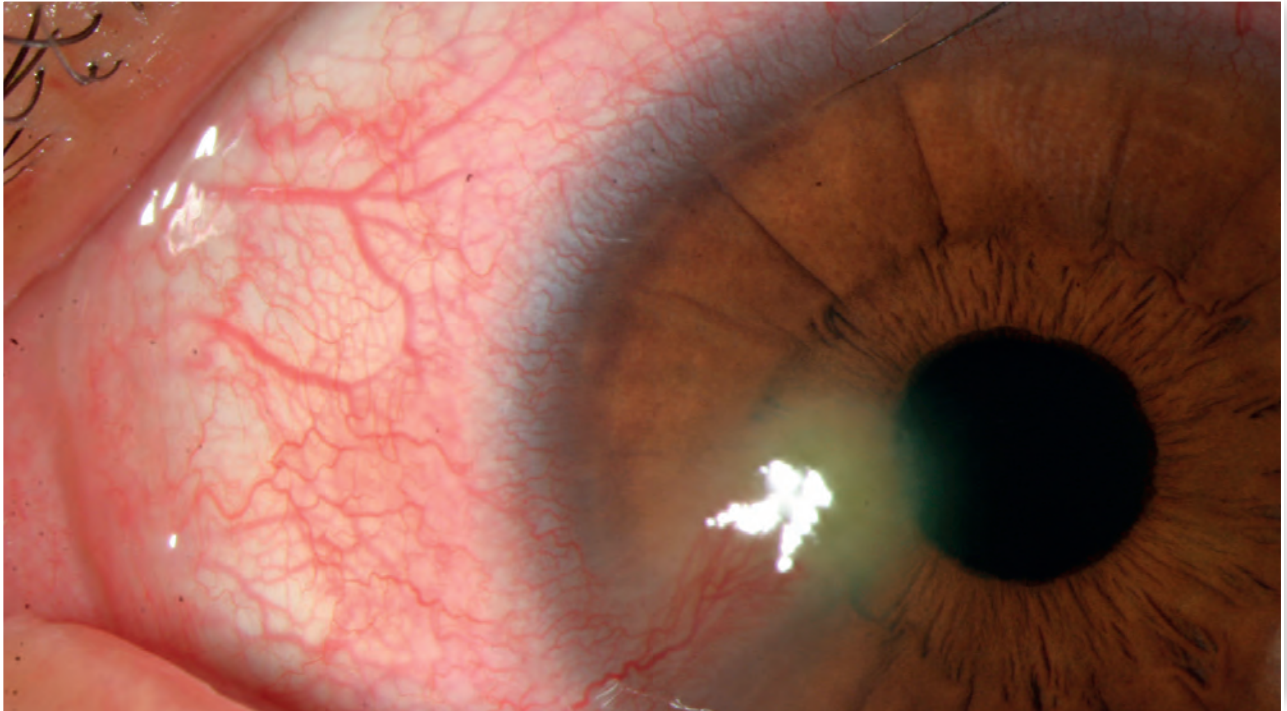
This condition gives the impression of the lesion «walking» on the cornea due to the progression of the neovascularisation and corneal opacities. Note, in the top right image, the large associated chalazion, evidence of the causal meibomitis. The lower images show favorable clinical course following the introduction of corticosteroid therapy and subsequent control of the meibomian gland dysfunction.

CATARRHAL INFILTRATES AND PHYCTENULAR KERATITIS



Phlyctenular keratoconjunctivitis.

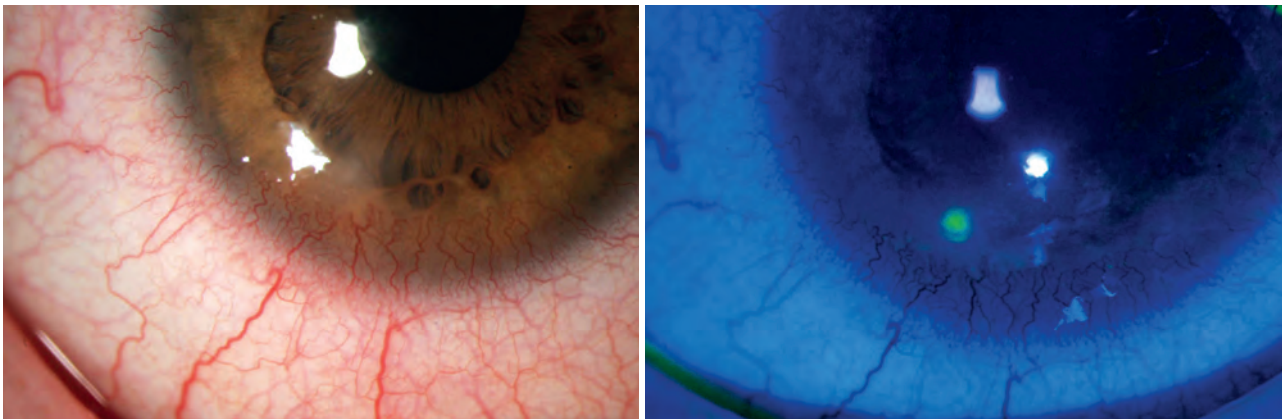
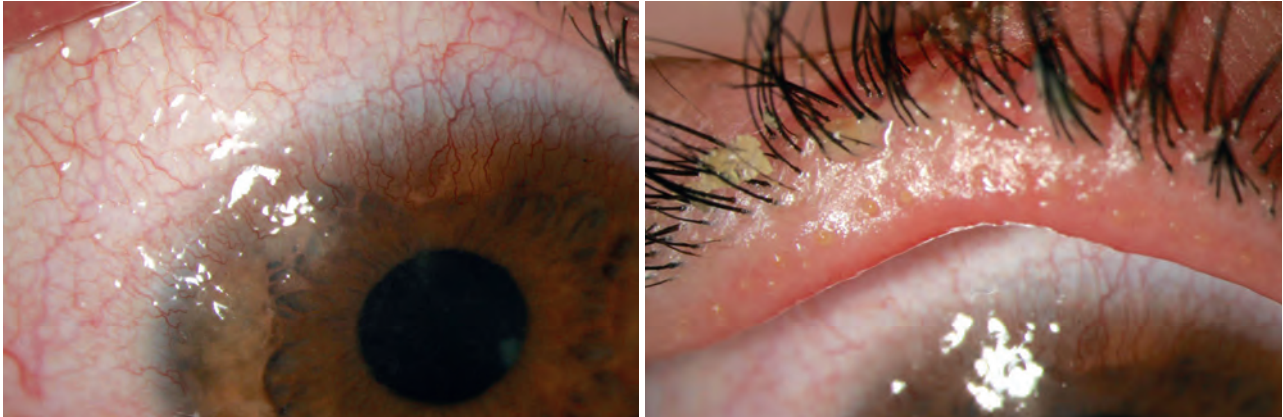
Grey-white appearance of the ulcerated phlyctenule and fascicular neovascularisation, associated with meibomian gland dysfunction.



Corneal phlyctenule.

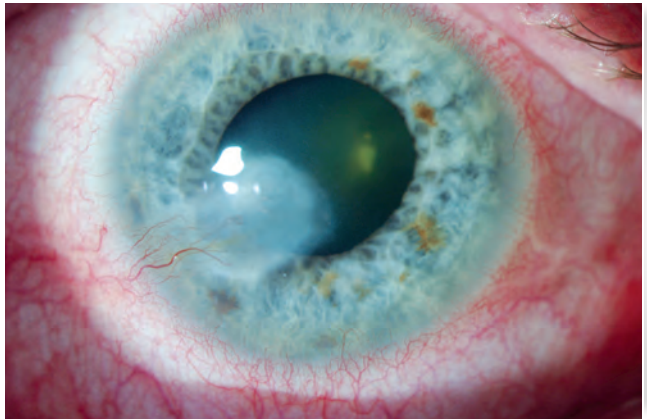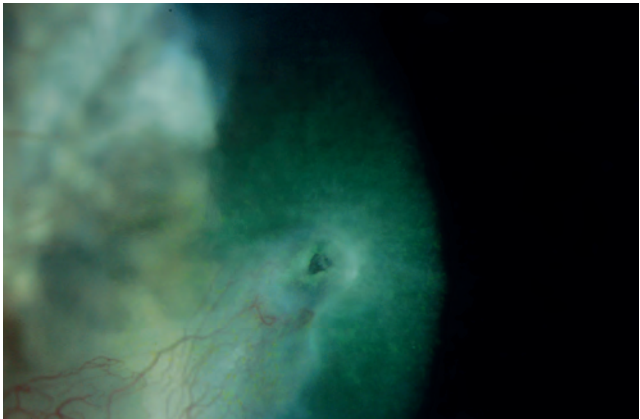
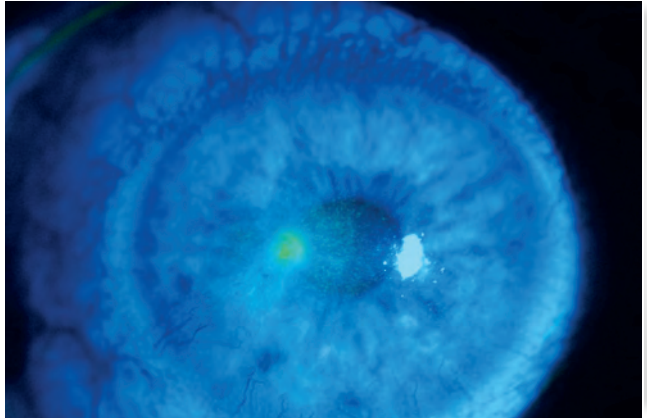
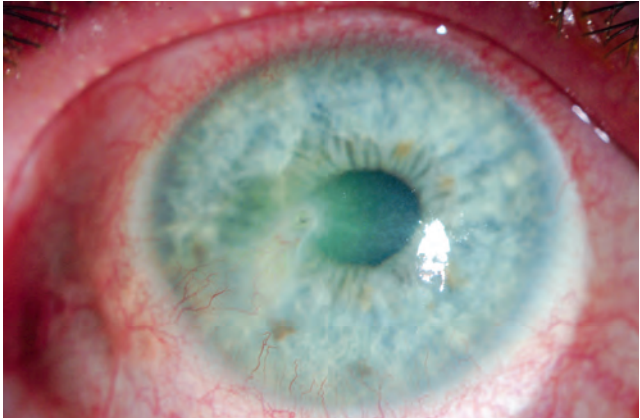It is not always easy to differentiate this presentation from an infectious keratitis. Note here, the fluorescein staining of the ulcerated phlyctenule as well as the fascicular neovascularisation.

CATARRHAL INFILTRATES AND PHYCTENULAR KERATITIS



Phlyctenular keratoconjunctivitis in a child.

Note the light, which is reflected on top of the conjunctival and corneal phlyctenules, giving an «embossed» appearance; and the associated meibomitis. Also note here, the associated corneal neovascularisation and the fluorescein staining, which reveals the overlying epithelial defect. The location is preferentially lower contrary to the neovascular pannus observed in trachoma which is usually upper.



Corneal phlyctenule progression.

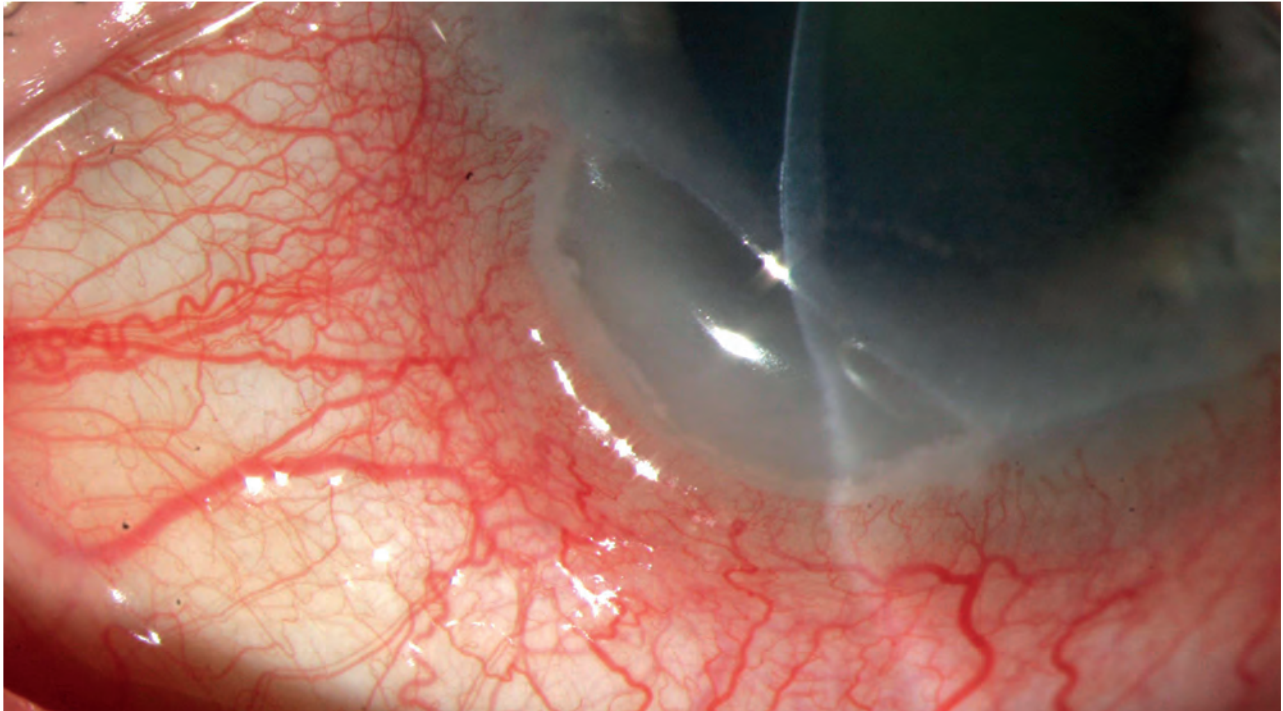
The overlying epithelium has broken down leaving a small ulcer, which may heal spontaneously or following treatment. This ulcer is connected to the limbus by fascicular neovascularisation. Note the stromal scar a few weeks later (at the bottom and on the right part).

AUTOIMMUNE MARGINAL ULCERS

- The limbal location of an ulcer is highly suggestive of a non-infectious inflammatory cause. Peripheral corneal inflammatory ulcers or marginal ulcers, are most often autoimmune, and are also referred to as Peripheral Ulcerative Keratitis or PUK^{6,7}. Autoimmune ulcers are associated with scleritis in 10 to 30% of cases. They are bilateral in about 40% of cases.
- The diagnosis and management of an **autoimmune marginal ulcer** should be prompt not only due to the corneal perforation risk but also because it may be the first manifestation of a previously unknown severe systemic disease that can be life threatening. The most frequently diagnosed diseases are rheumatoid arthritis and Wegener's disease. In the case of rheumatoid arthritis, corneal manifestations occur most often after many years of disease progression and may or may not, be associated with scleritis. The treatment strategy is based upon a therapeutic stepladder determined by the severity of the ulcer.

6. Tauber, J., M. Sainz de la Maza, T. Hoang-Xuan, et al. An analysis of therapeutic decision making regarding immunosuppressive chemotherapy for peripheral ulcerative keratitis. *Cornea* 1990;9:66-73.

7. Galor, A. and J.E. Thorne. Scleritis and peripheral ulcerative keratitis. *Rheum Dis Clin North Am.* 2007;33:835-54.

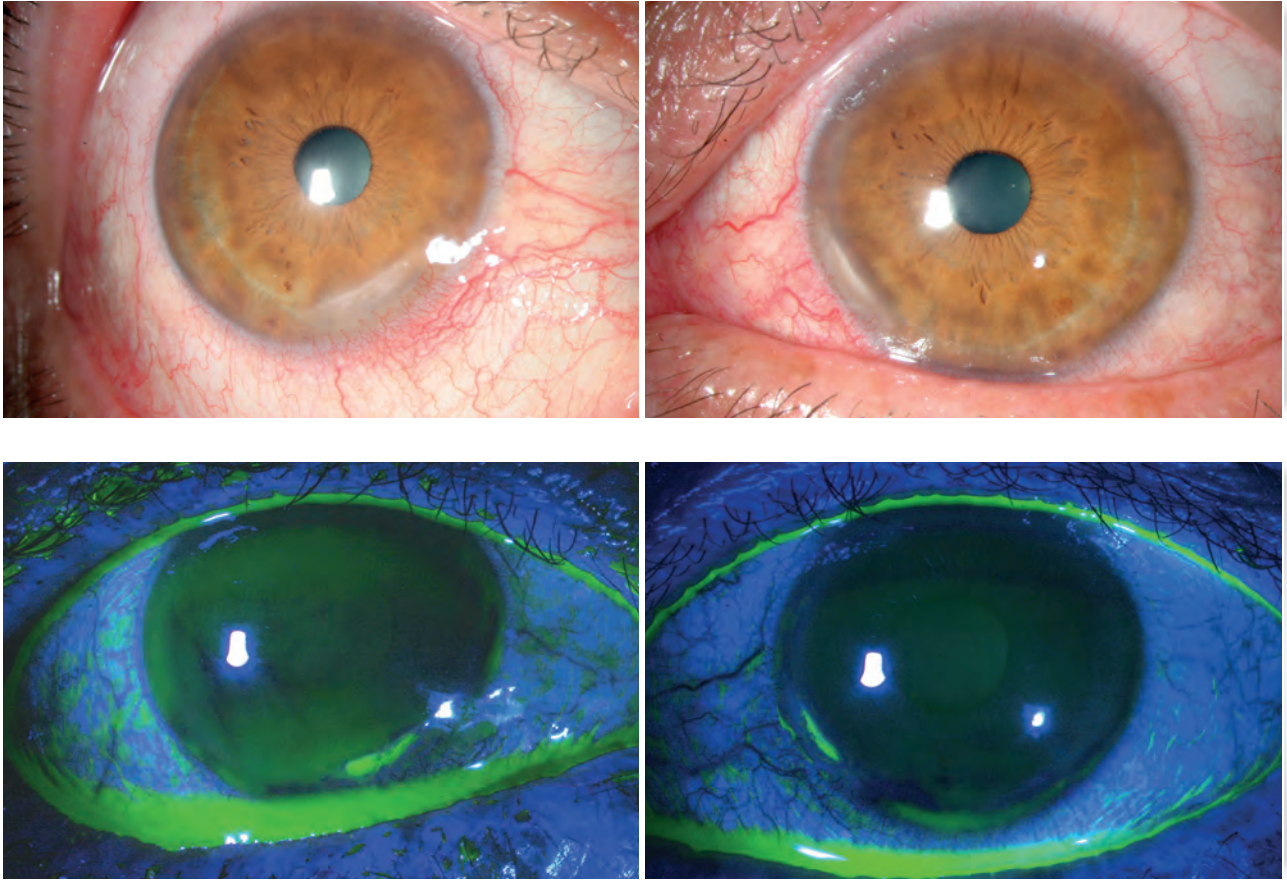


Corneal ulcer and Wegener's disease (or granulomatosis with polyangiitis).

Important causes of autoimmune marginal ulcers.

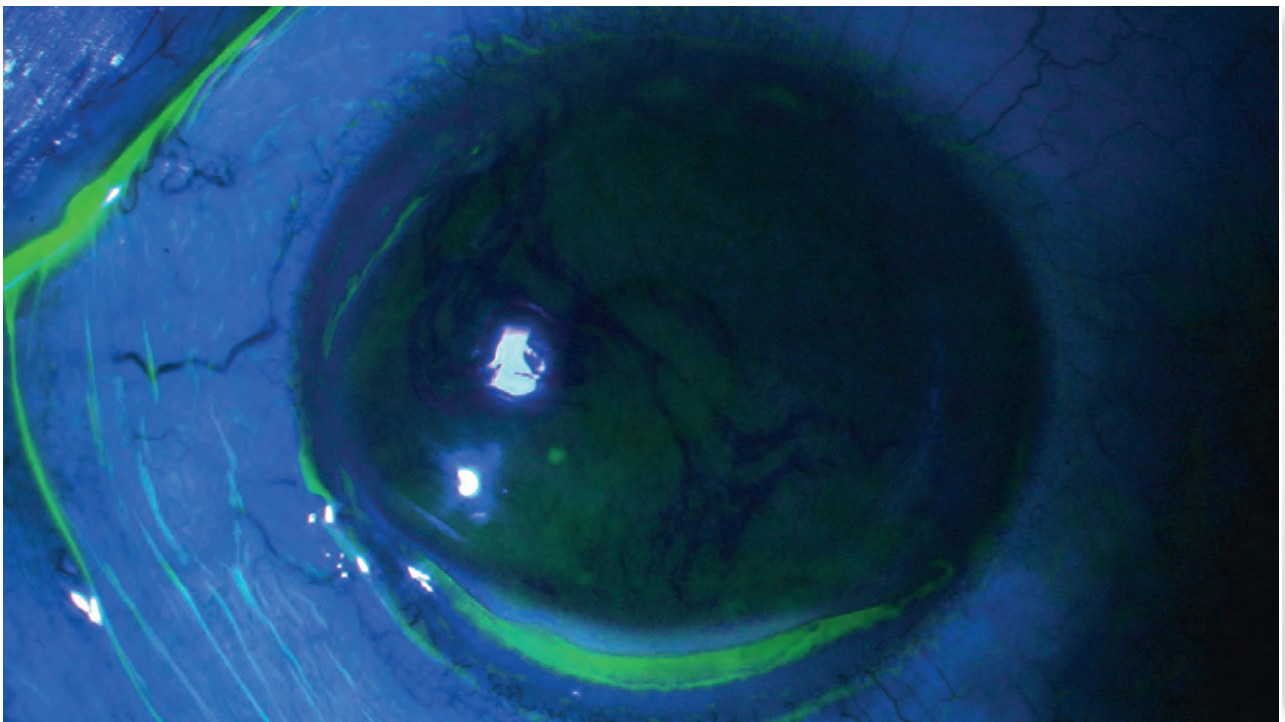
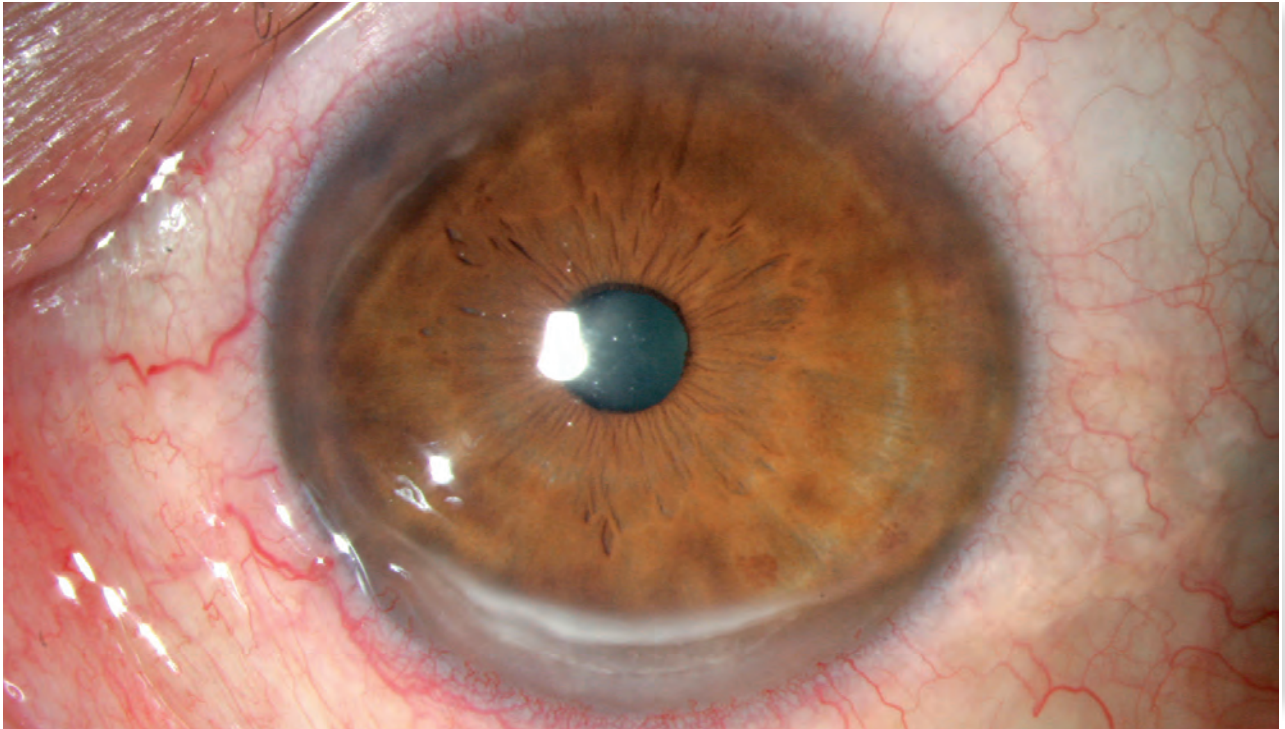
- Rheumatoid arthritis
- Wegener's granulomatosis (Granulomatosis with polyangiitis)
- Polyarteritis nodosa
- Relapsing polychondritis
- Systemic lupus erythematosus
- Sjögren's syndrome
- Behçet's disease, sarcoidosis, Crohn's disease
- Helminthiasis, Hepatitis C
- Mooren ulcer (idiopathic form)

AUTOIMMUNE MARGINAL ULCERS



Corneal ulcer in rheumatoid arthritis.

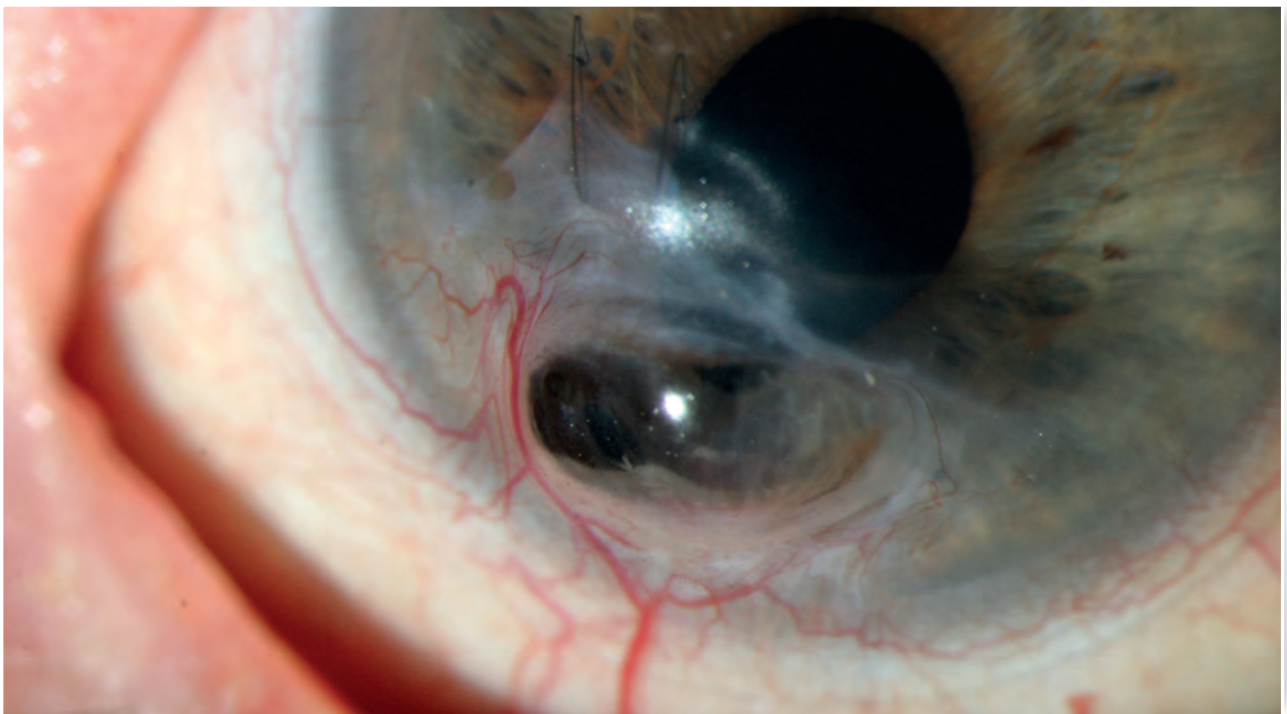
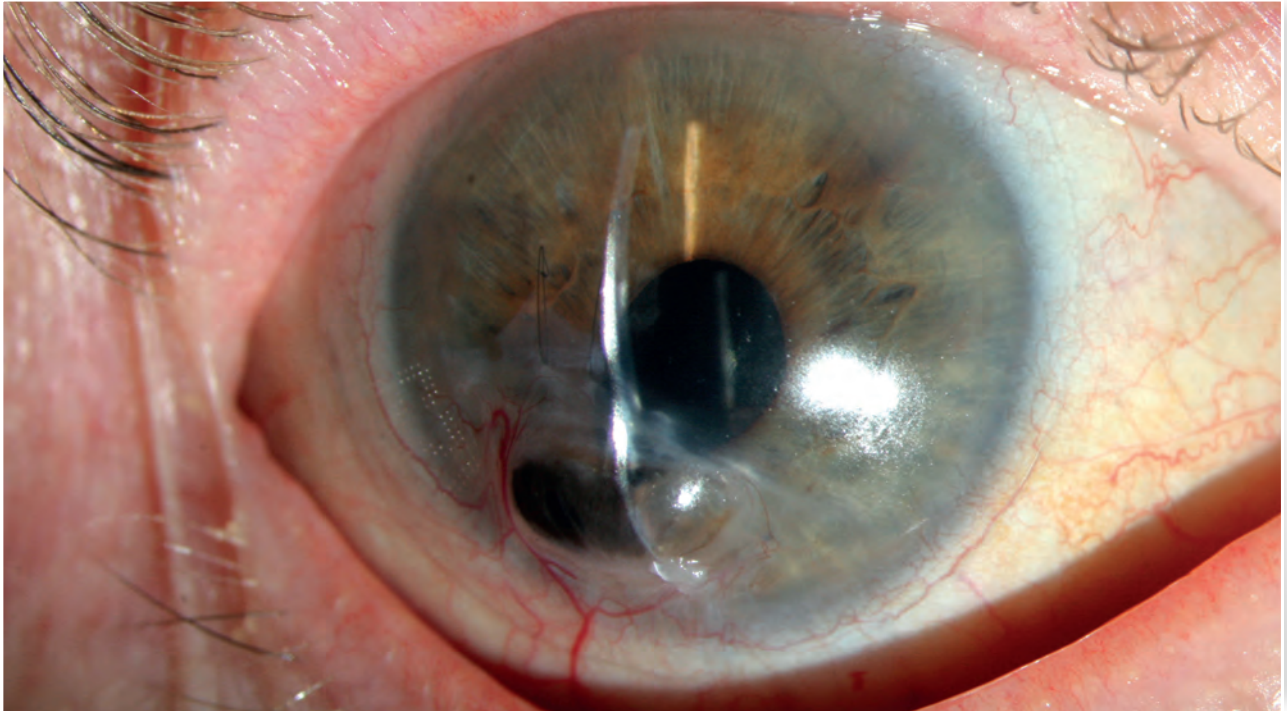
Bilateral peripheral ulcerative keratitis in the context of rheumatoid arthritis waxing and waning for 20 years.



Corneal ulcer in rheumatoid arthritis.

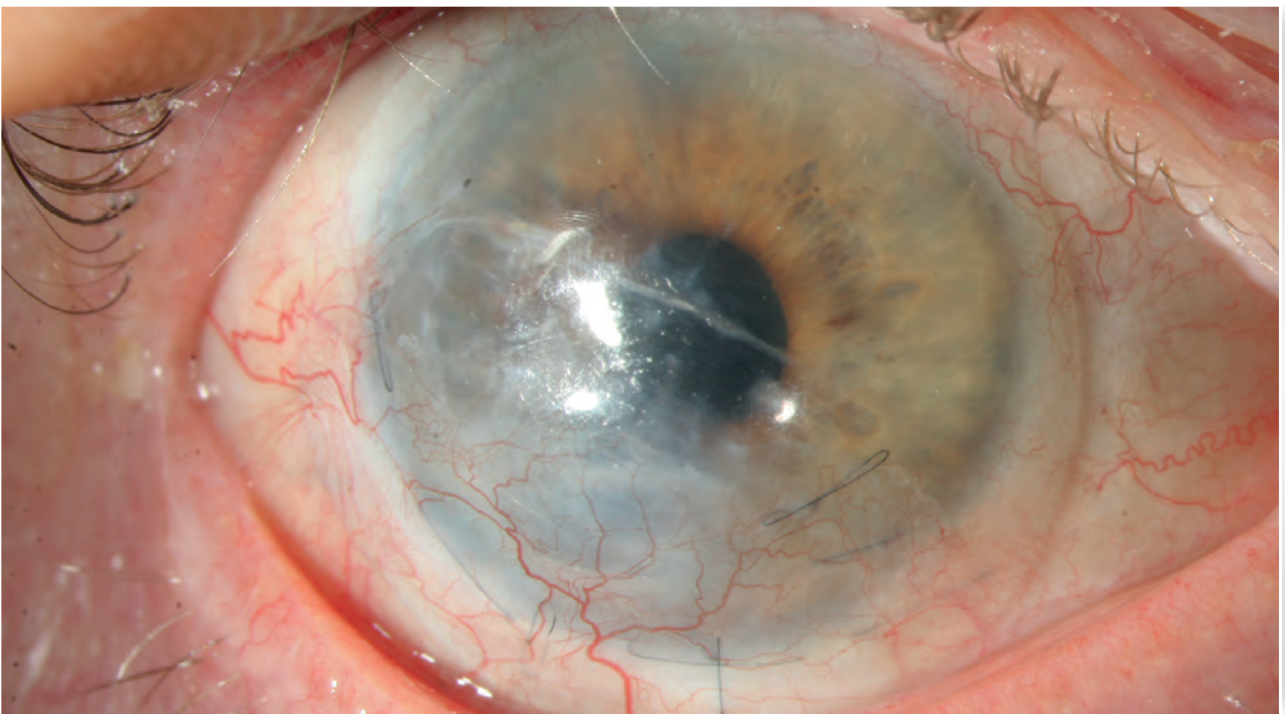
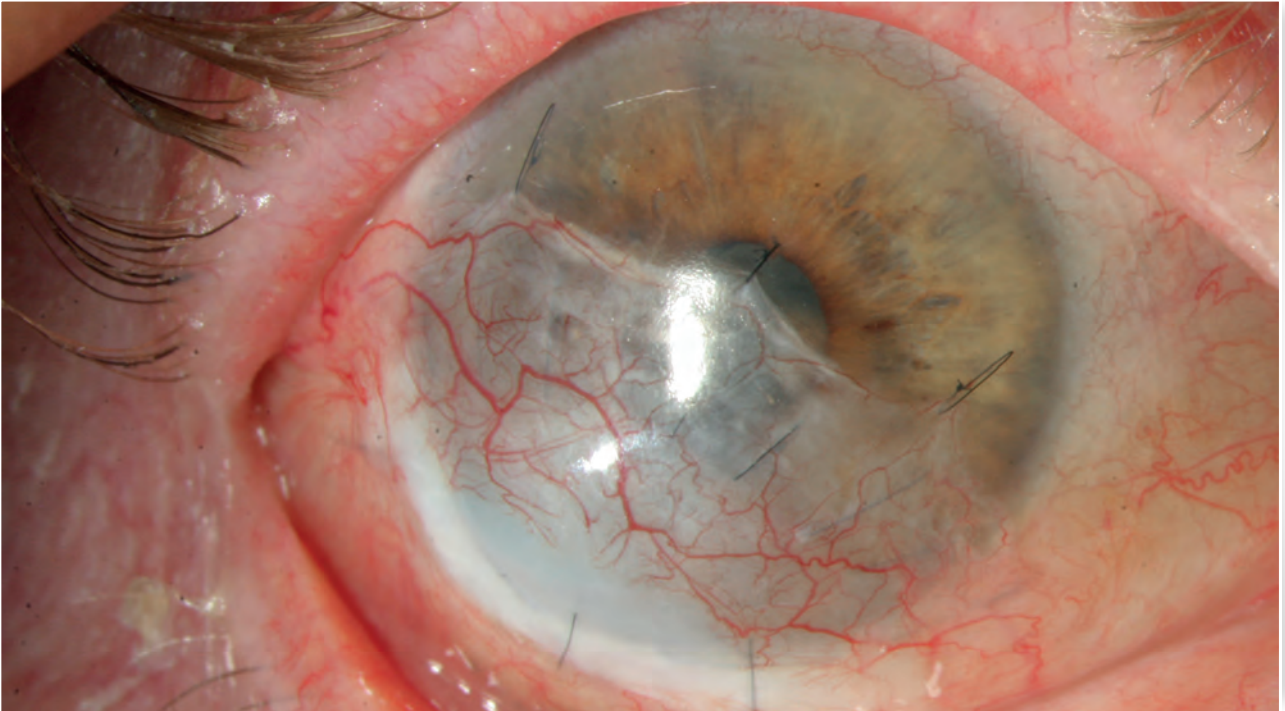
Same patient as the previous page. Recurrence of a marginal ulcer in the left eye 6 months into a reducing course of corticosteroid therapy.

AUTOIMMUNE MARGINAL ULCERS



Corneal ulcer and rheumatoid arthritis.

Recurrence of marginal ulcer following tectonic patch graft performed for perforation following phacoemulsification surgery in a patient with a history of secondary Sjögren's syndrome associated with rheumatoid arthritis.

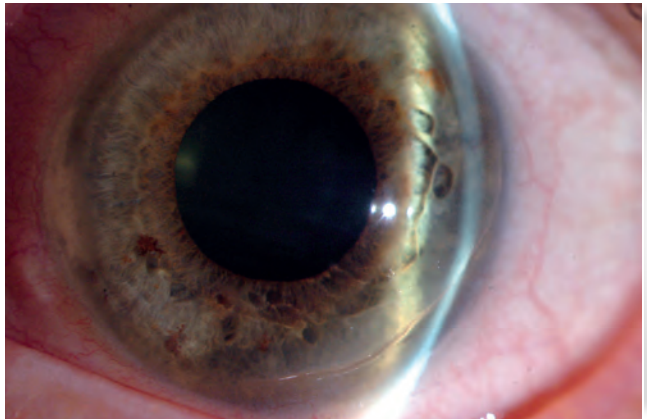
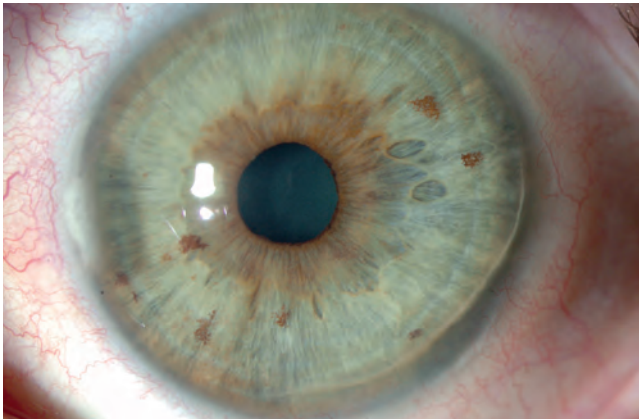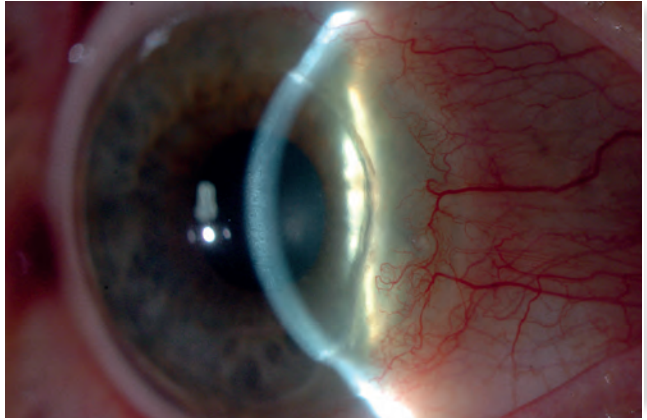
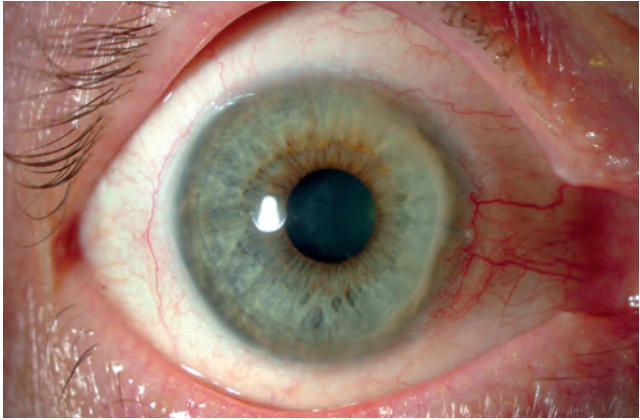


Corneal ulcer and rheumatoid arthritis (same patient).

Favorable clinical course after a new small tectonic keratoplasty associated with a conjunctival flap. Appearance at 1 (top) and 2 (bottom) years.

AUTOIMMUNE MARGINAL ULCERS

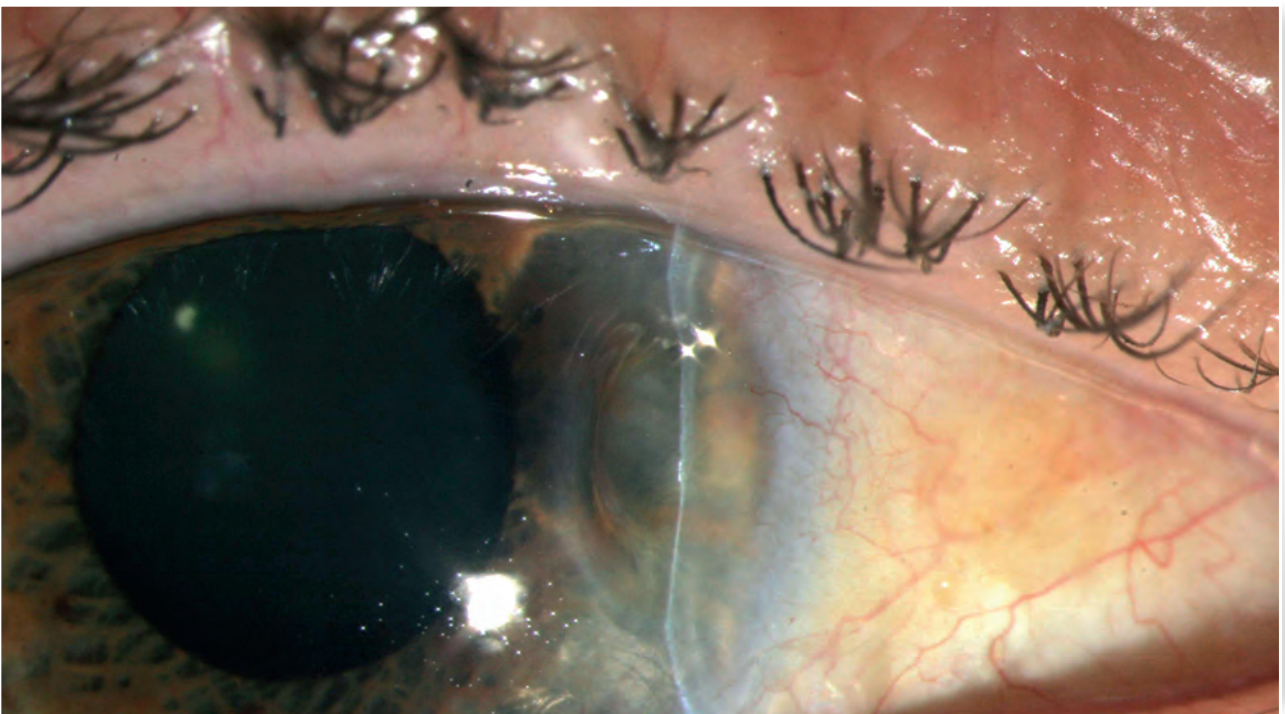
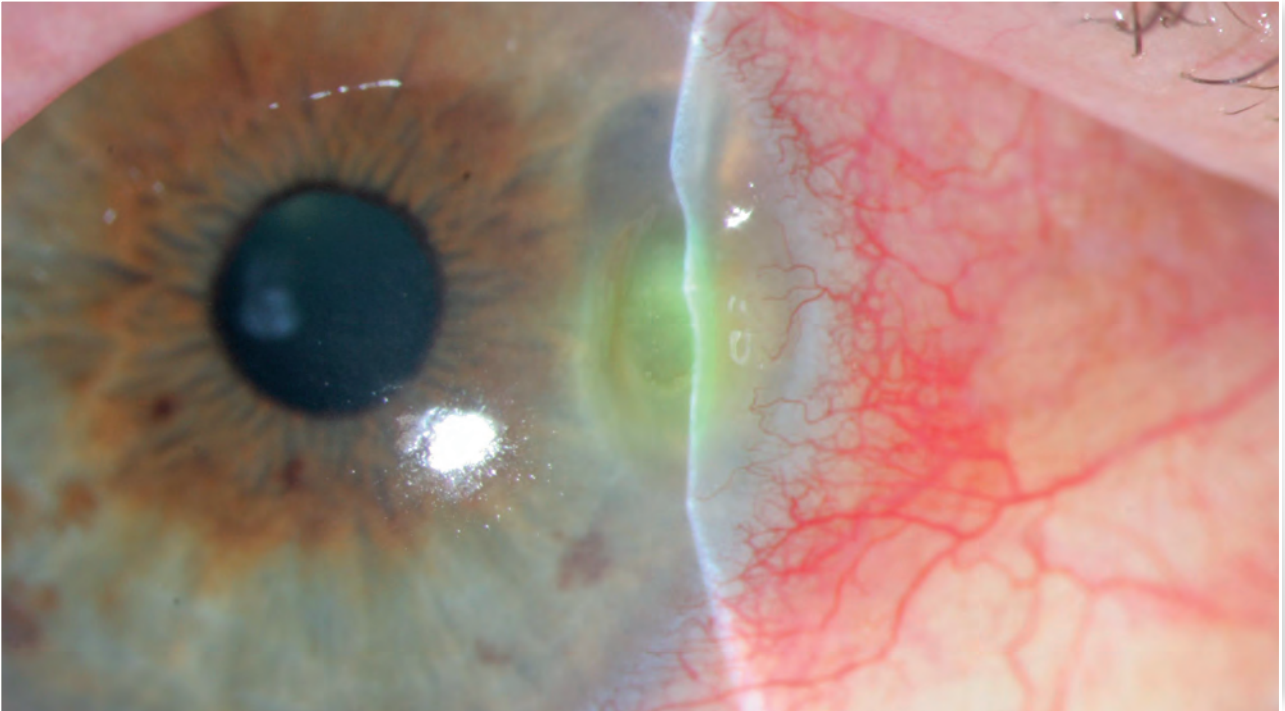
- Classically, a Mooren's ulcer is considered to be more painful than a systemic autoimmune peripheral ulcerative keratitis and is characterized by an overhanging edge at its central border. It is not associated with scleritis. It is a diagnosis of exclusion, which therefore requires the elimination of other conditions that may cause peripheral ulcerative keratitis.



Bilateral Mooren's ulcer.

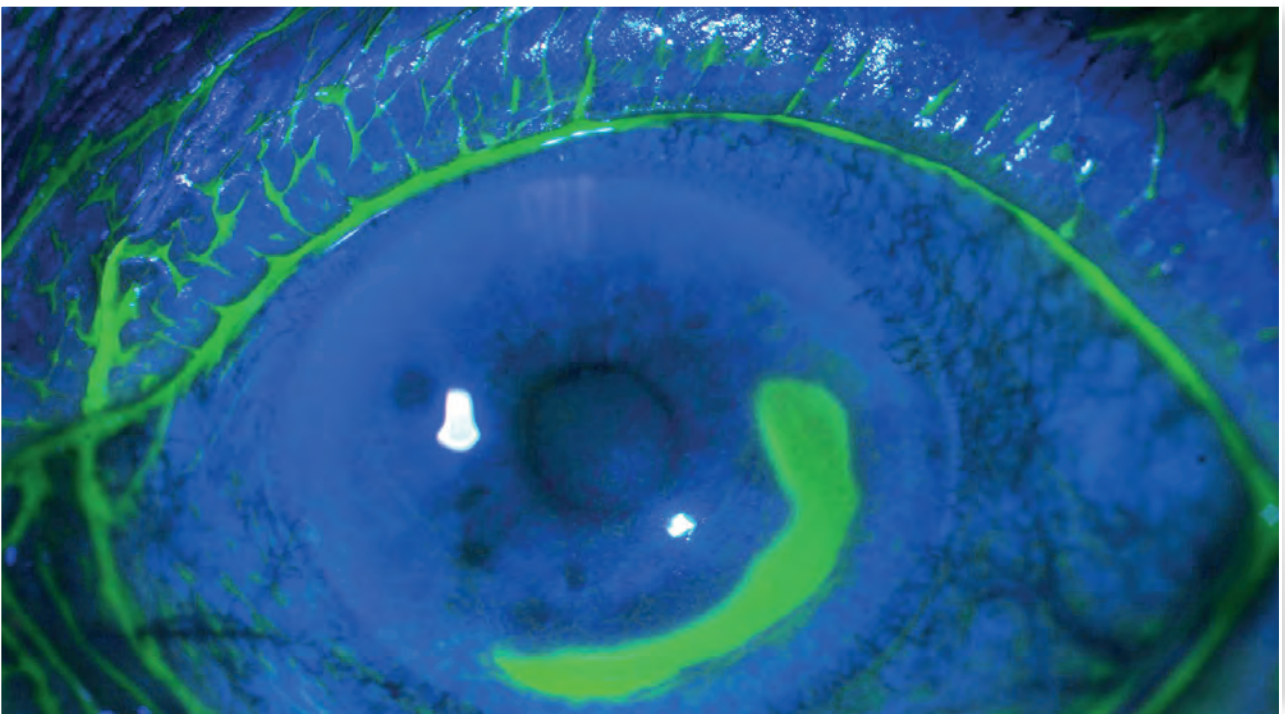
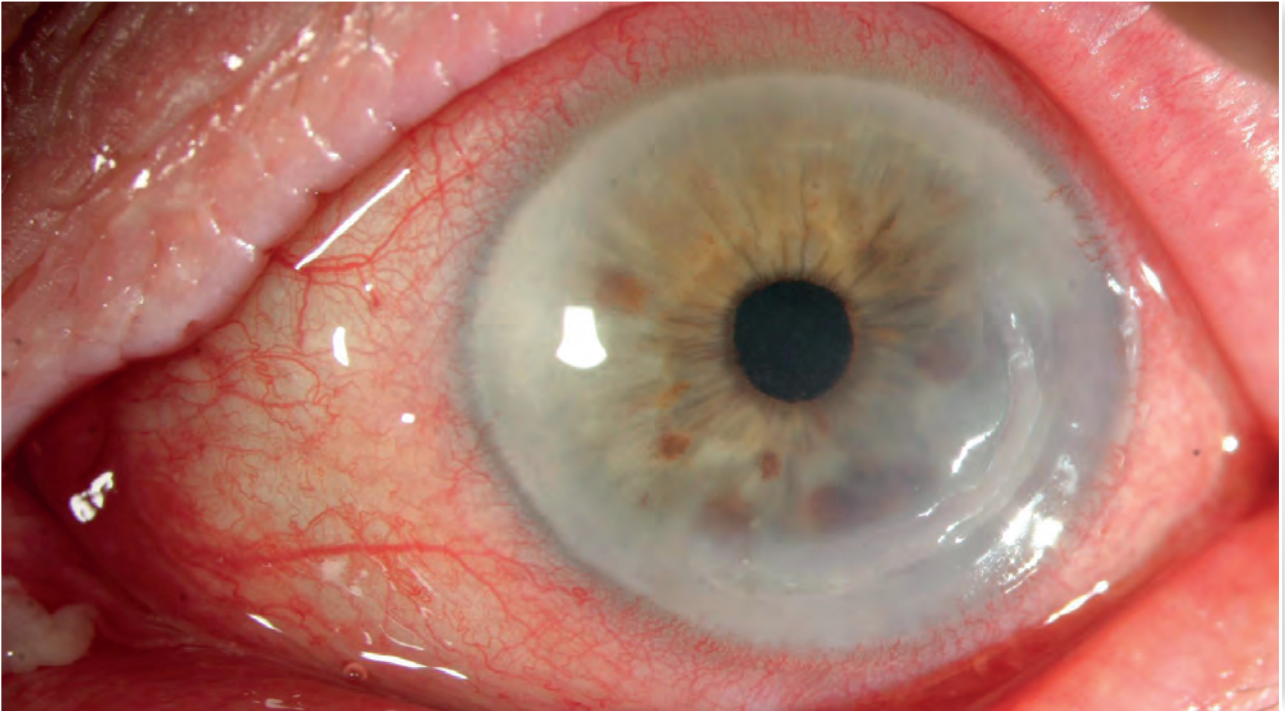
Note the limbal location of the ulcer with an overhanging central edge seen on biomicroscopic examination with the slit beam. The associated limbal injection indicating active disease.

AUTOIMMUNE MARGINAL ULCERS



Mooren's ulcer.

Marginal ulcer of unknown etiology. Favorable clinical course after high-dose topical corticosteroid therapy.

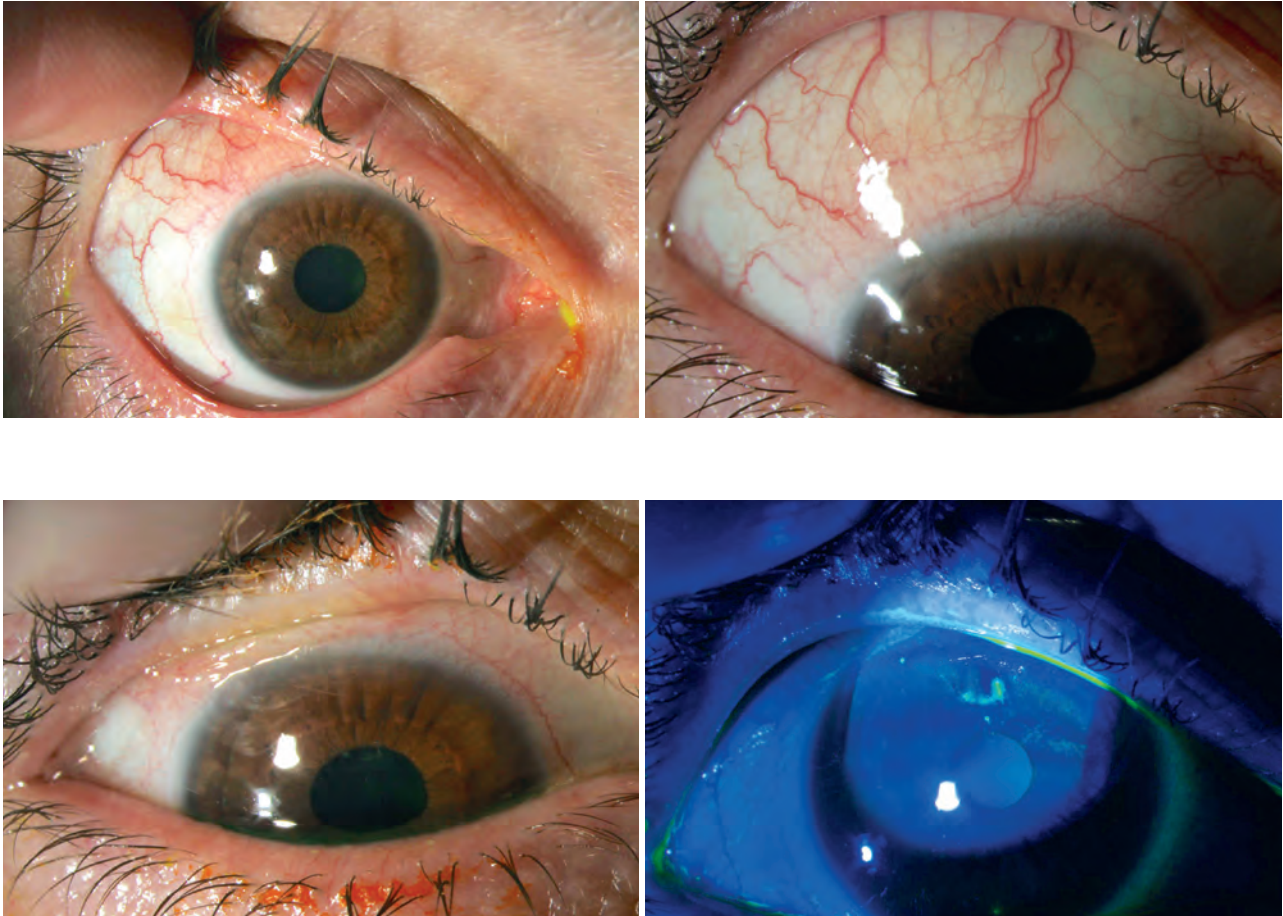


Mooren's ulcer.

Peripheral corneal ulcer in a patient aged 85, with negative workup for underlying systemic diseases. Note the thinning of the inferotemporal cornea and epithelial bow-shaped ulcer, confirmed after instillation of fluorescein.

SUPERIOR LIMBIC KERATOCONJUNCTIVITIS

- **Theodore's superior limbic keratoconjunctivitis (SLK)** is characterised by superior conjunctival hyperaemia. The disease leads more often to a chronic keratitis than an ulceration itself. Patients complain of symptoms of dry-eye or 'burning'. The upper eyelid effectively folds or pleats the upper bulbar conjunctiva, which appears thickened and redundant. The superior bulbar conjunctiva also stains with fluorescein, as does the limbus and the superior cornea. The existence of a superior superficial punctate and filamentary keratitis is highly indicative of this diagnosis. Thyroid dysfunction should also be suspected. The medical treatment is typically preservative free lubricant eye drops. In patients who have failed to respond to medical treatment, surgical superior conjunctival resection can be considered.



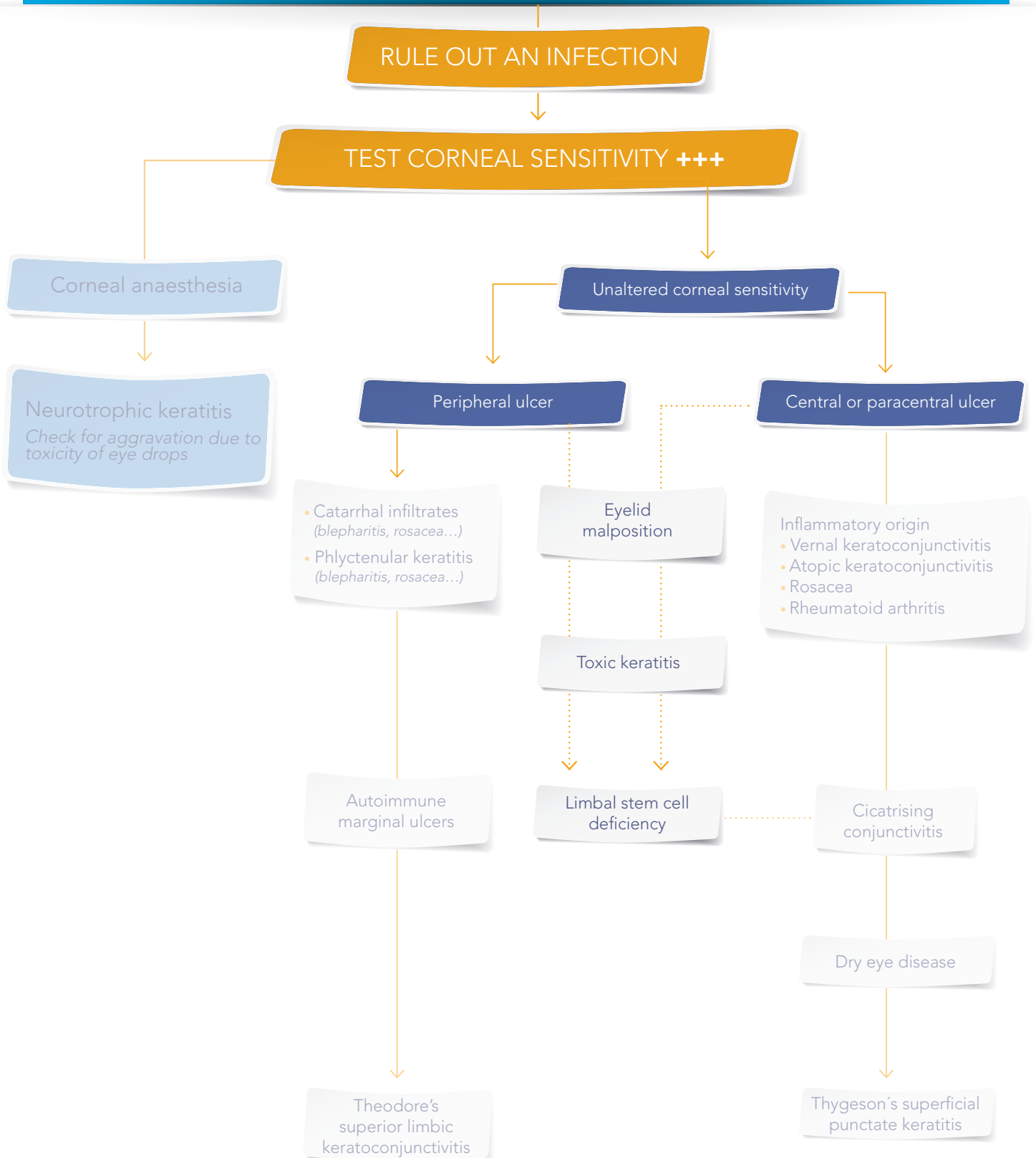
Superior limbic keratoconjunctivitis.

Note here the predominant conjunctival hyperaemia and excess conjunctiva, which folds under the upper eyelid. Note the punctate superficial and upper filamentary keratitis after instillation of fluorescein.

CENTRAL AND/OR PERIPHERAL ULCERS WITH UNALTERED SENSITIVITY

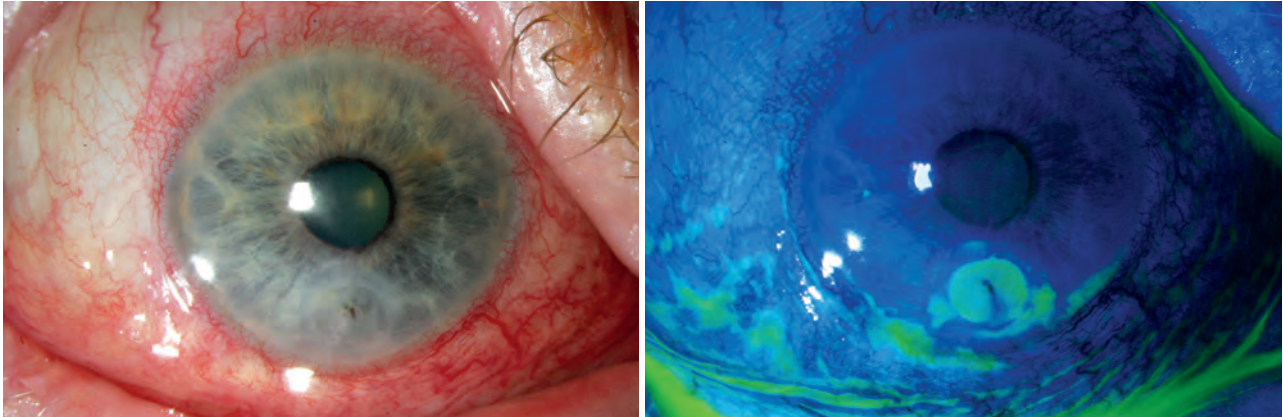
- It is worth remembering that certain condition can cause peripheral and central ulcers with equal frequency. These include eyelid malpositions, toxic keratitis and limbal stem cells deficiency. The latter will be discussed later in the context of central ulcers.

DIFFERENTIAL DIAGNOSIS WHEN FACED WITH KERATITIS OR A CHRONIC ULCER



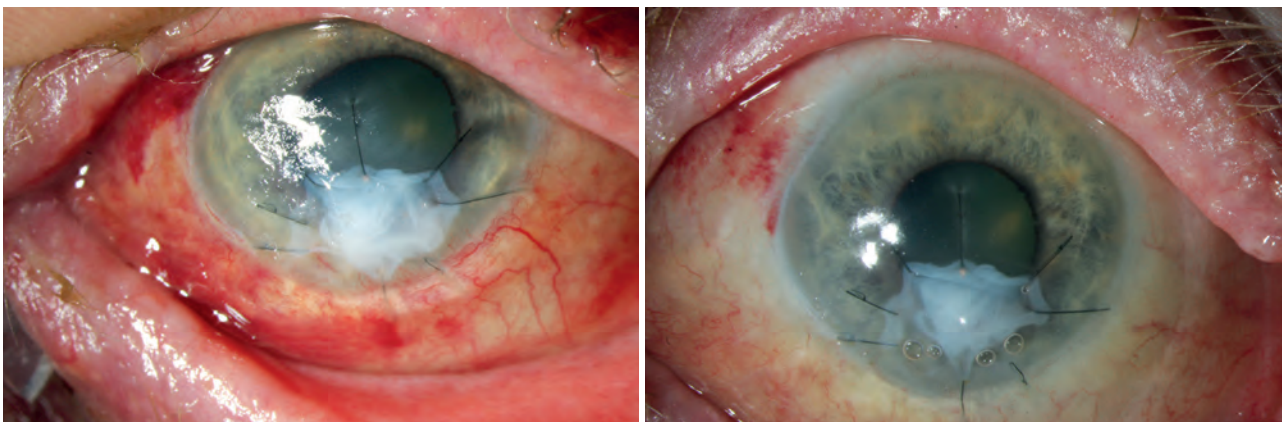
EYELIDS MALPOSITIONS

- The correct anatomic position of the eyelids and their proper closure are necessary for the maintenance of a healthy ocular surface. Any period of eyelid malposition or blinking abnormalities may cause damage to the ocular surface, such as chronic conjunctivitis or keratitis, complicated by ulceration.
- Persistent ectropion and entropion can result in chronic corneal exposure and subsequent ulceration. Similarly lagophthalmos and the less known floppy eyelid syndrome can have a similar effect. Floppy eyelid syndrome is characterised by lax and floppy upper eyelids, which evert easily, especially when sleeping. This leads to chronic conjunctival irritation and keratitis.



Corneal ulcer and floppy eye lid syndrome.

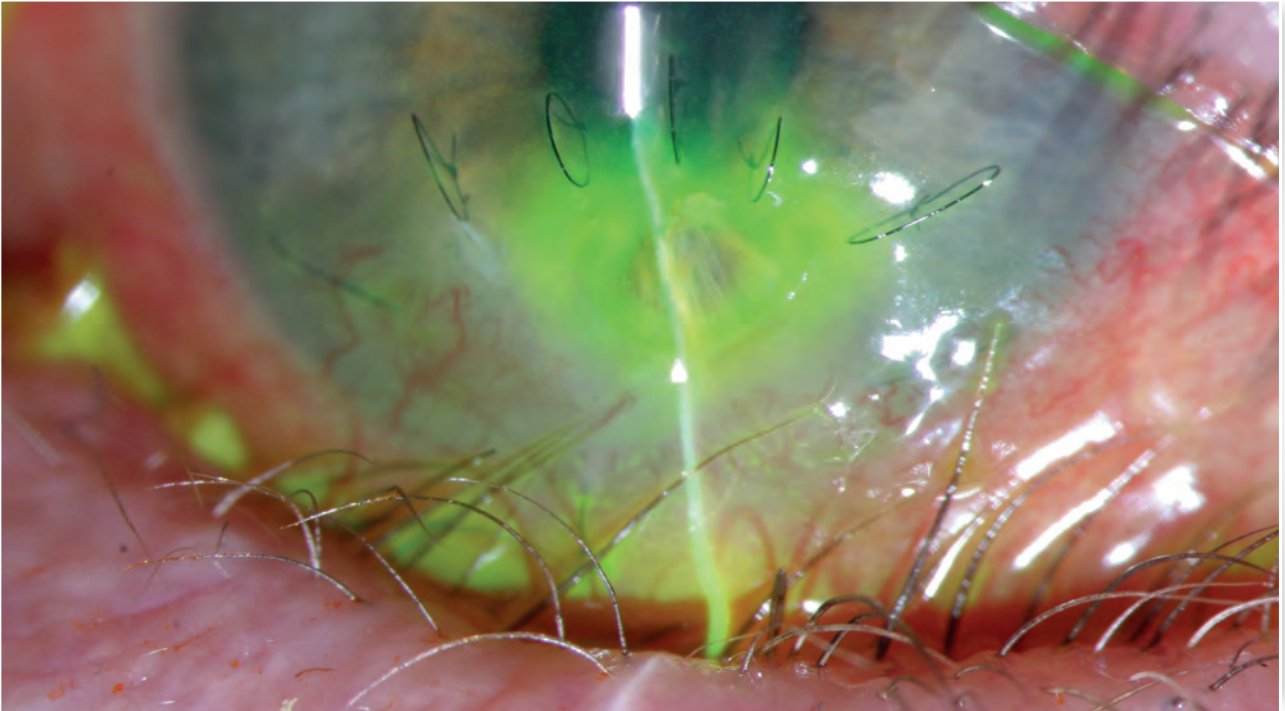
Right chronic ulcer, treated for several weeks, complicated by a perforation.



Corneal ulcer and floppy eyelid syndrome (same patient).

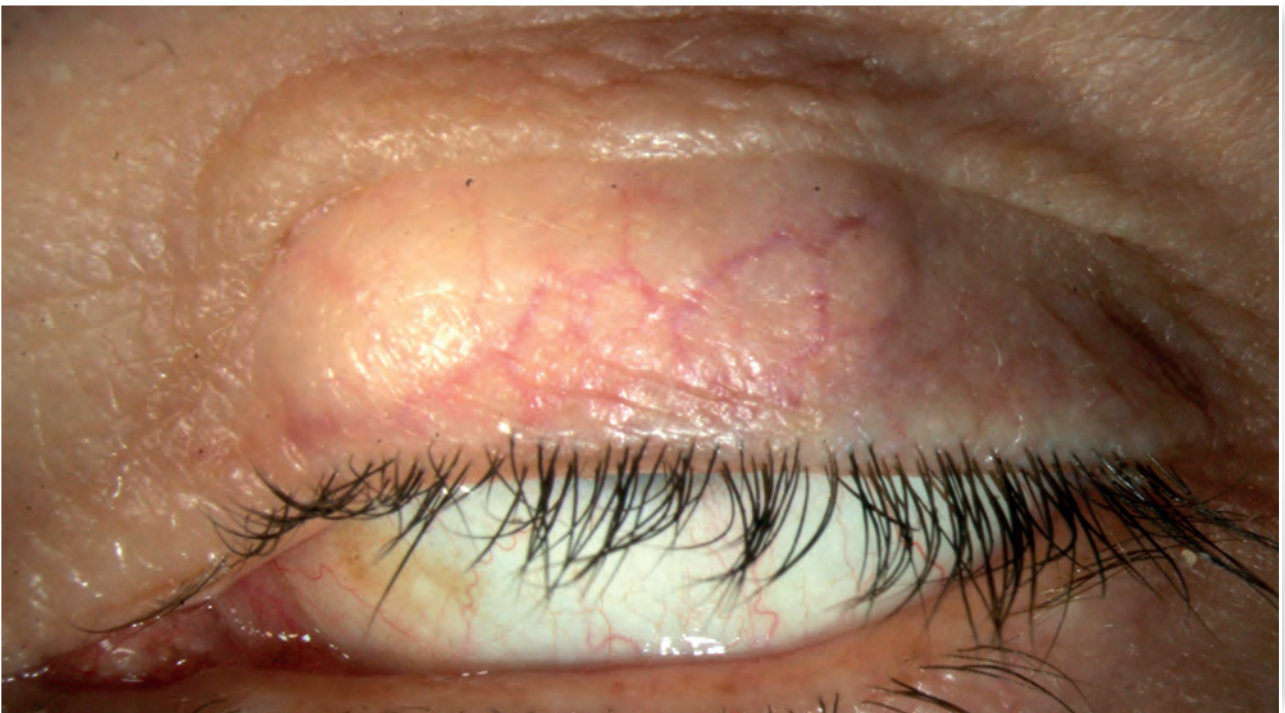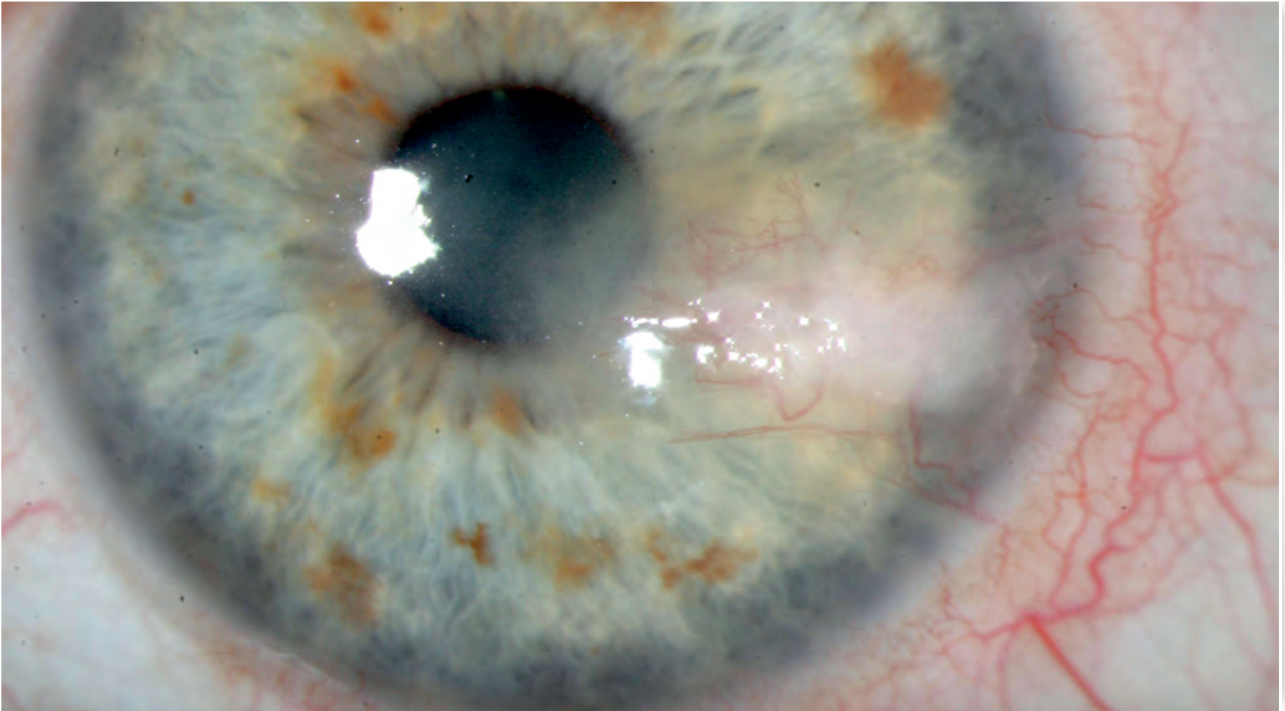
Failure of the first amniotic membrane transplantation due to the loss of contact lens prior to epithelial healing. Favorable clinical course after new multi layered amniotic membrane transplantation associated with tarsorrhaphy, which stopped the nocturnal corneal trauma and maintained the contact lens bandage in place until epithelial healing had occurred.

EYELIDS MALPOSITIONS



Inferior perforated corneal ulcer in a patient with an entropion.

A multi layered amniotic transplantation failed, and the corneal perforation recurred with iris prolapse, requiring an inferior partial conjunctival flap.

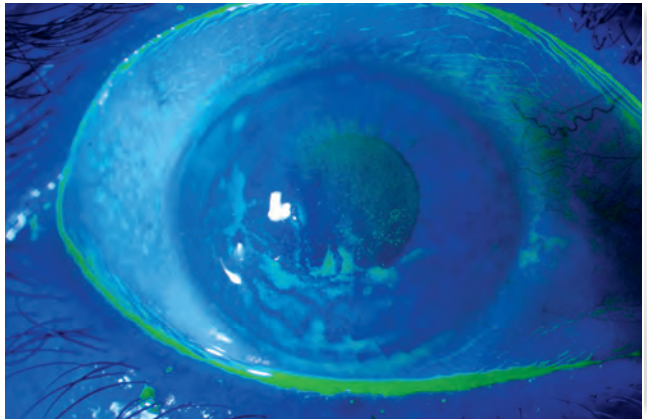
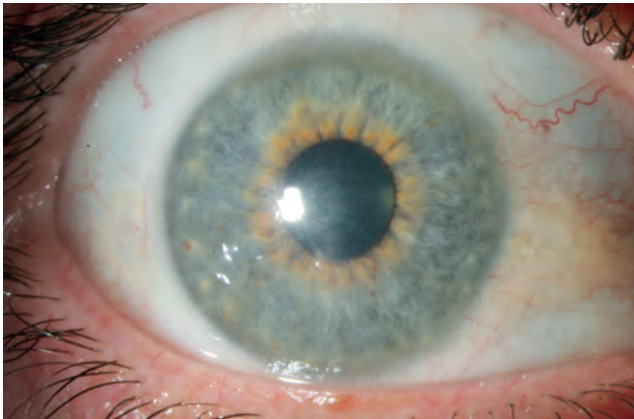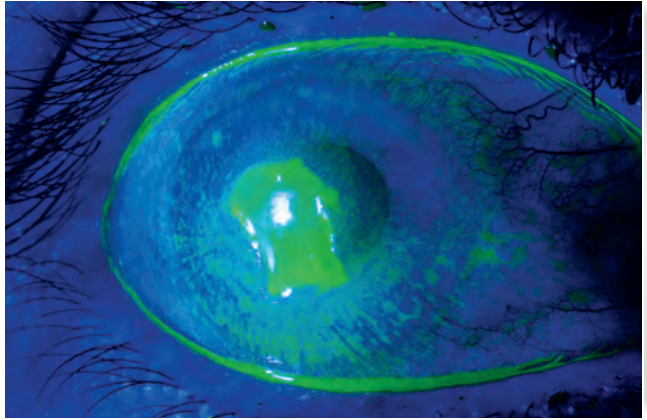
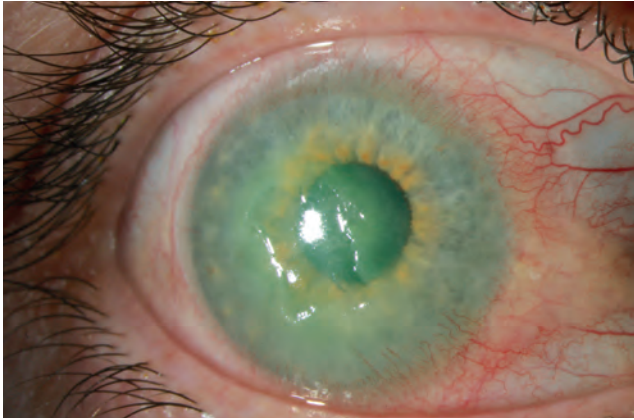


Corneal ulcer and facial paralysis.

Ulceration in an area of corneal exposure and desiccation due to lagophthalmos following post-operative (acoustic neuroma surgery) seventh cranial nerve palsy, which was treated with a gold weight implant to improve eyelid closure. The outline of the implant is discernable through the skin of the upper eyelid.

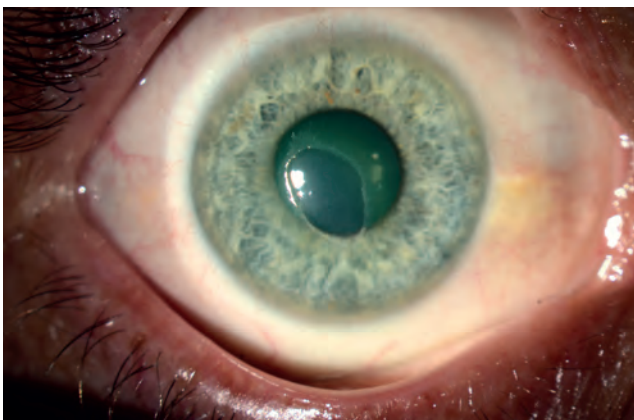TOXIC KERATITIS

- Faced with a chronic ulcer, it is essential to look for a toxic component related to topical medications, possibly instilled by the patient.
- The toxicity of topical medications may be related to the direct effect of the active substance itself or, more commonly, to the associated preservatives. The clinical features of **toxic keratitis** include superficial punctate keratitis, a pseudodendrite mimicking a herpes infection and a stromal ulcer. The signs are predominantly in the inferonasal cornea and are associated with a papillary, and often follicular, conjunctivitis.



Toxic keratitis.

Herpes keratitis treated for several weeks with antiviral eye drops. Epithelial healing occurred after 15 days of discontinuation of toxic and/or preserved topical treatments, but use of preservative-free lubricant eye drops was continued.



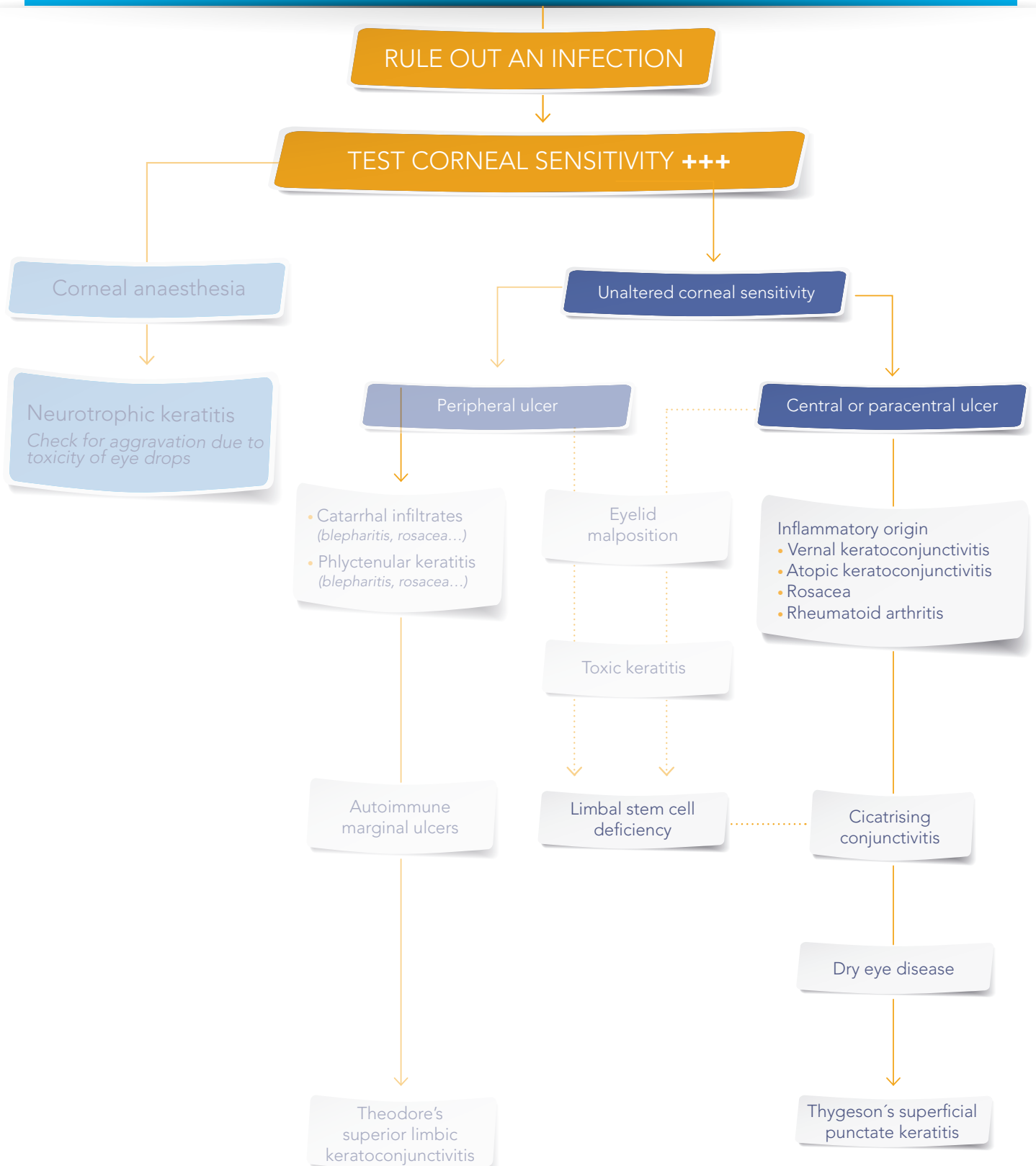
Toxic keratitis.

Delayed epithelial healing following cross-linking for keratoconus.

CENTRAL OR PARACENTRAL ULCERS WITH UNALTERED SENSITIVITY

- By this stage, working down the algorithm, infection and neurotrophic keratitis (as corneal sensitivity is preserved) have been eliminated as causes and the location of the ulcer is central or paracentral.

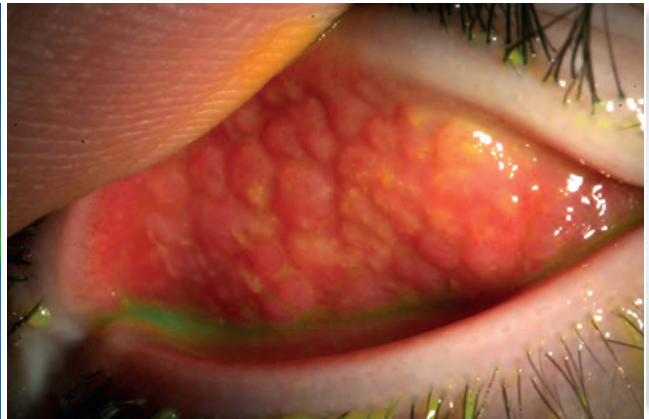
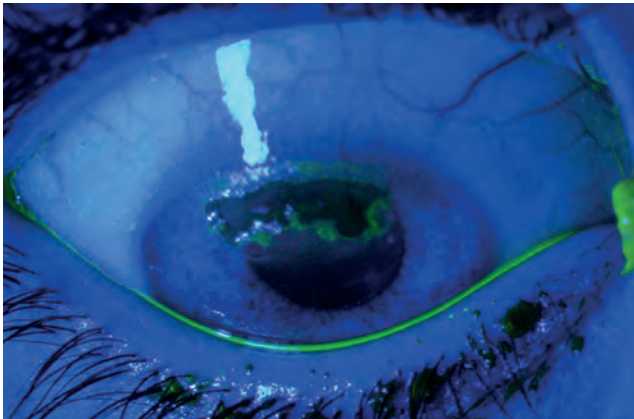
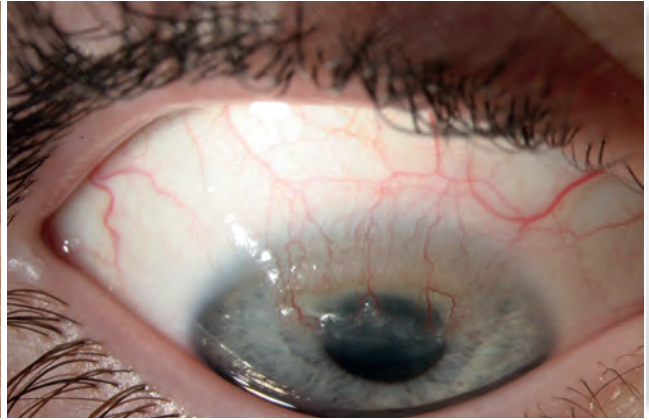
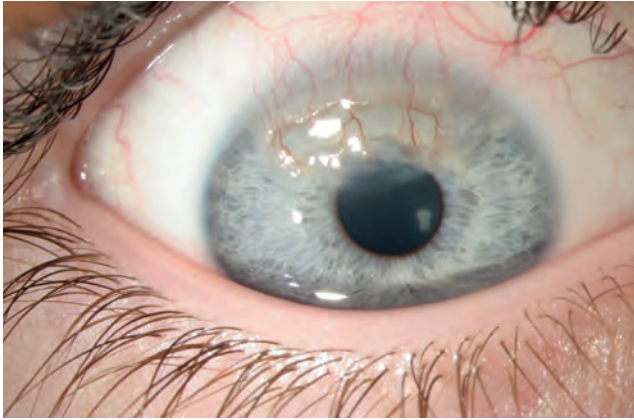
DIFFERENTIAL DIAGNOSIS WHEN FACED WITH KERATITIS OR A CHRONIC ULCER



VERNAL KERATOCONJUNCTIVITIS

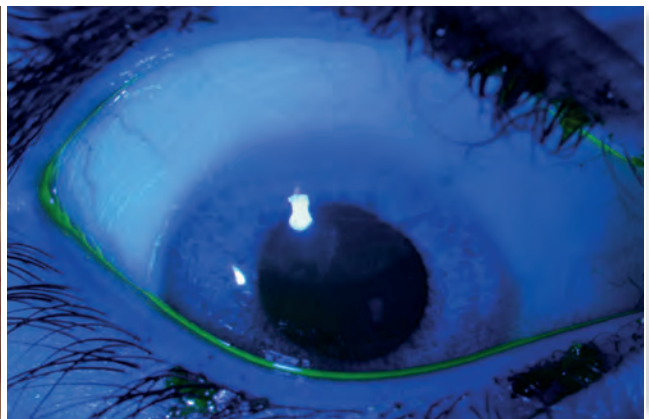
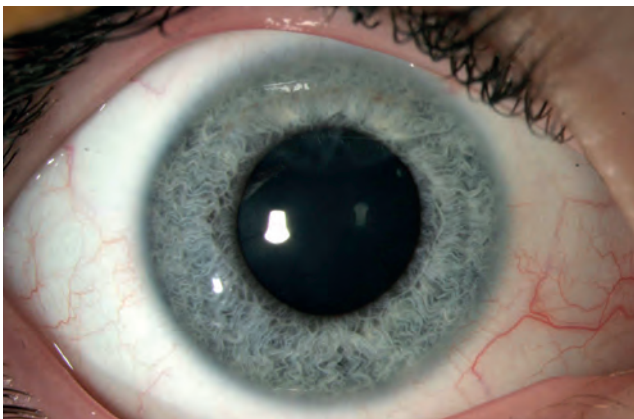
- **Vernal keratoconjunctivitis** is a severe form of ocular allergy⁸. Evolution is perennial with exacerbation during the spring and summer. The aggravating factors are normally allergens, but Sun and heat may also be involved. Allergic and atopic factors are found in half of all cases.
- The eyelids have a typical appearance, characterised by giant papillae (> 1mm) in the upper tarsal conjunctiva, causing eyelid thickening, which may give the appearance of pseudo-ptosis. The limbic form is characterised by a diffuse or sectorial translucent limbal gelatinous hyperplasia, in which it is possible to identify white nodules called Horner-Trantas dots, consisting of clusters of eosinophils.
- **Corneal complications** are more common in the palpebral form. They originate partly from a mechanical friction by the giant papillae, but also from toxicity and inflammation induced by released mediators. Clinical examination may reveal a superficial punctate keratitis, an epithelial ulcer (usually single) located at the junction of the upper third and the middle third of the cornea (shield ulcer) or a vernal plaque from aggregation of the mucus and epithelial secretions deposits over the epithelial defect, delaying or impairing healing. A vernal plaque can sometimes result in a neovascularised stromal scar if poorly managed.

8. De Smedt S, Wildner G, Kestelyn P. Vernal keratoconjunctivitis: an update. Br J Ophthalmol. 2013;97:9-14.



Corneal features in vernal keratoconjunctivitis.

Vernal plaque complicating a case of vernal keratoconjunctivitis, in a young boy aged 7 with history of atopy. Neovascularisation and cellular debris deposits are visible in the ulcer bed. Note the fluorescein staining and upper tarsal cobblestones.



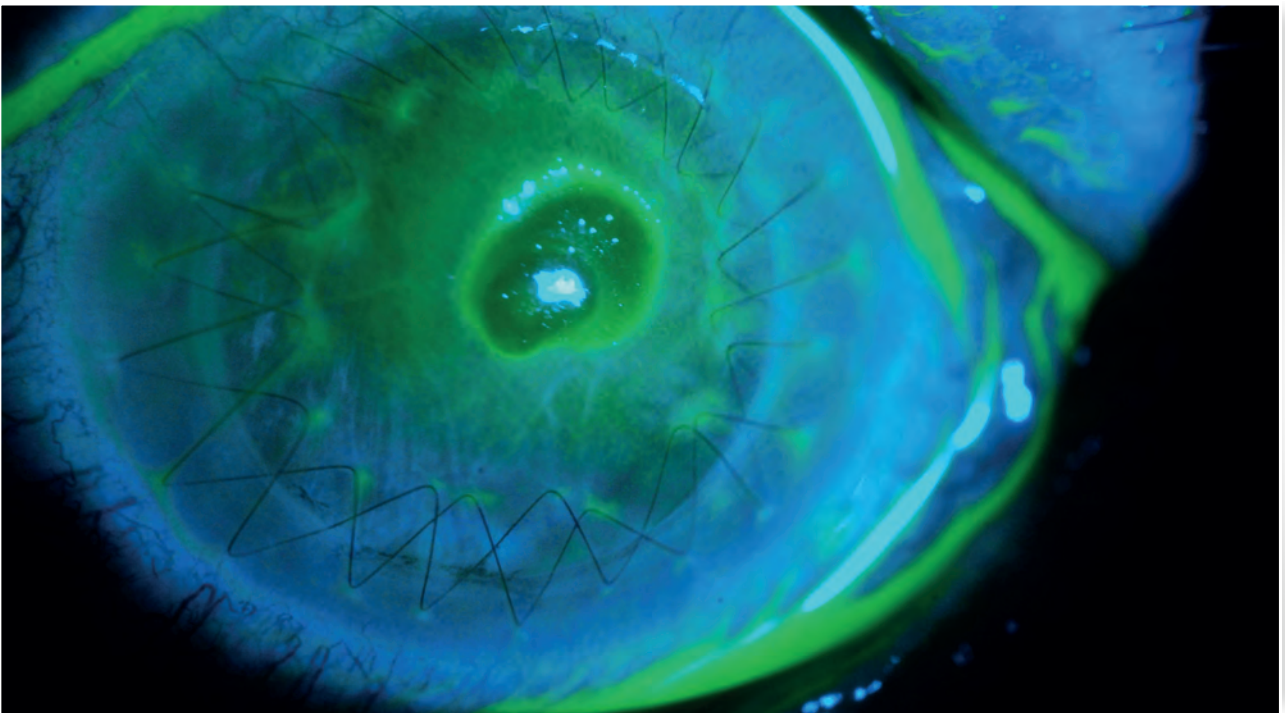
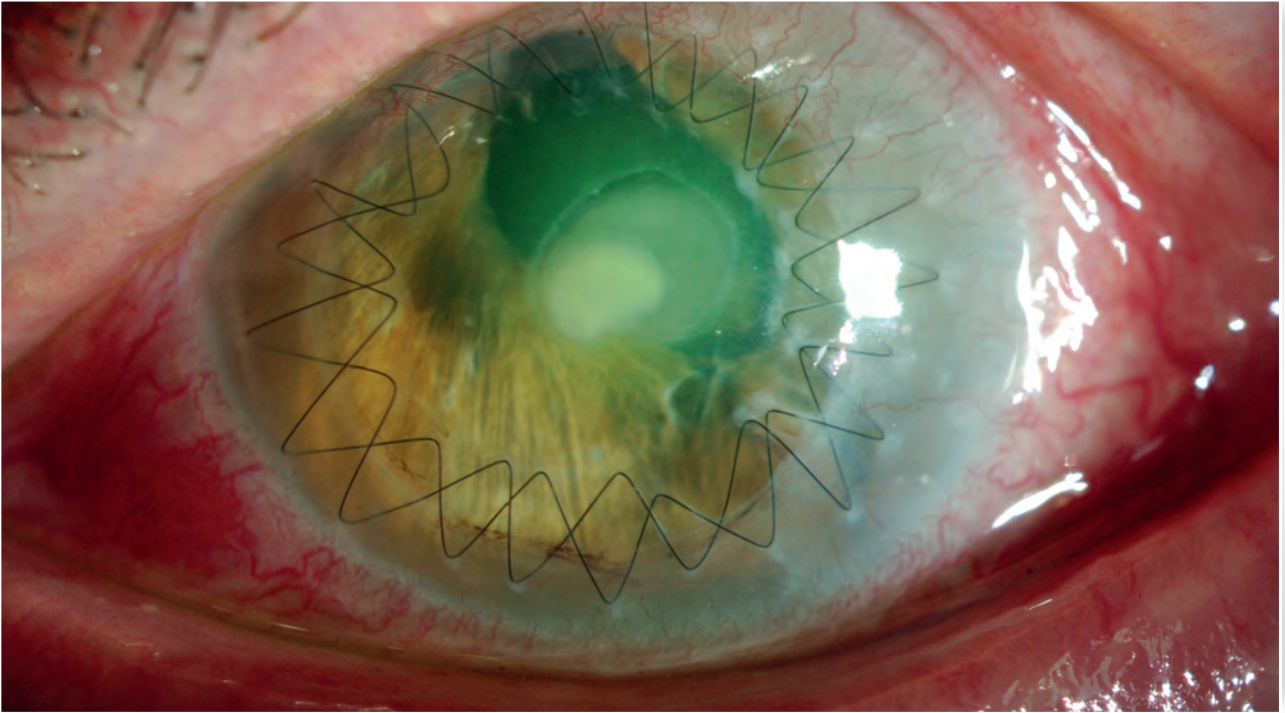
Corneal features in vernal keratoconjunctivitis (same patient).

Appearance 15 days following scraping of the plaque associated with high-dose topical steroid therapy.

ATOPIC KERATOCONJUNCTIVITIS

- **Atopic keratoconjunctivitis (AKC)** is a severe, chronic and bilateral keratoconjunctivitis occurring in patients suffering from atopic dermatitis, or with other manifestations of atopy such as asthma. Corneal lesions form constantly and are potentially sight-threatening. AKC is rare (<1% of patients suffering from ocular allergies), with a peak incidence between the ages of 30 and 50, predominantly in males. It is essential to establish a personal and/or family history of atopy to reach the diagnosis⁹.
- Corneal involvement manifests as superficial punctate keratitis, persistent epithelial defects, and occasionally a plaque, as in vernal keratoconjunctivitis, and corneal neovascularisation.

9. Creuzot-Garcher C. Les différentes formes cliniques de l'allergie conjonctivales. J Fr Ophtalmol. 2007;30:288-91.

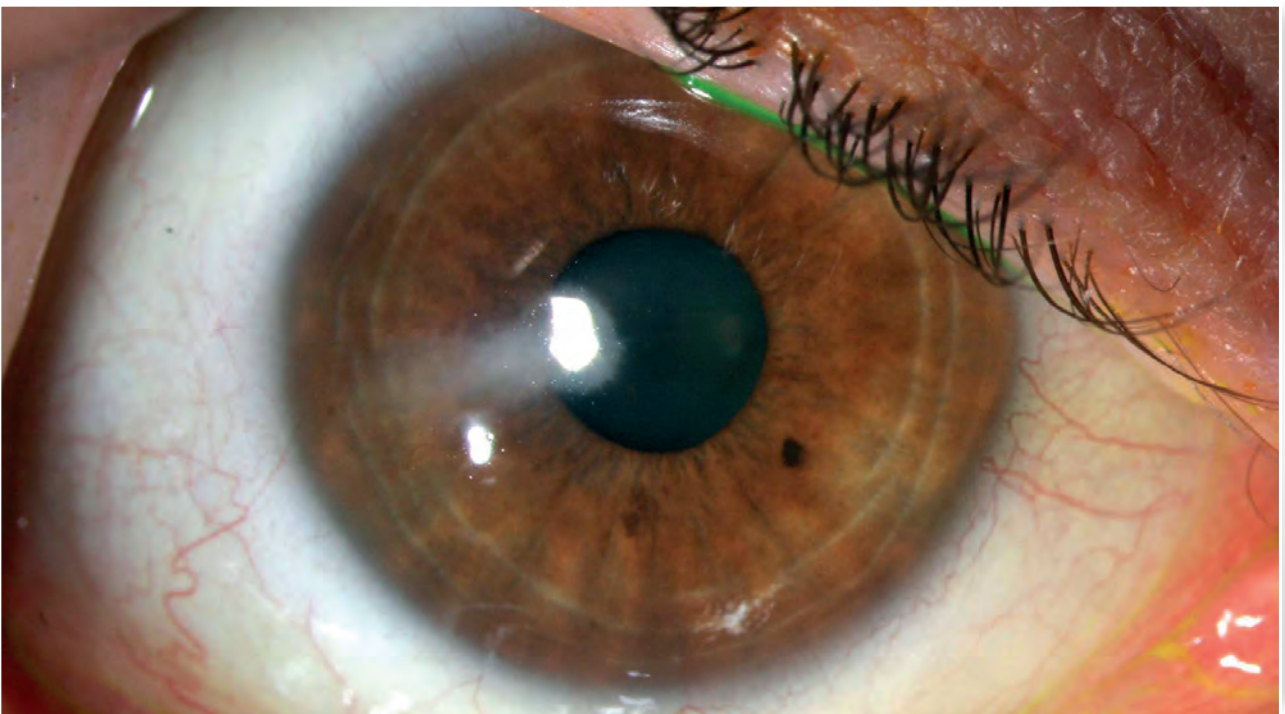
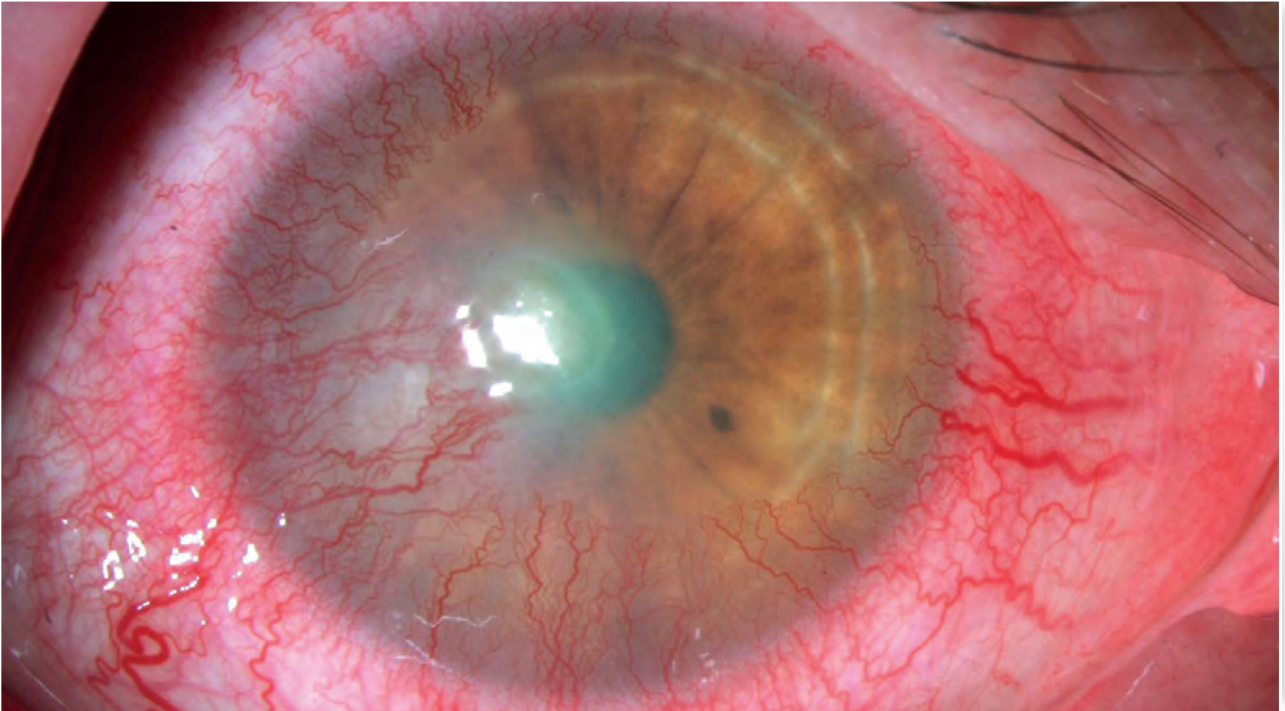


Corneal ulcer in atopic keratoconjunctivitis.

Relapsed corneal ulcer, similar to a vernal plaque, in a corneal graft. The patient had severe atopic keratoconjunctivitis.

ROSACEA (CENTRAL INVOLVEMENT)

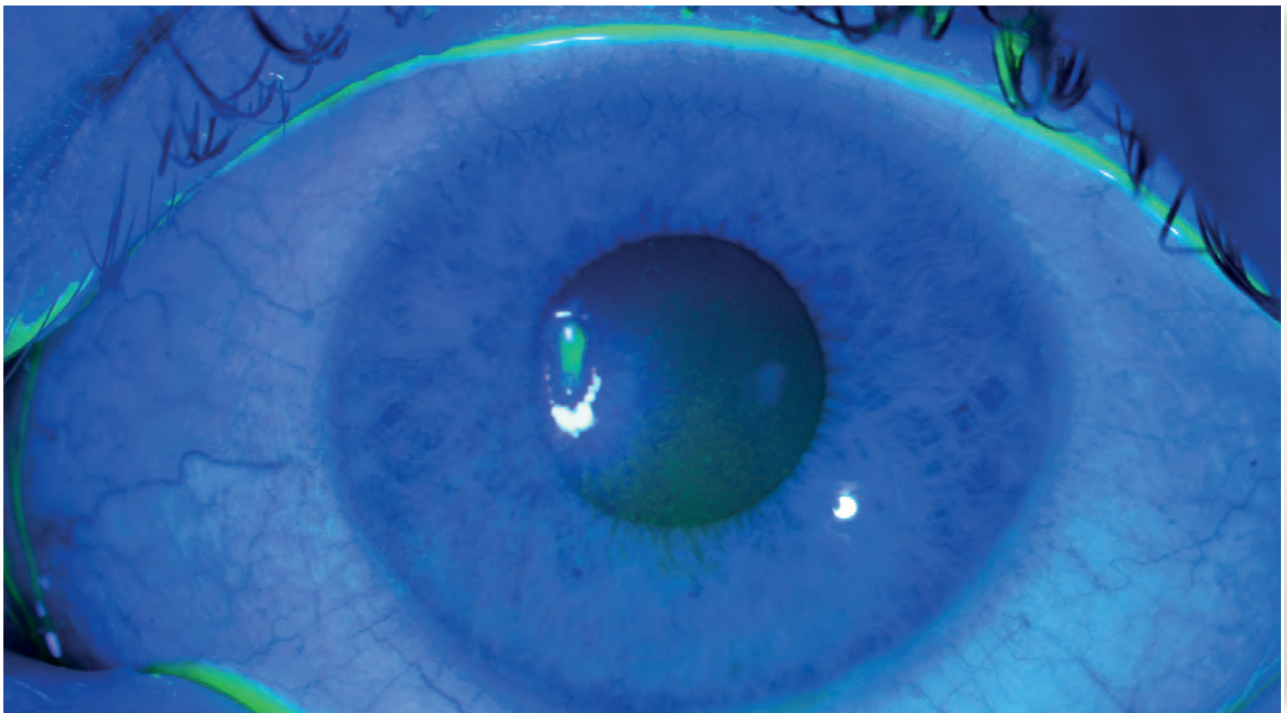
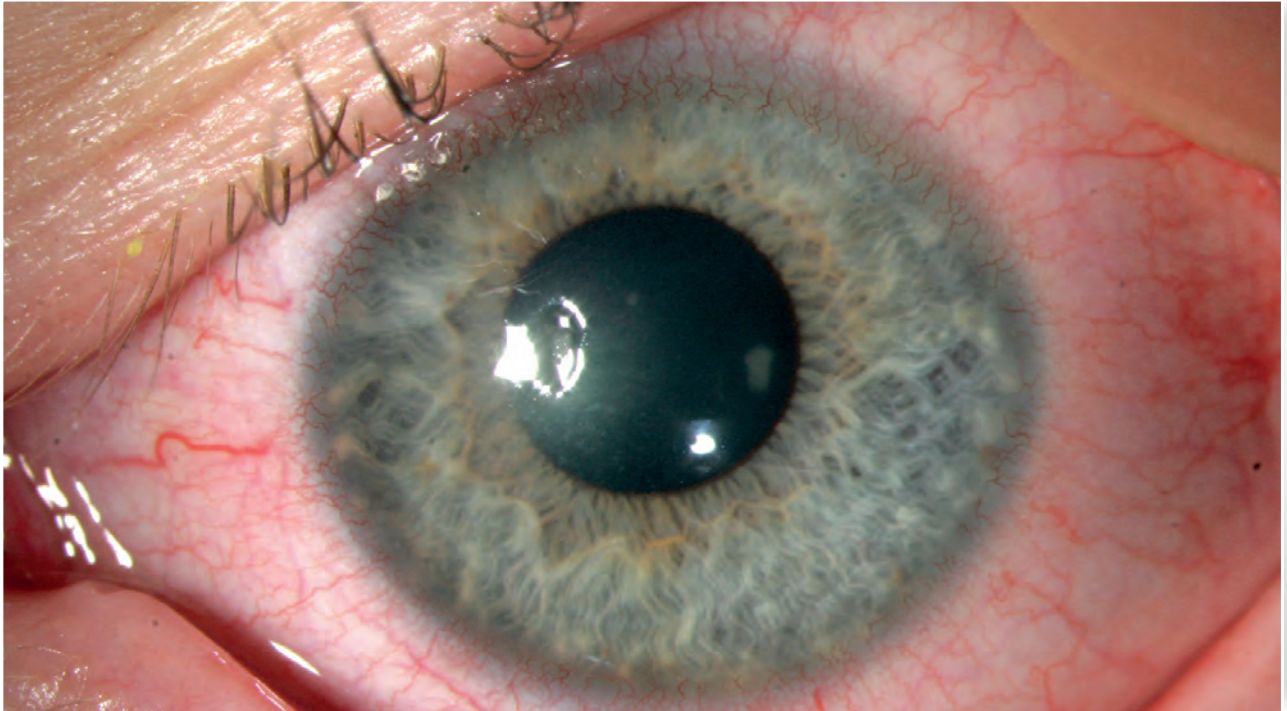
- Corneal phlyctenules found in rosacea are most often located near the limbus (see peripheral ulcers and phlyctenular keratitis). However, they may sometimes be distributed on the surface of the cornea and so cause a central or paracentral ulcer. Furthermore, successive recurrences of phlyctenules at the central edge of the previous one, may result in an ulcer near the center and limit visual acuity due to the induced stromal scar and neovascularisation.



Central corneal involvement in rosacea.

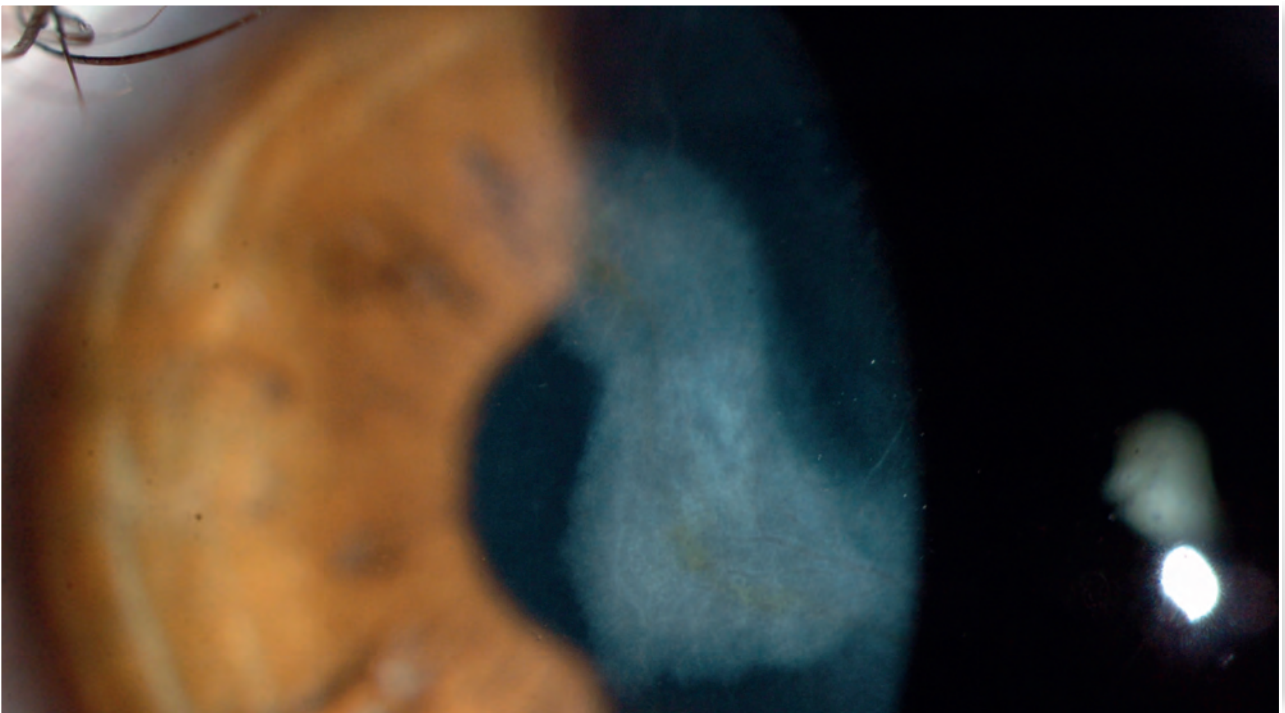
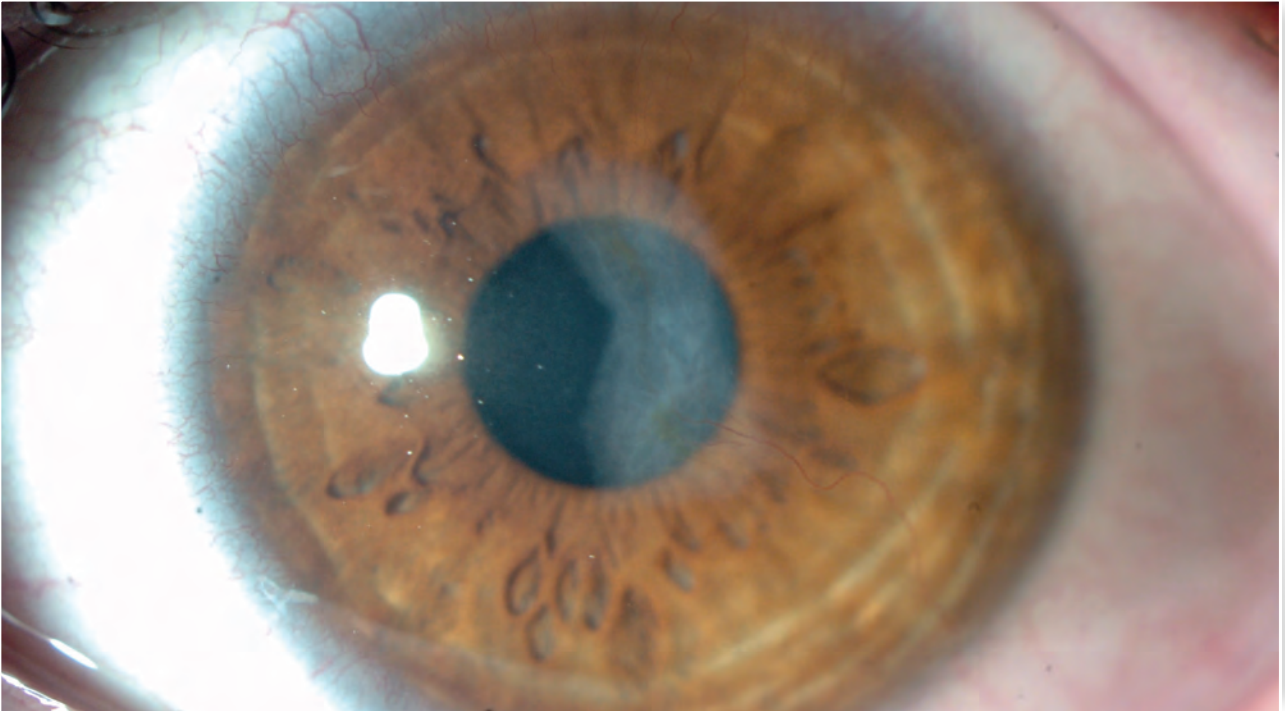
Phlyctenular keratoconjunctivitis in a patient aged 30. Note the central corneal phlyctenule at the extremity of the corneal neovascularisation. Note the appearance after topical corticosteroid therapy followed by therapy with steroid sparing agents (visual acuity measured at 20/25).

ROSACEA (CENTRAL INVOLVEMENT)



Paracentral corneal involvement in rosacea.

Child aged 10 with a history of multiple chalazia. Left paracentral ulcer showed rapid improvement with antibiotic/steroid eye drops.

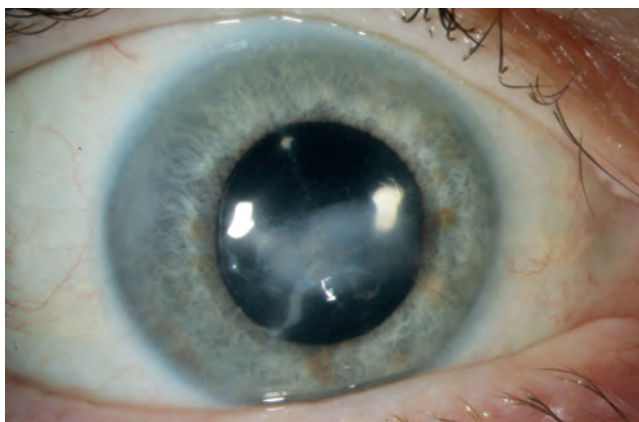
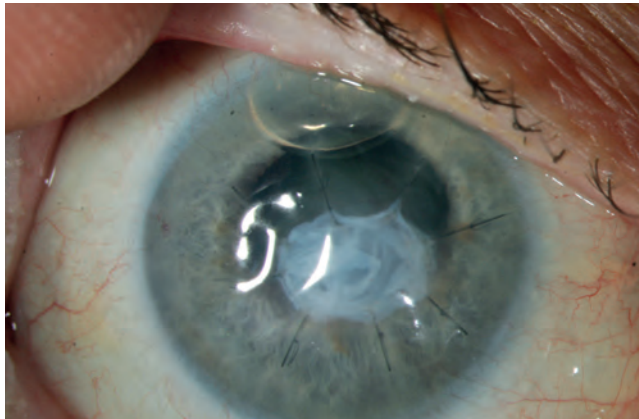
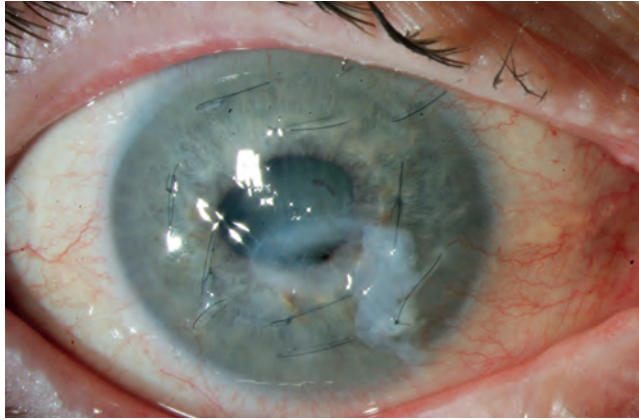


A central scar in phlyctenular keratoconjunctivitis.

Note the scar and the central thinning, as well as the inferior inactive neovascularisation.

KERATOLYSIS AND RHEUMATOID ARTHRITIS

- The corneal complications of rheumatoid arthritis can also be centrally located. Epithelial instability induced by keratoconjunctivitis sicca and associated systemic inflammation are both potential factors that could initiate the process of thinning and corneal perforation.
- Management of central ulcers associated with rheumatoid arthritis is challenging. Topical steroid therapy remains controversial. Systemic therapy is often required for effective healing.

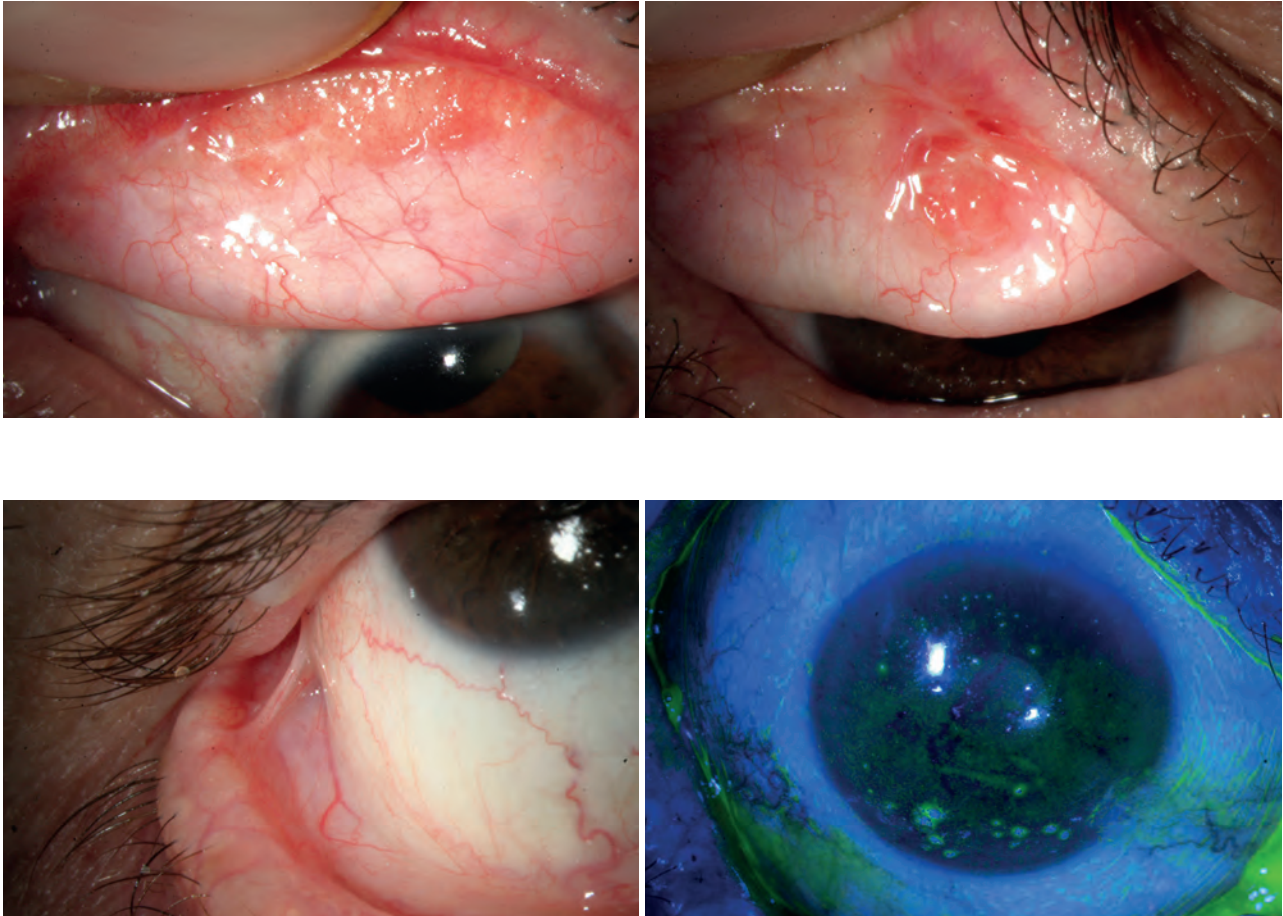


Keratolysis in rheumatoid arthritis.

Failure of an amniotic membrane transplantation performed for central keratolysis. Favorable clinical course after a second multi layered amniotic membrane transplantation and systemic steroid therapy. Appearance at 7 days and at 9 months after cataract surgery.

CICATRISING CONJUNCTIVITIS

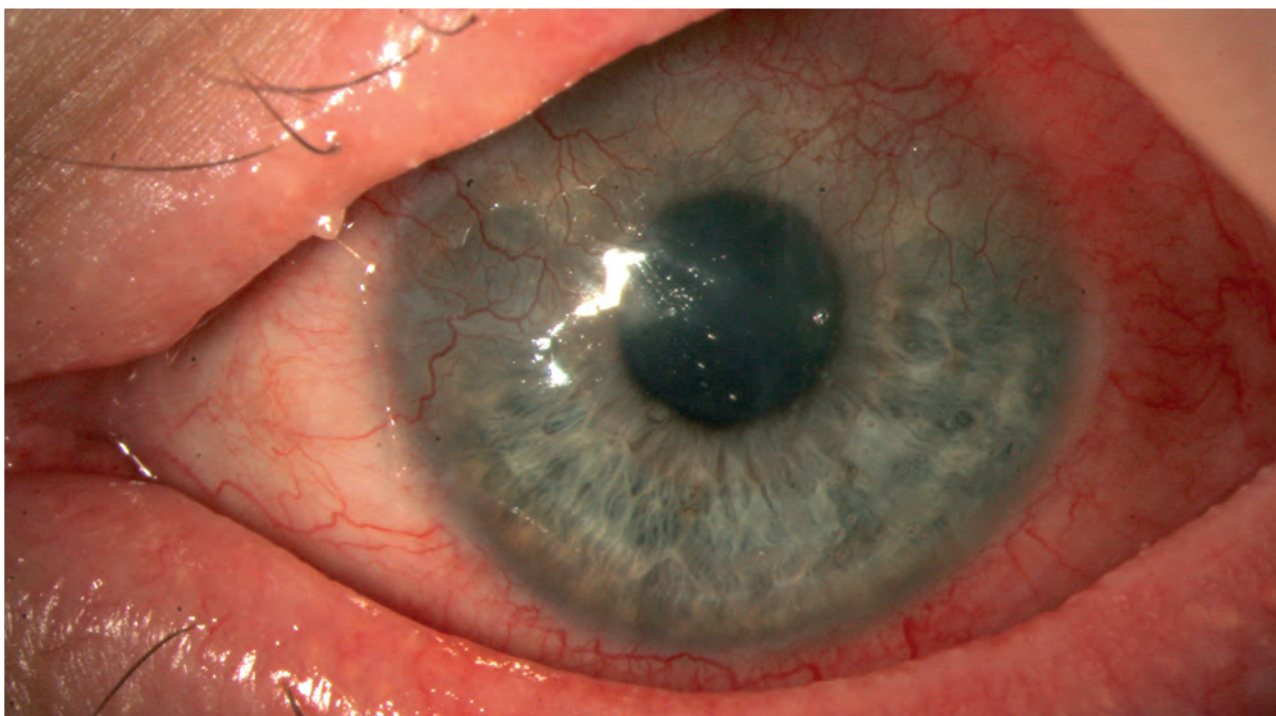
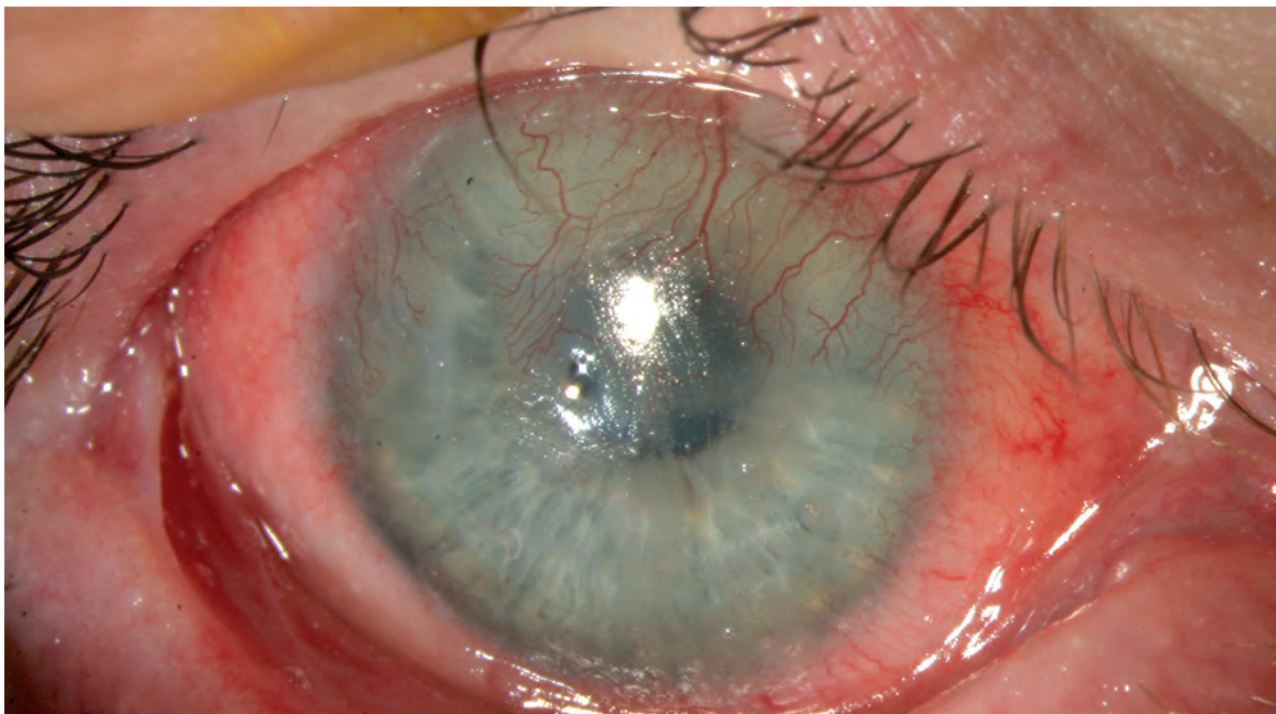
- **Cicatrising conjunctivitis** is characterised by chronic inflammation with progressive scarring, which can result in major alterations of the ocular surface (keratoconjunctivitis sicca, eyelids malpositions, symblepharon and corneal neovascularisation) that are potentially sight-threatening.
- Some causes of cicatrising conjunctivitis can present with an obvious clinical history such as **Stevens-Johnson's and Lyell's syndromes** (also named toxic epidermal necrolysis), or other less well known conditions such as **intolerance to eye drops** or cicatrising conjunctivitis associated with **severe atopy** or **ocular rosacea**. In other cases, the clinical setting is less suggestive, such as those associated with **autoimmune bullous dermatosis**, as in **ocular cicatricial pemphigoid**. Theoretically, any cause of chronic inflammation of the conjunctiva can cause conjunctival scarring.



Cicatrising conjunctivitis and ocular cicatricial pemphigoid.

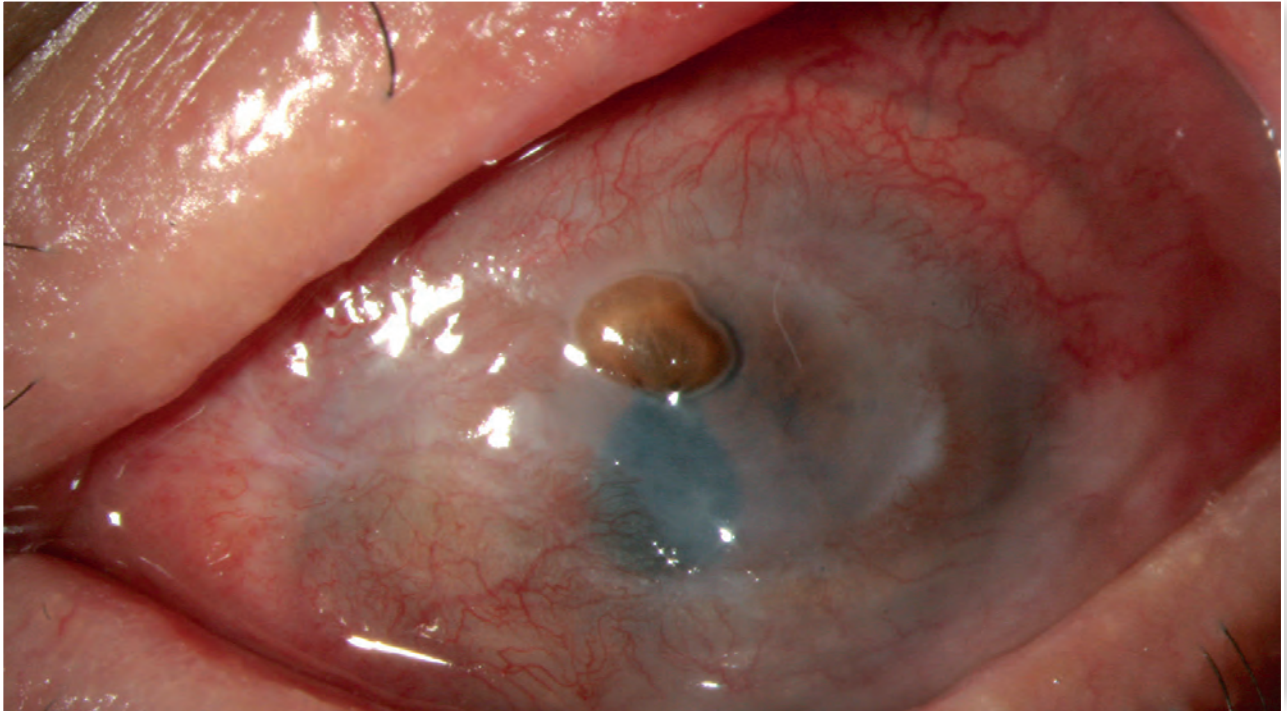
Note the conjunctival fibrosis visible in the superior tarsal conjunctiva as linear or stellate, whitish streaks, and the symblepharon in the right lateral canthus. Note the corneal involvement consisting in chronic superficial punctate keratitis.

CICATRISING CONJUNCTIVITIS



Toxic epidermal necrolysis.

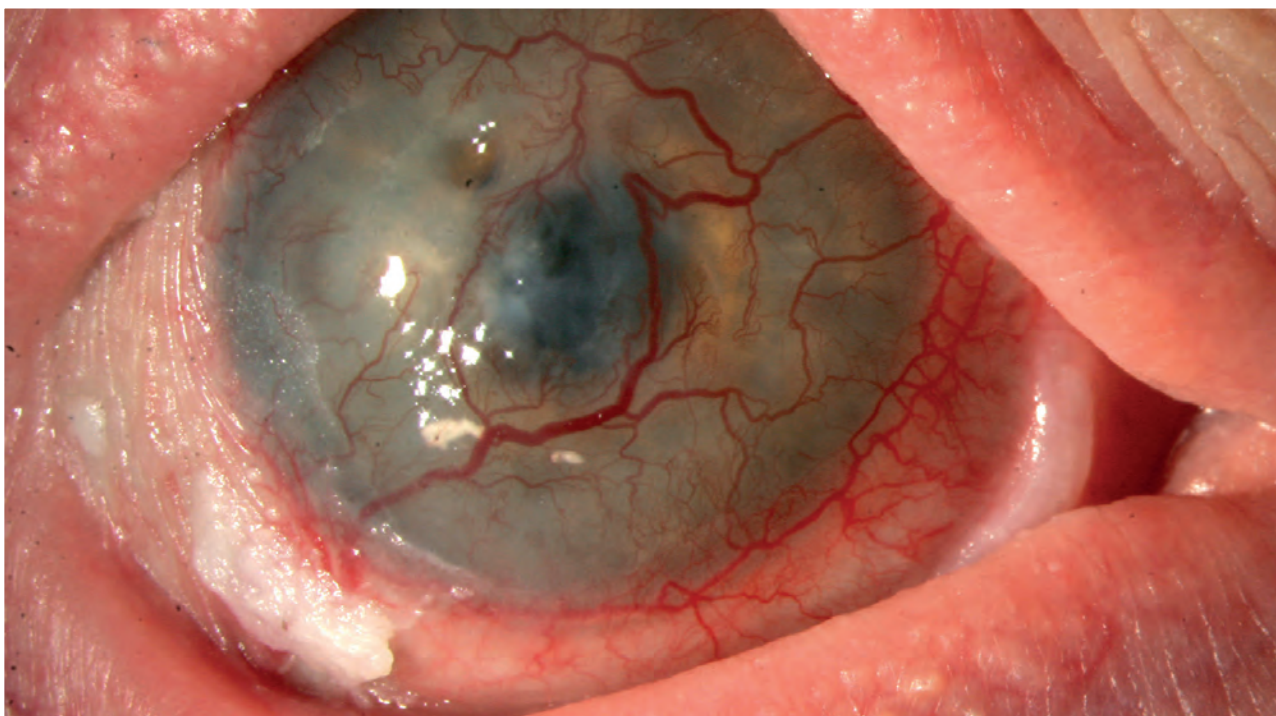
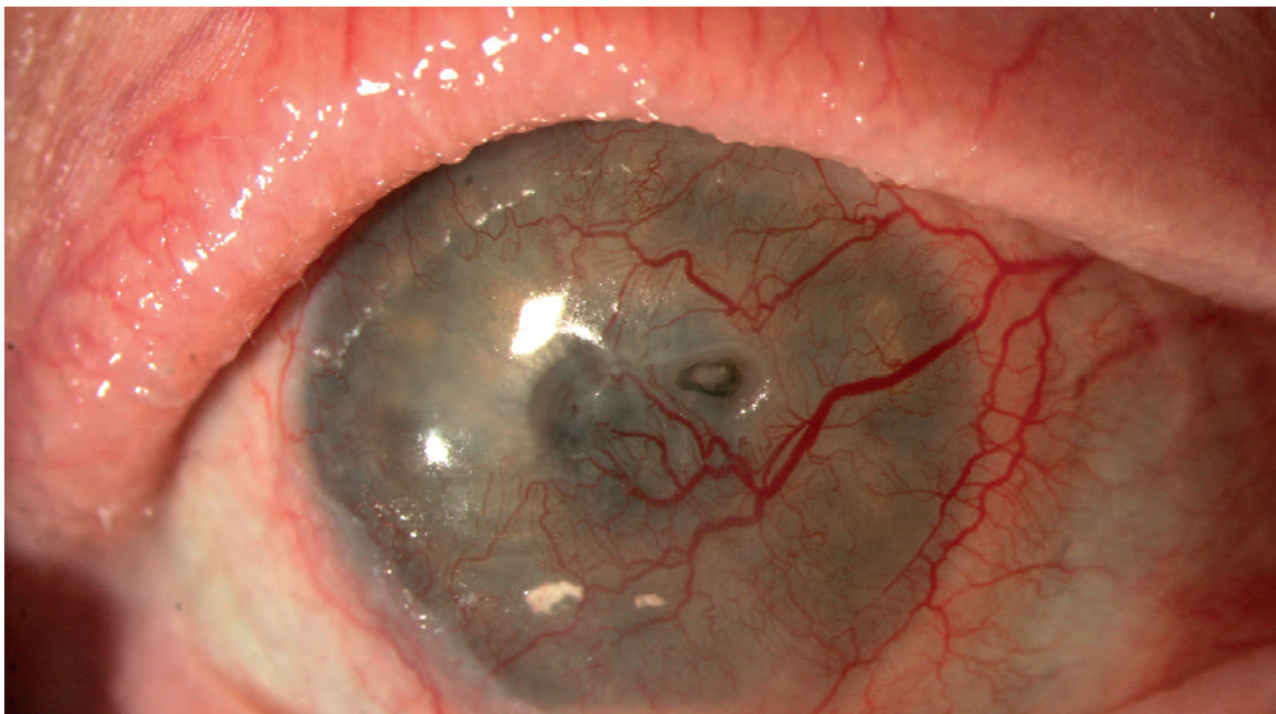
Patient aged 20 who presented with ophthalmologic sequelae of toxic epidermal necrolysis. Note the bilateral superior corneal neovascularisation (right eye and left eye).



Corneal complications of cicatrizing conjunctivitis.

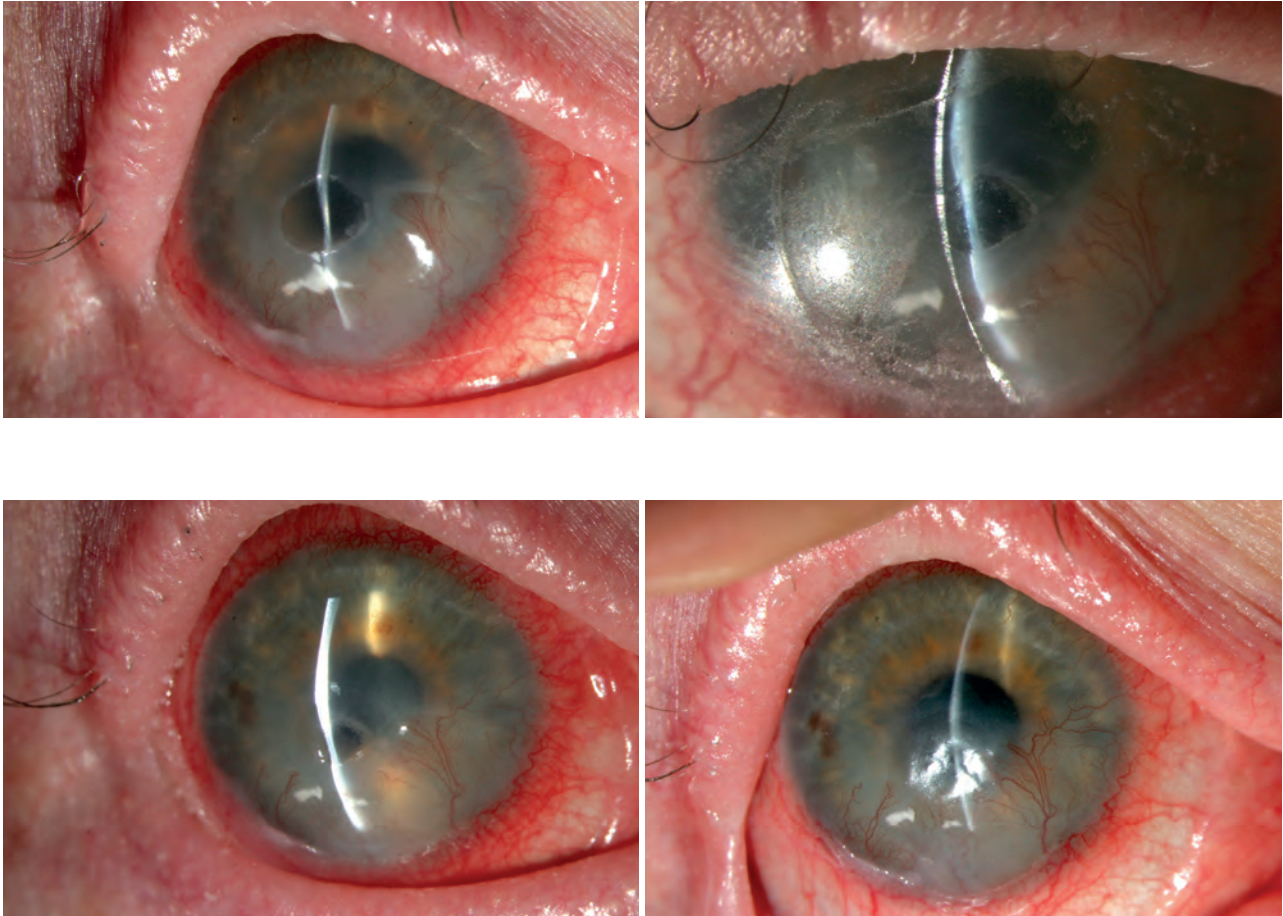
Corneal perforation with iris prolapse in a case of erythema multiforme.

CICATRISING CONJUNCTIVITIS



Sequelae related to toxic epidermal necrolysis.

Recurrent corneal ulcers in the same patient. Note the progression of keratinisation of the bulbar conjunctiva.



Toxic epidermal necrolysis and scleral contact lenses.

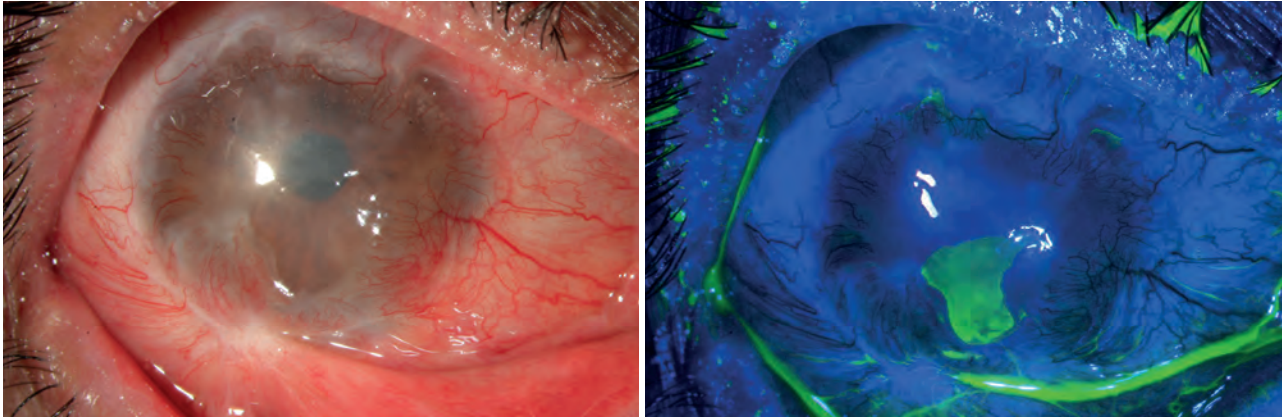
The use of scleral contact lenses offers a therapeutic alternative for these patients. Scleral contact lenses provide mechanical protection to the cornea by restricting the adverse effects of friction from conjunctival fibrosis and misdirected eyelashes. They enhance corneal hydration by maintaining a permanent liquid space between the cornea and the contact lens. Note here epithelial healing achieved after scleral lens fitting.

OTHER LIMBAL STEM CELL DEFICIENCIES

- In limbal stem cell deficiency, the renewal ability of corneal epithelium is impaired, thus promoting regeneration from the adjacent conjunctival epithelium. The corneal surface is invaded and covered by the conjunctival epithelium and thus changes its phenotype. This situation can occur in several pathological conditions and that lead to **limbal stem cell deficiency**. However, as cell differentiation is the result of the interaction of a group of cells and their microenvironment, any change to the corneal microenvironment (stroma and tear film), such as a chronic stromal keratitis, may itself cause an epithelial phenotype change and lead to the appearance of limbal stem cell insufficiency. Clinically, this manifests as «conjunctivalisation» of the cornea.

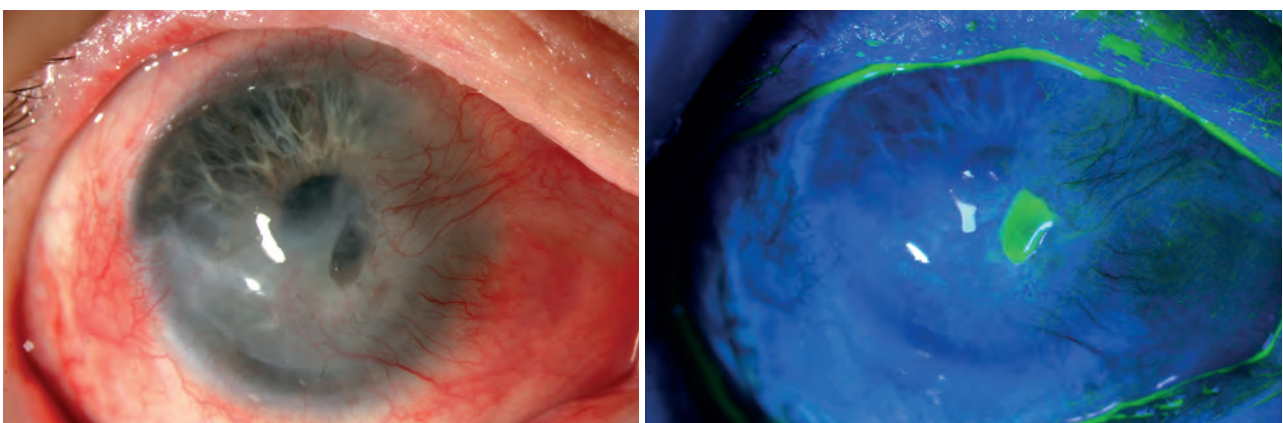
The main causes of limbal stem cell deficiency are:

- Chemical or thermal burn of the ocular surface.
- Immunological or inflammatory, following Stevens-Johnson syndrome or toxic epidermal necrolysis, ocular cicatricial pemphigoid, graft *versus* host disease and inflammatory diseases of the limbus.
- Postoperative, following major surgical resection of the limbus.
- Anoxic complications, related to extended wear of contact lenses.
- Post-infectious, following severe chronic keratoconjunctivitis (trachoma, herpes ...).
- Congenital, eg. aniridia.



Limbal stem cell deficiency after chemical burn.

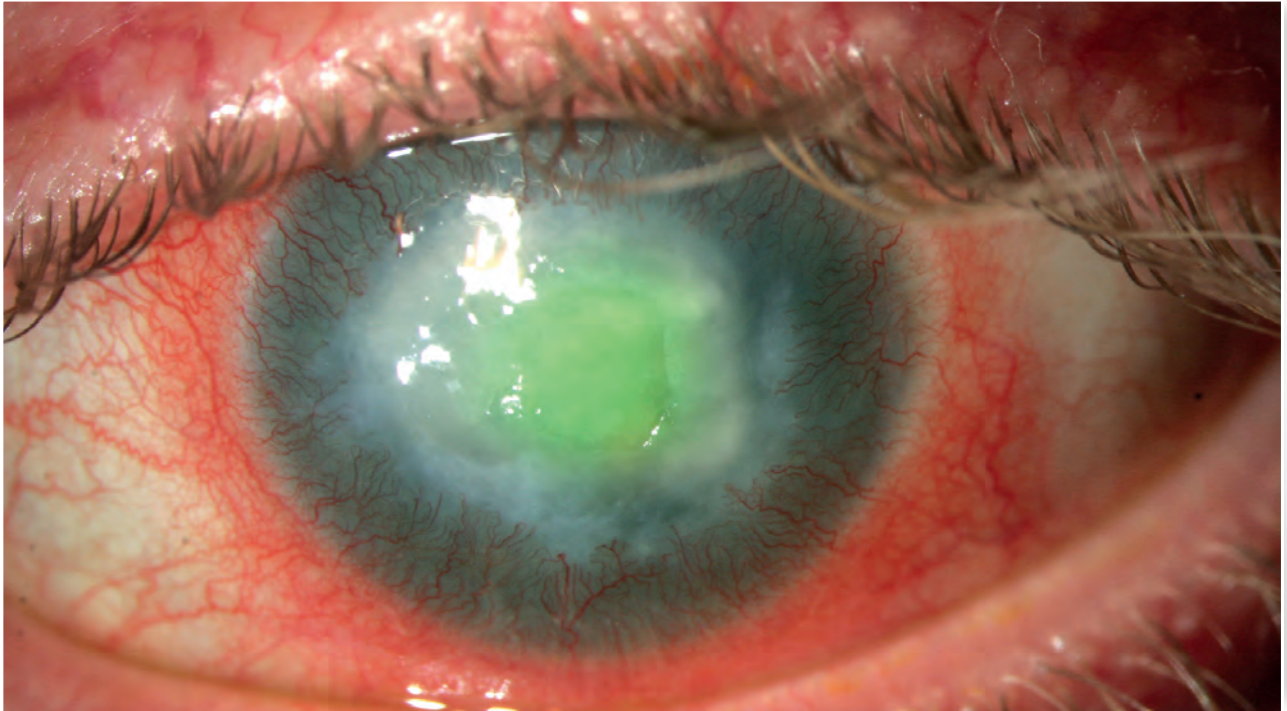
Clinical appearance at 8 months after alkali burn. The epithelial surface is more opaque and variable in thickness. Note the fibrovascular pannus on the cornea and the persistent corneal epithelial defect.



Limbal stem cell deficiency.

Chronic stromal corneal ulcer after alkali burn.

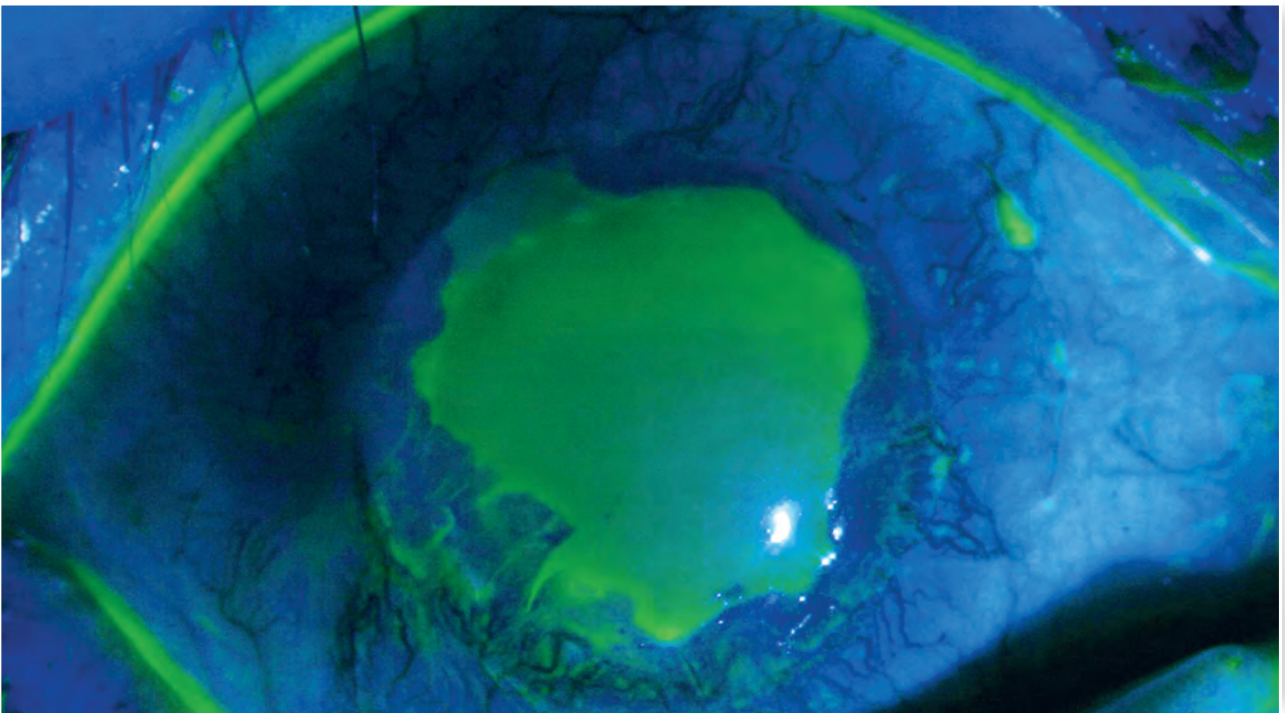
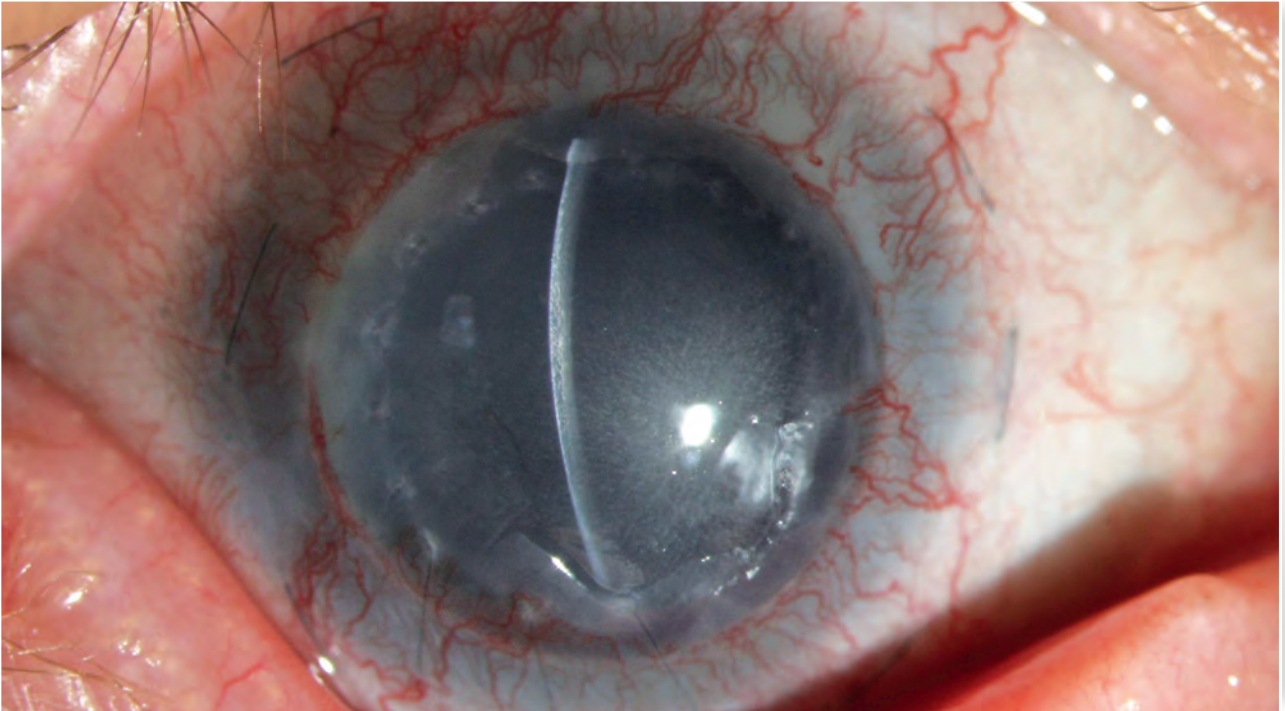
OTHER LIMBAL STEM CELL DEFICIENCIES



Aniridia-associated keratopathy.

Corneal ulcer secondary to limbal stem cell deficiency in congenital aniridia.

Congenital aniridia is a rare cause of non-acquired limbal stem cell deficiency, characterised by the complete or partial absence of the iris. Aniridia is associated with other ophthalmological anomalies such as cataracts, glaucoma or hypoplasia of the optic nerve and/or macula.



Aniridia-associated keratopathy and ulcer.

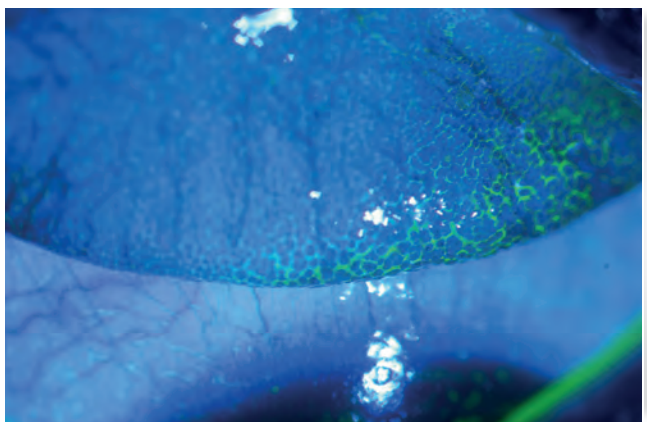
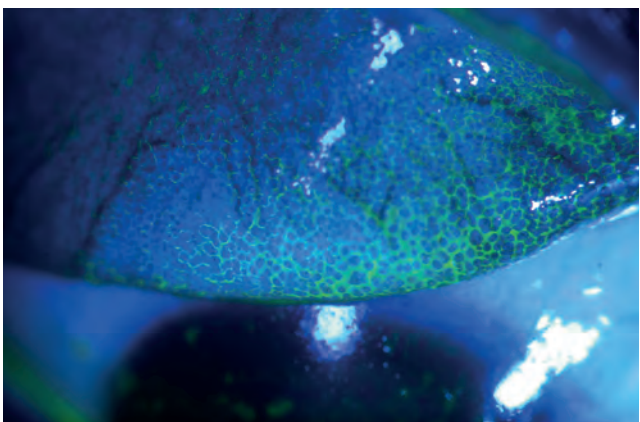
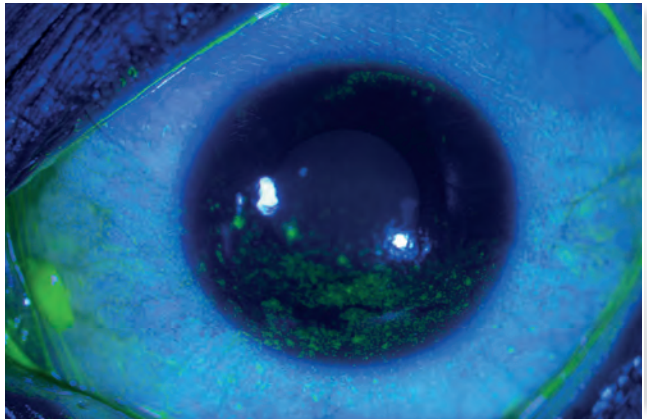
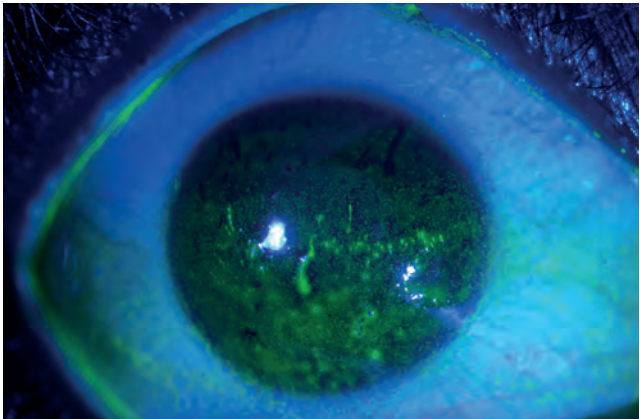
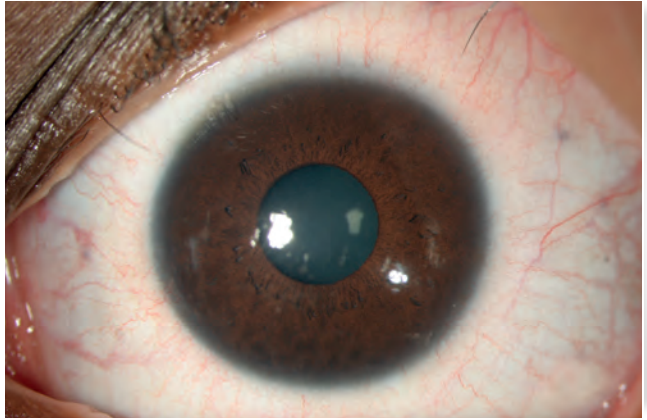
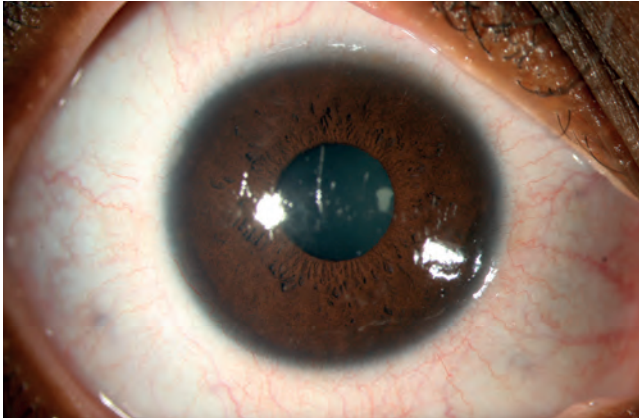
Patient with aniridia who underwent keratoplasty and overlay amniotic membrane transplantation. Recurrence of keratopathy with neovascularisation and ulcer.

DRY EYE DISEASE

- The international Dry Eye Workshop (DEWS) proposed in 2007 a definition and a classification of **dry eye disease**. It focuses on the concept of «disease» with potential damage of the ocular surface and stresses the main role of inflammation as both a triggering and auto-aggravating factor^{10,11}.
- Depending on the disorder of the tear film, two major subtypes of dry eye disease are distinguished:
 - **Aqueous deficient dry eye** where the aqueous component of the tear film is abnormal. This is related to chronic inflammation of the lacrimal and accessory lacrimal glands in conditions such as Sjogren's syndrome and graft *versus* host disease.
 - **Evaporative dry eye** or tear film instability involving disorders affecting the mucus and lipid layer.
- Physical examination may reveal conjunctival papillae, filamentary keratitis, superficial punctate keratitis in interpalpebral area and even epithelial ulceration.

10. The definition and classification of dry eye disease: report of the Definition and Classification Subcommittee of the International Dry Eye WorkShop (2007). Ocul Surf. 2007:75-92.

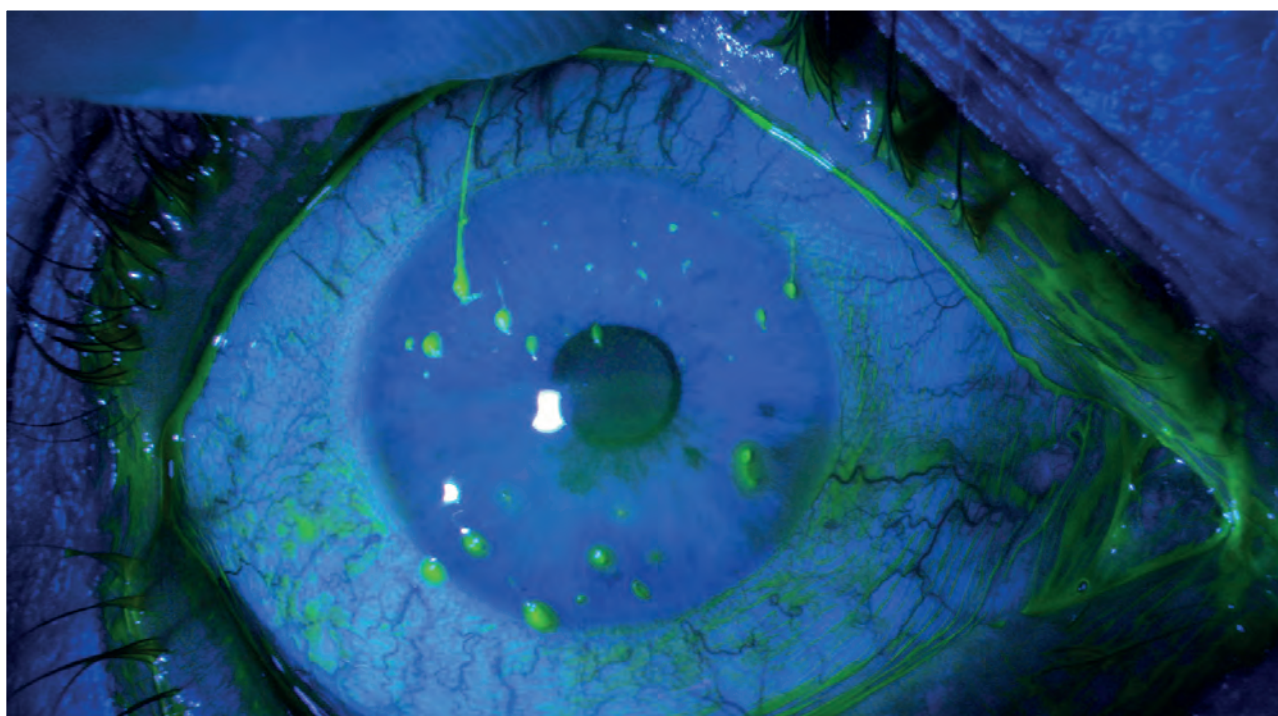
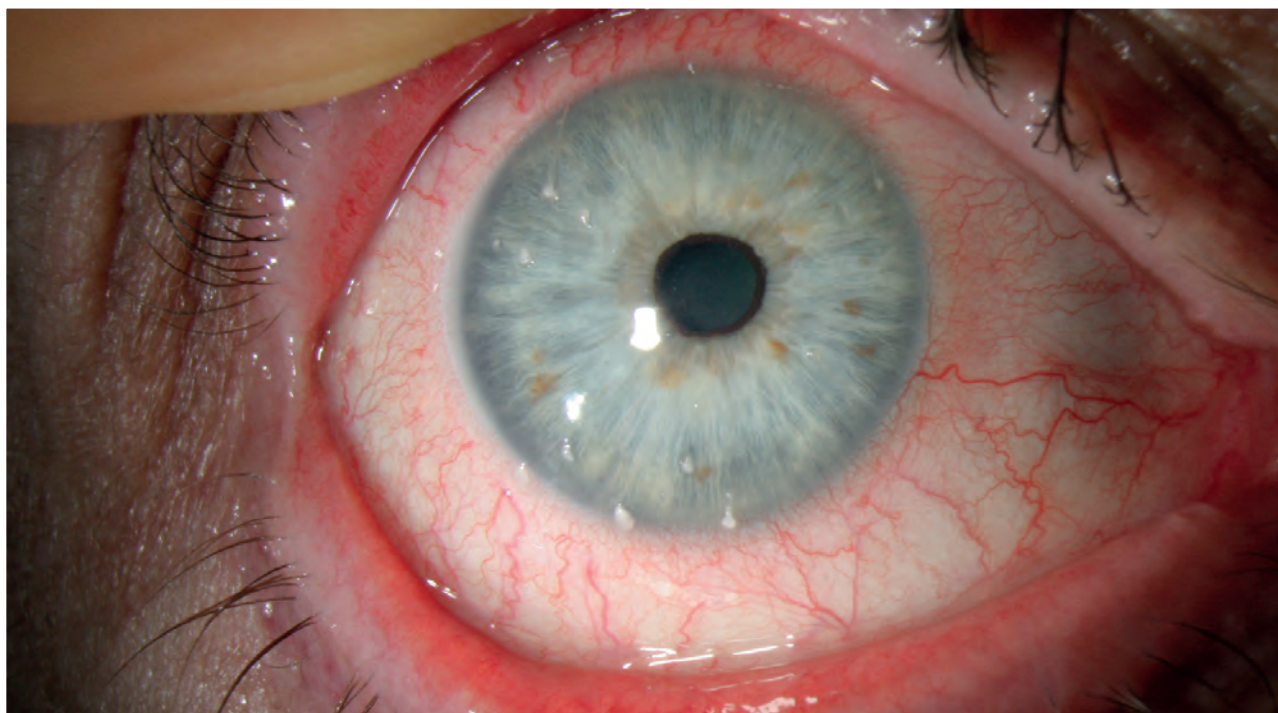
11. Management and therapy of dry eye disease: report of the Management and Therapy Subcommittee of the International Dry Eye WorkShop (2007). Ocul Surf. 2007:163-78.



Severe aqueous deficient dry eye.

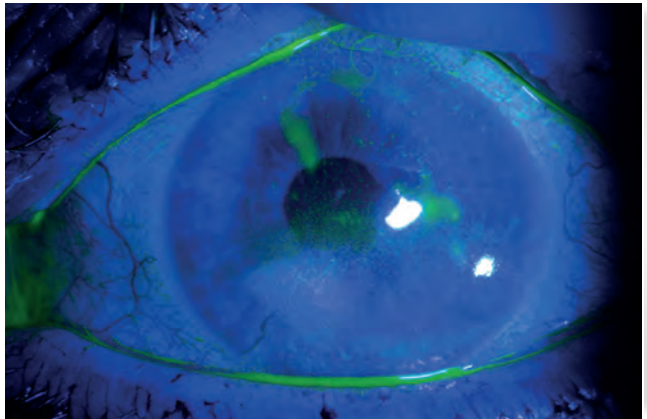
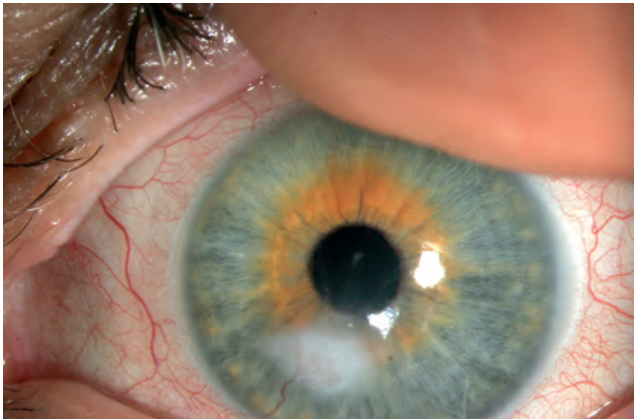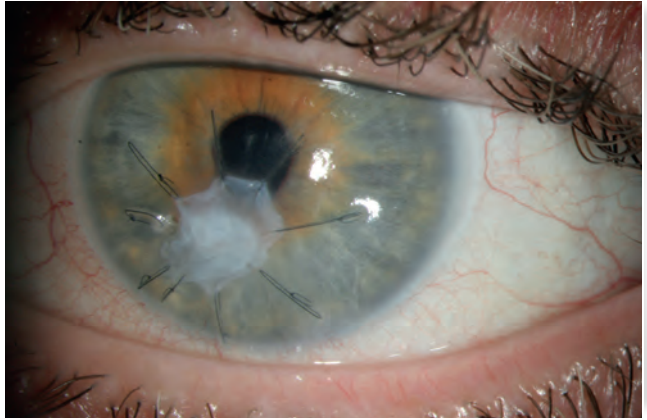
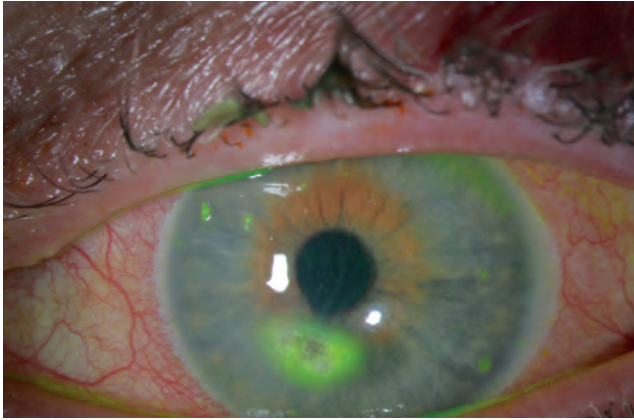
Sjögren's syndrome secondary to rheumatoid arthritis. Note the presence of conjunctival papillae and filamentary keratitis predominant in the right eye.

DRY EYE DISEASE



Dry eye syndrome in chronic graft versus host disease.

Severe filamentary keratitis in a patient suffering from multiple myeloma treated by allogeneic bone marrow transplantation.

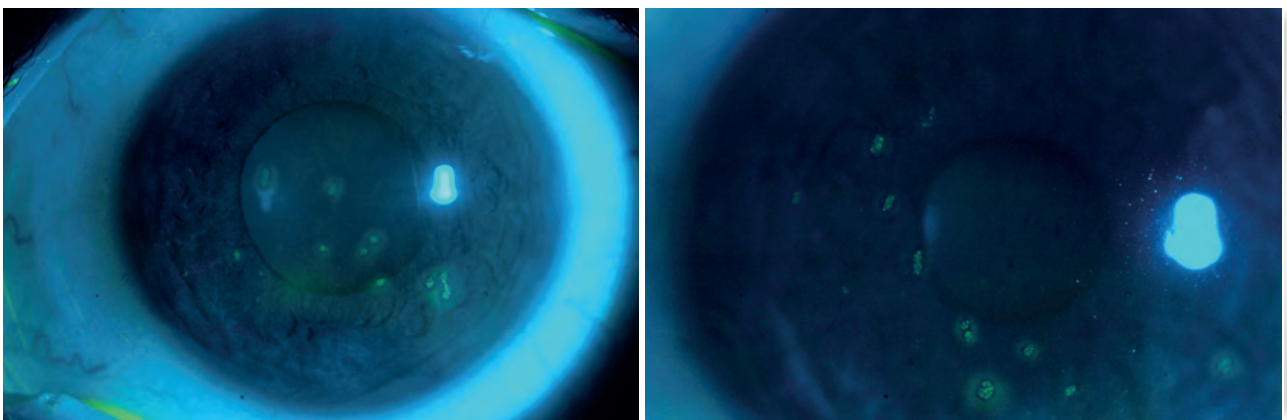
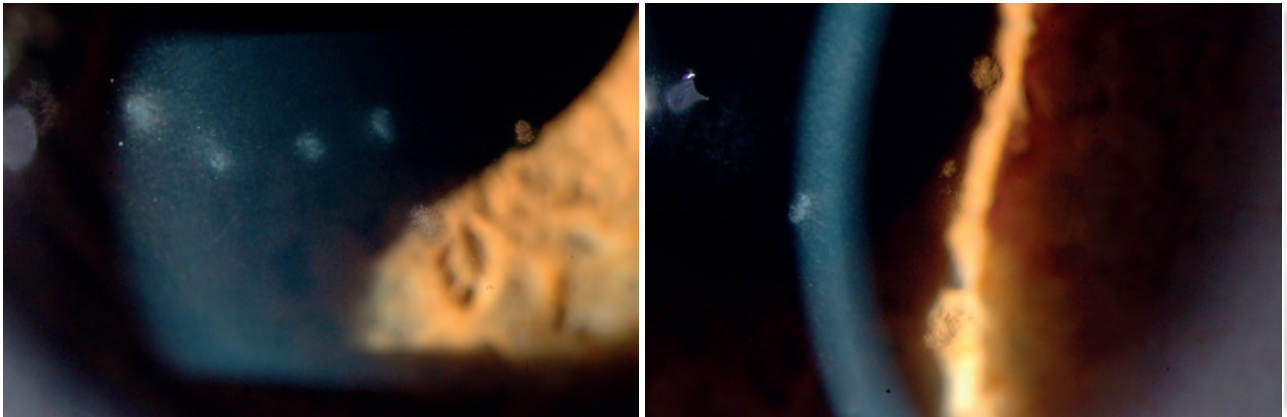
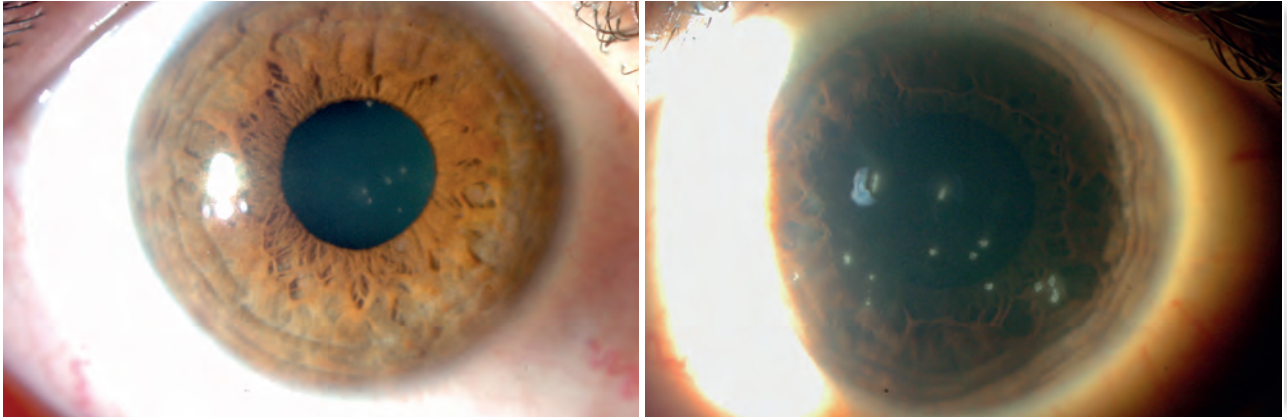


Corneal perforation in chronic graft versus host disease.

Corneal perforation is a possible complication, although rare in dry eye disease associated with graft versus host disease. Note the superior filamentary keratitis characterising severe keratoconjunctivitis sicca. Favorable clinical course after a multi layered amniotic membrane transplantation and topical steroid therapy; note the persistence of superficial punctate keratitis.

THYGESON'S SUPERFICIAL PUNCTATE KERATITIS

- This is characterised by chronic and recurrent keratitis rather than by chronic ulceration. The aetiology of **Thygeson's superficial punctate keratitis** is unknown. It presents as frequent paracentral or central intra-epithelial opacities, slightly elevated with some lesions staining positively with fluorescein. It is typically bilateral and recurrent with moderate conjunctival hyperaemia. This responds well to topical steroids. Classically, healing occurs without scar. Steroid therapy should be prescribed for a short period of time.

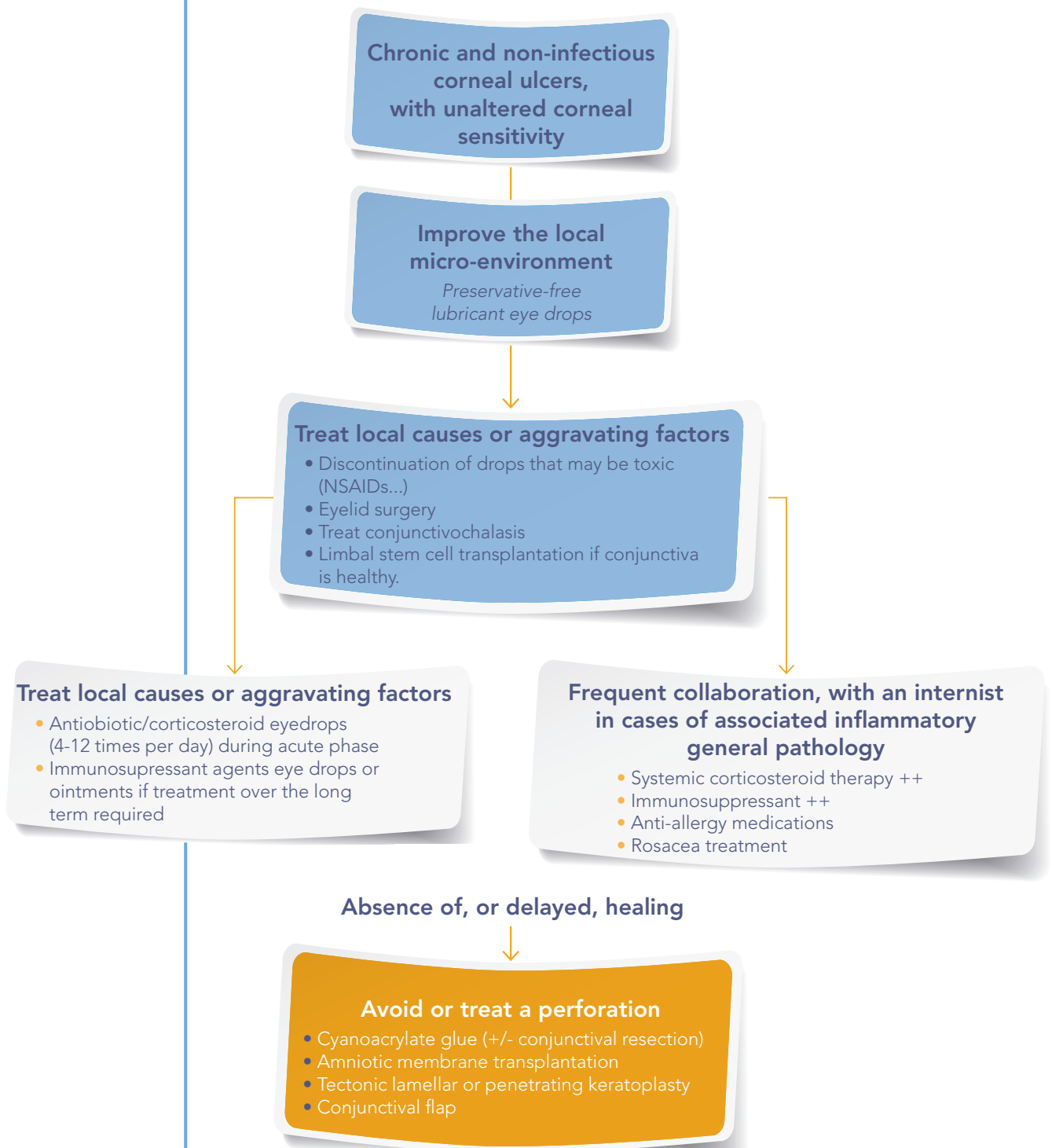


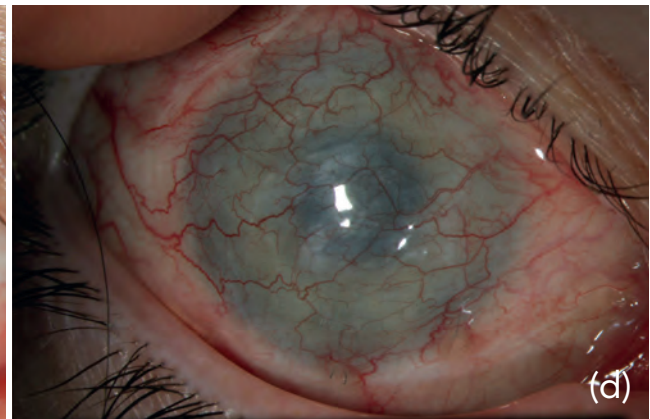
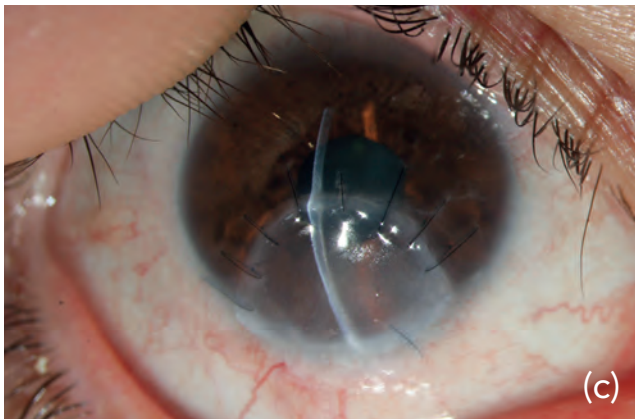
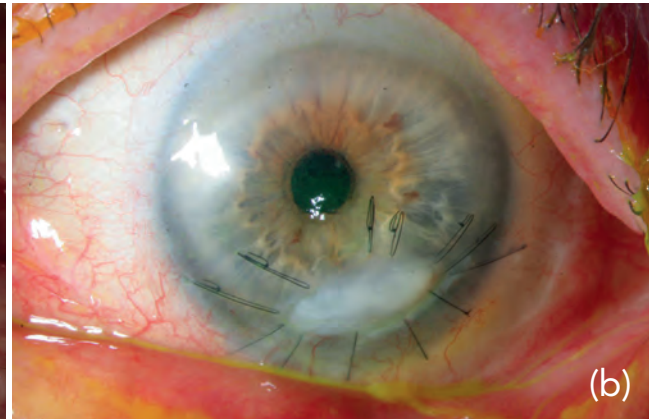
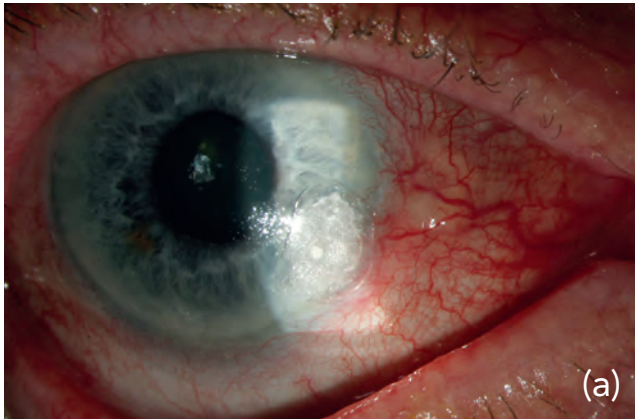
Thygeson's superficial punctate keratitis.

Note the discrete intra-epithelial opacities stained with fluorescein.

MANAGEMENT OF PERIPHERAL OR CENTRAL ULCERS WITH UNALTERED CORNEAL SENSITIVITY

- Due to the large number of aetiologies, we propose here only a therapeutic approach.





Surgical management of inflammatory corneal ulcers showing persistence or progression.

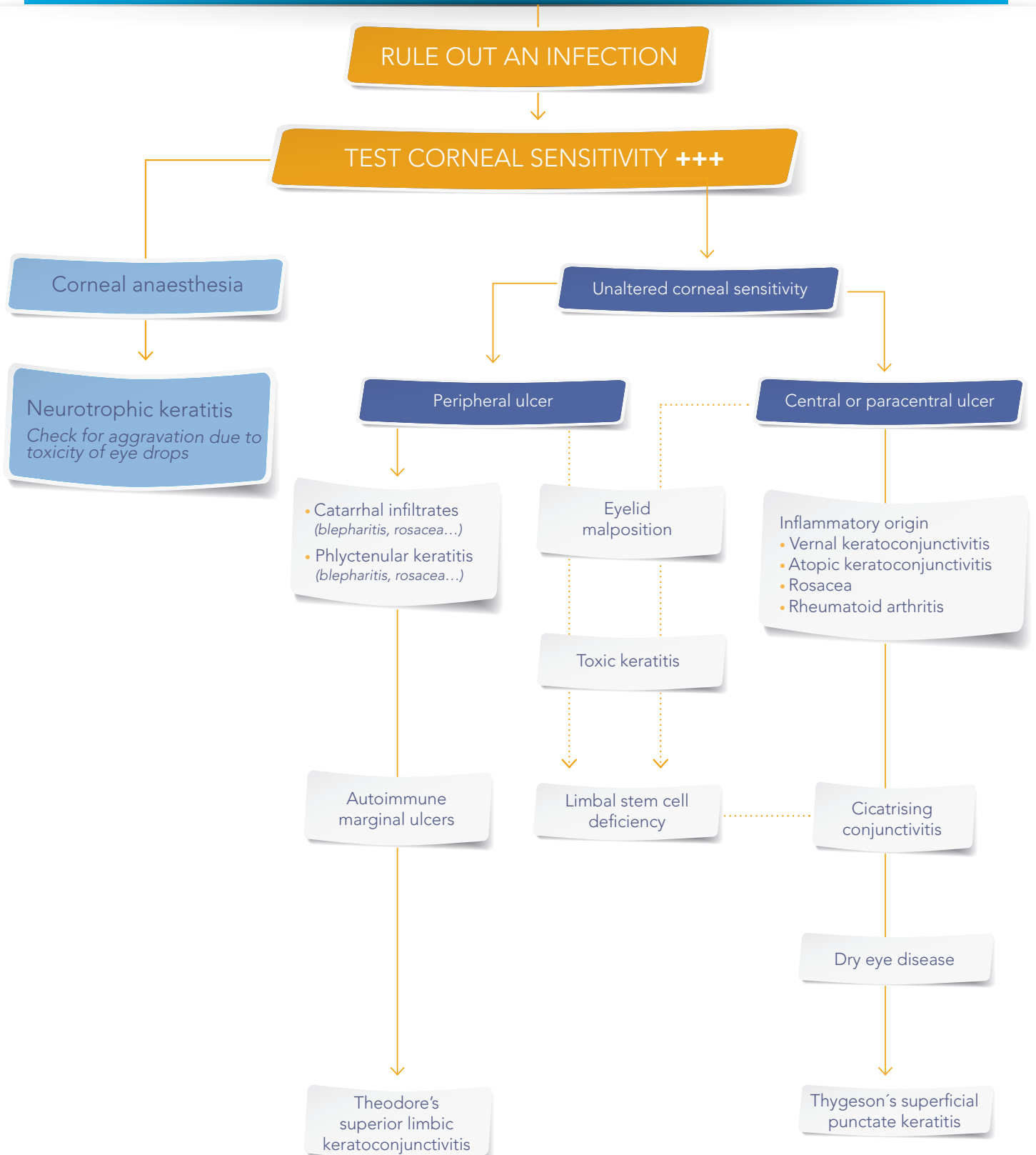
- (a) Cyanoacrylate glue
- (b) Multi layered amniotic membrane transplantation
- (c) Peripheral tectonic keratoplasty
- (d) Conjunctival flap

CONCLUSION

As illustrated throughout this atlas, there are many causes of chronic ulceration of the cornea. In conclusion therefore, let's revisit the decision algorithm on which we base our diagnostic approach. As we do so, never forget that the most important step is to test the corneal sensitivity before the application of anaesthetic eye drops, and that a simple discontinuation of ongoing treatments can often improve the situation. Finally, the handling of topical steroid therapy remains a major difficulty, as does systemic use in some cases.

*Marc Muraine
Julie Gueudry
Bernard Duchesne
François Majo*

DIFFERENTIAL DIAGNOSIS WHEN FACED WITH KERATITIS OR A CHRONIC ULCER

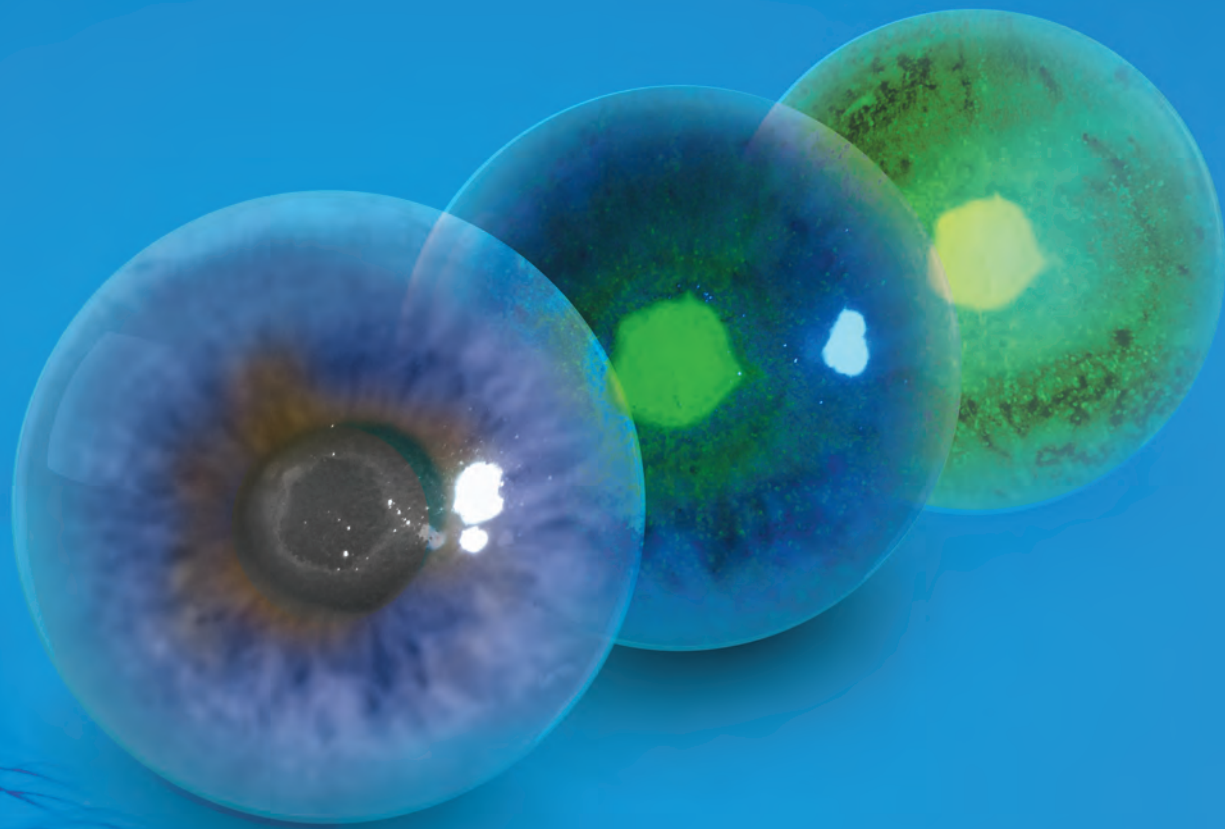




Edition

Edited by:
Laboratoires Théa
12 Rue Louis Blériot
63000 Clermont-Ferrand
Tel: +33 4 73 981 436

Laboratoires Moria SA
15 rue Georges Besse
92160 Antony



Pr Marc Muraine, Dr Julie Gueudry,
Pr Bernard Duchesne, Dr François Majo

CHRONIC CORNEAL ULCERS

Pr Marc Muraine

Dr Julie Gueudry

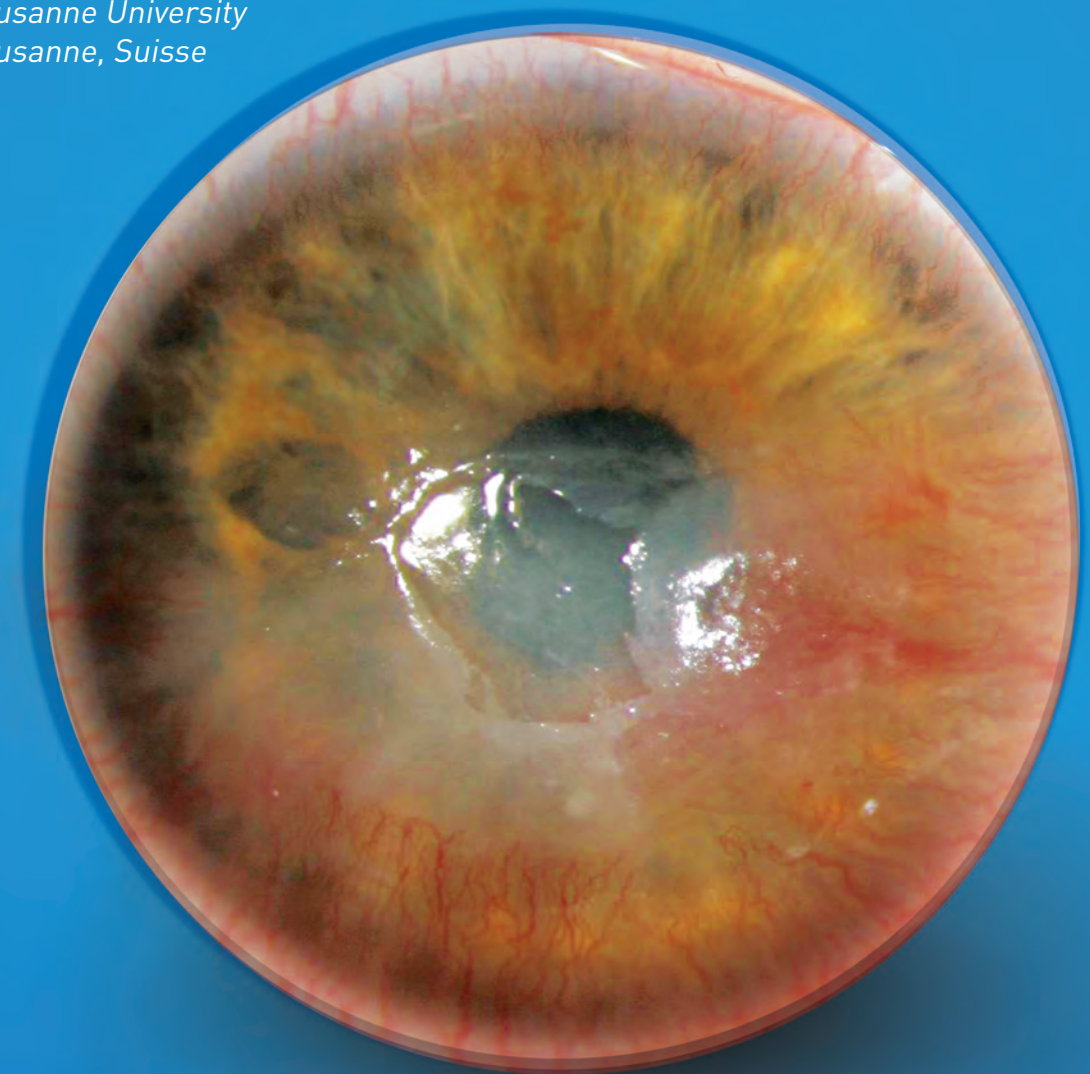*Ophthalmology department
University Hospital Charles Nicolle
Rouen, France*

Pr Bernard Duchesne

*Ophthalmology department
University Hospital
Liège, Belgique*

Dr François Majo

*MD, PhD, Privat Docent
Ophthalmic Hospital Jules-Gonin
Lausanne University
Lausanne, Suisse*



CHRONIC CORNEAL ULCERS

THE COR 0416

Théa Medical Library Collection



Laboratoires Théa
12 Rue Louis Blériot - ZI du Brézet
63017 Clermont-Ferrand cedex 2 - France
Tél. 04 73 98 14 36 - Fax 04 73 98 14 38
www.laboratoires-thea.com



Laboratoire Moria SA
15 rue Georges Besse
92160 Antony

